

Caso Clínico / Radiological Case Report

LEFT VENTRICULAR FALSE ANEURYSM CHARACTERIZED BY CARDIOVASCULAR MAGNETIC RESONANCE AND LATE ENHANCEMENT TECHNIQUE

CARACTERIZAÇÃO POR RESSONÂNCIA MAGNÉTICA CARDÍACA E TÉCNICA DE REALCE TARDIO DE UM PSEUDOANEURISMA DO VENTRÍCULO ESQUERDO

Luísa Costa Andrade¹, Paulo Donato², Maria João Ferreira³, Filipe Caseiro Alves⁴

¹Radiology Resident - Medical Imaging Department and Faculty of Medicine, University Hospital of Coimbra.

²Radiologist - Medical Imaging Department and Faculty of Medicine, University Hospital of Coimbra.

³Cardiologist - Cardiology Department and Faculty of Medicine, University Hospital of Coimbra.

⁴Radiologist (Head of Department) - Medical Imaging Department and Faculty of Medicine, University Hospital of Coimbra.

Abstract

Left ventricular pseudoaneurysm is a rare complication of myocardial infarction. Differentiation between true and false aneurysms, although difficult, is crucial, because of the different treatment options they entail.

We present a rare case of a giant pseudoaneurysm of the left ventricle related with a previous myocardial infarction. The present case highlights the pivotal role of magnetic resonance imaging for differential diagnosis between these entities.

Key-words

Left ventricle, magnetic resonance imaging, myocardial infarction, pericardium, pseudoaneurysm.

Resumo

O pseudoaneurisma do ventrículo esquerdo é uma complicação rara do enfarte do miocárdio. A distinção entre os aneurismas verdadeiros e falsos, apesar de difícil, é crucial devido às diferentes opções de tratamento que eles acarretam.

Apresentamos um caso raro de um pseudoaneurisma de grandes dimensões do ventrículo esquerdo, relacionado com um enfarte do miocárdio antigo. O presente caso destaca o papel fundamental da ressonância magnética para o diagnóstico diferencial entre estas duas entidades.

Palavras-chave

Ventrículo esquerdo, ressonância magnética, enfarte do miocárdio, pericárdio, pseudoaneurisma.

Correspondência

Luísa Costa Andrade
Medical Imaging Department and Faculty of Medicine, University Hospital of Coimbra.
Praceta Mota Pinto,
3000-075 Coimbra, Portugal
Email: isa.c.andrade@hotmail.com

Recebido a 20/01/2014
Aceite a 25/05/2014

Introduction

Rupture of the left ventricular free wall is a catastrophic complication occurring in 4% of patients after acute myocardial infarction. Though rare, the rupture may be contained by adherent pericardium or scar tissue, giving rise to a pseudoaneurysm.

Differentiation between true and false aneurysms, although difficult, is crucial, because true aneurysms tend to be managed conservatively whereas false aneurysms, because of the risk of rupture, are usually treated with urgent surgery. Distinguishing these two subtypes is therefore critical and cardiovascular magnetic resonance has a major role. The present case highlights the pivotal role of non-invasive imaging modalities, mainly magnetic resonance (MR) and pericardial delayed enhancement technique, for differential diagnosis between these entities in order to ensure appropriate management of these patients.

Case Report

A 78 year-old man with a history of myocardial infarction (8 years before) was admitted to our hospital with dyspnea (NYHA III), without angina. He had a mechanical aortic valve prosthesis since 2001. Routine transthoracic echocardiography showed a saccular extra-cardiac structure. A multidetector computed tomography (MDCT) was performed and showed an aneurysmatic enlargement of the anterior-inferior left ventricular wall measuring about 10cm. After administration of contrast material the lesion filled intensely, allowing us to exclude a pericardial cyst. We were not able to see the communication with the left ventricle and we were unable to distinguish a true aneurysm from a pseudoaneurysm (figure 1).

Cardiac MR imaging was performed and showed a large narrow-necked aneurysmal dilatation, arising from the infero-lateral wall of the left ventricle (LV) It was clearly demonstrated the communication of the dilatation with the left ventricle (figure 2).

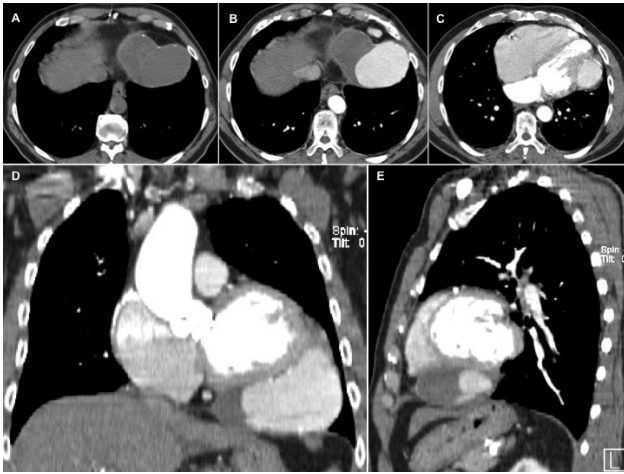


Fig. 1 - Axial unenhanced CT scan (A) shows a homogeneous mass with dense fluid attenuation, adjacent to infero-lateral left ventricular wall limited by pericardium with small calcifications. Axial contrast-enhanced CT scan (B and C) shows intense partial filling of the lesion with contrast material. D and E images show coronal and sagittal reformations, respectively.

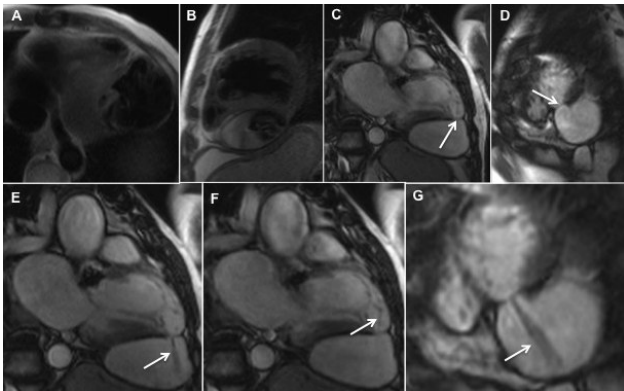


Fig. 2 - T2-w black-blood half-Fourier turbo spin-echo (HASTE) MR images - transverse (A) and sagittal (B) views show wall rupture of the left ventricular infero-lateral wall, resulting in a large left ventricular pseudoaneurysm with thrombus. Vertical long-axis view (C) and short-axis view (D) through the plane of the neck of the pseudoaneurysm, obtained with a fast steady-state cine MR imaging sequence, show a narrow interruption (arrows) of the infero-lateral left ventricular wall and formation of a bulging cavity. Note that the maximal width of the orifice is shorter than the maximal parallel internal diameter, a typical feature of false aneurysm. Oblique vertical long-axis view (E and F) and short-axis view (G) steady-state free precession MR images, through the plane of the neck of the pseudoaneurysm, clearly demonstrate the pseudoaneurysm and its communication with the left ventricle. There is a signal void jet flow (arrows) through the aneurysmal sac during the systole and another during diastole into the left ventricle.

The pericardium that was adherent to the wall of this pseudoaneurysm demonstrated late gadolinium enhancement (LGE) with associated mural thrombus, while the adjacent myocardium in the remaining wall returned a normal nulled signal (figure 3).

After extensive discussion of the potential risks and benefits of the surgical treatment, the patient refused this option.

Discussion

Left ventricular aneurysms can be subdivided into true and false aneurysms and both are complications of myocardial infarction. They are occurring much less frequent after myocardial infarction due to implementation of effective early revascularization strategies.

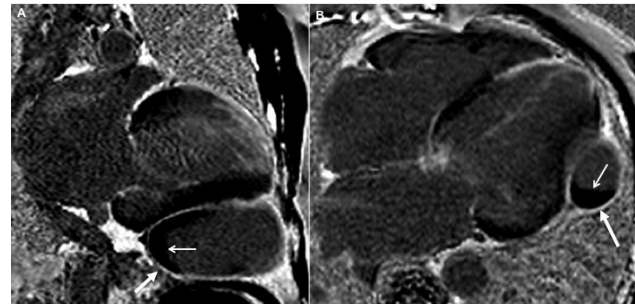


Fig. 3 - Vertical long-axis (A) and horizontal long-axis (B) views obtained with inversion-recovery-prepared breath-hold cine gradient-echo sequence, 10 minutes after injection of gadolinium, show delayed enhancement of the pericardium that forms the wall (large arrows) of the false aneurysm, as well as hypointense thrombus (small arrows) that abuts the false aneurysm wall.

The lesions are usually first identified with echocardiography or catheter angiography, but with the widespread availability of MDCT, some of these aneurysms are now being detected on routine CT.

Regarding catheter angiography, left ventriculography is considered the gold standard imaging modality, with diagnostic accuracy of around 85% (1). However, it is an invasive technique that also exposes the patient to ionizing radiation and presents a risk of possible embolization. On the other hand, transthoracic echocardiography is usually the first non-invasive imaging technique used for the assessment of patients with myocardial infarction due to its accessibility and repeatability, but the differential diagnosis between ventricular pseudoaneurysms and true aneurysms based on echocardiographic findings is sometimes difficult mainly due to the limited narrow echo window. Another important limitation of echocardiography is the inferior rate of detection of left ventricular thrombi comparing to cardiovascular MR imaging (2). MDCT is usually a second-line option in this context because it requires the use of iodinated contrast and exposes the patient to ionizing radiation. The advantage of this technique over MR imaging is the higher spatial resolution which enables accurate assessment of the coronary artery system.

Nevertheless, cardiovascular MR imaging is the most precise imaging tool that enables correct characterization and distinction between true and false LV aneurysms and enables tissue characterization.

True LV aneurysms occur most commonly in the setting of a transmural myocardial infarction and are defined as an area of bulging of the thinned and scarred myocardium which is dyskinetic, but involve the full thickness of the wall (3). Early focal ventricular expansion has been reported within 48h in approximately 50% of patients who develop aneurysms, while the remaining patients have evidence of aneurysm formation at 2 weeks (4).

They are more commonly found in the anteroapical wall following occlusion of the left anterior descending coronary artery. Less common causes include trauma, Chagas disease and sarcoidosis (4).

Rupture of the LV free wall is a catastrophic complication occurring in 4% of patients after acute myocardial infarction and in 23% of those who die of myocardial infarction (5). Though rare, the rupture of the ventricular free wall may be contained by adherent pericardium or scar tissue, giving rise

to a saccular formation with no myocardial fibers, which is termed a pseudoaneurysm. This usually occur 5-10 days post myocardial infarction (1,6) and if untreated has a risk of rupture of 30-45% (7).

Usually, myocardial rupture produces haemopericardium, tamponade and death. Occasionally, an organizing thrombus and hematoma, together with the pericardium and inflammatory tissue, seal the rupture of the LV, producing a cavity that lacks any elements of the original myocardial wall and communicates with the LV cavity through the point of rupture. Transmural myocardial infarction is the commonest cause of LV pseudoaneurysm, but it may result from cardiac surgery, trauma and endocarditis (1). False aneurysms arise more commonly from the base of the inferior and inferolateral wall (1), secondary to inferior wall myocardial infarction. The reason for this uneven distribution is explained by the fact that anterior wall rupture is more fatal and there is no chance of forming a pseudoaneurysm compared to an inferior or posterior wall rupture (5).

From a clinical standpoint, patients may be asymptomatic (up to 48% of cases), hence the diagnosis may be delayed as in this case (6), or present with recurrent chest pain, signs of heart failure, syncope or thromboembolic phenomena (1,8). Sudden death is the form of presentation of ventricular pseudoaneurysm in only 3% of cases (8).

Differentiation between true and false aneurysms can be difficult, but is of major importance distinguish the two because of the different treatment methods recommended. True aneurysms are unlikely to rupture following the early post-infarction period and are often managed medically unless they cause symptoms related to congestive heart failure or arrhythmia unresponsive to medical treatment. On the other hand, since untreated LV pseudoaneurysm has a greater tendency to rupture compared to LV true aneurysm, early surgical intervention is recommended (9). However, management of chronic LV pseudoaneurysms is controversial, and risk of rupture and embolism should be weighed against the estimated risk of surgery (10).

Cardiovascular MR imaging has been used since 1991 to improve diagnosis of ventricular pseudoaneurysms (8,11) and is now considered to be the most powerful tool for detecting and characterizing ventricular aneurysms (12-15).

Besides providing information on overall morphology and left ventricular wall motion and function, particularly ventricular volumes and systolic and valve function, cardiovascular MR imaging provides better morphological definition of a pseudoaneurysm's location, extension, its relations to adjacent structures and the presence of thrombi. Moreover, LGE sequences enable accurate assessment of the location and extent of the infarcted area and of viable myocardium, thus contributing to pre-operative planning. This cardiovascular MR study involve an inversion recovery sequence performed at 10-15 min post iv injection of gadolinium. On the images obtained, normal myocardium is nulled to produce a low signal while areas of fibrosis demonstrate significant increased signal owing to local gadolinium accumulation.

Although both types of aneurysms show late enhancement in the wall of the aneurysm sac, enhancement of the pericardium has been shown more frequently in patients with false aneurysms and is thought to represent the effects of seepage of blood into the pericardial space at the time of rupture,

with subsequent pericardial inflammation and fibrosis (13). Pericardial delayed enhancement (not only bordering the false cavity but in areas surrounding normal myocardium) has then been proposed as a useful method of distinguishing between pseudoaneurysm and true ventricular aneurysm, with a sensitivity of 100% and specificity of 83% (8,13).

Given its many advantages, cardiovascular MR imaging has an enormous potential to differentiate between ventricular aneurysms and pseudoaneurysms.

Certain cardiovascular MR imaging features are more suggestive of a false aneurysm: narrow neck in relation to the aneurysm sac (orifice to aneurysm diameter ratio < 1), origin of the inferior-lateral wall, discontinuity of the myocardium at the neck of the aneurysm, absence of coronary arteries overlying the aneurysm and delayed pericardial enhancement in the wall of the pseudoaneurysm (table I).

As in this case, the MR findings can provide accurate information to distinguish true from false aneurysms and to guide subsequent surgical intervention.

Table I - Differences between left ventricular aneurysms and pseudoaneurysms.

	LV Aneurysm	LV Pseudoaneurysm
Location	antero-apical wall	infero-lateral wall
Wall layers	3 wall layers	absence of myocardium
Contractility	non contractile	dyskinesia
Aneurysmal neck diameter	wide	narrow
Ratio of maximal internal width of the orifice to maximal parallel internal diameter	≥1	< 1
Late gadolinium enhancement	late myocardial enhancement	late pericardial enhancement in the wall of the false aneurysm
Treatment	Medical or Surgical therapy	Surgery

Conclusion

Differentiation between true and false LV aneurysms, although difficult, is of major importance because of the different treatment methods recommended: true aneurysms are often managed medically and false aneurysm requires an early surgical intervention because of their greater tendency to rupture.

There are cardiovascular MR imaging features suggestive of a false aneurysm: narrow neck in relation to the aneurysm sac (orifice to aneurysm diameter ratio < 1), origin of the inferior-lateral wall, discontinuity of the myocardium at the neck of the aneurysm, absence of coronary arteries overlying the aneurysm and delayed pericardial enhancement in the wall of the pseudoaneurysm.

References

- 1 - Frances, C.; Romero, A.; Grady, D. - *Left ventricular pseudoaneurysm*. J Am Coll Cardiol, 1998, 32: 557-561.
- 2 - Oliveira, S. M.; Dias, P.; Pinho, T. et al. - *Giant left ventricular pseudoaneurysm: The diagnostic contribution of different non-invasive imaging modalities*. Rev Port Cardiol., 2012 Jun, 31(6):439-44.
- 3 - Brown, S. L.; Gropler, R. J.; Harris, K. M. - *Distinguishing left ventricular aneurysm from pseudoaneurysm: A review of the literature*. Chest, 1997, 111:1403-1409.
- 4 - Shambrook, J. S.; Chowdhury, R.; Brown, I. W.; Peebles, C. R.; arden, S. P. - *Cross-sectional imaging appearances of cardiac aneurysms*. Clin Radiol., 2010 May, 65(5):349-57.
- 5 - Pollak, H.; Nobis, H.; Miczoc, J. - *Frequency of left ventricular free wall ruptures complicating acute myocardial infarction since the advent of thrombolysis*. Am J Cardiol, 1994, 74:184-186.

-
- 6 - Yeo, T. C.; Malouf, J. F.; Oh, J. K.; Seward, J. B. - *Clinical profile and outcome in 52 patients with cardiac pseudoaneurysm*. Ann Intern Med, 1998, 128:299-305.
- 7 - Catherwood, E.; Mintz, G. S.; Kotler, M. N. et al. - *Two-dimensional echocardiographic recognition of left ventricular pseudoaneurysm*. Circulation, 1980, 62:294-303.
- 8 - Gill, S.; Rakhit, D. J.; Ohri, S. K. et al. - *Left ventricular true and false aneurysms identified by cardiovascular magnetic resonance*. Br J Radiol., 2011, 84:e35-7.
- 9 - Vlodaver, Z.; Coe, J. I.; Edwards, J. E. - *True and false left ventricular aneurysms: Propensity for the latter to rupture*. Circulation, 1975, 51:567-572.
- 10 - Moreno, R.; Gordillo, E.; Zamorano, J. et al. - *Long term outcome of patients with postinfarction left ventricular pseudoaneurysm*. Heart, 2003, 89:1144-1146.
- 11 - Harrity, P.; Patel, A.; Bianco, J. et al. - *Improved diagnosis and characterization of postinfarction left ventricular pseudoaneurysm by cardiac magnetic resonance imaging*. Clin Cardiol., 1991, 14:603-6.
- 12 - Baks, T.; Cademartiri, F.; Spierenburg, H. A.; de Feyter, P. J. - *Chronic pseudoaneurysm of the left ventricle*. Int J Cardiovasc Imaging, 2006, 22:497-499.
- 13 - Konen, E.; Merchant, N.; Gutierrez, C. et al. - *True versus false left ventricular aneurysm: differentiation with MR imaging initial experience*. Radiology, 2005, 236:65-70.
- 14 - Heatlie, G. J.; Mohiaddin, R. - *Left ventricular aneurysm: comprehensive assessment of morphology, structure and thrombus using cardiovascular magnetic resonance*. Clin Radiol., 2005, 60:687-692.
- 15 - Tran, T.; Ross, B. D.; Colletti, P.; Ching, R. E. - *Gd-enhanced cardiovascular MR imaging to identify left ventricular pseudoaneurysm*. J Cardiovasc Magn Reson, 2005, 7:717-721.