

PHARMACOEPIDEMIOLOGY AND DRUG SAFETY 2014; 23: 221–233

Published online 27 January 2014 in Wiley Online Library (wileyonlinelibrary.com) DOI: 10.1002/pds.3566

## REVIEW

## Ophthalmic adverse drug reactions to systemic drugs: a systematic review

Ana Miguel<sup>1,2\*</sup>, Filipe Henriques<sup>2</sup>, Luís Filipe Azevedo<sup>1</sup> and Altamiro Costa Pereira<sup>1</sup><sup>1</sup>Center for Research in Health Technologies and Information Systems (CINTESIS) and Department of Health Information and Decision Sciences, Faculty of Medicine, University of Porto, Portugal<sup>2</sup>Department of Ophthalmology, Central University Hospital of Coimbra, Coimbra, Portugal

## ABSTRACT

**Purpose** To perform a comprehensive and systematic review regarding ophthalmic adverse drug reactions (ADRs) to systemic drugs to: (i) systematically summarize existing evidence, (ii) identify areas, ophthalmic ADRs or drugs that lacked systematization or assessment (namely drugs with original studies characterizing specific ophthalmic ADRs but without causality assessment nor without meta-analysis).

**Methods** Systematic review of several electronic databases (last search 1/7/2012): Medline, SCOPUS, ISI web of knowledge, ISI Conference Proceedings, International Pharmaceutical Abstracts and Google scholar. Search query included: eye, ocular, ophthalmic, ophthalmology, adverse and reaction. Inclusion criteria were: (i) Primary purpose was to assess an ophthalmic ADR to a systemic medication; (ii) Patient evaluation performed by an ophthalmologist; (iii) Studies that specified diagnostic criteria for an ocular ADR. Different types of studies were included and analyzed separately. Two independent reviewers assessed eligibility criteria, extracted data and evaluated risk of bias.

**Results** From 562 studies found, 32 were included (1 systematic review to sildenafil, 11 narrative reviews, 1 trial, 1 prospective study, 6 transversal studies, 6 spontaneous reports and 6 case series). Drugs frequently involved included amiodarone, sildenafil, hydroxychloroquine and bisphosphonates. Frequent ophthalmic ADRs included: keratopathy, dry eye and retinopathy.

**Conclusions** To increase evidence about ophthalmic ADRs, there is a need for performing specific systematic reviews, applying strictly the World Health Organization's (WHO) definition of ADR and WHO causality assessment of ADRs.

Some ophthalmic ADRs may be frequent, but require ophthalmological examination; therefore, ophthalmologists' education and protocols of collaboration between other specialties whenever they prescribe high-risk drugs are suggestions for the future. Copyright © 2014 John Wiley & Sons, Ltd.

KEY WORDS—adverse drug reactions; clinical pharmacology; pharmacoepidemiology; ophthalmology

Received 13 March 2013; Revised 10 November 2013; Accepted 9 December 2013

## INTRODUCTION

Ophthalmology is perhaps one of the medical specialties in which there are the fewest assessed adverse drug reactions (ADRs), representing a particular challenge in Pharmacovigilance.<sup>1</sup> However, the eye is a complex organ in which minimal impairment can produce a substantial functional effect.<sup>2</sup> Ophthalmic ADRs are usually not continuously detected, although they might be either frequent or specific of a drug or drug group, such as acute angle-closure glaucoma and myopic shift caused by topiramate,<sup>3</sup> cataracts provoked by

corticosteroids,<sup>4</sup> floppy iris syndrome caused by tamsulosine<sup>5</sup> and uveitis caused by rifabutin.<sup>6</sup>

Some ADRs are rare but can cause irreversible blindness (such as in optic atrophy provoked by ethambutol),<sup>7</sup> while others are extremely frequent but usually harmful (namely *cornea verticillata* caused by amiodarone).<sup>8</sup>

There are reports that suggest ophthalmic ADRs provoked by a systemic drug, but remain unsupported because no systematic review has been performed. Many ophthalmic ADRs have been identified solely due to spontaneous reports, namely blurred vision caused by leuprolide,<sup>9</sup> or other ophthalmic ADRs caused by different drugs such as bisphosphonates, cetirizine or isotretinoin.<sup>2</sup> Therefore, on the one hand, prospective studies or trials should be performed to study the causality of each drug to each ophthalmic ADR; on the other hand, a systematic review should

\*Correspondence to: A. Miguel, Department of Health Information and Decision Science, Faculty of Medicine of Oporto, Rua Quinta do Sardoal, VE3, nº10, 4430–182 V.N.Gaia, Portugal. Email: myworld\_ana@hotmail.com

be performed to clarify and assess what ophthalmic ADRs can occur after the correct prescription of each drug. A systematic review would be useful not only to identify drugs in which ophthalmic ADRs are frequent or serious, but also to increase knowledge of physicians (prescribing physicians and ophthalmologists), enabling a greater detection of ophthalmic ADRs after an ophthalmic examination and enabling the construction of multi-disciplinary protocols whenever a high-risk drug is prescribed.

General ADRs are estimated to cause of 2.7% to 15.7% hospital admissions and to occur in 16.9% of hospitalized patients (confidence interval 95%: 13.6%, 20.2%).<sup>11</sup> In a study performed in the United States (US), it was estimated that more than 100 000 people die every year as a consequence of fatal ADRs, placing fatal ADRs between the fourth and sixth leading causes of death in the US.<sup>12</sup> However, the specific frequency of ophthalmic ADRs is not known.

Although there are several studies about ophthalmic ADRs, this theme presents with specific difficulties,<sup>13,14</sup> and the methods of identification and reporting ADRs vary greatly.<sup>15,16</sup> Some studies have established recommendations,<sup>17,18</sup> and others offer guidelines to performing systematic reviews of studies of ophthalmic ADRs.<sup>19,20</sup>

We intended to perform a general systematic review about ophthalmic ADRs to systemic drugs in order to, on the one hand, systematically summarize existing evidence, and on the other hand, identify areas of specific ophthalmic ADRs or drugs that lacked systematization or assessment. This includes the identification of drugs that cause specific ophthalmic ADRs which are well described in original studies but without systematic review nor meta-analysis (therefore, opportunities for specific systematic reviews with meta-analysis in the future are also identified).

## METHODS

We performed a systematic review of studies that assessed ophthalmic ADRs to systemic drugs according to the guidelines of the Cochrane Collaboration<sup>19</sup> and PRISMA Statement,<sup>21</sup> adapted to this theme.

### Definitions

We used the following definition for *adverse drug reaction*: “any noxious, unintended and undesired effect of a drug, which occurs at doses used in humans for prophylaxis, diagnosis, or therapy”, according to the World Health Organization (WHO) definition<sup>22</sup> of 1972.

An adverse event is: “an injury related to medical management, in contrast to complications of disease”.<sup>23</sup> Medical management includes all aspects of care, including diagnosis and treatment, failure to diagnose or treat and the systems and equipment used to deliver care.<sup>23</sup> Therefore, to increase specificity, we wanted to assess only adverse drug reactions.

### Search methods

We searched through several electronic databases (last date of search was 1/7/2012): Medline, SCOPUS, ISI web of knowledge, ISI Conference Proceedings, International Pharmaceutical Abstracts and Google scholar. We used a search query created after a pilot study to add specificity (full search query available if requested to the corresponding author) that included the terms: eye, ocular, ophthalmic, ophthalmology, adverse and reaction. We searched for grey literature and unpublished data and hand-searched all references of included studies and relevant reviews.

### Selection criteria

Studies were included if they followed all **inclusion criteria** listed below:

- (1) Studies in which the primary purpose was to assess an ophthalmic ADR to a systemic medication. Since there is a wide misuse of the terms ADR, adverse event (AE) and adverse drug event (ADE), we obtained also the full text of studies who claimed to assess AEs or ADEs, to verify their methodology, and to include the studies that actually assessed ADRs, although they called it AEs or ADEs.
- (2) Studies with patient evaluation performed by an ophthalmologist.
- (3) Studies that specified diagnostic criteria for an ocular ADR.

We also included studies with different languages (we hired a translator), any country and experimental studies (if any). We did so to have a more thorough and complete literature search. We did not exclude systematic nor narrative reviews if they added useful information about ocular ADRs, as we intended to have a general overview that summarized and added further systematization to existing evidence, and to identify areas or specific ophthalmic ADRs that lacked systematization or assessment.

### Exclusion criteria:

- (1) Studies assessing adverse events that did not correspond to ADRs (for example, we excluded

reports of capsular rupture in phacoemulsification surgery, but we did not exclude reports of capsular rupture due to intra-operative floppy iris syndrome, a syndrome that is an ADR provoked by tamsulosine or other drugs).

- (2) Systemic ADRs to topical ophthalmic drugs, or ophthalmic ADRs to topical ophthalmic drugs (they were not the purpose of our study and would increase heterogeneity and reduce clarity of our study).
- (3) Studies that were comments or letters, if they would not add new scientific evidence to our review. However, letters or comments that included case reports not published elsewhere about specific ocular ADRs were not excluded, in order to identify rare ophthalmic ADRs.
- (4) Studies assessing drugs already removed from the market.

#### *Data collection and extraction*

Two independent reviewers, AM and FH, first examined each title and abstract to exclude obviously irrelevant reports and then independently examined each full text report, to determine eligibility according to inclusion criteria. Disagreements were solved by consensus, recorded and analyzed using kappa statistics.

Primary outcome was the presence and type of ocular ADR and the respective causative systemic drug. Secondary outcomes included: ocular structure affected, diagnosis, serious or vision-threatening ADR. All symptoms, visual acuity (VA), signals and results of complementary examination performed at presentation were recorded, as well as after a follow-up. Attitude or treatment performed for each ADR was also registered (suspension of the causative drug, specific treatment, administration of an antidote, no treatment necessary). If VA was not recorded in the logMAR scale,<sup>24</sup> it was converted.

We always assessed the drug name, identified the therapeutic drug class according to Anatomical Therapeutic Chemical Classification System of WHO<sup>25</sup> and reported the number of days during which the drug was used and the administration route (if that information was available). We verified if causality was assessed in the original studies (and according to what classification, preferably WHO's<sup>23</sup> or Naranjo's,<sup>26</sup> and respective results) as well as predictability of ADRs (using Hartwig's predictability scale, for example),<sup>27</sup> preventability (e.g. Schumok & Thornton's preventability criteria)<sup>28</sup> and types of ADRs (Rawlins and Thompson's classification<sup>29</sup>). We did not intend to identify all of the ophthalmic ADRs, but to systematize the

most important and the most frequent ADRs according to the results of our systematic search.

#### *Risk of bias assessment*

We performed risk of bias assessment for each included study and recorded it in a standardized form created to assess ADR studies (in a previous work<sup>10</sup>) and adapted to Ophthalmology after a pilot study. We did not use scales (discouraged by the Cochrane approach<sup>20</sup>) but criteria from Cochrane, STROBE,<sup>30</sup> QUOROM<sup>31</sup> and PRISMA<sup>21</sup> adapted to the particular scope of ophthalmic ADR evaluation, which included: complete description of study design, description of study type (case report, case series, prospective observational study, trial,...), adequate diagnostic criteria for ophthalmic ADR, complete ophthalmologic evaluation at presentation, quantified visual acuity at presentation and follow-up, results of complementary testing described at presentation and follow-up, definition of ADR presented, rationale for study size, causality assessment of ADR, preventability assessment of ADR, description of all statistical methods, characterization of study participants, description of methods to prevent bias (information bias, selection bias and other bias) and presentation of complete summary measures. The two reviewers independently assessed study quality and risk of bias; disagreements were solved by consensus.

Studies were divided in low risk of bias (5 or less parameters with medium, unclear or high risk of bias), medium risk (6 to 9) and high risk (10 or more parameters evaluated as medium, unclear or high risk of bias).

## RESULTS

### *Literature search*

Pubmed search yielded 124 results; SCOPUS yielded 72 results; Google Scholar 60; ISI Web of Knowledge yielded 154; others yielded 152. From these 562 studies (corresponding to 300 distinct studies), 163 were selected to obtain full text and then 32 studies were included<sup>9,17,32–61</sup> (Fig. 1): 1 systematic review of ADRs to a specific drug, 11 narrative reviews, 1 trial, 1 prospective study, 6 case–control or cohort or cross-sectional studies, 6 spontaneous reports and 6 case reports or case series. Kappa agreement for study inclusion was 0.80 during the first phase and 0.82 during the full text review (good agreement).

### *Characteristics of included studies*

Table 1 summarizes the characteristics of included studies. We identified several types of studies of ocular

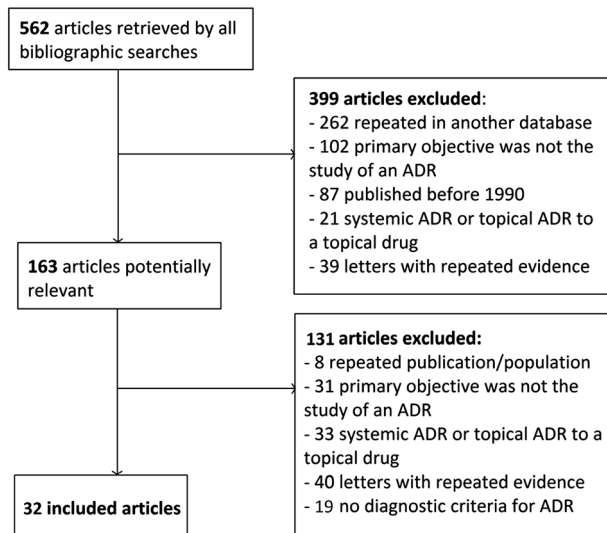


Figure 1. Flowchart of search strategy

ADRs, most of them narrative reviews without systematic criteria nor bibliographic search.

### Ophthalmic ADRs

Many different ophthalmic ADRs exist to many systemic drugs. In Table 2, we represent a summary of the main ophthalmic ADRs found in this systematic review, according to each specific drug, dose, risk factors and tried to characterize the ophthalmic ADR (if reported) and to evaluate the level of evidence of each of the studies reporting each ADR (according to the Oxford Levels of Evidence<sup>62</sup>). Keratitis, retinopathy, glaucoma, dry eye and blurred vision were the most frequent ADRs identified.

We identified many ophthalmic ADRs to drugs that have original studies but are currently lacking a systematic review (therefore representing an opportunity for further studies, as described in the Discussion Section, below). Many studies were found but only one systematic review (of ophthalmic ADRs to sildenafil<sup>56</sup>) and few narrative reviews with systematic search were performed. Therefore, examples of drugs that cause ophthalmic ADRs that would benefit from a recent and specific systematic review are: tamoxifen, amiodarone, antidepressants, phenothiazines, hydroxychloroquine, oral contraceptives, etc.

### Risk of bias assessment

In Fig. 2, we present the summary of our quality evaluation of included studies, according to each parameter assessed - risk of bias graph. Few studies had low risk of bias. Only one study performed rationale for

study size. Most studies (25) performed a complete initial evaluation by an ophthalmologist, but only 11 performed a follow-up of at least 1 month. Only 13 studies performed causality assessment for ADR and only 7 applied or presented WHO's definition of an ADR. Risk of bias summary, which contains detailed risk of bias assessment for each included study, is available if requested to contact author.

## DISCUSSION

### What this study adds

There is an increasing number of studies of ophthalmic ADRs. In spite of the common belief that ADRs in Ophthalmology are rare, some ADRs might be extremely frequent (such as *cornea verticillata* caused by amiodarone<sup>8</sup>), but require specific ophthalmological examination for its detection. Every ocular structure might be affected by an ADR. There is a need for performing specific systematic reviews of ophthalmic ADRs, because the majority of included studies were narrative non-systematic reviews, most of which without the strict application of WHO's definition of ADR nor causality assessment of ADRs.

Several drugs that may provoke different ophthalmic ADRs were identified, namely amiodarone, sildenafil, psychotropic drugs, alpha-blockers, corticosteroids and topiramate. Although *cornea verticillata* is found very frequently in patients medicated with amiodarone (authors report a rate of 100%<sup>46</sup>), this finding rarely reduces visual function; on the other hand, amiodarone may provoke a rare optic neuropathy that may provoke marked visual loss.<sup>18</sup> Sildenafil and tadalafil have been recently studied, but while some authors report no difference between ERG patterns of placebo versus these drugs,<sup>53</sup> others found several ADRs associated with sildenafil,<sup>58</sup> namely: ischemic optic neuropathy, central retinal vein occlusion, cilio-retinal artery occlusion, acute angle closure glaucoma and optic atrophy.

**Strengths** of our systematic review lie in the comprehensive search performed, the general increase in systematization and characterization of ophthalmic ADRs, the summary of existing evidence according to WHO's causality criteria for ADR and WHO's definition of ADR and finally the identification of specific ophthalmic ADRs that could benefit from future specific systematic reviews with possible meta-analysis.

**Limitations** of our systematic review include not only heterogeneity found in different types of ADRs but also the extreme variability in the methodologies of studies of ophthalmic ADRs (from isolated case reports to retrospective series of spontaneous reports,



Table 1. Included studies in this systematic review. \*Ophthalmic ADRs will be described with further detail in Table 2

| Year, author                      | Study type                              | Drug studied           | Ophthalmic ADR(s) reported*  | Summary of study   |
|-----------------------------------|---|------------------------|--|--|
| 1986 Davidson <sup>32</sup>       | Narrative review                        | Several                | Many ocular ADRs caused by: corticosteroids, chloroquine, amiodarone, phenothiazines, tamoxifen...   | Narrative review without definition of ADR nor causality assessment  |
| 1989 Curran <sup>33</sup>         | Case series                             | Doxorubicin            | Iritis, conjunctivitis, periorbital edema, keratitis, optic neuropathy   | Case series of 4 cases of ocular ADRs to doxorubicin   |
| 1991 Hobley <sup>34</sup>         | Case report                             | Digoxin                | Scintillating visual field loss (central scotoma) +dischromatopsia   | Case report: visual field defect due to digoxin (therapeutic level)  |
| 1992 Malek <sup>35</sup>          | Narrative review                        | Oral contraceptives    | • Retinal hemorrhage or emboli, macular or papillary edema, optic neuropathy   | Narrative review of ocular ADRs by oral contraceptives.  |
| 1993 Goldman <sup>36</sup>        | Narrative review                        | Anticonvulsivants      | • <b>Carbamazepine:</b> diplopia, paresis of extraocular muscles, nystagmus, visual allucinations<br>• <b>Phenytoin:</b> mistagmus without oscillopsia, mydriasis<br>• Others: paresis of extraocular muscles  | Narrative review of ocular ADRs of common anticonvulsivants  |
| 1994 Macarol <sup>37</sup>        | Spontaneous reports                     | Pamidronate            | Scleritis, conjunctivitis, anterior uveitis  | Retrospective series of spontaneous case reports   |
| 1995 Oshika <sup>38</sup>         | Narrative review                        | Neuropsychiatric drugs | • <b>Phenothiazine:</b> corneal et lens deposits<br>• <b>Thioridazine:</b> retinopathy<br>• <b>Tricyclic antidepressants:</b> glaucoma, decreased accommodation<br>• <b>Lithium:</b> papilledema, exophthalmia<br>• <b>Chlorpromazine:</b> keratopathy | A narrative review of ophthalmic ADRs of neuropsychiatric drugs  |
| 1995 Fraun-Felder <sup>9</sup>    | Letter with spontaneous reports         | Leuprolide             | Blurred vision   | A retrospective study of series of spontaneous reports of ocular ADRs of leuprolide  |
| 1995 b Fraun-Felder <sup>39</sup> | Retrospective                           | Niacin                 | Dryness, blurred vision, diplopia, cystoid maculopathy   | ADRs of patients taking niacin were compared to other dyslipidemia drugs   |
| 1997 Sweeney <sup>40</sup>        | case-control study<br>Prospective study | Risperidone            | Eye movements affected: prolonged latency after and alteration of saccadic movements   | Prospective study of patients with risperidone (4 weeks)   |
| 1999 Dullely <sup>41</sup>        | Narrative review                        | Tamoxifen              | • Retinopathy with deposits<br>• Keratopathy with deposits<br>• Colour vision defects<br>• Foveal dysfunction and ERG change<br>• Case 1: anterior uveitis<br>• Case 2: reactivation of herpetic keratitis<br>• Case 3: left keratoplasty rejection    | Narrative review about ocular ADRs of tamoxifen  |
| 1999 Solomon <sup>42</sup>        | Letter with case reports                | Influenza vaccine      | • Dry eye  | Letter with case reports not previously published  |
| 1999 Doughty <sup>43</sup>        | Narrative review                        | Migraine drugs         | Cyproheptadine, pizotyline, amitriptyline, propranolol, timolol, clonidine, flunarizine: dry eye   | A narrative review of medications of headaches and their ocular ADRs   |
| 2001 Ikaheimo <sup>44</sup>       | Observational cross-sectional study     | Flecainide             | • Corneal deposits<br>• Dry eye  | Observational study in which 38 flecainide medicated patients were examined.   |
| 2001 Fraunfelder <sup>45</sup>    | Case series of spontaneous reports      | Isotretinoin           | • Many ADRs: abnormal meibomian glands, blepharoconjunctivitis, corneal opacities, decreased vision, keratitis, ...  | Analysis of 1741 spontaneous reports with possible ocular ADRs to isotretinoin   |
| 2002 Ikaheimo <sup>46</sup>       | Observational cross-sectional study     | Amiodarone             | • Corneal deposits (in 100% of the patients)<br>• Anterior subcapsular lens deposit (22.2%)<br>• Dry eyes (9.1%)   | Observational study in which 22 patients with long-term amiodarone were studied  |
| 2003 Fraun-Felder <sup>18</sup>   | Narrative review                        | Several                | • <b>Amiodarone:</b> cornea verticillata, periorcular staining, optic neuropathy<br>• <b>Cetirizine:</b> mydriasis, oculogyric crisis...<br>• <b>Hydrochloroquine:</b> corneal deposits, epiphora, extraocular paresis, ptosis                         | A narrative review was performed of ocular ADRs, without systematic study search but with systematic WHO causality assessment whenever possible. Offers good guidelines and clinical implications for each drug. |

(Continues)

Table 1. (Continued)

| Year, author                    | Study type  | Drug studied                          | Ophthalmic ADR(s) reported*   | Summary of study   |
|---------------------------------|---|---------------------------------------|---|--|
| 2004 Fraun-Felder <sup>47</sup> | Retrospective series of reports   | Several                               | <ul style="list-style-type: none"> <li>• <b>Isotretinoin:</b> conjunctivitis, corneal deposits, acute myopia, optic neuritis</li> <li>• <b>Biphosphonates:</b> episcleritis, conjunctivitis, nerve palsy,...</li> <li>• <b>Sildenafil:</b> dischromatopsia, blurred vision</li> <li>• <b>Topiramate:</b> acute glaucoma, acute myopia, ocular pain, uveitis,...</li> <li>• <b>Biphosphonates:</b> conjunctivitis, uveitis, blurred vision, scleritis</li> <li>• <b>Cetirizine:</b> blurred vision, keratoconjunctivitis sicca, oculozytic crisis</li> <li>• <b>Isotretinoin:</b> blurred vision</li> <li>• <b>Topiramate:</b> acute glaucoma, acute myopia, periorbital edema, scleritis</li> </ul> | A large retrospective series of spontaneous reports of ocular ADRs to different systemic drugs. WHO's definition of ADR and WHO's causality assessment were performed.       |
| 2006 Fraun-Felder <sup>48</sup> | Letter with retrospective reports of spontaneous reports of ocular ADRs | Cyclooxygenase-2 Inhibitors           | Blurry vision and conjunctivitis were the most reported ADRs  | Letter with large series of spontaneous reports (1006) of ocular ADRs to cyclooxygenase-2 Inhibitors (238 reports of blurry vision and 71 of conjunctivitis from celecoxib). |
| 2007 Santaella <sup>49</sup>    | Narrative review  | Several                               | Several drugs were assessed, such as: pamidronate, alendronate, risedronate, topiramate   | Narrative review of several retrospective case series and reports of ocular ADRs to specific systemic drugs.   |
| 2007 Sowka <sup>50</sup>        | Case report   | Sildenafil                            | Optic atrophy after the use of sildenafil in a 68-year old man.   | Case report with a follow-up of 4 months. No causality assessment of ADR nor WHO's definition of ADR was used.   |
| 2008 Mandal <sup>51</sup>       | Two case reports  | Topiramate, >6 months, 100–150 mg/day | Defects in visual field (case 1-quadrantic defects, case 2-arcuate defects)   | Two case reports of visual field alterations induced by topiramate. (Naranjo's CA was performed).  |
| 2009 Bell <sup>52</sup>         | Retrospective study   | Tamsulosin                            | Intra-operative floppy iris (IFIS) and related surgical outcomes  | Retrospective cohort study of 96 128 patients: tamsulosin was associated with IFIS and intraoperative complications  |
| 2009 Corde <sup>53</sup>        | Trial   | Sildenafil and tadalafil              | Electroretinography (ERG) responses were the same for placebo, sildenafil and tadalafil.  | Subjects were randomized to use of a placebo (n = 82), tadalafil (n = 85) or sildenafil (n = 77) daily for 6 months.   |
| 2009 El-Domyati <sup>54</sup>   | Case report   | Sildenafil                            | A 48-year-old nonsmoker patient suffered from nonarteritic ischemic optic neuropathy. "Several weeks later", the visual acuity gradually improved   | Case report. Causality assessment of WHO was not performed. Follow-up of "several weeks later", not specified.   |
| 2010 Richa <sup>55</sup>        | Narrative review  | Psychotropics                         | <ul style="list-style-type: none"> <li>• Phenothiazines, lithium: keratoconjunctivitis</li> <li>• Chlorpromazine: periorcular pigmentation</li> <li>• Tricyclic antidepressants, topiramate: uveitis</li> <li>• TCAs, typical antipsychotics, selective serotonin reuptake inhibitors: mydriasis</li> </ul>   | A narrative review was performed with several psychotropic drugs   |
| 2010 Al-Hussaini <sup>56</sup>  | Comprehensive narrative review  | Alpha-blockers                        | Intra-operative Floppy Iris Syndrome (IFIS). "There is no evidence to support alpha-blocker discontinuation prior to surgery."  | Review about IFIS and drugs.   |
| 2011 Lebreton <sup>57</sup>     | Narrative review with systematic search                                 | Corticosteroids                       | <ul style="list-style-type: none"> <li>• Ocular hypertension</li> <li>• Cataract (posterior subcapsular)</li> <li>• Central Serous Chorioretinopathy</li> <li>• Ptosis</li> <li>• Exophthalmia</li> </ul>   | A narrative review was performed of ophthalmic ADRs of corticosteroids   |
| 2011 Azzouni <sup>58</sup>      | Systematic review   | Sildenafil                            |   | Systematic review of ocular ADRs by sildenafil. WHO's causality assessment was performed and of  |

National Registry of Drug-Induced Ocular Side Effects.

Authors searched acute angle-closure glaucoma, and investigated whether they had an exposure to antidepressants previously, using administrative databases.

Retrospective case series of 10 patients with ocular ADRs. Definition of ADR was not used.

Retrospective study with medical databases to identify ADRs in patients using isotretinoin.

Anterior and posterior nonarteritic ischemic optic neuropathy, central retinal vein occlusion, cilio-retinal artery occlusion, acute angle closure glaucoma and optic atrophy after sildenafil use.

Acute angle-closure glaucoma (AACG) (odds ratio for any antidepressant exposure in the period immediately preceding AACG was 1.62, 95% confidence interval of 1.16–2.26).

Multiple epithelial defects, corneal melting, ectropion and corneal perforation (requiring a penetrating keratoplasty).

An association was found between isotretinoin and conjunctivitis, hordeolum, chalazion, blepharitis, eye pain, and dry eye.

Case-crossover study

Case series

Retrospective study of outcomes

Antidepressants

Inhibitor of epidermal growth factor receptor (EGFR)

Isotretinoin

2012 Seitz<sup>59</sup>2012 Saint-Jean<sup>60</sup>2012 Neudorfer<sup>61</sup>

Table 2. Summary of ophthalmic adverse drug reactions

| Therapeutic group    | Drug(s) responsible(s)      | Description of ocular ADR   | Classification of ADR  | Reporting studies  |
|----------------------|-----------------------------|---|--|--|
| Acne treating agents | Isotretinoin                | - Patient (P), ocular segment/complaints (O)<br>- Complementary examination (C)<br>- Reversibility of ADR (R), follow-up time (F)<br><i>Certain ADRs: pseudotumour cerebri, meibomian gland alterations, blepharconjunctivitis, keratitis, myopia, corneal opacities, ocular discomfort, dry eye, photophobia, decreased vision and teratogenic ocular abnormalities.</i> (Many other ADRs were reported).<br>A recent study <sup>61</sup> identified a hazard ratio of 1.70 ( $p < 0.05$ ) for ocular ADRs after isotretinoin. | - Rawlin's type A/B<br>- Severity assessment (SA); causality assessment (CA)   | - Study's level of evidence (Oxford classification <sup>62</sup> )<br>Narrative review <sup>18</sup> and case series <sup>45</sup> (level 4) |
| Anti-allergic        | Anti-histamines: cetirizine | <b>Pupillary changes, anisocoria, decreased accommodation and blurred vision. Dry eye</b><br><b>Oculogyric crisis</b> <sup>18</sup> : "eyes and lids are tonically elevated and the neck is hyperextended, usually without visual complaints". It is a <i>certain ADR</i> . <sup>18</sup>   | - Type A and B<br>- With CA (WHO's)<br>- Type B: all except oculogyric crisis (A).<br>- WHO's causality assessment (CA) was performed. <sup>18</sup> | Retrospective study using medical databases <sup>61</sup> (level 2c)<br>Narrative reviews <sup>18,47</sup> (level 4)                         |
| Anti-arrhythmics     | Flecainide                  | <b>Corneal deposits: 14.5%</b><br><b>Dry eye: 10.5%</b>   | - Type A<br>- No CA nor SA   | - Cross-sectional study <sup>44</sup><br>- Level 2c  |

(Continues)

Table 2. (Continued)

| Therapeutic group                  | Drug(s) responsible(s)                      | Description of ocular ADR  | Classification of ADR  | Reporting studies  |
|------------------------------------|---|--|--|--|
|                                    |   | <ul style="list-style-type: none"> <li>- Patient (P), ocular segment/complaints (O)</li> <li>- Complementary examination (C)</li> <li>- Reversibility of ADR (R), follow-up time (F)</li> </ul>  | <ul style="list-style-type: none"> <li>- Rawlin's type A/B</li> <li>- Severity assessment (SA); causality assessment (CA)</li> </ul>                         | <ul style="list-style-type: none"> <li>- Study's level of evidence (Oxford classification)<sup>62</sup></li> </ul>   |
|                                    | Amiodarone                                  | <ul style="list-style-type: none"> <li>- 13 to 132 months of follow-up</li> <li><b>Corneal deposits:</b> 100% of the patients<sup>32,46</sup></li> <li>Anterior subcapsular <b>lens deposits</b><sup>46</sup>: 22%</li> <li><b>Dry eye</b><sup>46</sup>: 9%</li> <li><b>Amiodarone-optic neuropathy</b><sup>18</sup>: more insidious in onset and resolution, more bilateral, less involvement in visual acuity compared to non-arteritic ischaemic neuropathy.</li> <li><b>Other</b><sup>47</sup>: Photosensitivity, periorcular skin pigmentation, blepharoconjunctivitis, thyroid eye disease, loss of eyelashes, pseudotumor cerebri.</li> </ul> | <ul style="list-style-type: none"> <li>- Type A: dry eye, corneal and lens deposits. Rest: type B.</li> <li>- WHO causality<sup>18</sup></li> </ul>          | <ul style="list-style-type: none"> <li>- Cross-sectional study<sup>46</sup> (level 2c) and narrative reviews<sup>18,32,46</sup> (level 4)</li> </ul>                                       |
| Anticonvulsivants                  | - Carbamazepine (CB)                        | <ul style="list-style-type: none"> <li>- 3 to 131 months of follow-up in a prospective study<sup>46</sup></li> <li><b>Certain ADRs</b><sup>18</sup>: photosensitivity, corneal deposits, visual changes, skin pigmentation, blepharoconjunctivitis, thyroid eye disease.</li> <li><b>Diplopia:</b> caused by CB in 0.2–4% of patients<sup>36</sup> (if CB + other anticonvulsivants, frequency can rise to 88%). Diplopia can be reversible with dose reduction.<sup>36</sup></li> </ul>   | <ul style="list-style-type: none"> <li>- All Rawlin's type B (although diplopia may resolve with dose reduction<sup>38</sup>), except:</li> </ul>            | <ul style="list-style-type: none"> <li>- Narrative review based on case reports<sup>36</sup></li> </ul>  |
|                                    | - Phenytoin (PH)                            | <ul style="list-style-type: none"> <li><b>Nystagmus:</b> in 75% of patients with CB + PH.<sup>36</sup></li> </ul>  | <ul style="list-style-type: none"> <li>- Type A: decreased ocular movements, mydriasis, changes in convergence</li> <li>- No study with SA nor CA</li> </ul> | <ul style="list-style-type: none"> <li>- All studies Level 4</li> </ul>  |
|                                    | - Phenobarbital (PB) and other barbiturates | <ul style="list-style-type: none"> <li>Also reported after primidone and PH.</li> <li><b>Decreased ocular movements:</b> by CB and PB<sup>36</sup></li> <li><b>Ophthalmoplegia:</b> by PB and PH</li> <li><b>Oculogyric crisis:</b> by CB (in an 8-y., reversible<sup>36</sup>)</li> <li><b>Blurred vision:</b> CB<sup>36</sup>; Mydriasis: PH<sup>36</sup></li> <li><b>Disorders of convergence, miosis:</b> barbiturates<sup>36</sup></li> <li><b>Papilledema:</b> CB<sup>36</sup> (C, F: not specified in any study)</li> </ul>   | <ul style="list-style-type: none"> <li>- Usually type B (decreased accommodation is type A)</li> <li>- Na CA nor SA was performed</li> </ul>                 | <ul style="list-style-type: none"> <li>- Narrative reviews of case series of several psychiatric drugs<sup>38,55</sup></li> <li>- Prospective study of risperidone<sup>40</sup></li> </ul> |
| Antidepressants and antipsychotics | - Phenothiazine (PT)                        | <ul style="list-style-type: none"> <li><b>Corneal and lens deposits:</b> by PT, CP,<sup>38</sup> levopromazine; these deposits usually do not interfere with visual acuity</li> </ul>  |  |  |
|                                    | - Thioridazine                              | <ul style="list-style-type: none"> <li><b>Keratopathy:</b> Corneal edema by PT (reversible if stopped), epithelial keratopathy by CP<sup>38</sup> (visual acuity remains good, may be reversible if CP is stopped)</li> </ul>  |  |  |
|                                    | - Tricyclic antidepressants (TA)            | <ul style="list-style-type: none"> <li><b>Pigmentary retinopathy</b><sup>55</sup>: by thioridazine (more frequent in high dose, may be irreversible); rarely also by CP and trifluoperazine<sup>38</sup></li> </ul>  |  |  |
|                                    | - Lithium                                   | <ul style="list-style-type: none"> <li><b>Papilledema, exophthalmia:</b> lithium<sup>38</sup></li> </ul>   |  |  |
|                                    | - Chlorpromazine (CP)                       |  |  | <ul style="list-style-type: none"> <li>- Case crossover study<sup>59</sup></li> </ul>  |



|  |  |
|--|--|
| <p>Alteration of saccadic eye movements: risperidone<sup>38,40</sup></p> <p><b>Angle-closure glaucoma:</b> by TA, in susceptible patients with shallow anterior chamber<sup>59,63</sup></p> <p><b>Decreased accommodation:</b> TA, MAOIs (C, F, frequency: not specified)</p> <p><i>Certain ADRs</i><sup>18,47</sup>: <b>dyschromatopsia</b> (objects appear more blue/green), <b>blurred vision, changes in light perception, electroretinogram changes, conjunctival hyperemia and photophobia.</b></p> <p>Case report<sup>50</sup>: optic atrophy (without CA). Trial<sup>53</sup>: no changes in electroretinography responses for placebo, sildenafil and tadalafil (no ADR).</p> <p>Others<sup>58</sup>: Anterior and posterior nonarteritic ischemic optic neuropathy, central retinal vein occlusion, cilio-retinal artery occlusion, acute angle closure glaucoma.</p> <p><b>Blurry vision and conjunctivitis</b> by rofecoxib, celecoxib and valdecoxib (positive dechallenge and rechallenge tests)</p> <p><b>Ocular hypertension:</b> Odds ratio 1.41 (CI95% 1.2–1.6)<sup>64</sup> Glaucoma reportedly in up to 30% of patients<sup>32</sup></p> <p><b>Cataract</b> (posterior subcapsular): 4.7%–15.3%<sup>65,32</sup></p> <p><b>Central serous chorioretinopathy:</b> OR 37 (CI95% 6–222)<sup>57</sup></p> <p>Others: <b>ptosis, exophthalmia</b> (6–8%<sup>57</sup>), <b>viral retinitis, delay in corneal cicatrization</b></p> <p>More post-operative complications (in 14 days) in patients with tamsulosine<sup>32</sup>: intra-operative floppy iris</p> <p>Intra-operative Floppy Iris Syndrome (<b>IFIS</b>). IFIS severity is related with number of the following criteria:</p> <ul style="list-style-type: none"> <li>• iris billows with intraocular irrigation currents</li> <li>• iris prolapse tendency</li> <li>• intraoperative pupillary constriction</li> </ul> <p><b>Anterior uveitis:</b> uni or bilateral, 24 h to 17 days after medication,<sup>37</sup> mild to severe (2 hospitalizations)</p> <p><b>Scleritis, episcleritis:</b> unilateral, in 1–6 days.</p> <p><b>Conjunctivitis:</b> mild, in 1–48 h.</p> | <p>- Level 4 (low evidence) for the narrative reviews,<sup>38,55</sup> level 2c for case crossover<sup>59</sup> and 2b for the prospective study<sup>40</sup></p> <p>Narrative reviews,<sup>18,47</sup> systematic review of case reports<sup>58</sup> and case report<sup>50</sup> (level 4)</p> <p>Trial<sup>53</sup> (level 1b)</p>   |
| <p>- Monoamine oxidase inhibitors (MAOIs)</p> <p>- Risperidone</p> <p>Sildenafil</p> <p>Anti-erectile dysfunction agents</p>   | <p>- Type A and B</p> <p>- With CA: WHO's<sup>18,47</sup> and Naranjo's<sup>58</sup></p> <p>- Without CA nor SA<sup>50</sup></p>   |
| <p>Cyclooxygenase-2 Inhibitors</p> <p>Corticosteroids</p>  | <p>- Type B</p> <p>- With CA</p> <p>- Type A: cataract</p> <p>- Type B: other ADRs</p> <p>- Without CA nor SA</p>  |
| <p>Benign prostatic hyperplasia drugs</p> <p>Alpha-blockers (e.g. tamsulosin)</p>  | <p>Retrospective series of spontaneous reports<sup>48</sup> (level 4)</p> <p>Narrative reviews<sup>32,57</sup> (level 4)</p> <p>Case-control studies<sup>64,65</sup> (level 3b)</p>  |
| <p>Biphosphonates</p> <p>Pamidronate</p> <p>Risedronate</p> <p>Alendronic acid</p> <p>Zoledronic acid</p> <p>Risedronate sodium</p> <p>Etidronate disodium</p>   | <p>Retrospective study<sup>52</sup> of 96 128 patients (level 2b)</p> <p>Narrative review with systematic search<sup>56</sup></p> <p>- Retrospective series of spontaneous case reports<sup>37</sup> and narrative reviews<sup>18,47</sup></p> <p>- No CA,<sup>37</sup> but rechallenge was performed in 5 patients with uveitis (4 positive rechallenge tests)</p> <p>- With CA<sup>18</sup> performed in a narrative review</p> <p>- Level 4</p> |

(Continues)

Table 2. (Continued)

| Therapeutic group                  | Drug(s) responsible(s)                               | Description of ocular ADR  | Classification of ADR  | Reporting studies   |
|------------------------------------|--|--|--|---|
|                                    |  | <ul style="list-style-type: none"> <li>- Patient (P), ocular segment/complaints (O)</li> <li>- Complementary examination (C)</li> <li>- Reversibility of ADR (R), follow-up time (F)</li> </ul>  | <ul style="list-style-type: none"> <li>- Rawlin's type A/B</li> <li>- Severity assessment (SA); causality assessment (CA)</li> </ul>   | <ul style="list-style-type: none"> <li>- Study's level of evidence (Oxford classification)<sup>62</sup></li> </ul>  |
|                                    |  | <p><b>Nerve palsy, retrobulbar neuritis, yellow vision, blurred vision</b><br/>C, F, frequency: not specified. Causality assessment<sup>18,47</sup>:</p> <p><i>Certain ADR</i>: blurred vision, ocular irritation, conjunctivitis, pain, epiphora, photophobia, anterior uveitis, anterior scleritis, episcleritis, orbital edema.</p> <p><i>Possible</i>: retrobulbar neuritis, yellow vision, diplopia, cranial nerve palsy, ptosis, visual hallucinations.</p> <p>- 36-year-old female</p> <p><b>Dischromatopsia + scintillating visual field</b><br/>(VF) alterations; 3 months after administration of digoxin</p> <p>Colour test FM-100: defect on blue colour.</p> <p>- Reversibility, follow-up: not specified</p> <p><b>Periorbital edema</b> (after CA, <i>certain ADR</i>).</p> <p><b>Epiphora</b> (<i>probable ADR</i>)<br/>Other possible ADRs: <b>extraocular muscle paresis, ptosis and blepharconjunctivitis. Multiple epithelial defects</b> (in 10 eyes of all cases), <b>corneal melting</b> (in 3 eyes of 2 patients), lower lid <b>ectropion</b> (2 eyes of 1 patient) and <b>corneal perforation</b> requiring a penetrating keratoplasty (in 2 eyes of 2 patients). Variable follow-ups (all &gt; 1 month).</p> <p><b>Corneal deposits, epiphora, ophthalmoplegia, ptosis</b></p> <p><b>Maculopathy</b>: dramatic retinopathy with macular atrophy in a bull's-eye pattern. No frequency is reported but: "approximately one million people have used hydroxychloroquine, with only 20 cases of retinal toxicity in the low dose range (&lt; 6.5 mg/kg/day)"<sup>18</sup></p> <p>Baseline and annual ophthalmic examinations are recommended with: visual acuity, amsler's grid, colour test, and ideally fundus photograph and visual field.</p> <p><b>Retinal hemorrhage or emboli, Macular edema, Papillary edema, Retrobulbar optic neuropathy</b></p> <ul style="list-style-type: none"> <li>- Patient: not specified</li> <li>- Ocular segment: posterior (retinal alterations and papillary edema, vascular changes)</li> <li>- Complementary examination: angiography, CT scan</li> </ul> | <ul style="list-style-type: none"> <li>- Rawlin's: B/diosyncratic ADR</li> <li>- No SA</li> <li>- No CA</li> <li>- Type A: periorbital edema. Rest: type B.</li> <li>- With CA (WHO's)</li> <li>- Type B</li> <li>- No CA nor SA</li> <li>- Type A: maculopathy (related to cumulative dose), corneal deposits</li> <li>- Type B: ophthalmoplegia, ptosis</li> <li>- With CA (WHO)<sup>18</sup> and without<sup>32</sup></li> <li>- Rawlin's type B</li> <li>- No SA</li> <li>- No CA</li> </ul> | <ul style="list-style-type: none"> <li>- Case report<sup>34</sup></li> <li>- Level 4 (low evidence). Many other studies not included because toxic digoxin levels</li> <li>Narrative review<sup>18</sup> (level 4)</li> <li>Retrospective series of spontaneous reports<sup>60</sup> (level 4)</li> <li>Narrative reviews<sup>18,32</sup> (level 4)</li> <li>Narrative review<sup>35</sup> based on few case reports (low evidence)</li> <li>- Level 4</li> </ul> |
| Drugs used in heart failure        | Digoxin  |  |  |   |
| Drugs used in neoplastic disorders | Imatinib   |  |  |   |
|                                    | Inhibitor of epidermal growth factor receptor (EGFR) |  |  |   |
| Drugs used in Rheumatology         | Chloroquine  |  |  |   |
|                                    | Hydroxychloroquine                                   |  |  |   |
| Hormone-related therapy            | Oral contraceptives                                  |  |  |   |

|                       |   |   |
|-----------------------|---|---|
|                       | <p>- Follow-up: variable (case reports)</p> <p><b>Blurred vision:</b> duration between 1 h and 15 days, may be associated with headaches or dizziness.</p> <p><b>Other:</b> papilledema, ocular pain, "ocular vascular accidents"</p> <p><b>Crystallin retinopathy:</b> in the macula, may be associated with macular edema</p> <p><b>Keratopathy</b> with whorl-like opacities</p> <p><b>Colour vision</b> defects</p> <p><b>Foveal dysfunction</b> with ERG changes</p> <p>Case 1: <b>iritis, conjunctivitis</b></p> <p>Case 2: <b>periorbital edema</b></p> <p>Case 3: <b>keratitis</b></p> <p>Case 4: <b>optic neuropathy</b> (F, C, follow-up: not reported)</p> <p><b>Dry eye</b> (Fisher exact test <math>p=0.011</math>),</p> <p><b>Blurred vision</b> (<math>p=0.0011</math>)</p> <p><b>Diplopia</b> (<math>p=0.5</math>, non statistically significant)</p> <p><b>Cystoid maculopathy</b> (2 cases)</p> <p><b>Dry eye:</b> all</p> <p><b>Diplopia:</b> cyproheptadine, pizotyline, amitriptiline</p> <p><b>Mydriasis:</b> cyproheptadine, pizotyline, amitriptiline</p> <p><b>Decrease in accommodation:</b> propranolol, timolol</p> <p><b>Changes in intraocular pressure:</b> all</p> <p><i>Certain ADRs by topiramate: acute angle closure glaucoma</i> (usually bilateral, in 1–14 days, suprachoroidal effusion), <b>decreased vision, headaches, hyperemia, mydriasis, uveitis, visual field defects, myopia.</b></p> <p><i>Probable ADRs by topiramate: blepharospasm and oculogyric crisis.</i></p> <p>Case reports of others ADRs, as visual field defects<sup>51</sup></p> <p>Case 1: 41 y, man, reversible <b>anterior uveitis</b></p> <p>Case 2: 72 y, woman, reactivation of <b>herpetic keratitis</b></p> <p>Case 3: 74 y, man, <b>left keratoplasty rejection</b></p> | <p>- Series of spontaneous case reports<sup>9</sup></p> <p>- Level 4</p> <p>- Narrative review<sup>41,47</sup></p> <p>- Level 4</p> <p>- Case series of 4 cases<sup>33</sup> (level 4)</p> <p>- Case-control study<sup>39</sup></p> <p>- Level 3b</p> <p>- Narrative reviews<sup>43,18</sup></p> <p>- Level 4</p> <p>- Narrative reviews<sup>18,51</sup></p> <p>- Level 4</p> <p>- Letter with case reports<sup>42</sup></p> <p>- Level 4</p> |
| Leuprolide            | - Type B  |   |
| Tamoxifen             | - No CA nor SA  |   |
|                       | - Usually type B  |   |
|                       | - No CA nor SA <sup>41</sup>  |   |
|                       | - CA (WHO causality) <sup>47</sup>  |   |
| Doxorrubicin          | - Type B  |   |
|                       | - No CA nor SA  |   |
| Lipid lowering agents | - Type B  |   |
|                       | - No CA nor SA  |   |
| Migraine drugs        | - Type A  |   |
|                       | - No SA nor CA  |   |
|                       | - CA performed by Fraunfelder <sup>18</sup>   |   |
| Topiramate            |   |   |
| Vaccines              | - Type B  |   |
|                       | - No CA nor SA were performed   |   |

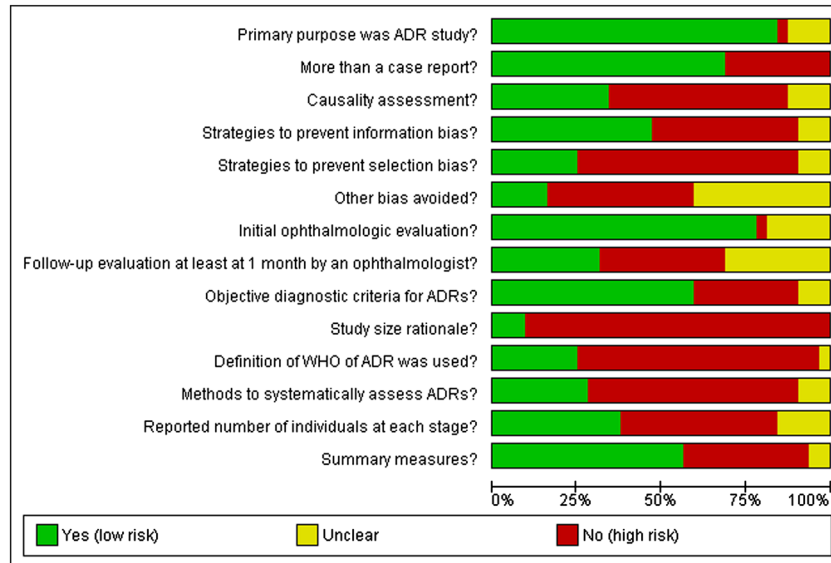


Figure 2. Risk of bias graph

prospective observational studies and trials). These limitations were expected, because this was a systematic review with a very general scope and because the detection of ophthalmic ADRs depends on the degree of suspicion and an adequately performed ophthalmologic examination. Many ophthalmic ADRs are only detected by case reports or spontaneous reports, representing a limitation but simultaneously an opportunity to improve. Consequently, there are many ophthalmic ADRs that are based on a low level of evidence. We believe this is an additional reason for applying systematically the WHO definition for ADR and a causality assessment (whether WHO's or Naranjo's), in order to decrease doubts. High-risk drugs such as the ones identified in Table 2 should be associated with protocols of evaluation (especially in susceptible individuals or in high doses) by an ophthalmologist, in order to detect sooner and with higher sensitivity and specificity the respective ophthalmic ADRs.

## CONCLUSION

Ophthalmologists' education (to increase recognition of ophthalmic ADRs) and the dissemination of protocols of collaboration between Ophthalmology and other Medicine specialties whenever they prescribe high-risk drugs (such as sildenafil, biphosphonates, psychiatric medication, tamoxifen, hydroxichloroquine) are strong suggestions for the future.

## CONFLICT OF INTEREST

The authors declare no conflict of interest.

## KEY POINTS

- Ophthalmology is perhaps one of the medical specialties in which there are the few assessed ADRs, but the eye is a complex organ in which minimal impairment can produce a substantial functional effect.
- We performed a systematic review regarding ophthalmic ADRs to systemic drugs, to systematically summarize evidence and to identify specific areas that lacked systematization or assessment.
- From 562 studies initially found, only 32 were included, and few studies had low risk of bias. Drugs frequently involved included amiodarone, sildenafil, hydroxychloroquine and biphosphonates.
- Many ophthalmic ADRs are frequent but remain unnoticed; therefore, the systematization of specific ophthalmic ADRs, the increase of knowledge and the dissemination of protocols of collaboration are suggested.

## ETHICS STATEMENT

Authors confirm to have adhered to Ethics principles and Helsinki Declaration during all phases of this study.

## ACKNOWLEDGEMENTS

The authors would like to thank MSD for obtaining the full text of 8 articles and Théa for obtaining the full text of 7 articles.

## REFERENCES

- Fraunfelder FW, Fraunfelder FT. Scientific challenges in postmarketing surveillance of ocular adverse drug reactions. *Am J Ophthalmol* 2007; **143**(1): 145–149. Epub 2006 Nov 13.
- American Academy of Ophthalmology. Fundamentals and principles in basic Ophthalmology. Section 2 in AAO's Basic and Clinical Science Course, Vol. 2, 2012; 249–265.
- Luykx J, Mason M, Ferrari MD, et al. Are migraineurs at increased risk of adverse drug responses? A meta-analytic comparison of topiramate-related adverse drug reactions in epilepsy and migraine. *Clin Pharmacol Ther* 2009; **85**(3): 283–8. Epub 2008 Nov 5.
- Fel A, Aslangul E, Le Jeune C. Eye and corticosteroid's use. *Presse Med* 2012; **41**(4): 414–21.
- Abdel-Aziz S, Mamalis N. Intraoperative floppy iris syndrome. *Curr Opin Ophthalmol* 2009; **20**(1): 37–41.
- Cano Parra J, Diaz-Llopis M. Drug induced uveitis. *Arch Soc Esp Oftalmol* 2005; **80**(3): 137–49.
- Carelli V, Ross-Cisneros FN, Sadun AA. Optic nerve degeneration and mitochondrial dysfunction: genetic and acquired optic neuropathies. *Neurochem Int* 2002; **40**(6): 573–84.
- Hollander DA, Aldave AJ. Drug-induced corneal complications. *Curr Opin Ophthalmol* 2004; **15**(6): 541–8.
- Fraunfelder FT, Edwards R. Possible ocular adverse effects associated with leuprolide injections. *JAMA* 1995; **273**(10): 773–4.
- Miguel A, Azevedo LF, Araújo M, et al. Frequency of adverse drug reactions in hospitalized patients: a systematic review and meta-analysis. *Pharmacoepidemiol Drug Saf* 2012; **21**(11): 1139–54.
- Lazarou J, Pomeranz BH, Corey PN. Incidence of adverse drug reactions in hospitalized patients: a meta-analysis of prospective studies. *JAMA* 1998; **279**(15): 1200–5.
- Cuervo LG, Clarke M. Balancing benefits and harms in health care. *Br Med J* 2003; **327**(7406): 65–66.
- Loke YK, Price D, Herxheimer A. Systematic reviews of adverse effects: framework for a structured approach. *BMC Med Res Methodol* 2007; **7**: 32–39.
- Pirmohamed M, Park BK. Genetic susceptibility to adverse drug reactions. *Trends Pharmacol Sci* 2001; **22**(6): 298–305.
- Davies EC, Green CF, Mottram DR, et al. Adverse drug reactions in hospitals: a narrative review. *Curr Drug Saf* 2007; **2**: 79–87.
- Cornelius VR, Perrio MJ, Shakir SAW, et al. Systematic reviews of adverse effects of drug interventions: a survey of their conduct and reporting quality. *Pharmacoepidemiol Drug Saf* 2009; **18**: 1223–1231.
- Chou R, Fu R, Carson S, et al. Methodological shortcomings predicted lower harm estimates in one of two sets of studies of clinical interventions. *J Clin Epidemiol* 2007; **60**(1): 18–28.
- Fraunfelder FW. Ocular adverse drug reactions. *Expert Opin Drug Saf* 2003; **2**(4): 411–20.
- Wren VQ. Ocular & visual side effects of systemic drugs - clinically relevant Toxicology and patient management. *J Beh Optom* 2000; **11**(6): 149–157.
- The Cochrane Collaboration. Cochrane Handbook for systematic reviews of interventions version 5.0.0. 2008; 434–449.
- Moher D, Liberati A, Tetzlaff J, et al. Preferred Reporting Items for Systematic Reviews and Meta-Analyses: The PRISMA Statement. *PLoS Med* 2009; **6**(7): e1000097.
- World Health Organization. *International Drug Monitoring: The Role of the Hospital*. World Health Organization: Geneva, Switzerland, 1966. Technical Report Series No. 425.
- World Health Organization. WHO Draft Guidelines for Adverse Event Reporting and Learning Systems. 2005. Available at: [http://www.who.int/patientsafety/events/05/Reporting\\_Guidelines.pdf](http://www.who.int/patientsafety/events/05/Reporting_Guidelines.pdf) [September 2013].
- Ferris FL, 3rd, Kassoff A, Bresnick GH, et al. New visual acuity charts for clinical research. *Am J Ophthalmol* 1982; **94**: 91–6.
- World Health Organization. Anatomical Therapeutic Chemical (ATC) classification system. Available at: [http://www.whocc.no/atc/structure\\_and\\_principles/](http://www.whocc.no/atc/structure_and_principles/) [October 2013].
- Naranjo CA, Busto U, Sellers EM, et al. A method for estimating the probability of adverse drug reactions. *Clin Pharmacol Ther* 1981; **30**: 239–245.
- Hartwig SC, Siegel J, Schneider PJ. Preventability and severity assessment in reporting adverse drug reactions. *Am J Hosp Pharm* 1992; **49**: 2229–32.
- Schumock GT, Thornton JP. Focusing on the preventability of adverse drug reactions. *Hosp Pharm* 1992; **27**: 538.
- Rawlins MD, Thompson JW. Pathogenesis of adverse drug reactions. In *Textbook of adverse drug reactions*, Davies DM (ed.). Oxford University Press: Oxford, 1977.
- Vandenbroucke JP, von Elm E, Altman DG, et al. Strengthening the reporting of observational studies in epidemiology (STROBE): explanation and elaboration. *PLoS Med* 2007; **4**(10): e297.
- Moher D, Cook DJ, Eastwood S, et al. Improving the quality of reports of meta-analyses of randomized controlled trials: the QUOROM statement. Quality of reporting of meta-analyses. *Lancet* 1999; **354**(9193): 1896–1900.
- Davidson SI, Rennie IG. Ocular toxicity from systemic drug therapy. An overview of clinically important adverse reactions. *Med Toxicol* 1986; **1**(3): 217–24.
- Curran CF, Luce JK. Ocular adverse reactions associated with adriamycin (doxorubicin). *Am J Ophthalmol* 1989; **108**(6): 709–11.
- Hobley A, Lawrenson J. Ocular adverse effects to the therapeutic administration of digoxin. *Ophthalmic Physiol Opt* 1991; **11**(4): 391–3.
- Malek N, Lebuissou DA. Adverse ocular reactions to oral contraceptive use. *Contracept Fertil Sex* 1992; **20**(4): 441–1.
- Goldman MJ, Schultz-Ross RA. Adverse ocular effects of anticonvulsants. *Psychosomatics* 1993; **34**(2): 154–8.
- Macarol V, Fraunfelder FT. Pamidronate disodium and possible ocular adverse drug reactions. *Am J Ophthalmol* 1994; **118**(2): 220–4.
- Oshika T. Ocular adverse effects of neuropsychiatric agents. Incidence and management. *Drug Saf* 1995; **12**(4): 256–63.
- Fraunfelder FW, Fraunfelder FT, Illingworth DR. Adverse ocular effects associated with niacin therapy. *Br J Ophthalmol* 1995; **79**(1): 54–6.
- Sweeney JA. Adverse effects of risperidone on eye movement activity: A comparison of risperidone and haloperidol in antipsychotic-naïve schizophrenic. *Neuropsychopharmacology* 1997; **16**(3): 217–28.
- Dulley P. Ocular adverse reactions to tamoxifen—a review. *Ophthalmic Physiol Opt* 1999; **19**(Suppl 1): S2–9.
- Solomon A, Siganos CS, Frucht-Pery J. Adverse ocular effects following influenza vaccination. *Eye (Lond)* 1999; **13**(3a): 381–2.
- Doughty MJ, Lyle WM. Medications used to prevent migraine headaches and their potential ocular adverse effects. *Optom Vis Sci* 1995; **72**(12): 879–91.
- Ikaheimo K, Kettunen R, Mantjarvi M. Adverse ocular effects of flecainide. *Acta Ophthalmol Scand* 2001; **79**(2): 175–6.
- Fraunfelder FT, Fraunfelder FW, Edwards R. Ocular side effects possibly associated with isotretinoin usage. *Am J Ophthalmol* 2001; **132**(3): 299–305.
- Ikaheimo K, Kettunen R, Mantjarvi M. Visual functions and adverse ocular effects in patients with amiodarone medication. *Acta Ophthalmol Scand* 2002; **80**(1): 59–63.
- Fraunfelder FW, Fraunfelder FT. Adverse ocular drug reactions recently identified by the National Registry of Drug-Induced Ocular Side Effects. *Ophthalmology* 2004; **111**(6): 1248–50.
- Fraunfelder FW, Solomon J, Mehelas TJ. Ocular adverse effects associated with cyclooxygenase-2 inhibitors. *Arch Ophthalmol* 2006; **124**(2): 277–9.
- Santaella RM, Fraunfelder FW. Ocular adverse effects associated with systemic medications: Recognition and management. *Drugs* 2007; **67**(1): 75–93.
- Sowka JW, Neiberg MN, Vollmer LA. Optic atrophy after sildenafil use. *Optometry* 2007; **78**: 122–128.
- Mandal A, Chatterjee S, Bose S, et al. Ocular adverse effects of Topiramate: Two case reports. *Indian J. Pharmacol* 2008; **40**(6): 278–280.
- Bell CM, Hatch WV, Fischer HD, et al. Association between tamsulosin and serious ophthalmic adverse events in older men following cataract surgery. *JAMA* 2009; **301**(19): 1991–6.
- Cordell WH, Maturi RK, Costigan TM, et al. Retinal effects of 6 months of daily use of tadalafil or sildenafil. *Arch Ophthalmol* 2009; **127**(4): 367–73.
- El-Domyati MM, El-Fakahany HM, Morad KE. Nonarteritic ischaemic optic neuropathy (NAION) after 36 h of intake of sildenafil citrate: first Egyptian case. *Andrologia* 2009; **41**(5): 319–21.
- Richa S, Yazbek JC. Ocular Adverse Effects of Common Psychotropic Agents: A Review. *CNS Drugs* 2010; **24**(6): 501–27.
- Al-Hussaini ZK, McVary KT. Alpha-blockers and intraoperative floppy iris syndrome: ophthalmic adverse events following cataract surgery. *Curr Urol Rep* 2010; **11**(4): 242–8.
- Lebreton O, Weber M. Ophthalmologic adverse effects of systemic corticosteroids (french). *Rev Med Interne* 2011; **32**: 506–512.
- Azzouni F, Abu samra F. Are Phosphodiesterase Type 5 Inhibitors Associated with Vision-Threatening Adverse Events? A Critical Analysis and Review of the Literature. *J Sex Med* 2011; **8**(10): 2894–2903.
- Seitz DP, Campbell RJ, Bell CM, et al. Short-term exposure to antidepressant drugs and risk of acute angle-closure glaucoma among older adults. *J Clin Psychopharmacol* 2012; **32**(3): 403–7.
- Saint-Jean A, Sainz de la Maza M, Morral M, et al. Ocular adverse events of systemic inhibitors of the epidermal growth factor receptor: report of 5 cases. *Ophthalmology* 2012; **119**(9): 1798–802.
- Neudorfer M, Goldshtein I, Shamai-Lubovitz O, Chodick G, Dadon Y, Shalev V. Ocular adverse effects of systemic treatment with isotretinoin. *Arch Dermatol* 2012; **148**(7): 803–8.
- OCEBM Levels of Evidence Working Group. The Oxford Levels of Evidence 2. Oxford Centre for Evidence-Based Medicine. Available at: <http://www.cebm.net/index.aspx?o=5653> [26th August 2013].
- Rossette E, Faggioni R. Glaucoma and psychotropic drugs. *Ophthalmologica* 1969; **158**(Suppl): 462–8.
- Garbe E, LeLorier J, Boivin JF, Suissa S. Risk of ocular hypertension or open angle glaucoma in elderly patients on oral glucocorticoids. *Lancet* 1997; **350**: 979–82.
- Sundmark E. The occurrence of posterior subcapsular cataracts in patients on long-term systemic corticosteroid therapy. *Acta Ophthalmol* 1963; **41**: 516–23.