

# Necrotizing Fasciitis after Shoulder Mobilization and Intra-Articular Infiltration with Betametasone



## Fasceíte Necrosante após Mobilização e Infiltração Intrarticular do Ombro com Betametasona

Joana BENTO-RODRIGUES<sup>1</sup>, Fernando JUDAS<sup>1</sup>, Jorge PEDROSA RODRIGUES<sup>3</sup>, João OLIVEIRA<sup>1</sup>, Pedro SIMÕES<sup>1</sup>, Francisco LUCAS<sup>1,2</sup>, António PAIS LOPES<sup>1</sup>  
**Acta Med Port 2013 Jul-Aug;26(4):456-459**

### ABSTRACT

Necrotizing Fasciitis is a rapidly progressive, potentially fatal infection of superficial fasciae and subcutaneous tissue, usually resulting from an inciting trauma to the skin. Medical literature refers few cases of necrotizing fasciitis related to intra-articular infiltrations, that often lead to patients death. This report describes the clinical events on a 55 year-old diabetic patient who developed upper extremity Necrotizing Fasciitis, 18 days after shoulder mobilization and intra-articular infiltration, due to *Staphylococcus epidermidis*. An early surgical debridement was performed and antibiotherapy was established, resulting in a successful outcome, despite the functional disability. We point out, through this case, the possibility of intra-articular injections of drugs causing Necrotizing Fasciitis, especially in risk patients.

**Keywords:** Necrotizing Fasciitis; Shoulder; Injections, Intra-Articular; Shoulder Pain.

### RESUMO

A Fasceíte Necrosante é uma infeção de rápida progressão, potencialmente fatal, das fâscias superficiais e tecido celular subcutâneo, que resulta geralmente de um traumatismo da pele. Há poucos relatos na literatura médica de casos de Fasceíte Necrosante relacionados com infiltrações intrarticulares, que culminaram com frequência na morte dos doentes. Este relato descreve os eventos clínicos de um doente diabético de 55 anos que desenvolveu uma Fasceíte Necrosante por *Staphylococcus epidermidis* do membro superior, 18 dias após uma mobilização do ombro e infiltração intrarticular. O doente foi submetido a desbridamento cirúrgico e antibiooterapia precoces, que foram bem sucedidos, apesar da limitação funcional. Com este caso alertamos para a possibilidade de uma Fasceíte Necrosante, após infiltração intrarticular de fármacos, particularmente em doentes de risco.

**Palavras-chave:** Dor de Ombro; Fasceíte Necrosante; Infiltrações Intrarticulares; Ombro.

### INTRODUCTION

Necrotizing fasciitis (NF) was first described by Fournier in 1883. It is a rare infection of soft tissues, which rapidly spreads across the subcutaneous planes and progressively destroys fasciae and fat, with fulminating deterioration and high mortality if not promptly diagnosed and aggressively treated.<sup>1</sup> Usually resulting from an inciting trauma to the skin, NF can affect any region, most commonly the extremities (36% to 55%) and the trunk (18% to 64%),<sup>2</sup> the last one more frequent in children.<sup>3</sup>

NF is categorized as type I or type II. Type I tends to occur after surgical procedures in immunocompromised, diabetic or obese patients; results from a mixed aerobic and anaerobic infection of pathogens including *Staphylococcus aureus*, *Vibrio vulnificus*, *Clostridium perfringens*, *Bacteroides fragilis*, *Streptococci*, *Enterococci*, among others, with an average of five isolates. Type II typically occurs in previously healthy individuals, predominantly caused by group-A  $\beta$ -hemolytic *Streptococcus* and *Staphylococcus aureus*. Although type-I constitutes 55% to 90% of all cases, the incidence of monomicrobial infections caused by *Staphylococcus aureus* has increased in the past decade.<sup>2,4</sup>

Medical literature refers very few cases of NF related to intra-articular injections, that often lead to the patients

death.<sup>5,6</sup>

This report describes the clinical events on a diabetic patient who developed upper extremity NF, after shoulder mobilization and intra-articular infiltration.

### CASE REPORT

We present the case of a 55 year-old male, caucasian, woodcutter, with dyslipidemia and type 2 *diabetes mellitus* (DM), not controlled (H<sub>g</sub>A<sub>1c</sub> 9.1%), treated with metformin and intermediate-acting insulin.

In the outpatient orthopaedics clinic we diagnosed a right frozen shoulder. With no contraindication from the Endocrinologist, it was proposed and later performed shoulder mobilization in the operating room, under sedation and aseptic conditions. It consisted in intra-articular injection of xylocaine and physiologic saline solution (0.9%), followed by shoulder mobilization and intra-articular infiltration with betamethasone 14mg/2ml. The intervention was uneventful, and the patient was discharged the same day.

Eighteen days later he was admitted to the emergency room (ER), presenting fever (37.9°C), severe pain and warm swelling in the right shoulder and arm (Fig.1) for 24 hours. Blood tests revealed: C-reactive protein (CRP)

1. Department of Orthopaedics. Coimbra University Hospital. Coimbra. Portugal.

2. Department of Orthopaedics. Faculty of Medicine. University of Coimbra. Coimbra. Portugal.

3. Vila Nova de Poiares Primary Health Care Centre. Vila Nova de Poiares. Portugal.

Recebido: 14 de Outubro de 2012 - Aceite: 17 de Abril 2013 | Copyright © Ordem dos Médicos 2013

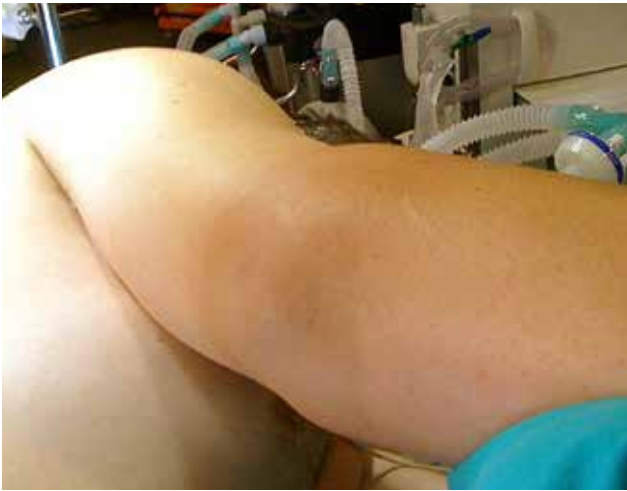

Figure 1 – Warm swelling in the right shoulder and arm.

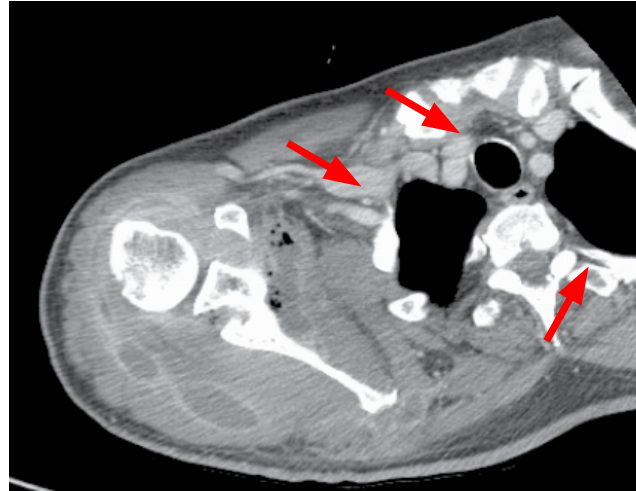


Figure 2 – CT of left shoulder with multiple images of gas density inside.

22.03; leucocytes 19800/ $\mu$ L; haemoglobin 11.2 g/dl; sodium 133 mmol/L, creatinine 0.78 mg/dl; glucose 421 mg/dl, mg/dl. Computerized tomography (CT) showed swelling of the soft tissues of shoulder girdle and arm, especially muscular structures, outlining non-liquid low-density formations with multiple gas-density images within (Fig. 2).

NF was diagnosed and the patient received supportive treatment, intravenous imipenem/cilastatin 500/500 mg (8/8 hours) and underwent surgery, 8 hours after entering the ER. During surgery, a posterior approach of scapula (with rhomboids dissection) and an extended deltopectoral approach of the shoulder were performed, resulting in drainage of extensive collections of purulent content (Fig. 3), located between girdle, shoulder and arm muscle planes and subcutaneous fat; debridement of devitalized tissues and mechanical washing with physiologic saline solution and povidone-iodine were performed (Fig. 4). Samples were taken for culture and antibiogram and *Staphylococcus epidermidis* was identified.

There were no registered complications during the post-operative period and intravenous imipenem/cilastatin was

kept till patient discharge, 23 days later. After six months, in the outpatient orthopaedics clinic scheduled appointment, surgical scars presented slightly hypertrophic (Fig. 5), he reported slight shoulder pain and mild hand paresthesia; shoulder mobility was limited (abduction of 45°, external rotation of 20°, internal rotation of 20°).

## DISCUSSION

Necrotizing fasciitis is characterized by early severe pain disproportionate to cutaneous signs, evidence of systemic inflammation, rapid progression to local necrosis, crepitus, blistering, discharge, worsening sepsis and septic shock. The lack of specific clinical features and skin changes in the initial stage of the disease easily lead to underestimation or misdiagnosis, delaying treatment and worsening prognosis.<sup>7</sup>

NF infection can derive from skin lesions, organ or musculoskeletal infections, though in up to 15% of cases there is no evidence of any source of infection.<sup>8</sup>

According to Fanfarillo et al's 2011 review, intra-articular steroid injections are very rarely reported in the literature as

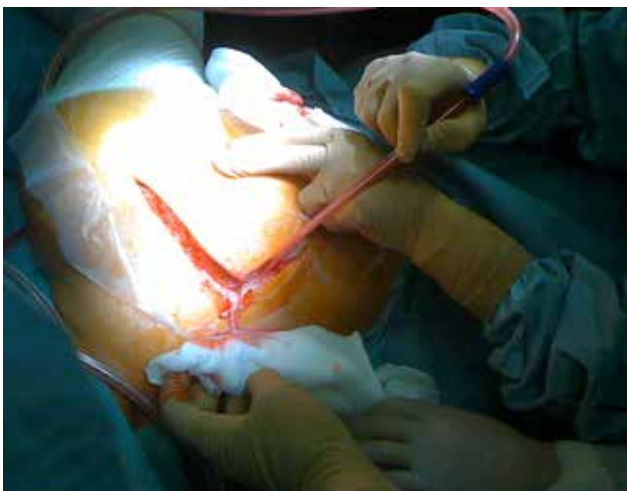

Figure 3 – Extensive collections of purulent content drained (posterior approach of scapula).

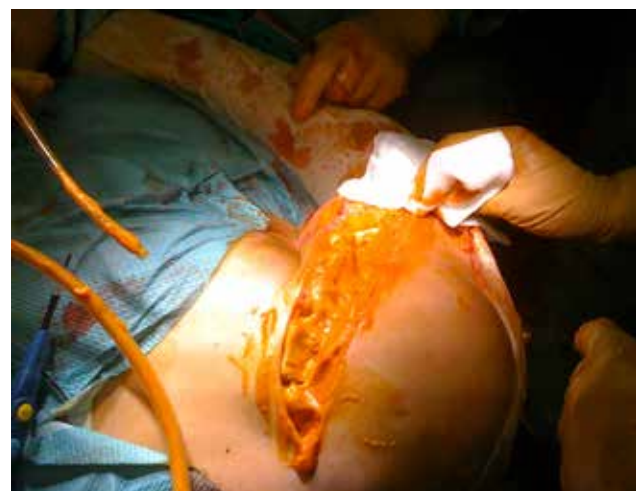

Figure 4 – Washing with physiologic saline solution and povidone-iodine.

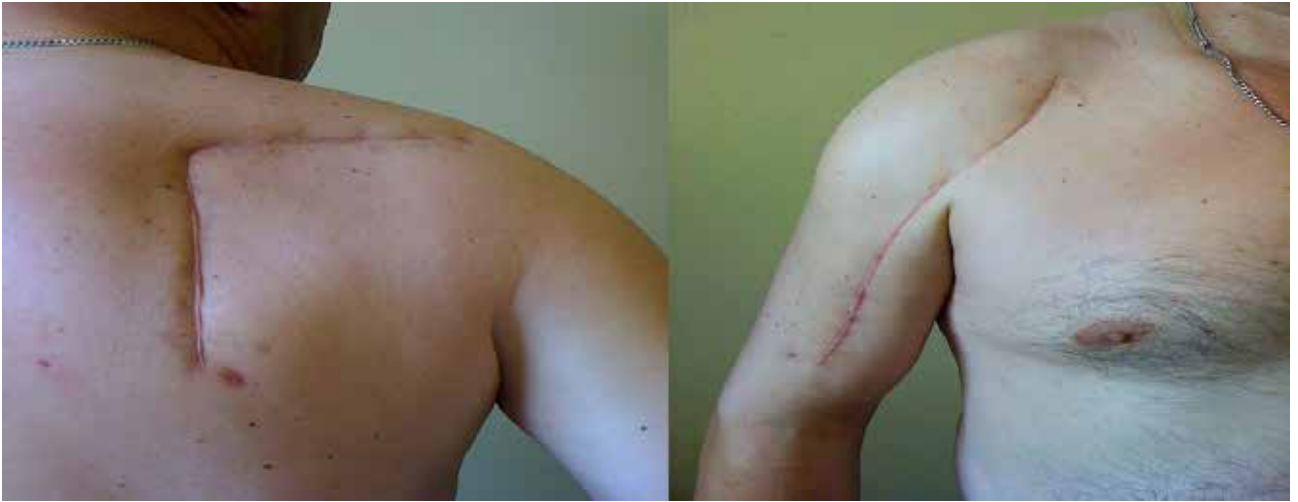

Figure 5 – Slightly hypertrophic surgical scars.

a cause of NF. The puncture itself and the possible interference of steroids with leucocyte function can cause soft tissue infection. DM may also be a predisposing condition because of associated microvasculature and immune system changes, that allow rapid progression of infection, and peripheral sensory neuropathy that increases susceptibility to trauma and delays presentation of patients to medical examination.<sup>9</sup>

Regarding diagnosis, CT and magnetic resonance imaging are useful, particularly if gas images are present (a specific sign of NF),<sup>10</sup> and to confirm deep tissue involvement and evaluate lesion spread.<sup>11</sup> Their interpretation is though challenging, as they lack specificity.<sup>11</sup>

LRINEC (Laboratory Risk Indicator for Necrotizing Fasciitis) Score may be also helpful in diagnosing NF. It is based on the following parameters: serum CRP  $\geq 15.0$  g/L (4 points); leucocytes 15000 to 25000/ $\mu$ l (2 points), hemoglobin 11.0 to 13.5 g/dl (1 point) or  $\leq 11$  g/dl (2 points), serum sodium  $< 135$  mmol/L (2 points), serum creatinine  $> 1.6$  mg/dl (2 points), serum glucose  $> 180$  mg/dl (1 point). A score of 8 or higher is highly predictive ( $> 75\%$ ) of NF; 6 or higher is suspicious.<sup>12</sup> In the presented case the score was 10, a highly predictive result. Clinical suspicion is though of great value, considering LRINEC score may fail to detect NF.<sup>13</sup>

## REFERENCES

- Burge TS. Necrotizing fasciitis—the hazards of delay. *J R Soc Med.* 1995;88:342–3.
- Wiler JL. Diagnosis: Necrotizing Fasciitis. *EMN.* 2011;11–13.
- Fernandes C, Dâmaso C, Duarte R, Cardoso DS, Casella P. Necrotizing fasciitis post-acute appendicitis. *Acta Med Port.* 2011;24:S621–6.
- Tsai YH, Wen-Wei HR, Huang KC, Huang TJ. Comparison of necrotizing fasciitis and sepsis caused by *Vibrio vulnificus* and *Staphylococcus aureus*. *J Bone Joint Surg Am.* 2011;93:274–84.
- Unglaub F, Guehring T, Fuchs PC, Perez-Bouza A, Groger A, Pallua N. Nekrotisierende fasziiitis nach injektionstherapie im schultergelenk *Orthopade.* 2005;34:250–2.
- Hofmeister E, Engelhardt S. Necrotizing fasciitis as complication of injection into greater trochanteric bursa. *Am J Orthop.* 2001;30:426–7.
- Bucca K, Spencer R, Orford N, Cattigan C, Athan E, McDonald A. Early diagnosis and treatment of necrotizing fasciitis can improve survival: an observational intensive care unit cohort study. *ANZ J Surg.* 2012.
- Gonzalez MH, Kay T, Weinzwieg N, Brown A, Pulvirenti J. Necrotizing fasciitis of the upper extremity. *J Hand Surg Am.* 1996;21:689–92.
- Fanfarillo F, Pace F, Maida R, Pignata D, Cerqua G. Necrotizing fasciitis following intra-articular steroid injection: case report and review of the literature. *Geriatr Gerontol Int.* 2012;12:353–5.
- Stevens DL. Chapter 10: Necrotizing fasciitis, gas gangrene, myositis and myonecrosis. In: Cohen J, Powderly WG, editors. *Infectious Diseases.* 2nd ed. Amsterdam: Elsevier; 2004. p.145–54.
- Malghem J, Lecouvet FE, Omoumi P, Maldague BE, Vande Berg BC. Necrotizing fasciitis: Contribution and limitations of diagnostic imaging.

The gold standard for diagnosis is thus surgery. Prompt surgical debridement, intravenous antibiotics, fluid and electrolyte management, and analgesia are mainstays of therapy.<sup>14</sup>

The mortality rate of NF has decreased since the disease was first described, although it remains high, with reported rates from 16% to 40% in studies over the last decade.<sup>7</sup> Significant associations with negative outcomes have been detected for a large number of factors, like extremes of age ( $> 60$  and  $< 1$ ), immunologic compromise and systemic diseases. The main factor recognized to influence prognosis negatively is late surgical debridement.<sup>15</sup>

## CONCLUSION

In conclusion, NF can follow intra-articular injections and should be considered, especially in immunocompromised, diabetic or obese patients. Diagnosis is based in high clinical suspicion. Aggressive surgical treatment along with appropriate antibiotherapy must be performed as soon as diagnosis is established, in order to save the patient's life.

## CONFLICT OF INTERESTS

None stated.

## FUNDING SOURCES

None stated.

- Joint Bone Spine. 2013;80:146-54.
- Citak M, Backhaus M, Tilkorn DJ, Meindl R, Muhr G, Fehmer T. Necrotizing fasciitis in patients with spinal cord injury: An analysis of 25 patients. Spine. 2011;36:E1225-9.
  - Wilson MP, Schneir AB. A case of necrotizing fasciitis with a LRINEC score of zero: clinical suspicion should trump scoring systems. J Emerg Med. 2013;44:928-31.
  - Young MH, Aronoff DM, Engleberg NC. Necrotizing fasciitis: pathogenesis and treatment. Expert Rev Anti Infect Ther. 2005;3:279-94.
  - Lancerotto L, Tocco I, Salmaso R, Vindigni V, Bassetto F. Necrotizing fasciitis: classification, diagnosis, and management. J Trauma Acute Care Surg. 2012;72:560-6.

# Localized Pigmented Villonodular Synovitis of the Shoulder: a Rare Presentation of an Uncommon Pathology

## Sinovite Vilonodular Pigmentada Circunscrita do Ombro: uma Apresentação Rara de uma Patologia Incomum

João MADRUGA DIAS<sup>1</sup>, Maria Manuela COSTA<sup>1</sup>, Artur DUARTE<sup>2</sup>, José A. PEREIRA da SILVA<sup>1</sup>  
Acta Med Port 2013 Jul-Aug;26(4):459-462

### ABSTRACT

Pigmented Villonodular Synovitis is a rare clinical entity characterized as a synovial membrane benign tumour, despite possible aggressive presentation with articular destruction. The localized variant is four times less frequent and the shoulder involvement is uncommon. We present the case of a Caucasian 59 year-old patient, who presented with left shoulder pain, of uncharacteristic quality, with local swelling and marked functional limitation of 1 month duration. Shoulder ultrasonography showed subacromial bursitis. An ultrasound-guided aspiration was performed: synovial fluid was citrine-colored and translucent. One month later, the patient maintained swelling, pain and functional impairment of the left shoulder. New shoulder ultrasound revealed exuberant subacromial bursitis, which was again aspirated using ultrasound guidance. The synovial fluid was haematic, without changes in the cell count or biochemical analysis and cultural exams. We performed an injection with 60 mg of hexacetonide triamcinolone. Two months later there was a relapse, with shoulder ultrasonography once more showing subacromial bursitis with extensive synovial membrane proliferation. Shoulder MRI revealed subacromial bursitis involving the anterior, posterior and medial recesses, with deltoid distension, but without tendinous or intra-articular involvement. In the interior of the bursa hypointense images in T2 were observed, suggesting the diagnosis of Pigmented Villonodular Synovitis. The patient had surgical bursectomy with success and without complications. The histological exam of the operatory piece confirmed the imaging diagnosis. Pigmented Villonodular Synovitis is uncommon, rarely affecting the shoulder in a localized variant. It is a diagnosis to be considered in shoulder pain, especially if associated with recurrent subacromial bursitis.

**Keywords:** Synovitis, Pigmented Villonodular, Shoulder Joint.

### RESUMO

A Sinovite Vilonodular Pigmentada é uma entidade clínica rara caracterizada como um tumor benigno da membrana sinovial, apesar de possível apresentação agressiva com destruição articular. A variante circunscrita é quatro vezes menos frequente e o envolvimento do ombro é incomum. Apresentamos o caso de uma doente de 59 anos de idade, que apresentava omalgia à esquerda, incapacitante, com tumefacção local e limitação funcional de um mês de duração. A ecografia do ombro mostrou bursite subacromial. Foi efectuada uma aspiração ecoguiada: o líquido sinovial era translúcido e de cor citrina. Um mês mais tarde, a doente mantinha tumefacção, dor e incapacidade funcional do ombro esquerdo. Foi efectuada nova ecografia do ombro, que revelou bursite subacromial exuberante, que foi novamente aspirada com apoio ecográfico. O líquido sinovial era hemático, sem alterações nos exames culturais e citológico. Efectuou-se injeção ecoguiada na bursa com 80 mg de hexacetonido de triamcinolona. Dois meses mais tarde houve recorrência de sintomas e a ecografia mostrou uma vez mais bursite subacromial com proliferação sinovial extensa. A RMN do ombro revelou bursite subacromial envolvendo os recessos anteriores, posterior e interno, com distensão do deltóide, mas sem envolvimento tendinoso ou intra-articular. No interior da bursa observaram-se imagens hipointensas em T2, sugerindo o diagnóstico de Sinovite Vilonodular Pigmentada. A doente foi sujeita a bursectomia cirúrgica, com sucesso e sem complicações. O exame histológico da peça operatória confirmou o diagnóstico imagiológico. A Sinovite Vilonodular Pigmentada é incomum, raramente afectando o ombro na variante circunscrita. É um diagnóstico a ser considerado na omalgia, especialmente se associado a bursite subacromial recorrente.

**Palavras-chave:** Articulação do Ombro; Sinovite Vilonodular Pigmentada.

### INTRODUCTION

Pigmented Villonodular Synovitis (PVNS) is a benign tissue proliferation that presents as a frontier case between a reactive and a neoplastic process and emanates from the tenosynovial layers, joint capsule or the synovial bursa. It was first defined in 1941<sup>1</sup> in a series of patients with proliferative lesions arising from the synovium of various joints.

Pigmented Villonodular Synovitis is an uncommon clinical

entity, with an estimated prevalence of 1,8:1 000 000 people.<sup>2</sup> It usually occurs in young adults, between the 3<sup>rd</sup> and 4<sup>th</sup> decades of life, with men and women equally affected.<sup>3</sup> Some authors found a female predominance.<sup>4</sup> It can present as a diffuse or a localized/circumscribed form, and it is usually monoarticular. Polyarticular involvement is exceptionally rare.<sup>3,5</sup> The extra-articular form of pigmented

1. Serviço de Reumatologia. Hospital de Santa Maria. Centro Hospitalar Lisboa Norte. Lisboa. Portugal.

2. Serviço de Radiologia. Hospital de Santa Maria. Centro Hospitalar Lisboa Norte. Lisboa. Portugal.

Recebido: 16 de Outubro de 2012 - Aceite: 26 de Abril de 2013 | Copyright © Ordem dos Médicos 2013

