

WHAT IS YOUR DIAGNOSIS?

Case for diagnosis*

Caso para diagnóstico

Rita Cabral¹Inês Coutinho¹José Pedro Reis²DOI: <http://dx.doi.org/10.1590/abd1806-4841.20132430>

CASE REPORT

A 70-year-old male patient with a prior history of diabetes and hypertension presented with hyperkeratotic, erosive nodules scattered over the trunk and limbs, scratching lesions and marked scaling, with two months of evolution. The palms, bilaterally, presented honey-colored crusting and burrows (Figure 1). He complained of pruritus, mainly at night, but there was no epidemiological context of infestation. He was hospitalized to treat a cellulitis in the right leg. On dermoscopy (Dermalite Pro II) we observed burrows in the palm of the hand, with identification of a mite in its extremity (Figure 2). Light microscopy of skin scrapings (after 10% potassium hydroxide) of one of the burrow allowed a better view of the agent (Figure 3).

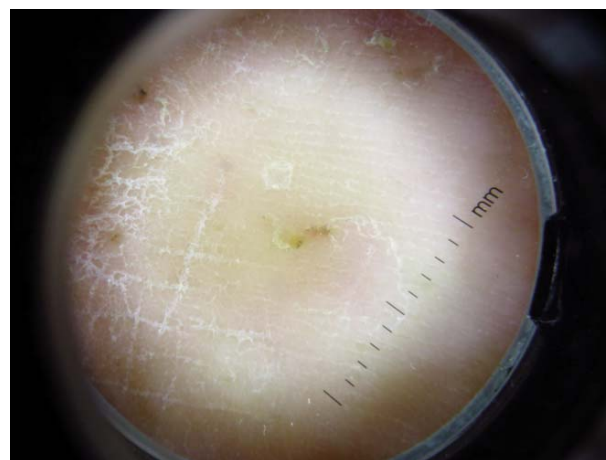


FIGURE 2: Dermoscopy (Dermalite Pro II, magnification 10x) of a burrow

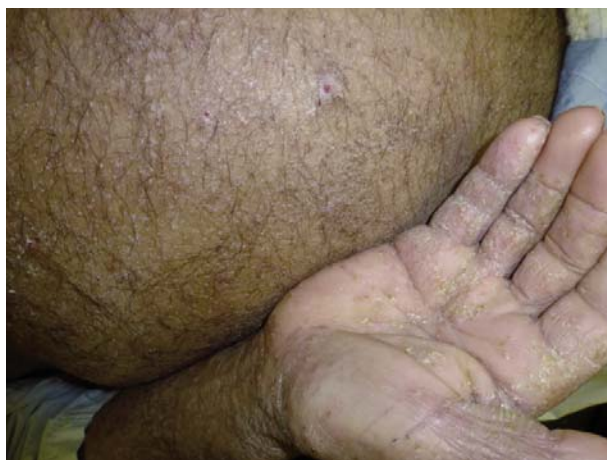

FIGURE 1: Burrows and honey-colored crusting in the palms with marked scaling and scratching lesions in the abdomen

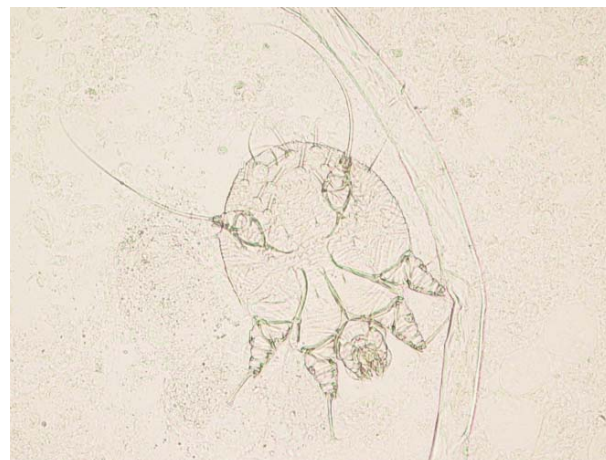


FIGURE 3: Mite identified by light microscopy (100x amplification) in skin scrapings of a burrow (after 10% KOH)

Received on 11.01.2013.

Approved by the Advisory Board and accepted for publication on 04.02.2013.

* Work performed at the Dermatology Department, Coimbra University Hospital, Coimbra, Portugal.

Conflict of interest: None

Financial funding: None

¹ MD, Resident in the Dermatology Department, Coimbra University Hospital - Coimbra, Portugal.² MD, Graduate in the Dermatology Department, Coimbra University Hospital - Coimbra, Portugal.

©2013 by Anais Brasileiros de Dermatologia

DISCUSSION

Crusted scabies is a very contagious skin infestation caused by the mite *Sarcoptes scabiei* var. *hominis*, an obligate human parasite, spreading by direct skin-to-skin contact.¹ Pruritus, with typical nocturnal exacerbation, is the main symptom. Clinically, crusted scabies involves larger areas than common scabies, with hyperkeratotic, crusted lesions, and marked scaling.^{2,3} It affects mainly patients with immunosuppression, neurological disorders or institutionalized.¹ Definitive diagnosis is made by *ex vivo* identification of mites, eggs or feces, with microscopic examination of skin scrapings, performed at appropriate sites. Noninvasive, *in vivo* mite identification can be achieved by "epiluminescence microscopy", a broad term in which standard dermoscopy is included, with observation of pathognomonic scabietic burrows and hand-glider characteristic images.^{4,5}

The authors present a case where standard dermoscopy offered a fast, easy and viable method to identify the burrows and the parasite, as brownish, triangular structures in the shape of a hand-glider

(these corresponding to the anterior portion of the *Sarcoptes scabiei*), later confirmed by light microscopy of skin scrapings. Our patient began treatment with topical sulphur ointments (6%), oral ivermectin 3mg/Kg on days 1 and 15, and sedating antihistamines.⁶ Isolation measures were taken in the ward, as well as treatment of all household members and close personal contacts. Re-evaluation of the patient, three weeks later, confirmed the disappearance of the symptoms and cutaneous lesions. Infestation of close contacts was not detected.

Our case report supports previous studies, confirming standard dermoscopy as an easily accessible, less time-consuming, approach. As a high sensitivity tool for the diagnosis of hyperkeratotic scabies, it is also better accepted by the patients.⁴ This allowed the prompt and correct treatment not only of the patient, but also of all his close contacts, in this case in a hospital ward, thereby preventing an outbreak of scabies in the hospital environment. □

Abstract: Human scabies is an intensely pruritic skin infestation caused by *Sarcoptes scabiei* var. *hominis*. Crusted scabies (previously known as Norwegian scabies) is a rare form, very contagious and transmitted by direct contact with the skin. Despite being readily treatable, a delayed diagnosis often leads to widespread infestation of contacts, and therefore difficult to restrain. This case concerns a patient where dermoscopy (with scabietic burrows and a visible hand-glider structure), together with direct microscopic examination, allowed a prompt diagnosis, thereby reinforcing the increasing importance of this technique in daily practice.

Keywords: Dermoscopy; Pruritus; Scabies; Skin diseases, parasitic

Resumo: A escabiose ou sarna humana é uma infestação cutânea intensamente pruriginosa causada por *Sarcoptes scabiei* var. *hominis*. A sarna crostosa (previamente conhecida como sarna norueguesa) é uma forma rara, muito contagiosa e transmitida pelo contacto direto com a pele. Apesar de eficazmente tratável, um atraso no diagnóstico leva muitas vezes ao contágio e infestação dos contactos, o que dificulta a contenção dos surtos. Apresentamos o caso de um doente onde os achados dermatoscópicos (sulcos escabióticos e estruturas em asa delta), confirmados pelo exame parasitológico direto, permitiram um rápido diagnóstico, reforçando o papel crescente que esta técnica assume na prática clínica.

Palavras-chave: Dermatopatias parasitárias; Dermosopia; Escabiose; Prurido

REFERENCES

1. Guldbakke KK, Khachemoune A. Crusted scabies: a clinical review. *J Drugs Dermatol.* 2006;5:221-7.
2. Johnston G, Sladden M. Scabies: diagnosis and treatment. *BMJ.* 2005;331:619-22.
3. Elgart ML. Scabies. *Dermatol Clin.* 1990;8:253-63.
4. Dupuy A, Dehen L, Bourrat E, Lacroix C, Benderdouche M, Dubertret L, et al. Accuracy of standard dermoscopy for diagnosing scabies. *J Am Acad Dermatol.* 2007; 56:53-62.
5. Towersey L, Cunha MX, Feldman CA, Castro CG, Berger TG. Dermoscopy of Norwegian scabies in a patient with acquired immunodeficiency syndrome. *An Bras Dermatol.* 2010;85:221-3.
6. Aubin F, Humbert P. Ivermectin for crusted (Norwegian) scabies. *N Engl J Med.* 1995;332:612.

MAILING ADDRESS:

Ana Rita Gomes da Cruz Rodrigues Cabral
Dermatology Department,
Coimbra University Hospital
Praceta Mota Pinto
3000-075 - Coimbra
Portugal
E-mail: ritaca@portugalmail.com

How to cite this article: Cabral R, Coutinho I, Reis JP. Case for diagnosis. Itching - a little help from dermoscopy. *An Bras Dermatol.* 2013;88(5):826-7.