

Intracardiac aorto-right atrial tunnel

Rita Pancas*, Gonçalo F. Coutinho and Manuel J. Antunes

Department of Cardiothoracic Surgery, University Hospital of Coimbra, Coimbra, Portugal

* Corresponding author. Hospitais da Universidade de Coimbra, Centro de Cirurgia Cardiotorácica, Praceta Professor Mota Pinto, 3000-075 Coimbra, Portugal. Tel: +351-961-458337; fax: +351-239-829674; e-mail: rita_agante@hotmail.com (R. Pancas).

Received 13 September 2011; received in revised form 11 January 2012; accepted 12 January 2012

Keywords: Congenital aorto-right atrial fistula • Surgical correction

A 51-year old asymptomatic woman with no history of trauma or other relevant pathological background was referred to our institution due to an intracardiac aorta-right atrial fistula.

Diagnosis was made by echocardiography and confirmed by cardiac catheterization. Surgical closure of both orifices (Figs. 1 and 2) was performed under cardiopulmonary bypass.

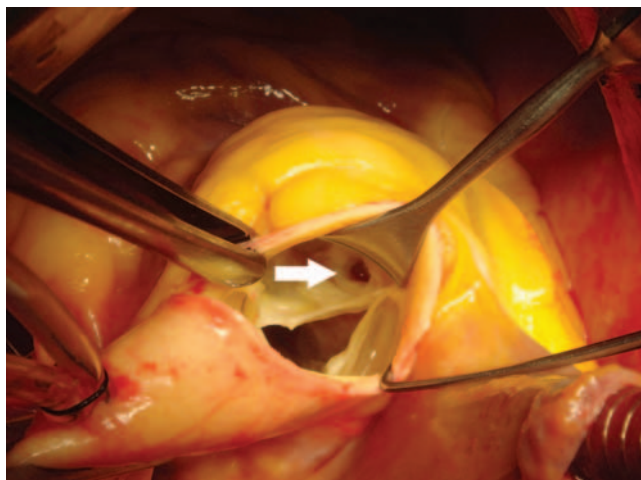


Figure 1: Aortic component.

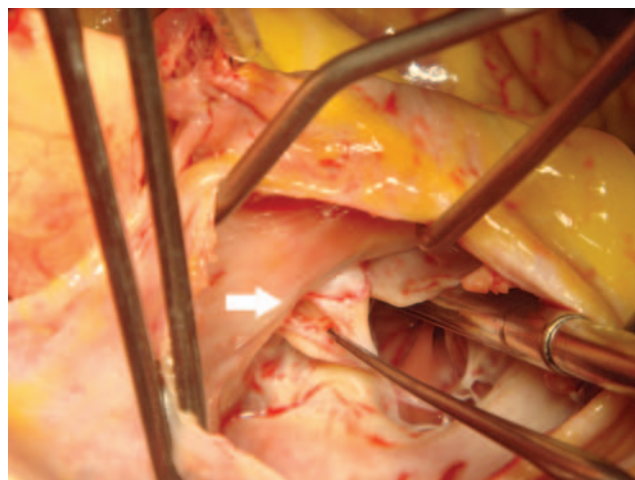


Figure 2: Right atrial component.