

# 27 Mechanisms in Cutaneous Drug Hypersensitivity Reactions

Margarida Gonçalo and Derk P. Bruynzeel

## CONTENTS

27.1	Introduction.....	259
27.2	Pathomechanisms in Cutaneous Adverse Drug Reactions.....	259
27.2.1	Immune and Nonimmune Mechanisms Involved in CADR.....	259
27.2.2	Drug Recognition by the Immune System and Skin Reaction Patterns.....	260
27.2.3	Concomitant and Predisposing Factors in Drug Eruptions.....	260
27.3	Immediate Adverse Drug Reactions.....	261
27.4	Delayed Cutaneous Adverse Drug Reactions.....	262
27.4.1	Maculopapular Exanthems.....	262
27.4.2	Drug-Induced Hypersensitivity Syndrome/Drug Reaction with Eosinophilia and Systemic Symptoms.....	263
27.4.3	Acute Exanthematic Generalized Pustulosis.....	264
27.4.4	Stevens–Johnson Syndrome/Toxic Epidermal Necrolysis.....	265
27.4.5	Fixed Drug Eruption.....	266
27.5	Concluding Remarks.....	266
	References.....	267

## 27.1 INTRODUCTION

Adverse drug reactions involving the skin are a common problem but their real incidence is not known. Among inpatients 2–5% experience a cutaneous adverse drug reaction (CADR)<sup>1,2</sup> but, although it is a frequent cause of consultation or urgent observation at a Dermatology department,<sup>3</sup> no precise data exists concerning its incidence in outpatients. Only 2% are severe reactions,<sup>1</sup> therefore, most are not reported to the pharmacovigilance systems. Also, in some cases, the diagnosis of CADR is one of presumption, with no definitive test to prove it, or of exclusion for which the dermatologist has to be alert. Some CADR are mild and resolve spontaneously, others represent an exaggeration of the drug pharmacological effect, some are similar to viral exanthems or idiopathic urticaria, and others mimic skin diseases which are not usually drug-induced, namely pemphigus, bullous pemphigoid, lupus erythematosus, psoriasis, and lichen planus.<sup>1,3,4</sup>

**AQ1**

## 27.2 PATHOMECHANISMS IN CUTANEOUS ADVERSE DRUG REACTIONS

### 27.2.1 IMMUNE AND NONIMMUNE MECHANISMS INVOLVED IN CADR

Most CADR are certainly not immune mediated, representing a pharmacological drug effect often exaggerated due to drug interactions, concomitant diseases that modify drug

bioavailability, or predisposing genetic polymorphisms of drug detoxifying enzymes. As an example, skin and oral mucosa erosions can occur during methotrexate treatment in patients with low serum albumin, low renal clearance, or on concomitant use of nonsteroidal antiinflammatory drugs (NSAID). These predictable reactions, called type A, may represent up to 80% of CADR<sup>4</sup> and are not the object of this chapter.

Unpredictable, idiosyncratic CADR, called type B, namely drug “rashes” or “drug eruptions,” are those mostly dependent on immune hypersensitivity reactions. CADR upon systemic drug exposure include a wide variety of skin reaction patterns occurring either immediately upon exposure or with a delay of hours, days, sometimes after weeks, or months of drug administration, depending on the hypersensitivity mechanisms involved and whether the individual is already sensitized or not. The pathogenic mechanisms involved are not usually simple and include a complex interplay of different effectors of the immune system, which orchestrate the immuno-inflammatory skin reaction in a still not yet fully understood way.<sup>1,4</sup>

The 4 classical mechanisms of immune hypersensitivity defined by Gell and Coombs participate in CADR. Immediate type I hypersensitivity from drug specific IgE is involved in acute urticaria and anaphylaxis, type II antibody-mediated cytotoxicity is reported in drug-induced hemolytic anemia and drug-induced immune complexes can be deposited in small cutaneous vessels inducing leukocytoclastic vasculitis,

representing a type III reaction.<sup>4</sup> Delayed type IV hypersensitivity involving T cells that specifically recognize the drug (or a drug metabolite) has been well documented namely in generalized maculopapular exanthema (MPE), in the drug induced hypersensitivity syndrome (DIHS) also known as DRESS (Drug-induced rash with eosinophilia and systemic symptoms), in acute generalized exanthematic pustulosis (AGEP), in fixed drug eruption (FDE), and in the more widespread and severe Stevens–Johnson syndrome (SJS) or toxic epidermal necrolysis (TEN).<sup>4–6</sup> For each of these different clinical and histological patterns, delayed hypersensitivity is involved through different subsets of T cells and soluble effectors that recruit a wide range of other cells and orchestrate the inflammatory response, inducing lesions that affect only the skin or, eventually, also other organs.<sup>5</sup>

Topical drugs cause allergic contact dermatitis, a typical T-cell mediated reaction, which can become widespread simulating a drug eruption due to percutaneous drug absorption.<sup>6,7</sup> Also, systemic exposure to drugs to which patients were previously sensitized through the skin can induce systemic contact dermatitis,<sup>8</sup> presenting as a “baboon syndrome” also known as SDRIFE (symmetrical drug-related intertriginous and flexural exanthema)<sup>9</sup> or an acrovesicular dermatitis.<sup>6,8</sup>

Photo-active drugs, either upon topical or systemic exposure, can induce a photosensitive eruption on sun exposed areas, due to a phototoxic or a photoallergic mechanism, in this case dependent on a type IV hypersensitivity reaction to the drug or a photoproduct. One such example is piroxicam, a NSAID which upon UVA exposure gives rise to a photoproduct chemically and antigenically similar to the thiosalicylate moiety of thiomersal, and, therefore, induces photoallergy in individuals previously sensitized to thiomersal.<sup>10,11</sup>

In some cases, the drug modifies the immune response promoting autoimmunity or induces the production of pathogenic antibodies directed against skin structures, as in vancomycin-induced linear IgA dermatitis,<sup>12</sup> in drug-induced pemphigus, and in terbinafine-induced subacute lupus erythematosus. Sometimes autoantibodies are found during the eruption but their pathogenic significance is not known, as in a case of DRESS with antibodies against the 190 kDa antigen targeted usually in pemphigus foliaceus or paraneoplastic pemphigus.<sup>13</sup>

### 27.2.2 DRUG RECOGNITION BY THE IMMUNE SYSTEM AND SKIN REACTION PATTERNS

Apart from the wide list of drugs capable of inducing immune mediated CADR, each drug can induce several skin reaction patterns and depending on the reaction pattern (and sometimes within the same reaction pattern), the antigenic moiety recognized by the immune system is different: the drug itself, an intermediate metabolite, both the drug and a metabolite, or proteins/peptides modified by reactive drugs or metabolites. Drugs can be specifically recognized by IgE in immediate hypersensitivity, by antibodies fixed on red blood cells inducing hemolytic anemia, by soluble antibodies inducing

immune complex vasculitis, or by the TCR of T cells, both in the context of HLA-class I or class-II molecules and either covalently or noncovalently bound.<sup>14,15</sup> The problem is more complex as, for instance, in the case of MPE from cotrimoxazol, some T-cell clones recognize sulfamethoxazole and other antiinfectious sulfonamides with a same conformational structure, giving rise to cross-reactions,<sup>16</sup> whereas other T-cell clones recognize intermediate metabolites, like hydroxylamine sulfamethoxazole or nitroso sulfamethoxazole,<sup>15</sup> either presented directly in the HLA groove<sup>14,15</sup> or after antigen processing and with MHC restriction,<sup>14,16</sup> with a more restricted cross-reactive pattern. In the case of immediate hypersensitivity to penicillin, IgE can recognize either the benzylpenicilloyl moiety or the side chain; therefore, recognizing by cross-reaction other penicillins or, eventually, also cephalosporins.<sup>17,18</sup> For piroxicam, the moiety recognized by the immune system depends on the reaction pattern. The thiosalicylate moiety, which is formed after UVA radiation is responsible for the photoallergic reaction. As this photoproduct is exclusive for piroxicam, other oxicams like tenoxicam can be safely used in photoallergy. Whereas, in FDE the immune system recognizes another oxicam moiety which is common to tenoxicam and, therefore, all patients with FDE to piroxicam cross react with tenoxicam.<sup>10,11,19</sup>

### 27.2.3 CONCOMITANT AND PREDISPOSING FACTORS IN DRUG ERUPTIONS

Even though we do not understand all the steps of sensitization to drugs and how some individuals become sensitized and develop CADR while others do not, there are few known predisposing factors.

One important aspect deals with the drug detoxification process where polymorphisms within drug metabolizing enzyme genes, namely in the cytochrome  $P_{450}$ , can give rise to different intermediate reactive (or nonreactive) drug metabolites or to distinct amounts of the culprit metabolite.<sup>20,21</sup> Some HLA haplotypes, which may be related to the capacity of the drug to combine or insert into the HLA groove of antigen presenting or target cells, have been associated with increased or reduced capacity to develop a drug eruption to a certain drug,<sup>5</sup> as shown for HLA-B\*1502 predominance in patients from Twaian who develop SJS to carbamazepine.<sup>22</sup> Also polymorphisms in immuno-inflammatory response pathways may increase the risk of some particular drug reactions: predisposition to produce higher levels of soluble FAS ligand and polymorphisms in the TNF-promoter region may correlate with an increased severity of drug reactions,<sup>5,22</sup> disturbances in complement and cinin metabolism, namely in carboxypeptidase that degrades bradykinin, may favor angioedema induced by ACEI, and polymorphisms in the gene for LTC4 synthase may justify familial aggregation of aspirin induced urticaria.<sup>23</sup>

Also, the immune status of the patient during drug exposure may be important for the outcome of the CADR. Concomitant aggressions (exposure to other reactive chemicals or other drugs), infectious diseases (bacterial or viral infections),

A03

A02

A04

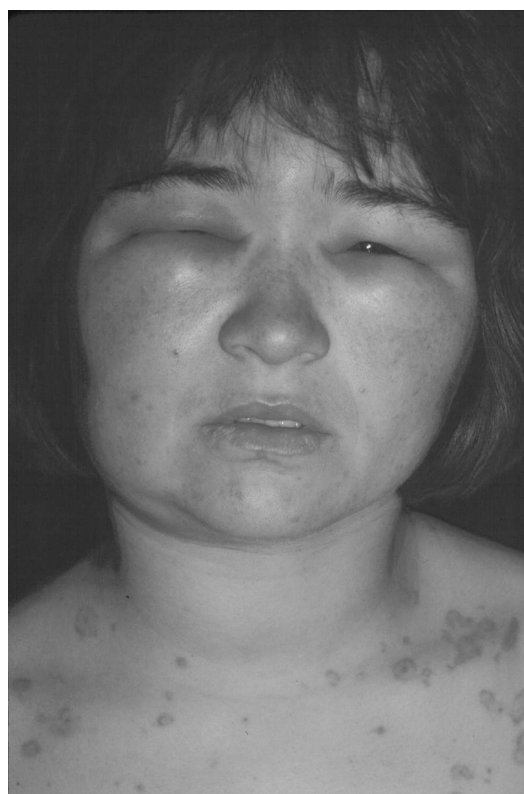chronic immuno-inflammatory diseases (Still's disease, systemic lupus erythematosus), or nonspecific immune activation by reactive drug metabolites may act as “danger” signals that alert the innate immune system and activate monocyte/macrophages or dendritic cells that become increasingly capable of presenting the drug to T cells.<sup>20,24</sup> Therefore, these concurrent factors may be of extreme importance, especially during active drug sensitization, but also during the development of the CADR in a sensitized individual. As an example, patients with systemic lupus erythematosus or HIV+ patients are more susceptible to CADR, namely from sulfonamides.<sup>15,24</sup> During Epstein-Barr virus (EBV) or Cytomegalovirus (CMV) infection, antibiotics induce MPE in a high proportion of patients,<sup>25,26</sup> but even though aminopenicillins induce an MPE in almost every patient, only a few of these really become sensitized to the drug and develop a skin rash on re-exposure without the concomitant infection.<sup>25–27</sup> Also, during the last decades attention has been drawn to the association of the DIHS/DRESS with human herpes virus type 6 (HHV-6) primo-infection or reactivation.<sup>26,28,29</sup> Concomitant use of aminopenicillins and allopurinol also seem to represent a risk factor for developing CADR.<sup>25,30</sup>

**AQ5** Nevertheless, and apart from these difficulties and variables that complicate, the study of pathomechanisms involved in CADR, immediate and delayed skin testing, drug rechallenge, and *in vitro* studies using drug specific antibodies or drug specific T cell clones isolated from the blood and skin of patients with CADR or from positive skin tests, have brought new light into the immune mechanisms involved in CADR, that we will review for the main reaction patterns.

### 27.3 IMMEDIATE ADVERSE DRUG REACTIONS

These reactions occur within minutes to a few hours after drug exposure and present clinically as pruritus, urticaria, or angioedema regressing with no residual lesions within minutes to hours. In severe cases, urticaria and angioedema are associated with systemic symptoms like nausea, abdominal cramps, sneezing, bronchospasm, and dispnea that can progress to hypotension and shock in its most severe expression— anaphylaxis. The most severe acute immediate reactions are induced by beta-lactam antibiotics (pencillin G and aminopenicillins), iodinated radiocontrast media, and muscle relaxants used in anesthesia, whereas the more frequent but less severe immediate reactions are due to aspirin and NSAID, codein, vancomycin, angiotensin converting enzyme inhibitors (ACEI), heparins, and insulin, but any drug can induce an immediate adverse reaction.<sup>4,17,31</sup> (Figure 27.1 showing an immediate reaction with urticaria and angioedema from a NSAID.)

Immediate reactions are dependent on drug specific IgE fixed on tissue mast cells and circulating basophils, but clinically similar reactions, although usually less severe, occur without the identification of a drug specific immune reaction, and are, therefore, called pseudoallergic or anaphylactoid.<sup>1,4,31</sup> In all cases, the tissue mast cells, blood basophils and, eventually, platelets,<sup>32</sup> liberate the content of



**FIGURE 27.1** Angioedema and urticarial lesions after ingestion of a NSAID (diclofenac).

their granules (histamine, tryptase, heparin, cytokines, and chemokines) and produce secondary vasoactive mediators (prostaglandins, leukotrienes, PAF/platelet activation factor, and cinins), which together are responsible for the vasodilatation, increased vascular permeability, and pruritus observed in urticaria.<sup>4,33</sup>

In immediate hypersensitivity, cell degranulation occurs upon specific mast cell or basophil IgE bridging by the drug.<sup>4</sup> Nevertheless, degranulation can occur by nonIgE dependent mechanisms like the activation of cell receptors for complement anaphylotoxins (C3a and C5a), direct drug effect on the cellular membrane or in intracellular pathways that regulate degranulation, or imbalance between prostaglandins and leukotrienes due to cyclooxygenase inhibition by NSAID. Still, a similar reaction can occur from the increase of bradykinin and other vasoactive mediators due to drugs that inhibit their degradation, like ACEI.<sup>1,4,34–36</sup>

In immediate hypersensitivity reactions, a drug specific IgE is found in *in vitro* tests, there is *in vitro* drug specific basophil activation (measured either by the expression of CD63 by flow cytometry or by mediator release),<sup>33,37</sup> and immediate skin testing (prick or intradermal) and drug rechallenge (which is not advised in severe cases) are positive in a high proportion of patients (>80%).<sup>31</sup> Nevertheless, with several drugs that induce IgE mediated reactions, like muscle relaxants, iodinated radiocontrast media and heparins, there is also a direct capacity for nonspecific basophil or mast cell activation, which can be responsible for nonspecific

positive skin and basophil activation tests (CD63 expression or mediator release).<sup>34,35,38</sup> Also, occasionally, drug specific IgE has been documented in aspirin-induced urticaria and asthma, classically considered pseudoallergic,<sup>39</sup> and even for penicillin a nonspecific capacity for mast cell activation (albeit low) has been documented *in vitro*. Therefore, this makes the distinction between what are called allergic and pseudoallergic reactions difficult, both on clinical and laboratory grounds.

Drug specific IgG or IgM antibodies can also be responsible for immediate symptoms,<sup>36</sup> because these antibodies give rise to circulating immune complexes and complement activation and induce urticaria with systemic symptoms within the context of serum disease (fever, arthralgia or arthritis, abdominal pain and urticaria, urticaria vasculitis, or leukocytoclastic vasculitis), which occurs either immediately or within a few days of drug administration.<sup>4,40</sup>

## 27.4 DELAYED CUTANEOUS ADVERSE DRUG REACTIONS

There are several clinical and experimental arguments that confirm the involvement of delayed type hypersensitivity with the participation of drug specific T cells in the following CADR: MPE, DIHS/ DRESS, AGEP, SJS, TEN, and FDE.<sup>4,24,41</sup> (1) These eruptions begin within 7–21 days in the 1st episode and 1–2 days after drug reintroduction; (2) Drug specific positive oral rechallenge with lower doses is usually observed;<sup>42</sup> (3) On histopathology there is mainly a dermo-epidermal infiltration of activated T cells; (4) In a high

percentage of cases, the culprit drug induces specific positive patch, prick, or intradermal skin testing with delayed readings;<sup>6,43–46</sup> (5) *In vitro* tests show drug specific T lymphocyte proliferation/activation;<sup>47,48</sup> and (6) Drug specific T-cells lines and T-cell clones have been isolated from the blood and skin during the acute episode or, later, from positive patch tests.<sup>41,49</sup>

Nevertheless, as there are distinct subsets of T cells with distinct cytokines/chemokines and aggressive machinery, they orchestrate the inflammatory skin reaction giving rise to different patterns of drug reactions. Therefore, a subdivision of delayed hypersensitivity T-cell reactions has been made in agreement into type IVa, IVb, IVc and, more recently, type IVd.<sup>5</sup> They represent, respectively, the reactions mediated predominantly by T-helper 1 (interferon (IFN)- $\gamma$ ), T-helper 2 (interleukin (IL)-4 and IL-5), cytotoxic reactions (CTL, CD8+ rich in perforin, granzyme B, and FasL), and CXCL8 (IL-8) secreting T cells that promote neutrophilic inflammation.<sup>24,50</sup>

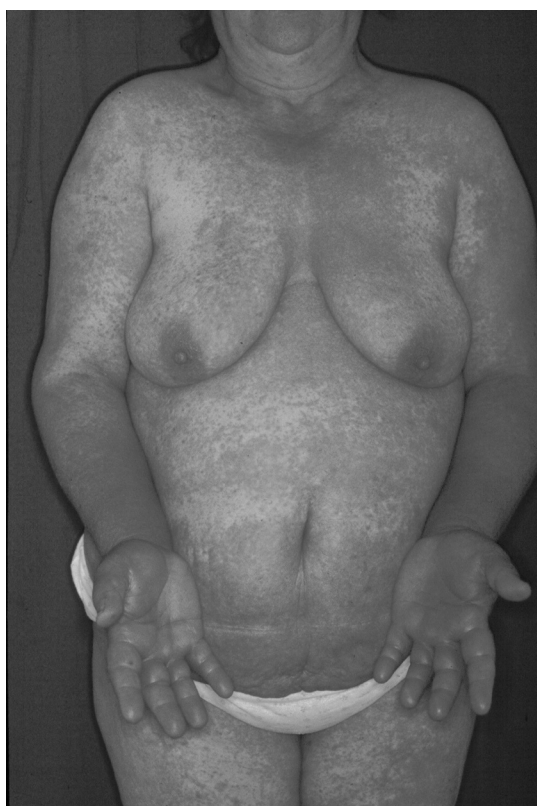The participation of these subsets is very particular in the different patterns of delayed drug eruptions, as detailed below in Table 27.1.

### 27.4.1 MACULOPAPULAR EXANTHEMS

MPE, the most frequent pattern of CADR, appear as generalized symmetric eruptions of isolated and confluent erythematous macules or papules, often starting in the trunk and then spreading to the extremities. Mucosa are not involved, there are no evident systemic symptoms apart from a low-

**TABLE 27.1**  
General Aspects of the Hypersensitivity (HS) Mechanisms Involved in the Main CADR

Type of Reaction	Immediate	Delayed				
		MPE	DRESS	AGEP	SJS/TEN	FDE
Reaction pattern	Urticaria/ anaphylaxis	MPE	DRESS	AGEP	SJS/TEN	FDE
Main drugs	Penicillins, Contrast media, NSAID	Antibiotics	Anticonvulsivants	Antibiotics	Allopurinol	NSAID
Drug recognition	IgE	Allopurinol	Allopurinol	Aminopenicillins	Anticonvulsivants	
Effector cells	Mast cells	Allopurinol	Minocycline		Sulfonamides	
Soluble mediators	Basophils	TCR/HLA I-II	TCR/HLA-II	TCR /HLA I	TCR	TCR
Target cells	Histamine	CD4/CD8	CD4/CD8	CD4+	CD8+CD56+	CD8+CD69
<i>In vivo</i> tests	Trypsin		eosinophils	neutrophils		
<i>In vitro</i> tests	PGs, LTs, PAF	Perforin	IL-5	CXCL8	Fas/FasL	Fas/FasL
Other aspects	Endothelial cells	IFN- $\gamma$	IFN- $\gamma$	GM-CSF	TNF- $\alpha$	IFN- $\gamma$
Type of HS		IL-5	IFN- $\gamma$	IFN- $\gamma$	Perforin	
		Keratinocytes other skin cells	Keratinocytes other skin cells	Epidermis	Keratinocytes	Keratinocytes
		Patch testing oral challenge	Patch testing	Patch testing	...	Lesional testing Oral challenge
		LTT	LTT	LTT	LTT	N/A
		Mimic viral and bacterial exanthems	Concomitant HHV-6	Neutrophilic Inflammation	High mortality rate	"preactivated" T cells in residual lesions
		Type IVa, IVb, and IVc	Type IVa, IVb, and IVc	Type IVd	Type IVc	Type IVc



**FIGURE 27.2** Maculopapular exanthem from carbamazepine.

grade fever which can also contribute to mimic a viral or bacterial exanthem. The reaction develops within 7–14 days after drug intake (or within 1 or 2 days in sensitized patients) mainly due to antibiotics (aminopenicillins, cephalosporins, and sulfonamides), allopurinol, and anticonvulsivants. The reaction may be mild and regress within a few days, but most often it progresses for a few days even after drug suspension and then fades progressively within 10–15 days, often with desquamation.<sup>5,51</sup> (Figure 27.2 showing a MPE from carbamazepine.)

On histopathology, early lesions show an interface dermatitis with hydropic degeneration of basal keratinocytes, mild spongiosis, scattered dyskeratotic and necrotic keratinocytes, and lymphocytes mainly at the dermal epidermal junction and in papillary dermis with eosinophils along dermal vessels.<sup>51,52,24</sup> Lymphocytes are skin homing highly activated T cells (CLA+, CD3+, DR+, CD25+) expressing adhesion molecules such as CD11a-CD18 (LFA-1) and CD62L (L-selectin). They are attracted from the blood through the expression of the corresponding adhesion molecules in endothelial cells and keratinocytes (ICAM-1, HLA-II) and by the production of keratinocyte chemokines, like the CCRL27 (also known as CTACK-cutaneous T-cell attracting chemokine) that selectively recruits skin homing memory T cells expressing the CCR10 receptor.<sup>15,52,53</sup> Most lymphocytes infiltrating the skin are CD4+ T cells expressing high levels of perforin and granzyme B but CD8+ T cells are also found, mainly in the epidermis.<sup>5,51,52</sup> T cells secrete a heterogenous profile of cytokines and chemokines: type 1 cytokines (IFN- $\gamma$ ) activate

dendritic cells and keratinocytes increasing their expression of HLA-II that binds the drug and presents it to T cells; IL-5, a type 2 cytokine, along with the eotaxin/CCL-11 is responsible for the recruitment and activation of eosinophils, a local and systemic hallmark of cutaneous maculopapular drug eruptions.<sup>51</sup> During the acute phase, CLA+CD4+ T cells expressing perforin are also increased in the blood and after isolation exhibit *in vitro* cytotoxic activity against keratinocytes, therefore, reinforcing their capacity to cause keratinocyte damage in the skin.<sup>51</sup> Similar cells have been isolated from positive epicutaneous patch tests with the culprit drug and it has been shown that the T-cell clones isolated from the blood, skin, and positive patch tests in patients with MPE are specifically stimulated by the culprit drug and exhibit similar profiles of activity, namely perforin expression and production of cytokines and chemokines (INF- $\gamma$ , IL-5).<sup>41,49</sup>

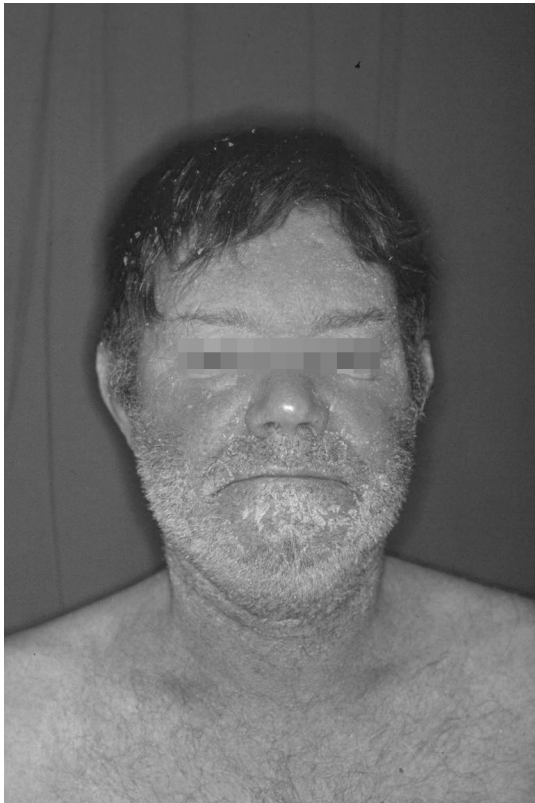**AQ6**

Therefore, after a process of T-cell sensitization, a further exposure to the drug that reaches the skin and combines with skin proteins or HLA molecules of keratinocytes and dendritic cells, activates resident skin and circulating CD4+ and CD8+ T cells, which are attracted to the skin and selectively damage the cells where the drug is fixed, mainly by perforin and granzyme B. Cytokines and chemokines produced by T cells and resident skin cells recruit other inflammatory cells that orchestrate the dermal and epidermal inflammatory reaction in MPE. Therefore, various subtypes of delayed hypersensitivity, mainly type IVa, IVb, and IVc seem to be involved in this pattern of CADR.<sup>5</sup>

#### 27.4.2 DRUG-INDUCED HYPERSENSITIVITY SYNDROME/DRUG REACTION WITH EOSINOPHILIA AND SYSTEMIC SYMPTOMS

DRESS is a severe life-threatening CADR that develops 2–8 weeks after drug intake, usually an anticonvulsant, allopurinol, a sulfonamide, dapsone, or minocycline. It involves the skin, presenting with a nonspecific maculopapular rash or a more generalized exfoliative dermatitis, often with severe facial edema (Figure 27.3 shows a case of DRESS induced by allopurinol with an exfoliative dermatitis and facial edema). Systemic symptoms are always present and consist of fever, malaise, arthralgia, enlarged lymph nodes, hepatic, renal or pulmonary failure, and blood leukocytosis with circulating atypical (activated) lymphocytes and eosinophilia that sometimes occurs a few days later. It begins after a longer interval than for other drug rashes and also regresses slowly often with exacerbations, either related with steroid withdrawal, viral reactivation, or administration of a cross reactive drug.<sup>1,28,29</sup> Also, delayed reactivation apparently with no drug exposure or with exposure to a nonrelated drug have been reported.<sup>54</sup>

In DRESS, circulating activated T cells expressing CLA+ and CCR10 increase in the blood in proportion with the skin severity, and these CD4+ and CD8+ T cells infiltrate the dermis and epidermis.<sup>15</sup> In carbamazepine and lamotrigine sensitive patients, T-cell clones generated from these infiltrating skin and circulating cells, react specifically to these drugs on HLA-II matched antigen presenting cells



**FIGURE 27.3** Exfoliative dermatitis with facial edema in a case of DRESS induced by allopurinol.

apparently independent of drug metabolism and antigen processing.<sup>15</sup> These T cells have a  $\alpha\beta$  TCR, almost all with the V $\beta$  5.1 chain, suggesting that the drug might also act as a superantigen.<sup>55</sup> These T-cell clones are rich in perforin and secrete a type 1 cytokine pattern with IFN- $\gamma$  and chemokines that control the duration and severity of the inflammatory response,<sup>15</sup> but they also show a very significant IL-5 secretion which is responsible for the characteristic eosinophilia observed in this syndrome.<sup>56</sup>

Nevertheless, and even though these drug specific T-cells clones have been isolated in DRESS<sup>15</sup> and, in our experience, patch tests with the drug, namely with carbamazepine, are often positive,<sup>57</sup> the pathomechanisms involved seem to be complex and not exclusively dependent on the drug. Most authors refer the need for a concomitant HHV-6 reactivation, which would be responsible for the systemic symptoms as well as for exanthem reactivation without drug.<sup>29,28,54</sup> Recent studies presented by Yoko Kano and Testsuo Shiohara suggest that HHV-6 reactivation, evaluated by detection of viral deoxyribonucleic acid (DNA) by Polymerase chain reaction (PCR) and by the increase in anti-HHV-6 IgG titer in blood, occurs after a certain degree of immunosuppression, particularly hypogammaglobulinemia, induced by the drug.<sup>29</sup> They also suggest that, just after drug suspension, the recovery of CD4+ and CD8+ cells will be responsible for an immune reconstitution inflammatory syndrome (IRIS) with damage of the tissues where the virus/drug is localized, as observed in acquired immune deficiency syndrome (AIDS) after

highly active antiretroviral therapy (HAART) treatment.<sup>58</sup> This might explain why, in their experience, lymphocyte transformation tests (LTT) are positive only after a certain time of evolution of the DRESS when there is a full immune reconstitution.<sup>58</sup>

Although drug specific T cells with a high production of IL-5 and eotaxin, responsible for the systemic and skin eosinophilia,<sup>55,56</sup> have been observed in DRESS, suggesting the involvement of a type IVb and IVc hypersensitivity reaction, further studies are needed to fully understand the mechanisms underlying this severe ADR.

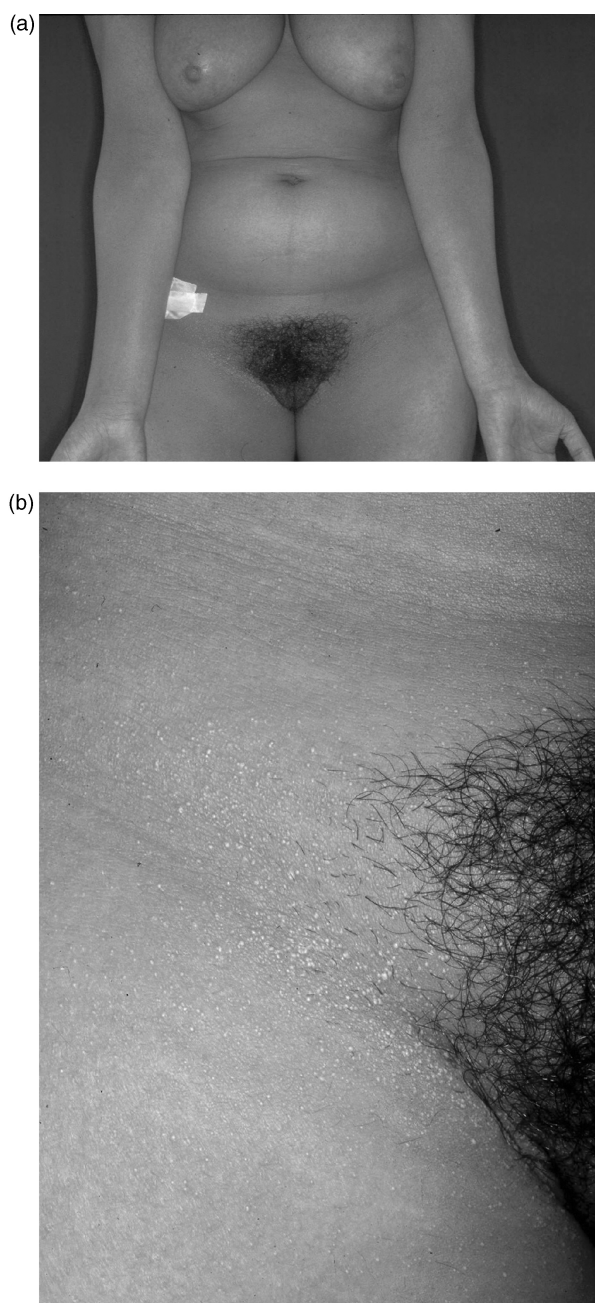
### 27.4.3 ACUTE EXANTHEMATIC GENERALIZED PUSTULOSIS

AGEP is a very peculiar reaction pattern induced by drugs in more than 90% of cases, mainly by aminopenicillins and other antibiotics. It is characterized by the acute onset of symmetrical widespread edematous erythema covered by small nonfollicular sterile pustules, predominating in the face and body folds, high fever ( $>38^{\circ}\text{C}$ ), leukocytosis, neutrophilia and, occasionally, eosinophilia. (Figures 27.4a and 27.4b show a patient with AGEP from amoxicillin with the predominance of small pustules on body folds.) The reaction develops around 1 week after drug intake and regresses in 5–10 days after drug withdrawal. Lymphocyte transformation tests and, typically, patch tests are positive<sup>9</sup> and, after 72 hours, show a pustulous pattern similar to the acute reaction.<sup>60,61</sup>

The histology and immunohistochemistry of early biopsies from AGEP show a dermo-epidermal infiltration of T cells, mainly CD4+DR+CD25+, with discrete vacuolar keratinocyte degeneration and a perivascular infiltrate, sometimes with vasculitis.<sup>62,63</sup> Lesions progress to spongiotic vesicles that soon transform into subcorneal pustules due to neutrophil accumulation.<sup>63</sup> This same pattern occurs at positive patch tests, which make them a very useful tool to study the pathomechanisms involved in AGEP. From the blood and skin biopsies of patch tests, several drug-specific T-cell lines and T-cell clones have been isolated and characterized. They are mainly CD4+ memory effector T cells, which exhibit cytotoxicity against drug laden target cells, both through perforin/granzyme B and Fas ligand.<sup>64</sup> They secrete mainly a type 1 cytokine pattern (IFN- $\gamma$  and GM-CSF), in some cases with IL-5, responsible for eosinophilia observed in about one third of AGEP patients.<sup>61</sup> Nevertheless, the main particular characteristic of these T cells is the high production of CXCL8 (IL-8) and other cytokines, like GM-CSF, that recruit and prolong survival of neutrophils in the skin. Actually, *in vitro* tests have shown that apart from CXCL8 that recruits neutrophils bearing the CXCR1, other mediators of these T cells, like GM-CSF and INF- $\gamma$ , acting mainly through the CXCR2, prevent neutrophil apoptosis and prolong their skin survival.<sup>60</sup>

But, preceding neutrophil skin infiltration, drug specific CD4+ T cells (with less than 30% CD8+), expressing CCR6 as the skin homing receptor, are present in the skin and exert some cytotoxicity in the epidermis<sup>5</sup> before they secrete

**AQ7**



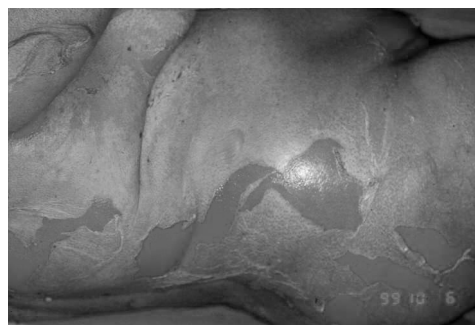**FIGURE 27.4** (a) Acute generalized exanthematous pustulosis induced by amoxicillin. (b) Detail of Figure 27.4a. Small pustules mainly on body folds in AGEP.

CXCL8 that recruits neutrophils. As both T cells and keratinocytes secrete CXCL8 and T cells also express the CXCR1, there is further T-cell activation by CXCL8 produced by keratinocytes.<sup>61</sup> Opposing MPE, there is a much lower expression of HLA-II by keratinocytes and no exotoxin was observed in the epidermis, but only along endothelial cells.<sup>61</sup>

This very peculiar pattern of drug specific T-cell reaction, now considered a type IVd hypersensitivity reaction,<sup>5</sup> develops with drugs that usually induce other type IV reactions, namely aminopenicillins. No reason has, thus far, been found to justify why in some patients and in what circumstances a drug can elicit this particularly CXCL8 rich Tcell activity.

#### 27.4.4 STEVENS–JOHNSON SYNDROME/ TOXIC EPIDERMAL NECROLYSIS

SJS and its more extensive variant, TEN, represent a life-threatening pattern of CADR characterized by widespread symmetrically distributed macular lesions, showing typical or mainly atypical targets, with central bulla, that coalesce to form large sheets of necrotic epidermis covering more than 30% of the body surface area in TEN (Figure 27.5 represent a case of TEN from allopurinol, with skin detachment involving about 60% of the body surface area). The eruption is often preceded by fever, malaise, mucosal pain/erosions and, as the skin rash progresses from the head to the extremities, fever and systemic symptoms occur in a variable intensity and combination. Conjunctivae, oral, and genital epithelial shedding is usually intense and painful, and can be associated with epithelial necrosis of the oropharynx, gastrointestinal tract, trachea, and bronchia. SJS/TEN are due to drugs in more than 90% of cases, usually an antibiotic (sulfonamide), allopurinol, an anticonvulsant (lamotrigine, carbamazepine), or a NSAID (oxicam).<sup>1,4</sup> In the skin there is a variable degree of inflammatory infiltrate, ranging from almost absent to a dense dermal T infiltrate, which seems to correlate positively with the percentage of the area of skin detachment and, consequently, with the mortality rate.<sup>65,66</sup> Factor XIIIa+ dermal dendritic cells are increased contrasting with a reduction of CD1a+ Langerhans cells. CD4+ and CD8+ T cells are scattered in the dermis and many cytotoxic activated CD8+CD56+ T cells are found in the blister fluid.<sup>67,68</sup> But the most striking histologic marker of TEN is the keratinocyte cell death extending to all epidermal layers.<sup>65</sup> There is evidence that this is due to apoptosis, dependent on several mechanisms. The Fas/Fas ligand (CD95/CD95L) pathway, in its membrane bound or soluble form, seems to be mainly involved, but there are other pathways leading to keratinocyte apoptosis, namely TNF- $\alpha$ , granzyme B, and perforin and calcium dependent calprotectin.<sup>69–71</sup> These soluble mediators are found in high amounts in the serum but very particularly in the blister fluid, where they are detected with other cytokines that may be liberated by damaged keratinocytes and which amplify the inflammatory loop and the epidermal apoptosis, namely IL-18, IFN- $\gamma$ , and IL-10.<sup>71</sup>



**FIGURE 27.5** Extensive skin detachment in a patient with toxic epidermal necrolysis from allopurinol.

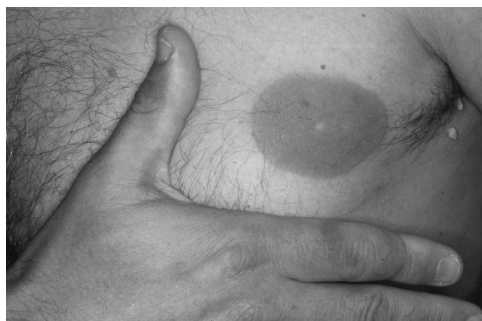The main origin of these death mediators are drug specific T cells, mainly CD8+, present in the blister fluid of patients with TEN.<sup>67,68</sup> These CD8+CD56+ T cells have an important cytotoxic potential against HLA-I restricted keratinocytes combined with the culprit drug, mainly due to granzyme B and perforin,<sup>16,68</sup> but also through soluble FAS produced in high amounts after drug stimulation of these cells.<sup>70</sup> Therefore, after a first aggression by CD8+ cytotoxic T cells that need cell contact or proximity, other soluble mediators secreted by drug specific T cells (IFN- $\gamma$ , sFAS) can be important for disease spreading. IFN- $\gamma$  activates keratinocytes that increase HLA-I expression, rendering them more susceptible to CD8+ specific T-cell killing,<sup>16</sup> upregulates their secretion of CCL27/CTACK, a potent chemokine that further attracts CCR10+ cutaneous memory T cells,<sup>53</sup> and increases their expression of receptors for TNF and Fas and their production of Fas ligand, making keratinocytes more susceptible to apoptosis and capable of inducing apoptosis of neighboring cells.<sup>16</sup>

The factors that drive the CADR into a SJS or TEN are not known. TEN inducing drugs are not different from those that induce other CADR, and sometimes at the beginning the skin reaction simulates a MPE. Nevertheless, increased serum levels of soluble Fas may indicate the progression to a more severe life-threatening reaction,<sup>70</sup> and some authors suggest that, in individuals who develop SJS or TEN, their lymphocytes have an increased capacity of secreting sFas, even in basal conditions.<sup>22</sup> Therefore, this and other genetic susceptibility markers can be of importance in determining this pattern of CADR.

#### 27.4.5 FIXED DRUG ERUPTION

FDE is due to drug hypersensitivity in more than 95% of the cases. The clinical presentation is very typical, with round erythematous lesions, that may progress to plaques or bulla and regress spontaneously within 10–15 days with a grey-brown hyperpigmentation (Figure 27.6 shows two typical round lesions of FDE induced by piroxicam). Lesions may vary from a few to a widespread involvement making a differential diagnosis with TEN difficult.<sup>19,72</sup>

At the acute phase there is a mononuclear inflammatory infiltrate, mainly at the dermal epidermal junction, with



**FIGURE 27.6** Typical round erythematous-violaceous lesions in fixed drug eruption from piroxicam.

hydropic degeneration of basal keratinocytes and scattered or more extensive apoptosis of keratinocytes, eventually involving the whole epidermal thickness, as in TEN. Upon regression, melanophages are easily visible in the dermis for years and, if special immunohistochemical stains are performed, CD8+ T cells can also be detected in the epidermis in abnormal numbers over prolonged periods after clinical resolution,<sup>74</sup> probably due to the expression of the skin homing receptor (CLA+) and the integrin  $\alpha 3\beta 7$  (CD103), which binds E-cadherin in keratinocytes.<sup>73,75</sup> They are CD3+, CD45RA+, CD11b+, and CD8+ effector memory T cells that share some surface and activation markers with NK cells, namely the CD69,<sup>73,75</sup> but they do not harm the neighboring cells, which are protected from apoptosis.<sup>74</sup> Within a few hours upon exposure to the culprit drug these resting or “pre-activated” T cells initiate a process of epidermal aggression. They upregulate mRNA for IFN- $\gamma$  and secrete this cytokine in high amounts;<sup>73,74</sup> they express FAS-ligand which binds FAS on keratinocytes, thus, inducing apoptosis;<sup>73–75</sup> TNF- $\alpha$ , perforin, and granzyme secreted by these cells and other CD8+ effector T cells recruited from the circulation also participate in the epidermal aggression.<sup>73,74</sup> Along with CD8+, which migrate mainly to the epidermis and CD4+ which localize preferentially in the dermis and among this subgroup, CD4+CD25+hi regulatory T cells seem to down-regulate the reaction either by direct cell contact or by secretion of IL-10 or TGF- $\beta$ .<sup>76</sup> These cells also seem to be involved in the process of desensitization in FDE.<sup>77</sup>

The presence of the “pre-activated” T cells in the residual lesional epidermis can explain why patch testing is negative in normal skin whereas, a few hours after application of the culprit drug in a residual lesion reactivation occurs with the clinical and histopathology typical of a FDE.<sup>19,72</sup> Although some authors suggest that these lesions can be reactivated by nonspecific stress/danger signals,<sup>74,78</sup> in our experience lesional reactivation by patch testing is drug specific and allows the confirmation of the culprit drug and study of cross reactions.<sup>19,79</sup>

#### 27.5 CONCLUDING REMARKS

The knowledge of the pathomechanisms involved in drug hypersensitivity are of extreme importance for the clinician to understand the clinical and evolutive pattern of CADR, to choose the most adequate therapeutic attitude when facing a CADR, to understand and determine which drug is imputed with the highest probability in patients on multiple therapies, to further choose the most adequate complementary tools to confirm the culprit drug (immediate skin tests and IgE/basophil activation tests in immediate reactions, patch testing, or IDR with late readings and LTT in delayed reactions), and to take the most adequate preventive measures to avoid a further CADR.

Nevertheless several aspects of these mechanisms are not yet fully understood, namely what triggers sensitization to the drug, which drug epitopes (or other related epitopes) are recognized by the immune system so that cross reactions are



better understood and patients are better informed on drugs to avoid in the future, how lesions fully develop and how we can interfere in their progression, at least in the most severe reactions like SJS and TEN for which no definitive therapy exists to stop their evolution and decrease mortality.

Also, the study of hypersensitivity mechanisms induced by drugs, where oral rechallenge or patch testing has been a complementary tool to understand more pieces of this complex puzzle, contributed to the understanding of pathomechanisms involved in nondrug related skin diseases. The discovery of CXCL8+ producing T-cell clones in AGEP has stimulated the study of their contribution in other neutrophil rich inflammatory skin diseases, like psoriasis, Sweet's syndrome and Beçhet's disease, and have given immunologists the suggestion to consider a new type IV hypersensitivity reaction (IVd).<sup>5,60</sup>

## REFERENCES

- Roujeau, J.C., Clinical heterogeneity of drug hypersensitivity, *Toxicology*, 209, 123, 2005.
- Bigby, M., Rates of cutaneous reactions to drugs, *Arch. Dermatol.*, 137, 765, 2001.
- Fernandes, B. et al., Farmacovigilância no serviço de dermatologia dos HUC no ano de 1998 – estudo comparativo com 1988, *Trab. Soc. Port. Dermatol. Venereol.*, 58, 335, 2000.
- Friedmann, P.S. et al., Mechanisms in cutaneous drug hypersensitivity, *Clin. Exp. Allergy*, 33, 861, 2003.
- Lerch, M., and Pichler, W.J., The immunological and clinical spectrum of delayed drug-induced exanthems, *Curr. Opin. Allergy Clin. Immunol.*, 4, 411, 2004.
- Bruynzeel, D., and Gonçalo, M., Patch testing in adverse drug reactions, in *Contact Dermatitis*, 4th ed., Frosch, P., Menné, T., and Lepoittevin, J.-P., Eds., Springer-Verlag, Berlin Heidelberg, 2006, chap. 24.
- Marques, C. et al., Allergic contact and systemic contact dermatitis from cinchocaine, *Contact Dermatitis*, 33, 443, 1995.
- Bruynzeel, D.P., and Maibach, H.I., Patch testing in systemic drug eruptions, *Clin. Dermatol.*, 15, 479, 1997.
- Hausermann, P., Harr, T., and Bircher, A.J., Baboon syndrome resulting from systemic drugs: is there strife between SDRIFE and allergic contact dermatitis syndrome? *Contact Dermatitis*, 51, 297, 2004.
- Gonçalo, M., Exploration dans les photo-allergies médicamenteuses, in *Progrès en Dermato-allergologie Tome IV*, G.E.R.D.A., Eds., John Libbey Eurotext, Nancy, 1998, chap. 8.
- Gonçalo, M. et al., Photosensitivity to piroxicam: absence of cross reaction with tenoxicam, *Contact Dermatitis*, 27, 287, 1992.
- Coelho, S. et al., Vancomycin-associated linear IgA bullous dermatosis mimicking toxic epidermal necrolysis, *Int. J. Dermatol.*, 45, 995, 2006.
- Yun, S.J. et al., Drug rash with eosinophilia and systemic symptoms induced by valproate and carbamazepine: formation of circulating autoantibodies against 190-kDa antigen, *Acta Derm. Venereol.*, 86, 241, 2006.
- Pichler, W.J., Pharmacological interaction of drugs with antigen-specific immune receptors: the p-i concept, *Curr. Opin. Allergy Clin. Immunol.*, 2, 301, 2002.
- Naisbitt, D.J., Drug hypersensitivity reactions in the skin: understanding mechanisms and the development of diagnostic and predictive tests, *Toxicology*, 194, 179, 2004.
- Nassif, A. et al., Toxic epidermal necrolysis: effector cells are drug specific cytotoxic T cells, *J. Allergy Clin. Immunol.*, 114, 1209, 2004.
- Blanca, M. et al., Specificities of B cell reactions to drugs. The penicillin model, *Toxicology*, 209, 181, 2005.
- Romano, A. et al., Cross-reactivity among drugs: clinical problems, *Toxicology*, 209, 169, 2005.
- Oliveira, H.S. et al., Fixed drug eruption to piroxicam. Positive patch tests with cross-sensitivity to tenoxicam, *J. Dermatol. Treat.*, 10, 209, 1999.
- Park, B.K. et al., Metabolic activation in drug allergies, *Toxicology*, 158, 11, 2001.
- Young Lee, A. et al., Genetic polymorphism of cytochrome P<sub>450</sub> in diphenylhydantoin-induced cutaneous adverse drug reactions, *Eur. J. Clin. Pharmacol.*, 60, 155, 2004.
- Lan, C.E. et al., Diagnostic role of soluble Fas ligand secretion by peripheral blood mononuclear cells from patients with previous drug-induced blistering disease: a pilot study, *Acta Dermatol. Venereol.*, 86, 215, 2006.
- Mastalerz, L. et al., Familial aggregation of aspirin-induced urticaria and leukotriene C4 synthase allelic variant, *Br. J. Dermatol.*, 154, 256, 2005.
- Pichler, W.J., Delayed drug hypersensitivity reactions, *Ann. Intern. Med.*, 139, 683, 2003.
- Dakdouki, G.K. et al., Azithromycin-induced rash in infectious mononucleosis, *Scand. J. Infect. Dis.*, 34, 939, 2002.
- Carlson, J.A., et al., Adverse antibiotic-induced eruptions associated with Epstein Barr Virus infection and showing Kikuchi-Fujimoto disease-like histology, *Am. J. Dermatopathol.*, 28, 48, 2006.
- Renn, C.N. et al., Amoxicillin-induced exanthema in young adults with infectious mononucleosis: demonstration of drug-specific lymphocyte reactivity, *Brit. J. Dermatol.*, 147, 1166, 2002.
- Debarbieux, S. et al., Syndrome d'hypersensibilité médicamenteuse associé à primo-infection HHV6, *Ann. Dermatol. Venereol.*, 133, 145, 2006.
- Kano, I., Inaoka, M., and Shiohara, T., Association between anticonvulsivant hypersensitivity syndrome and human herpes virus 6 reactivation and hypogammaglobulinemia, *Arch. Dermatol.*, 140, 183, 2004.
- Pérez, A. et al., Erythema-multiforme-like eruption from amoxicillin and allopurinol, *Contact Dermatitis*, 44, 113, 2001.
- Demoly, P., Anaphylactic reactions—value of skin and provocation tests, *Toxicology*, 209, 221, 2005.
- Kasperska-Zajac, A., and Rogala, B., Platelet function in anaphylaxis, *J. Investig. Allergol. Clin. Immunol.*, 16, 1, 2006.
- Kleine-Tebbe, J. et al., Diagnostic tests based on human basophils: potentials, pitfalls and perspectives, *Int. Arch. Allergy Immunol.*, 141, 79, 2006.
- Kvedariene, V. et al., Diagnosis of neuromuscular blocking agent hypersensitivity reactions using cytofluorimetric analysis of basophils, *Allergy*, 61, 311, 2006.
- Brockow, K., Contrast media hypersensitivity—scope of the problem, *Toxicology*, 209, 189, 2005.
- Bircher, A.J., Drug-induced urticaria and angioedema caused by non-IgE mediated pathomechanisms, *Eur. J. Dermatol.*, 9, 657, 1999.
- Gamboa, P. et al., The flow-cytometric determination of basophil activation induced by non-steroidal anti-inflammatory drugs (NSAIDs) is useful for in vitro diagnosis of the NSAID hypersensitivity syndrome, *Clin. Exp. Allergy*, 34, 1448, 2004.

AQ8

38. Laroche, D., Immediate reactions to contrast media: mediator release and value of diagnostic testing, *Toxicology*, 209, 193, 2005.
39. Grattan, C.E.H., Aspirin sensitivity and urticaria, *Clin. Experim. Dermatol.*, 28, 123, 2003.
40. Mathelier-Fusade, P., Urticaires chroniques d'origine medicamenteuse, *Ann. Dermatol. Venereol.*, 130, 1531, 2003.
41. Yawalkar, N. et al., T cells isolated from positive epicutaneous test reactions to amoxicillin and ceftriaxone are drug specific and cytotoxic, *J. Invest. Dermatol.*, 115, 647, 2000.
42. Lammintausta, K., and Kortekangas-Savolainen, O., Oral challenge in patients with suspected cutaneous adverse drug reactions: findings in 784 patients during a 25-year period, *Acta Dermatol. Venereol.*, 85, 491, 2005.
43. Barbaud, A. et al., Guidelines for performing skin tests with drugs in the investigation of cutaneous adverse drug reactions, *Contact Dermatitis*, 45, 321, 2001.
44. Lammintausta, K., and Kortekangas-Savolainen, O., The usefulness of skin tests to prove drug hypersensitivity, *Br. J. Dermatol.*, 152, 968, 2005.
45. Torres, M.-J. et al., Skin test evaluation in nonimmediate allergic reactions to penicillins, *Allergy*, 59, 219, 2004.
46. Barbaud, A., Drug patch testing in systemic cutaneous drug allergy, *Toxicology*, 209, 209, 2005.
47. Hari, Y. et al., T cell involvement in cutaneous drug eruptions, *Clin. Experim. Allergy*, 31, 1398, 2001.
48. Merck, H.F., Diagnosis of drug hypersensitivity: lymphocyte transformation test and cytokines, *Toxicology*, 209, 217, 2005.
49. Kuechler, P.C. et al., Cytotoxic mechanisms in different forms of T-cell-mediated drug allergies, *Allergy*, 59, 613, 2004.
50. Meth, M.J., and Sperber, K.E., Phenotypic diversity in delayed drug hypersensitivity: an immunologic explanation, *Mt. Sinai J. Med.*, 73, 769, 2006.
51. Yawalkar, N., Drug-induced exanthems, *Toxicology*, 209, 131, 2005.
52. Brönnimann, M., and Yawalkar, N., Histopathology of drug-induced exanthems: is there a role in diagnosis of drug allergy? *Curr. Opin. Allergy Clin. Immunol.*, 5, 317, 2005.
53. Tapia, B. et al., Involvement of CCL27-CCR10 interactions in drug induced cutaneous reactions, *J. Allergy Clin. Immunol.*, 114, 335, 2004.
54. Wong, G.A.E., and Shear, N., Is a drug alone sufficient to cause the drug hypersensitivity syndrome? *Arch. Dermatol.*, 140, 226, 2004.
55. Poszeczynska-Guiné, E., Revuz, J., and Roujeau, J.C., Mécanismes immunologiques des réactions cutanées aux médicaments, *Ann. Dermatol. Venereol.*, 131, 177, 2004.
56. Choquet-Kastylevsky, G. et al., Increased levels of interleukin 5 are associated with the generation of eosinophilia in drug-induced hypersensitivity syndrome, *Br. J. Dermatol.*, 139, 1026, 1998.
57. Gonçalves, M., Coelho, S., and Figueiredo, A., Ascertaining patch test concentration in cutaneous adverse drug reactions to aminopenicillins and carbamazepine, *J. Invest. Dermatol.*, 126, S67, 2006.
58. Asano, Y., Kano, Y., and Shiohara, T., Drug induced hypersensitivity syndrome is a manifestation of newly observed immune reconstitution inflammatory syndrome. *J. Invest. Dermatol.*, 126, S95, 2006.
59. Girardi, M. et al., Cross-comparison of patch test and lymphocyte proliferation responses in patients with a history of acute generalized exanthematous pustulosis, *Am. J. Dermatopathol.*, 27, 343, 2005.
60. Schaerli, P. et al., Characterization of human T cells that regulate neutrophilic inflammation, *J. Immunol.*, 173, 2151, 2004.
61. Britschgi, M. et al., T-cell involvement in drug-induced acute generalized exanthematous pustulosis, *J. Clin. Invest.*, 107, 1433, 2001.
62. Sidoroff, A. et al., Acute generalized exanthematous pustulosis (AGEP) – a clinical reaction pattern, *J. Clin. Pathol.*, 28, 113, 2001.
63. Britschgi, M., and Pichler, W.J., Acute generalized exanthematous pustulosis. Role of cytotoxic T cells in pustule formation a clue to neutrophil-mediated processes orchestrated by T cells, *Curr. Opin. Allergy Clin. Immunol.*, 2, 325, 2002.
64. Schmid, S. et al., Acute generalized exanthematous pustulosis. Role of cytotoxic T cells in pustule formation, *Am. J. Pathol.*, 161, 2079, 2002.
65. Quinn, A.M. et al., Uncovering histologic criteria with prognostic significance in toxic epidermal necrolysis, *Arch. Dermatol.*, 141, 683, 2005.
66. Faye, O., Wechsler, J., and Roujeau, J.-C., Cell-mediated immunologic mechanism and severity of TEN, *Arch. Dermatol.*, 141, 775, 2005.
67. Correia, O. et al., Cutaneous T-cell recruitment in toxic epidermal necrolysis. Further evidence of CD8+ lymphocyte involvement, *Arch. Dermatol.*, 129, 466, 1993.
68. Nassif, A. et al., Drug specific cytotoxic T-cells in the skin lesions of a patient with toxic epidermal necrolysis, *J. Invest. Dermatol.*, 118, 728, 2002.
69. Paquet, P., and Piérard, G.E., Keratinocyte injury in drug-induced epidermal necrolysis: simultaneous but distinct topographic expression of CD95R and calprotectin, *Int. J. Molecular Med.*, 10, 15, 2002.
70. Abe, R. et al., Toxic epidermal necrolysis and Stevens-Johnson syndrome are induced by soluble Fas ligand, *Am. J. Pathol.*, 162, 1515, 2003.
71. Nassif, A. et al., Evaluation of the potential role of cytokines in toxic epidermal necrolysis, *J. Invest. Dermatol.*, 123, 850, 2004.
72. Gonçalves, M. et al., Topical provocation in fixed drug eruption from nonsteroidal anti-inflammatory drugs, *Exogenous Dermatol.*, 1, 81, 2002.
73. Mizukawa, Y. et al., Direct evidence for interferon-gamma production by effector-memory-type intraepidermal T cells residing at an effector site of immunopathology in fixed drug eruption, *Am. J. Pathol.*, 161, 1337, 2002.
74. Shiohara, T., Mizukawa, Y., and Teraki, Y., Pathophysiology of fixed drug eruption: the role of skin-resident T cells, *Curr. Opin. Allergy Clin. Immunol.*, 2, 317, 2002.
75. Choi, H.J. et al., Possible role of Fas/Fas ligand mediated apoptosis in the pathogenesis of fixed drug eruption, *Br. J. Dermatol.*, 154, 419, 2006.
76. Teraki, Y., and Shiohara, T., IFN- $\gamma$ -producing effector CD8 T cells and IL-10-producing regulatory CD4+ T cells in fixed drug eruption, *J. Allergy Clin. Immunol.*, 112, 609, 2003.
77. Teraki, Y., and Shiohara, T., Successful desensitization to fixed drug eruption: the presence of CD25+CD4+ T cells in the epidermis of fixed drug eruption lesions may be involved in the induction of desensitization, *Dermatology*, 209, 29, 2004.
78. Shiohara, T., and Mizukawa, Y., The immunological basis of lichenoid tissue reaction, *Autoimmunity Rev.*, 4, 236, 2005.
79. Cravo, M., Gonçalves, M., and Figueiredo, A., Fixed drug eruption to cetirizine with positive lesional patch tests to the three piperazine derivatives, *Int. J. Dermatol.*, 45, 2006 (in press).

AQ9

AQ10

## QUERY FORM

### Taylor and Francis

### Marzulli and Maibach`s Dermatotoxicology, 7th Edition

JOURNAL TITLE:	9773
ARTICLE NO:	CH027

#### ***Queries and / or remarks***

Query No.	Details Required	Author's Response
AQ1	Please check if the edit made in the sentence “ Some CADR...lichen plannus” is ok.	
AQ2	Is the abbreviation UVA well known? If not, please expand at its first occurrence.	
AQ3	Is this abbreviation well known? If not, please expand at its first occurrence.	
AQ4	Please check if the edit made in the sentence “One important...culprit metabolite” is ok.	
AQ5	Please check if the edit made in the sentence “ Nevertheless...reaction pattern” is ok.	
AQ6	Please check if the edit made in the sentence “Similar cells...chemokines” is ok.	
AQ7	Is the abbreviation GM-CSF well known? If not, please expand it in its first occurrence.	
AQ8	Please provide the names of the editor with their initials for Goncalo, 1998 in reference 10.	
AQ9	Please provide the citation for Girardi et al., 2005 in the text.	
AQ10	Please provide the page range of Cravo et al., 2006 if available.	