

# HOW DO I DO IT





## PTERIONAL CRANIOTOMY FOR ANTERIOR CIRCULATION ANEURYSMS

EANS COURSE  
OPATIJA, SEPT 2009

MARCOS BARBOSA

Serviço de Neurocirurgia

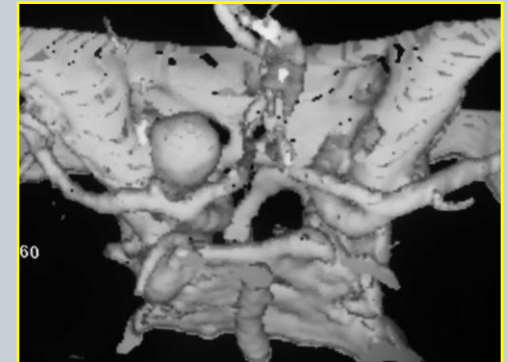
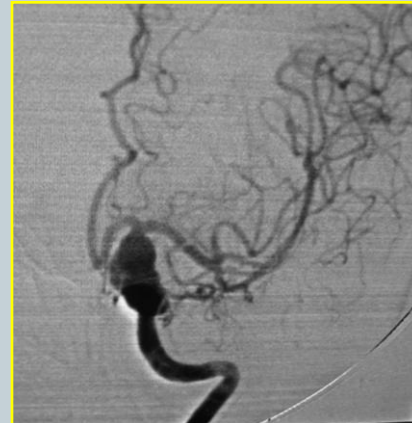
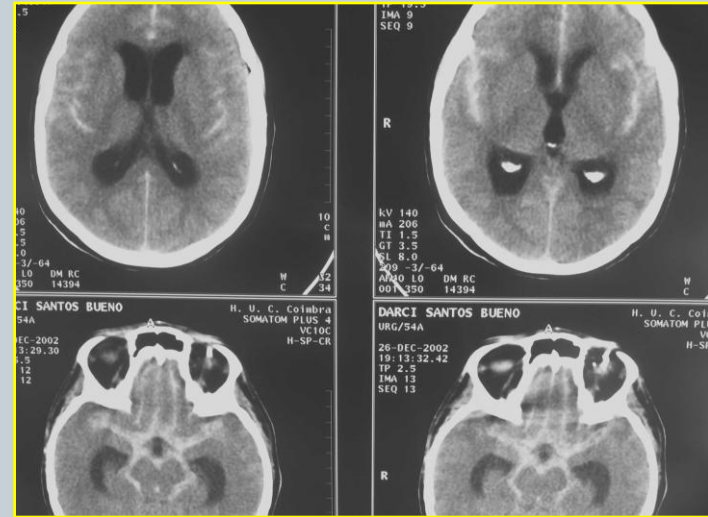
HOSPITAIS DA UNIVERSIDADE DE COIMBRA  
PORTUGAL



# pterional craniotomy



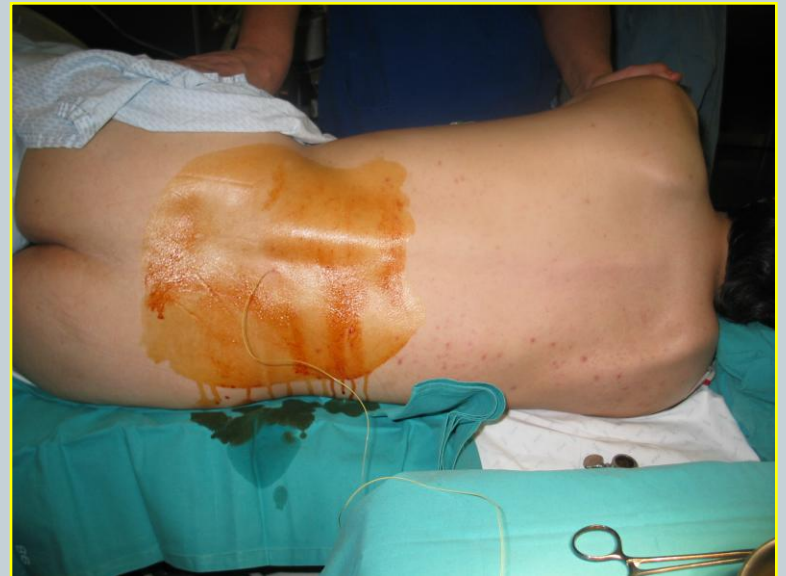- Patient evaluation
- Imaging evaluation
- Timing of surgery
- Craniotomy



# pterional craniotomy



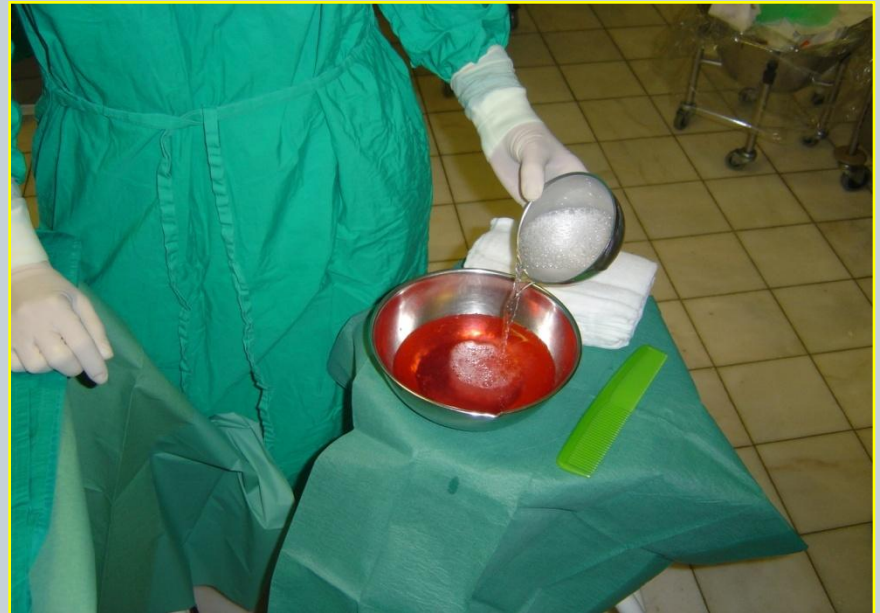- Surgery planning
- Difficulties anticipation
- CT scan
- Angio (angio CT)



# pterional craniotomy



- Shaving
- Side of approach

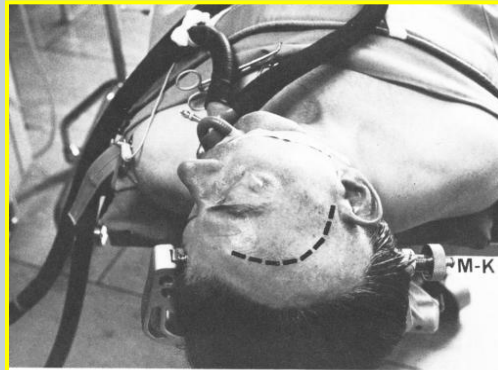

4% Chlorexidine + double distilled water (50%)

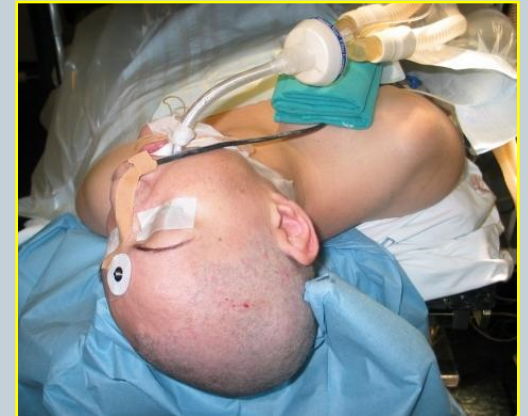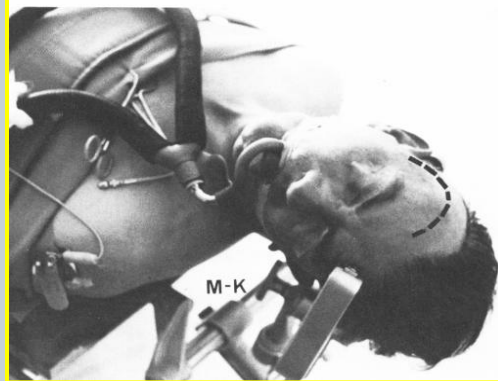
# pterional craniotomy



- Head fixing



- Head positioning



# pterional craniotomy



- ACOm - small deflection and rotation
- MC - maximal deflection, minimal or no rotation
- IC/PCOm - minimal deflection, rotation depends on fundus orientation

# pterional craniotomy



- Draping
- Incision line
- Skin infiltration
- Interfascial or miocutaneous
- Adequate bone removal
- CSF removal
- Cisterns dissection
- Lesion identification

