

- 4 Simonart T, Noel JC, Van Vooren JP, *et al.* Role of viral agents in the pathogenesis of Kaposi's sarcoma. *Dermatology* 1998; **196**: 447–449.
- 5 Guttman-Yassky E, Cohen A, Kra-Oz Z, *et al.* Familial clustering of classic Kaposi's sarcoma. *J Infect Dis* 2004; **189**: 2023–2026.
- 6 Monti M, Mancini LL, Ceriani R, *et al.* Iatrogenic Kaposi's

- sarcoma and HCV infection. *J Eur Acad Dermatol Venereol* 2004; **18**: 191–193.
- 7 Montella M, Serraino D, Crispo A, *et al.* Infection with human herpes virus type 8 in an area at high prevalence for hepatitis C virus infection in southern Italy. *J Viral Hepat* 2004; **11**: 268–270.

Vancomycin-associated linear IgA bullous dermatosis mimicking toxic epidermal necrolysis

Dear Sir,

Linear IgA bullous dermatosis (LABD) is an auto-immune vesiculobullous disease with an often misleading clinical picture. Although most reported cases are idiopathic, drug-induced disease may rarely occur. Both forms of LABD have indistinguishable clinical, histological, and immunofluorescence features. The clinical presentation is heterogeneous and can resemble dermatitis herpetiformis, bullous pemphigoid, cicatricial pemphigoid, pemphigus vulgaris, erythema multiforme, lichen planus, and rarely toxic epidermal necrolysis (TEN). Identification of linear IgA deposition at the basement membrane zone on direct immunofluorescence is essential to diagnosis. We describe an exuberant case of LABD to Vancomycin presenting as TEN.

Case report

A 67-year-old woman was transferred to our department because of a bullous dermatosis of 3 days' evolution. The patient had been hospitalized in another hospital for 2 weeks owing to pneumonia and received a 10-day course of vancomycin, subsequently substituted for meropenem. Cutaneous lesions started abruptly 3 days after stopping vancomycin, presenting as tense bullae with a symmetric distribution on the arms, hands (Fig. 1), breasts, back, lower legs, buttocks, and perineum. Most of the bullae had a surrounding erythema, and on the trunk were associated with annular maculo-papules. There was no mucous or ocular involvement. The patient complained of a burning sensation and denied pruritus. During the following 72 h extensive erosions progressed (Fig. 2) with a positive Nikolsky sign obtained at their periphery. The patient was on chronic prednisolone (30 mg/day) owing to rheumatoid arthritis, and besides being blind had no other relevant medical antecedents. We diagnosed TEN. The patient was in good general condition and the relevant laboratorial changes were leucocytosis (19.5 g/L) with 93% neutrophils and anemia (8.3 g/dL). Oral prednisolone and meropenem were maintained and endovenous methylprednisolone (500 mg) was administered. On the next day the patient had maintained a good general condition although new lesions had occurred and there was progression of erosions covering 40% of body surface. Microscopic examination of the frozen section of a blister roof showed a normal epidermis. Toxic epidermal

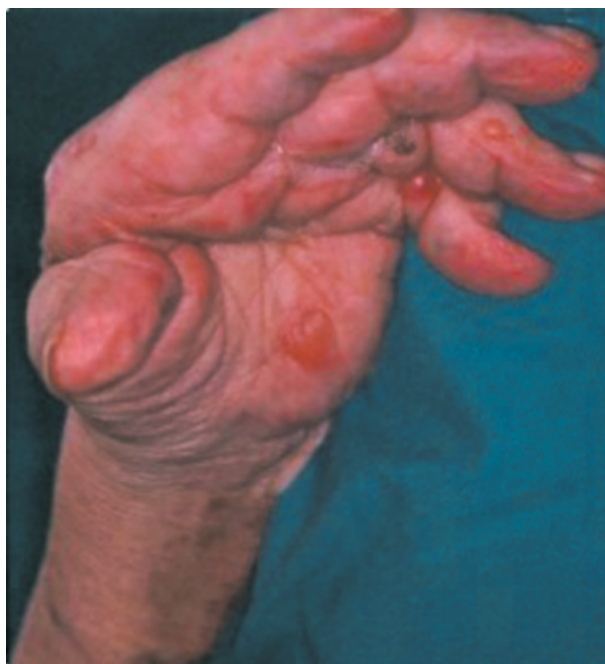

Figure 1 Hand with tense bullae within erythematous plaques

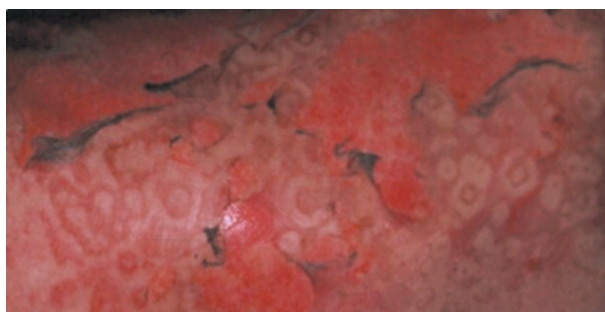


Figure 2 Back showing annular maculo-papules and major exfoliation leaving areas of denuded skin

necrolysis was therefore excluded and linear IgA bullous dermatosis to vancomycin seemed the probable diagnosis. This was confirmed by direct immunofluorescence (DIF) on perilesional skin, which revealed a linear IgA deposition at the basement membrane zone. Histology of the lesional skin exposed a subepidermal blister with a superficial dermal inflammatory infiltrate composed of polymorphonuclear

neutrophils, mononuclear cells, and some interspersed eosinophils. Prednisolone was maintained at the same dosage and topical betametasone was initiated. Five days after beginning the dermatosis no new lesions had developed and the eruption had completely resolved in 2 weeks without scarring. Meropenem was suspended on the ninth day of dermatosis owing to the favorable pulmonary evolution.

Discussion

The interest of this case report is the unusual clinical presentation suggesting TEN. Although vancomycin is the most frequently involved agent in drug-induced LABD, this form of presentation has been rarely reported.¹⁻⁴ A similar case was described with phenytoin,⁵ and there are a few reports of idiopathic LABD mimicking Stevens-Johnson syndrome⁶ and TEN.^{7,8} When the later is suspected the microscopic examination of the frozen section of a blister roof is helpful to confirm full-thickness epidermal necrosis. On drug-induced disease, if the suspected agent is interrupted a spontaneous remission of lesions is noticed and IgA deposits will also disappear. This evolution is not observed in the idiopathic form.

Polymorphous clinical and immunopathologic features of this dermatosis can be partially explained by the different target antigens identified on Western blotting, namely collagen type VII⁹ and antigens of 97 kDa and 230 kDa.¹⁰

This case demonstrates the benignity of drug-induced LABD, even in cases presenting as a severe bullous eruption.

Sónia Coelho, MD

Oscar Tellechea, MD, PhD

José Pedro Reis, MD

Angelina Mariano, MD

Américo Figueiredo, MD, PhD

University Hospital, Coimbra, Portugal

Cutaneous small vessel vasculitis and pulmonary tuberculosis: an unusual association

Cutaneous small vessel vasculitis (CSVV) may present as "palpable" purpura, erythema, urticaria, bullae, or skin infraction leading to ulceration. Causative factors vary.¹ Mycobacterium tuberculosis is a rather uncommon etiologic agent for CSVV. Our case report deals with the infrequent coexistence of pulmonary tuberculosis (PT) and CSVV.²

A 39-year-old Greek man presented to our hospital with a 3-month history of an eruption located mainly on the legs, which began with the appearance of erythema progressing to sparse palpable purpuric macules. Medical history revealed a low-grade fever, a slight nonproductive cough and a weight loss of 5–8 kg over the last 5 months. There was non-associated medication use. Initial investigations showed an erythrocyte sedimentation rate of 68 mm/h and a white cell count of 12,650-cells/mL. Blood chemistries and urine anal-

References

- 1 Mofid MZ, Costaragos C, Bernstein B, *et al.* Drug-induced linear immunoglobulin A bullous disease that clinically mimics toxic epidermal necrolysis. *J Burn Care Rehabil* 2000; 21: 246–247.
- 2 Hughes AP, Callen JP. Drug-induced linear IgA bullous dermatosis mimicking toxic epidermal necrolysis. *Dermatology* 2001; 202: 138–139.
- 3 Dellavalle RP, Burch JM, Tayal S, *et al.* Vancomycin-associated linear IgA bullous dermatosis mimicking toxic epidermal necrolysis. *J Am Acad Dermatol* 2003; 48: S56–S57.
- 4 Waldman MA, Black DR, Callen JP. Vancomycin-induced linear IgA bullous disease presenting as toxic epidermal necrolysis. *Clin Exp Dermatol* 2004; 29: 633–636.
- 5 Tran D, Kossard S, Shumack S. Phenytoin-induced linear IgA dermatosis mimicking toxic epidermal necrolysis. *Australas J Dermatol* 2003; 44: 284–286.
- 6 Schneck B, Termeer C, Mockenhaupt M, *et al.* Linear IgA dermatosis in an adult with clinical signs of Stevens-Johnson syndrome. *Hautarzt* 1999; 50: 288–291.
- 7 Abreu A, Bowers K, Mattson DH, *et al.* Linear IgA bullous dermatosis in association with multiple sclerosis. *J Am Acad Dermatol* 1994; 31: 797–799.
- 8 Buchvald J, Filo V, Horvathova J. IgA-linear dermatosis imitating Lyell syndrome. *Bratisl Lek Listy* 1987; 88: 211–217.
- 9 Wakelin SH, Allen J, Zhou S, *et al.* Drug-induced linear IgA disease with antibodies to collagen VII. *Br J Dermatol* 1998; 138: 310–314.
- 10 Paul C, Wolkenstein P, Prost C, *et al.* Drug induced linear IgA disease: Target antigens are heterogeneous. *Br J Dermatol* 1997; 136: 406–411.

ysis were normal. Antinuclear antibodies, anti-DNA, anti-Sm, anti-Ro, anti-La, anticardiolipin, lupus anticoagulant, cytoplasmic, and perinuclear antineutrophil antibodies were all negative. C-reactive protein, cryoglobulins, and complement levels were found within normal ranges. Immunoglobulins fraction revealed a slight elevation of IgG and IgA. The viral serology was negative for hepatitis B, C, and acquired human immunodeficiency virus. Chest X-rays showed calcificated lymph nodes and a few confluent opacities in the upper pulmonary segments. The skin purified protein derivative (PPD) test was positive (indurations of 14 mm) and the Ziehl–Nielsen staining of the sputum was positive for acid-fast bacilli. Sputum culture eventually grew *Mycobacterium tuberculosis*. Skin biopsy from a recent purpuric lesion showed perivascular polymorphonuclear infiltration in the upper dermis with extravasation of erythrocytes, fibrinoid necrosis of dermal vessels and presence of

This document is a scanned copy of a printed document. No warranty is given about the accuracy of the copy. Users should refer to the original published version of the material.