

## CASE REPORT

# Adenocarcinoma arising in adenomyosis: report of an unusual case

DANIELA COUTO<sup>1</sup>, FERNANDO MOTA<sup>1</sup>, TERESA SILVA<sup>2</sup> AND CARLOS DE OLIVEIRA<sup>1</sup>

From the Departments of <sup>1</sup>Gynecology, and <sup>2</sup>Pathology, University Hospital of Coimbra, Coimbra Codex, Portugal

*Acta Obstet Gynecol Scand* 2004; 83: 406–408. © Acta Obstet Gynecol Scand 83 2004

**Keywords:** adenomyosis, endometrial adenocarcinoma

Submitted 29 July, 2002

Accepted 21 October, 2002

Endometrial adenocarcinoma and adenomyosis are both common pathologic conditions that develop in the uterus.

Adenocarcinoma arising from adenomyosis is rare but has been described, with similar alterations in the endometrium. Furthermore, there have been a few reports of adenocarcinoma developing in adenomyotic areas without endometrial involvement (1–11).

We report a case of endometrial adenocarcinoma arising in a focus of adenomyosis localized in the outer half of the myometrium, with no involvement of the surface of the endometrium.

## Case report

OFBGB, a 62-year-old, nulliparous, white woman, presented with postmenopausal bleeding for 2 years with no other complaints.

Menarche at the age of 11 years. Menopause at the age of 53 years. She had been on antidiabetic and antihypertensive drugs for several years. She was an obese woman with a body mass index of 34.2. Dilatation and curettage (D & C) was performed, revealing endometrial hyperplasia with atypia. The serum level of CA-125 was within normal limits.

Magnetic resonance imaging of the pelvis showed four uterine nodules, with the biggest being 2 cm in diameter, hypodense at T1 and T2, most probably corresponding to fibroids. In the myometrium there was a nodule with an intermediate sign at T1 and T2 that pushed inwards the adjacent endometrium. Inside this nodule there were two punctate images with an identical sign to that of the endometrium. This nodule may represent an area of adenomyosis (Fig. 1). The nodule was well circumscribed and localized in the inner third of the myometrium. The endometrium had normal thickness throughout the cavity. The cervix was normal. Abnormal lymph nodes were not identified.

## Abbreviations:

D & C: dilatation and curettage; FIGO: International Federation of Gynecology and Obstetrics; ER: estrogen receptor; PR: progesterone receptor.

The patient underwent a total abdominal hysterectomy with bilateral adnexectomy.

## Pathologic findings

Gross examination of the surgical specimen, showed a uterus (6.5 × 4.0 × 3.5 cm) covered by smooth, glistening mucosa. The endometrial cavity (4.5 cm in length) was a tiny slit with a tan-pink flat endometrium lining (0.2 cm in thickness on average).

The myometrium measured 2.0 cm in maximum thickness and contained several cystic hemorrhagic areas (adenomyosis) in the whole thickness, as well as several nodules that had a white-tan whorled appearance and no hemorrhage or necrosis, except for nodule (1.3 cm in its greatest dimension), subserosal, located on the lateral wall, near the fundus. It had a granular white appearance and was 0.7 cm away from the endometrial cavity.

## Histologic findings

The normally situated endometrium was atrophic, without hyperplasia or malignant lesions (Fig. 2). There were several leiomyomas, as well as numerous adenomyotic foci in the whole thickness of the myometrium. The granular intramural nodule was a well-differentiated endometrioid adenocarcinoma, arising in adenomyosis (Fig. 3), and transition from adenomyotic epithelium to adenocarcinoma was observed in several foci. There was no involvement of the uterine serosa, but there was minimal myometrial (outer half) invasion (Fig. 4) and lymphatic involvement.

## Adjuvant therapy

Postoperative radiation was offered to the patient. She was well 6 months after surgery, is regularly followed up and, so far, has no signs or symptoms of tumor recurrence.

## Discussion

Adenocarcinoma arising in adenomyosis of the uterus is uncommon. However, malignant transformation of the glandular epithelium in adenomyotic foci is possible, as these foci are downward extensions of the basal layer of the endometrium, which has considerable growth potential (11). Thus, when persistent estrogenic stimulation is present, proliferative changes may occur in these foci, including hyperplastic changes that can develop into carcinoma.

There are a few documented cases of carcinoma arising in adenomyosis with or without endometrial involvement (1–10).

Rolly (1) published the first report in 1987. In 1980, a review of the literature carried out by Hernandez and Woodruff (5) revealed 16 cases of adenocarcinoma in adenomyosis. In eight of these cases the carcinoma was present only in adenomyotic foci; in the remaining eight cases there was malignant alteration in both surface and intramyometrial endometrium.

In 1986, Woodruff et al. (6) reported two more cases of adenocarcinoma arising in adenomyosis without surface endometrial changes. Both patients were postmenopausal women who underwent a total hysterectomy with bilateral adnexectomy because of persistent atypical cytologies,

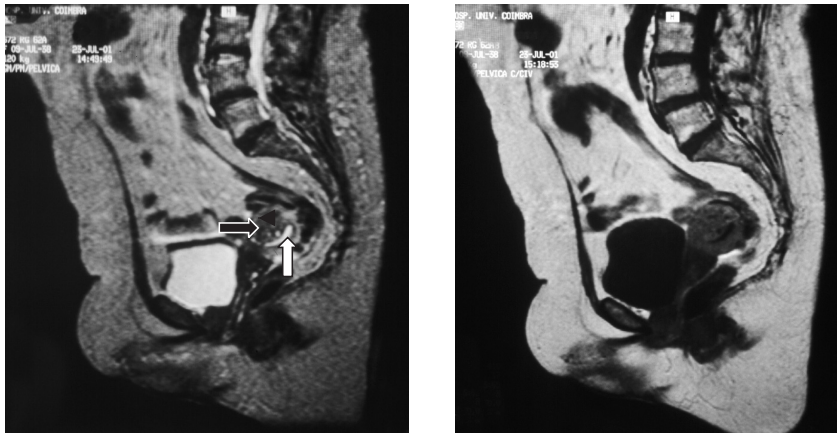


Fig. 1. Nodule in the myometrium with an intermediate sign at T1 and T2 that may represent an area of adenomyosis (black arrow), as there are two punctate images inside the nodule with an identical sign to that of the endometrium (white arrow).

despite negative findings on biopsies obtained by D & C. In these cases, the diagnosis was only made after the histologic examination of the surgical specimens.

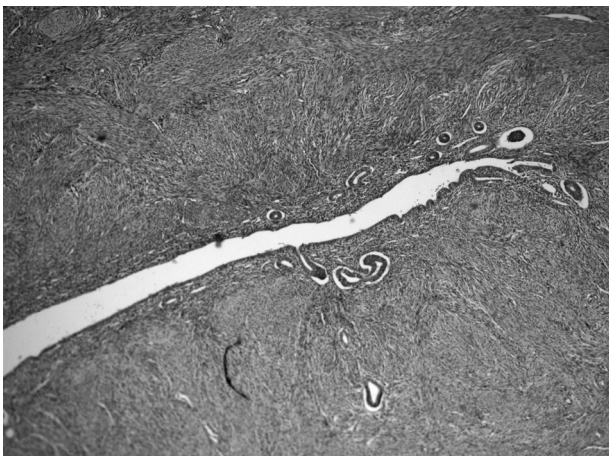

Fig. 2. Endometrium atrophic without hyperplasia or malignant lesions.

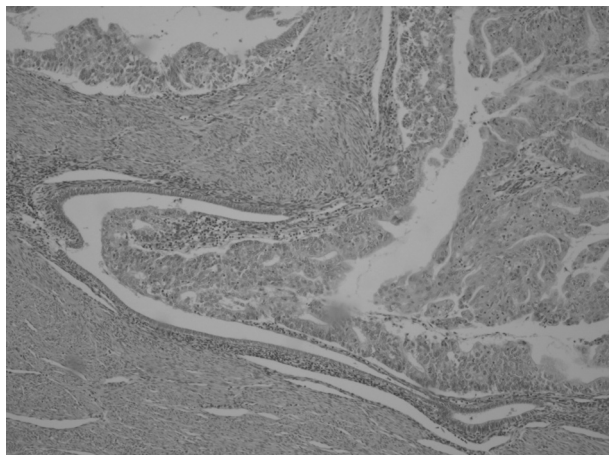


Fig. 3. Well-differentiated endometrioid adenocarcinoma arising in adenomyosis.




Fig. 4. Invasion of the myometrium without involvement of the uterine serosa.

Finally, in 2001, Toshiki et al. (7) reported a similar case of adenocarcinoma arising in adenomyosis without endometrial involvement, but there were already lymph node metastasis and involvement of the uterine serosa by the time the diagnosis was made. Thus, based on the International Federation of Gynecology and Obstetrics (FIGO) classification system, the case was classified as FIGO stage IIIc. They made an immunohistochemical analysis of the growth factors, including estrogen receptor (ER), progesterone receptor (PR), p53, bcl-2 protein and Ki-67 antigen, and found no expression of ER, PR or bcl-2 in the carcinoma cells. However, there was focal expression of p53 and prominent expression of Ki-67. These results suggest that some biological factors, including oncogenes and tumor suppressor genes, may play a role in the carcinogenesis of endometrial carcinoma arising from adenomyosis without surface endometrial changes.

In our case, the adenocarcinoma arose from an adenomyotic foci situated in the outer half of the myometrium, there was no malignant transformation on the surface of the endometrium, but the tumor invaded the adjacent myometrium. We found it difficult to classify this tumor, as the FIGO classification system does not foresee these cases. However, because there were myometrial invasion (on the outer half) and lymphatic involvement, we classified and treated this tumor as FIGO stage Ic.

It is conceivable that in localized areas of adenomyosis, cellular changes occur, involving mutations of tumor suppressor genes and activation of oncogenes that may result in malignant transformation.

Additional cocarcinogenic factors, such as proliferative stimulation as a result of endogenous estrogens, may be responsible for further genomic instability that promotes development of cellular clones with invasive potential. In the present case, this hormonal stimulation might also have been operative, as it was diagnosed as an atypical hyperplasia, probably focal, which was completely removed by curettage.

Fortunately, adenocarcinomas arising in adenomyosis are rare events, because they generally represent pathologic findings of a surgical specimen.

Further efforts should be made to clarify the pathogenesis of these tumors, namely the genetic abnormalities encountered in neoplastic areas in comparison with the nontumor components of the adenomyotic focus.

## References

1. Rolly F. Uber einen fall vonadenomyoma uterine uberbang in Karzinom und metastasen bildung. *Virchows Arch (Pathol Anat)* 1897; 150: 555.
2. Colman HI, Rosenthal HA. Carcinoma developing in areas of adenomyosis. *Obstet Gynecol* 1959; 14: 342–8.
3. Jacques S, Lawrence D. Endometrial adenocarcinoma with variable-level myometrial involvement limited to adenomyosis: a clinicopathologic study of 23 cases. *Gynecol Oncol* 1990; 37: 401–7.
4. Kuwashima Y, Uehara T, Kishi K, Tajima H, Shiromizu K, Matsuzawa M et al. Intramural adenocarcinoma of the uterus, arisen from adenomyosis uteri, showing unique histologic

- appearances: report of two cases. *Eur J Gynaec Oncol* 1994; 6: 418–23.
5. Saul Kay WJ, Frable Goplerud DR. Endometrial carcinoma arising in a large polypoid adenomyoma of the uterus. *Int J Gynecol Pathol* 1988; 7: 391–8.
6. Hernandez E, Woodruff JD. Endometrial adenocarcinoma arising in adenomyosis. *Am J Obstet Gynecol* 1980; 138: 827–32.
7. Woodruff JD, Erozan YS, Genadry R. Adenocarcinoma arising in adenomyosis detected by atypical cytology. *Obstet Gynecol* 1986; 67: 145–8.
8. Toshiki Sasaki et al. Endometrioid adenocarcinoma arising from adenomyosis: report and immunohistochemical analysis of an unusual case. *Pathol Int* 2001; 51: 308–13.
9. Grayzel D. Carcinoma arising in an adenomyoma of the uterus. *Am J Obstet Gynecol* 1959; 14: 342.
10. Andrews HR. Case of carcinoma of uterus arising in adenomyoma. *Proc R Soc Lond (Biol)* 1921; 14: 321.
11. Longacre T, Hendrickson M. Diffusely infiltrative endometrial adenocarcinoma: an adenoma malignum pattern of myoinvasion. *Am J Surg Pathol* 1999; 23: 69–78.
12. Siegler A, Camilien L. Adenomyosis. *J Reprod Med* 1994; 39: 841–53.

### Address for correspondence:

Daniela Couto, MD  
Serviço de Ginecologia  
Hospitais da Universidade de Coimbra  
Praceta Prof. Mota Pinto  
3049 Coimbra Codex  
Portugal  
e-mail: dcouto@net.sapo.pt

## — CASE REPORT —

# Three-dimensional transvaginal sonographic diagnosis of asymptomatic interstitial pregnancy at 6 weeks of gestation

CHINNAIYA ANANDAKUMAR AND NURUDDIN BADRUDDIN MOHAMMED  
Antenatal Diagnostic Center, Division of Maternal and Fetal Medicine, Department of Obstetrics and Gynecology, National University of Singapore, Singapore

*Acta Obstet Gynecol Scand* 2004; 83: 408–410. © Acta Obstet Gynecol Scand 83 2004

**Key words:** 3D ultrasound scan; asymptomatic interstitial pregnancy; early diagnosis

Submitted 11 June, 2002

Accepted 17 January, 2003

Interstitial pregnancies account for 2–4% of all tubal pregnancies (1) and are especially feared because of their devastating outcome (2). Even with advances in transvaginal

ultrasound technology, and although interstitial gestations can be identified at an early asymptomatic stage (2), it is still difficult to distinguish between an interstitial pregnancy and an angular pregnancy using two-dimensional (2D) transvaginal sonography (3). However, with the availability of 3D ultrasonography, diagnostic distinction between the various anatomic locations of tubal ectopic pregnancies is possible (4). This is of particular clinical importance as angular and interstitial pregnancies follow different clinical courses (5). Here, we report a case in which 3D transvaginal sonography with multiplanar analysis was used to confirm the diagnosis of asymptomatic interstitial pregnancy at 6 weeks of gestation.

## Case report

A 32-year-old woman, gravida 5 para 0, with a previous history of four recurrent first-trimester pregnancy losses, was referred to our antenatal diagnostic center at 6 weeks of amenorrhea for the evaluation and management of a left-sided tubal ectopic pregnancy. On presentation to us, the patient was asymptomatic. Her vital signs were stable and she had no pain or vaginal bleeding. Quantitative B-human chorionic gonadotropin (BhCG) concentration was 6671 IU/L. Two-dimensional transvaginal ultrasonography was performed, revealing a 15 mm × 13 mm gestational sac containing a viable embryo with crown rump length of 5 mm close to the left uterotubal junction. A corpus luteum was noted in the right ovary measuring 12 mm × 11 mm. Color flow Doppler ultrasound demonstrated a ring of fire sign, indicative of intense peritrophoblastic vascular activity surrounding the sac with resistance index of 0.64.

Copyright of *Acta Obstetricia et Gynecologica Scandinavica* is the property of Blackwell Publishing Limited and its content may not be copied or emailed to multiple sites or posted to a listserv without the copyright holder's express written permission. However, users may print, download, or email articles for individual use.