

UCLA

UCLA Previously Published Works

Title

Advancements in endoscopic hemostasis for non-variceal upper gastrointestinal bleeding.

Permalink

<https://escholarship.org/uc/item/1d27173t>

Journal

World Journal of Gastrointestinal Endoscopy, 16(7)

ISSN

1948-5190

Authors

Li, Xue

Fung, Brian

Publication Date

2024-07-16

DOI

10.4253/wjge.v16.i7.376

Peer reviewed



Advancements in endoscopic hemostasis for non-variceal upper gastrointestinal bleeding

Xue Jing Li, Brian M Fung

Specialty type: Gastroenterology and hepatology

Provenance and peer review: Invited article; Externally peer reviewed.

Peer-review model: Single blind

Peer-review report's classification

Scientific Quality: Grade C

Novelty: Grade C

Creativity or Innovation: Grade C

Scientific Significance: Grade B

P-Reviewer: Zhao JL

Received: March 27, 2024

Revised: June 6, 2024

Accepted: June 26, 2024

Published online: July 16, 2024

Processing time: 103 Days and 3.5 Hours



Xue Jing Li, Department of Gastroenterology and Hepatology, Banner-University Medical Center Phoenix, Phoenix, AZ 85006, United States

Brian M Fung, Department of Gastroenterology, Arizona Digestive Health, Mesa, AZ 85210, United States

Corresponding author: Brian M Fung, MD, Doctor, Department of Gastroenterology, Arizona Digestive Health, 603 W Baseline Rd, Ste 200, Mesa, AZ 85210, United States.
brianfung@outlook.com

Abstract

Non-variceal upper gastrointestinal (GI) bleeding is a significant cause of morbidity and mortality. Traditionally, through-the-scope (TTS) clips, thermal therapy, and injection therapies are used to treat GI bleeding. In this review, we provide an overview of novel endoscopic treatments that can be used to achieve hemostasis. Specifically, we discuss the efficacy and applicability of over-the-scope clips, hemostatic agents, TTS doppler ultrasound, and endoscopic ultrasound, each of which offer an effective method of reducing rates of GI rebleeding.

Key Words: Doppler probe; Endoscopic ultrasound; Endoscopy techniques; Gastrointestinal bleeding; Hemospray; Hemostasis; Hemostatic agents; Over-the-scope clips; Ovesco

©The Author(s) 2024. Published by Baishideng Publishing Group Inc. All rights reserved.

Core Tip: Non-variceal upper gastrointestinal bleeding is a significant cause of morbidity and mortality. In this review, we provide an overview of novel endoscopic treatments that can be used to achieve hemostasis. Specifically, we discuss the efficacy and applicability of over-the-scope clips, hemostatic agents, and adjunctive tools such as through-the-scope doppler ultrasound and endoscopic ultrasound.

Citation: Li XJ, Fung BM. Advancements in endoscopic hemostasis for non-variceal upper gastrointestinal bleeding. *World J Gastrointest Endosc* 2024; 16(7): 376-384

URL: <https://www.wjgnet.com/1948-5190/full/v16/i7/376.htm>

DOI: <https://dx.doi.org/10.4253/wjge.v16.i7.376>

INTRODUCTION

Non-variceal upper gastrointestinal (GI) bleeding is a leading cause of hospitalization, with an incidence ranging from 61-78 cases per 100000 and an estimated mortality between 2%-10%[1]. Bleeding can originate from sites within the esophagus, stomach, and duodenum, commonly manifesting as hematemesis and melena, and in cases of brisk bleeding, hematochezia[1,2]. The primary culprits are gastric and duodenal ulcers, Mallory-Weiss tears, esophagitis, and gastritis, and less frequently angiodysplasias, gastric antral vascular ectasias, Dieulafoy's lesions, polyps, and malignancy[1,2].

Currently, the mainstay of care for those hemodynamically stable involves endoscopic evaluation through esophago-gastroduodenoscopy[2]. Over the past 30 years, numerous endoscopic devices have been developed with demonstrated effectiveness at controlling upper GI bleeding. These include the use of through-the-scope (TTS) clips, thermocoagulation [*e.g.*, argon plasma coagulation (APC), multipolar, and bipolar electrocautery], and injection therapy[1,3]. In cases of continued or refractory bleeding, surgery or trans-arterial embolization is subsequently attempted[1,3]. However, novel endoscopic devices have provided additional methods of controlling challenging or recurrent bleeding, and have provided alternative methods that can be attempted prior to more invasive interventions (Figure 1).

In this review, we discuss novel endoscopic devices designed to achieve hemostasis in challenging or recurrent non-variceal upper GI bleeding, including the use of over-the-scope (OTS) clips, topical hemostatic agents, and adjunctive tools, such as TTS doppler ultrasound and endoscopic ultrasound (EUS).

TRADITIONAL THERAPIES

TTS clips have been used for hemostasis since 1975[4]. Manufactured by five key players (Olympus, Boston Scientific, Cook Medical, ConMed, and Micro-Tech), these clips are available in various sizes ranging from 8 mm, 11 mm, 12 mm, 16 mm, to 22 mm in opening width[5,6]. They are all designed to fit through the standard 2.8 mm biopsy channel of an endoscope or colonoscope, and some offer bidirectional rotation capabilities[5,6].

Thermal therapy is another option for treating GI bleeding. This class of therapy includes APC, a non-contact device which uses argon gas to treat superficial vascular lesions such as angiodysplasias or gastric antral vascular ectasia, as well as contact devices including bipolar electrocoagulation [*e.g.*, Gold Probe™ Catheter (Boston Scientific, Marlborough, Massachusetts, United States)] and monopolar electrocoagulation (*e.g.*, hemostatic forceps and snare tip soft coagulation)[3,7,8]. Both bipolar and monopolar electrocoagulation devices generate heat to cauterize vessels and apply direct pressure to the bleeding site[3,7,8].

Other conventional treatments include injection therapies, such as epinephrine for vasoconstriction, sclerosing agents for local thrombosis (*e.g.*, ethanol), and tissue adhesives for tissue bonding and sealing (*e.g.*, thrombin and cyanoacrylate)[3,7,8]. Epinephrine is the most commonly used agent in this class, usually diluted to 1:10000 or 1:20000 and injected in 0.5 to 2 mL aliquots to the ulcer base. It is combined with bipolar electrocoagulation or TTS clips, as combination therapy has been demonstrated to be superior to epinephrine monotherapy at preventing recurrent bleeding (relative risk (RR) 0.34, 95% confidence interval (CI) 0.23-0.50)[9].

The recent 2021 American College of Gastroenterology (ACG) guideline on upper GI bleeding strongly recommends bipolar electrocoagulation or injection of absolute ethanol for patients with ulcers and conditionally supports monopolar coagulation, APC, or TTS clips for treatment of bleeding due to ulcers[3]. Advantages include ease of access, abundance of safety data, and low cost. However, disadvantages can include risk of rebleeding especially with monotherapies like epinephrine and potential perforation with contact therapy[10].

OTS CLIPS

Over the past two decades, another type of clip has been developed, called OTS clips. In contrast to the conventional TTS clips, OTS clips can treat larger fibrotic ulcers and facilitate full-thickness wall closure in cases of leaks, perforations, and fistulas[11]. While the European and Japanese gastroenterology societies recommend OTS clips as a first-line therapy for GI bleeding, American gastroenterology societies currently position it as a second line hemostatic treatment as of the writing of this review[3,8]. The 2021 ACG guideline recommends using OTS clips for recurrent ulcer bleeding after previously successful endoscopic hemostasis, while the 2020 American Gastroenterological Association guideline suggest its use in select patients where conventional methods fall short[3,8].

Currently, two OTS clip systems are approved by the United States Food and Drug Administration (FDA): The OTSC® System (Ovesco Endoscopy GmbH, Tübingen, Germany), and the Padlock Clip® (previously Aponos Medical Co., Kingston, New Hampshire, United States, now Steris United States Endoscopy, Mentor, Ohio, United States)[11]. Both systems involve deploying a large nitinol magnetic resonance imaging-biocompatible clip using a transparent applicator cap attached to the distal end of the endoscope while applying suction in a technique similar to variceal banding[11,12].

OTSC, FDA-approved in the United States in 2010, is used for repairing perforations < 20 mm, and achieving hemostasis from mucosal/submucosal defects < 3 cm, arteries < 2 mm, polyps < 1.5 cm in diameter, diverticula, or bleeding ulcers in both the upper GI tract and the lower GI tract (Figure 2)[13]. It is a bear-claw-shaped clip with three prongs available in four sizes: A 10 mm diameter kit for pediatric endoscopy or narrow passage (*i.e.* through stents), an 11 mm and 12 mm diameter kit for adult endoscopes, and a 14 mm diameter kit for colonoscopes[13,14]. It comes with two cap depths: A 3 mm cap for smaller or thin tissue area, and a deeper 6 mm cap for extensive defects. The closing spikes vary according to intended use: Type "a" (atraumatic) has blunt teeth for soft tissue, type "t" (therapeutic) has spiked

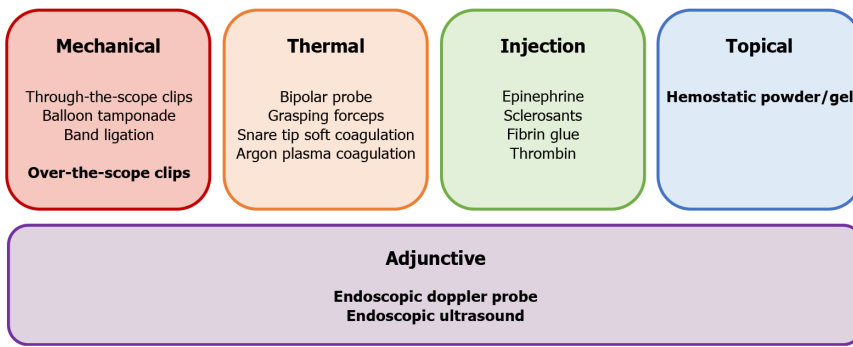


Figure 1 Common methods of endoscopic hemostasis. Novel techniques discussed in this review are bolded.

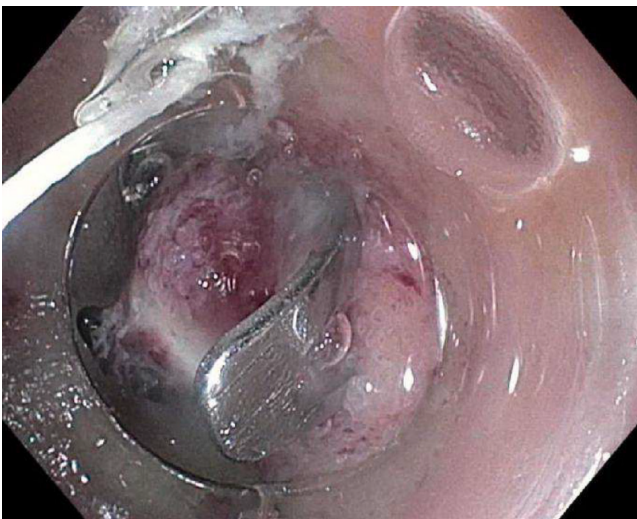


Figure 2 Use of OTSC clip for a duodenal ulcer. Here, an OTSC clip is used to successfully treat gastrointestinal bleeding from a Forrest IIa duodenal bulb ulcer.

teeth for hard/fibrotic tissue, and type “gc” has longer pointed teeth for gastric perforation/fistula closure[13,14]. Additional application aids (such as the OTSC Anchor and OTSC Twin Grasper) can be advanced through the working channel of the endoscope to help approximate tissues after full-thickness resection prior to OTSC deployment[13].

The other FDA-approved OTS clip is the Padlock Clip, approved in 2012 for the same uses as the Ovesco OTSC[15]. Although it was briefly recalled in 2019, it has been back on the market since 2020[16]. Unlike the bear-claw shape of the OTSC clip, the Padlock system has a hexagonal star-shaped clip design with six inner prongs that allows for a circumferential grip on tissues[15,17]. It comes in two forms. The Padlock Clip Defect Closure system has tip diameters ranging from 9.5 mm to 11 mm with a fixed chamber depth of 1 cm for endoscopes, while the Pro Select closure system has tip diameters ranging from 11.3 to 14 mm with variable depth (8-20 mm) for colonoscopes[17]. Unlike the OTSC system, the linking cable to deploy the clip runs outside the scope rather than within the instrument channel[15,17]. Additionally, while OTSC has a specialized cutter system (Ovesco remOVE System) to remove the clip if it gets stuck, the Padlock Clip cannot be removed once placed[18]. There are currently no human trials comparing the different types of OTS clips. In a study comparing the OTSC and Padlock Clip in a model using a porcine stomach, the OTSC was noted to have a success rate of 100% (11/11 procedures) and the Padlock had a 0% success rate (0/11 procedures)[19].

Both OTS clip systems come with advantages, including the ability to grasp large amounts of tissue or fibrotic ulcers, and providing significant compressive forces. In a meta-analysis by Faggen *et al*[20] on 11 studies comparing the OTS clip with standard endoscopic therapies for non-variceal upper GI bleeding, the former showed lower rates of rebleeding at 30 days (RR 0.58; 95%CI: 0.41-0.92), though there were no differences in mortality (RR 0.69; 95%CI: 0.38-1.23). A similar meta-analysis of ten studies was done by Bapaye *et al*[21], which found that OTS had lower 7-day (RR 0.41; 95%CI: 0.24-0.68) and 30-day rebleeding risk (RR 0.46; 95%CI: 0.31-0.65), shorter procedure time by 6.63 minutes (95%CI: 2.58-10.67), but no difference in mortality (RR 0.55; 95%CI: 0.24-1.24). With regards to efficacy as a primary therapy and rescue intervention, a meta-analysis of 16 studies found similar primary hemostasis rates (93% *vs* 91%) for use as a primary and rescue therapy, respectively. However, there was a decreased risk of re-bleeding in patients treated with OTS clips as primary therapy *vs* rescue (RR = 0.52, 95%CI: 0.31-0.89)[22]. Likewise, a meta-analysis by Zhong *et al*[23] looking at 16 studies found that OTS clips had high technical (95.7% success rate) and clinical (84.2% success rate) success.

However, OTS clips also come with limitations. Challenges include needing to remove the endoscope to attach the applicator cap and reintubate the patient prior to deployment, difficulty positioning the clip on a target lesion, difficulty navigating it through strictures and areas of stenosis, and difficulty performing other hemostasis maneuvers should bleeding persists following deployment. Additional adverse events include accidental deployment, clip dislodgement, mucosal damage, gastric and jejunal stenosis, secondary perforations, maceration of the perforated site, and tissue necrosis[24]. The overall adverse event rate was 1.8% in a retrospective study by Kobara *et al*[25] involving 58 patients. However, in another retrospective study of 30 patients by Mercky *et al*[26], OTS clips were associated with an adverse event rate of 13.3%.

HEMOSTATIC AGENTS

Topical hemostatic agents offer an alternative strategy for managing non-variceal upper GI bleeding, providing a non-contact, non-thermal, non-traumatic application, distinct from hemoclips or thermocoagulation[11]. Because directed targeting is not necessary, their ease of application makes them suitable for scenarios where bleeding is diffuse and challenging to localize, such as from ulcers, tumors, anastomosis, or iatrogenic lesions secondary to endoscopic submucosal dissection (ESD), endoscopic mucosal resection (EMR), and polypectomy. The 2021 ACG guideline recommends hemostatic powders as a temporizing measure to stop bleeding in cases where conventional modalities fall short of achieving hemostasis, bridging the gap to more definitive therapies like transarterial embolization or surgery[3].

Presently, three FDA-approved single-use hemostatic powders are available (Tables 1 and 2): TC-325 (Hemospray[®], Cook Medical, Winston-Salem, North Carolina, United States); EndoClot[®] Polysaccharide Hemostatic System (PHS) (EndoClot Plus, Santa Clara, California, United States); UI-EWD Nexpowder[™] (Nextbiomedical, Incheon, Republic of Korea)[11,27]. All involve a 220 cm delivery catheter through the working channel of an end-viewing endoscope, connected to a powder dispenser and a delivery system. At the bleeding site, the powders form a temporary mechanical barrier that sloughs off within 1-3 days[11,27].

TC-325 (Hemospray), FDA-approved in 2018 for both non-variceal upper and lower GI bleeding, uses sodium bentonite, a natural aluminum phyllosilicate clay, to absorb water on contact with blood[28,29]. It has two versions: HEMO-7 compatible with a 2.8 mm endoscope accessory channel, and HEMO-10 compatible with a 3.7 mm channel[28, 29]. Contraindications include patients with a GI fistula and those at high risk of or suspected of having a GI perforation, as each canister of TC-325 can add 3 L of additional volume to the GI tract, posing a possibility of overdistension[28-30]. While risks include failure to control bleeding, biliary obstruction at sites of sphincterotomy, device malfunction, and perforation[30,31], previous concerns about bowel obstruction, allergic reactions, and embolization have not been observed clinically[28]. A maximum of three devices per patient is recommended at a time. The shelf life is 3 years[28,29]. One limitation is the risk of early activation of the powder and catheter clogging if moisture comes in contact with the catheter prematurely[29]. This can be prevented by preflushing the working channel with air prior to catheter insertion and deploying the spray from a distance of 1-2 cm away in 1- to 2-second bursts. Additionally, efficacy in nonbleeding lesions is limited, as the powder primarily adheres to blood. Washing the lesion site or cleaning the lens post-spray is also not recommended, as it may wash away the powder[27,28,32].

EndoClot PHS, FDA-approved in 2021, is a spray composed of absorbable modified polymers derived from plant starch[33,34]. It is approved for the same intended use as Hemospray but with a reduced scope of practice, as it excludes Forrest Ia (spurting) ulcers[34]. Similar to TC-325, the polymers initiate a dehydration process, resulting in a high concentration of platelets, red blood cells, and coagulation proteins at the bleeding site. This forms a gel adhesive matrix that promotes the physiologic clotting cascade[33,34]. The matrix is readily dissolved by saline irrigation and is degraded by amylase and glucoamylase, and eliminated through stool within 24 hours[33]. Contraindications include starch sensitivity, with other limitations similar to TC-325[33,34]. The shelf life is 3 years. EndoClot is also available in 180 cm catheter length[33,34].

UI-EWD (Nexpowder[™]), FDA-approved since 2022, is a spray that consists of succinic anhydride and oxidized dextran derived from microbial extraction (Figure 3)[35,36]. While sharing the same intended use as Hemospray, it is not approved for lower GI bleeding[36]. Unlike EndoClot and TC-325, Nexpowder can be used in non-bleeding sites, as the two compounds in the spray crosslink to form a highly adhesive, distinctive blue hydrogel in the presence of any moisture[35]. Additionally, unlike EndoClot or TC-325, UI-EWD uses a battery-powered system, eliminating the need for CO₂-pressurized air compressors, thereby improving endoscopic visibility and reducing the risk of the catheter clogging [35]. Contraindications include patients with galactose intolerance, Lapp lactase deficiency, or glucose-galactose malabsorption due to the presence of lactose in the powder[35,36]. Additionally, the spray cannot be used in patients with hypersensitivity to brilliant blue FCF dye, bowel obstruction, GI fistulas, or suspected/high-risk GI perforation. The shelf life is 15 months[35,36].

Recently, a hemostatic gel has also gained approval for non-variceal GI bleeding, excluding Forrest Ia ulcers. PuraStat[®] (3-D Matrix, Newton, Massachusetts, United States), FDA-approved since 2021, is a sterile gel composed of a synthetic repeating 16-amino acid (acetyl-[arginyl-alanyl-aspartyl-alanyl]4-amide tetrahydrochloride) oligopeptide suspended in sterile water[37,38]. When exposed to blood, a pH-induced transformation induces the peptide to self-assemble into a scaffold fiber structure that mimics the human extracellular matrix, creating a transparent adhesive surface[38]. It is packaged in a 5-mL prefilled syringe containing 1, 3, or 5 mL of gel (2.5% peptide content)[38]. Similar to all hemostatic sprays, PuraStat is delivered to the intended site through a delivery catheter inserted into the working channel. Aside from primary non-variceal GI bleeding, it is also approved for hemostasis of mild and moderate bleeding post ESD or EMR, as an adjunct, bridge, prophylactic, or rescue therapy for intraprocedural venous bleeding or prophylactic therapy

Table 1 Advantages and limitations of the different modalities

	Advantages	Limitations
Through-the-scope clips	Multiple sizes available; ease of access; well studied	Not suitable for large lesions or defects as can have slippage or incomplete closure; deployment challenging in certain locations (<i>e.g.</i> , duodenal sweep)
Thermal therapy	Ease of access; well studied; compatible with other modalities (<i>e.g.</i> , injections, clips)	Potential perforation; delayed bleeding
Injections (epinephrine, sclerosing agents)	Cost-effective; fast onset; well studied; compatible with other modalities (<i>e.g.</i> , thermal therapy, clips)	Higher risk of rebleeding if used as monotherapy; localized tissue necrosis and ulceration; limited efficacy for larger lesions; Potential systemic side effects (<i>e.g.</i> , tachycardia and arrhythmia with epinephrine)
Over-the-scope clips	Grasp large area; approved for perforation and fistula closures; durability; lower risk of rebleeding compared to traditional therapies	Must remove endoscope to attach application cap; difficulty positioning on target lesion; limited options for further hemostatic intervention after deployment; can be challenging to remove
Hemostatic agents	Ease of application: No direct targeting needed; application to large area in short time; lower risk of tissue damage	Device malfunction: Catheter clog, early activation of powder, washing away powder; contraindicated if history of fistula; can cause biliary obstruction; risk of rebleeding after days; limited penetration of deeper lesions
Endoscopic doppler probe	Real-time evaluation of vasculature; can assess for risk of rebleeding; distinguish arterial <i>vs</i> venous blood flow	Variability in doppler signal interpretation; false signals from cardiac pulsations
Endoscopic ultrasound	Can visualize small vessels not seen on radiologic exam; can concurrently assess submucosal anatomy (<i>e.g.</i> , tumor depth, <i>etc.</i>); real-time evaluation of vasculature; can assess for risk of rebleeding; distinguish arterial <i>vs</i> venous blood flow	Need for training in endosonography; limited portability; imaging artifacts from retained blood; not standardized for use in non-variceal GI bleeding

Table 2 United States Food and Drug Administration indications for hemostatic agents

	Forrest Ia	Forrest IB	Forrest IC	Forrest IIa	Forrest IIb	Forrest IIc	Forrest III	Lower GI bleeding
Hemospray	x	x	x	x	x	x	x	x
Nexpowder	x	x	x	x	x	x	x	
PuraStat		x	x	x	x	x	x	x
EndoClot		x	x	x	x	x	x	x

GI: Gastrointestinal.

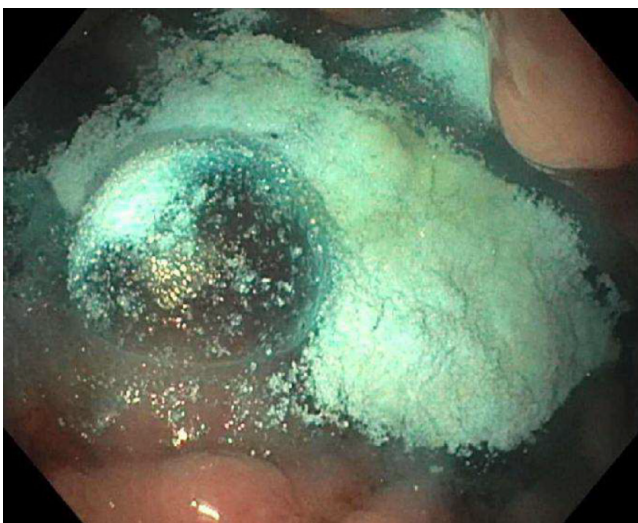

Figure 3 Use of Nexpowder for tumor bleeding. Application of Nexpowder to stop diffuse bleeding from gastric adenocarcinoma.

to prevent post-procedure bleeding, and for rectal mucositis[37]. Unlike hemostatic powder, PuraStat must be applied as close as possible to the bleeding site during application to form a mechanical barrier. It must also be stored in a refrigerator (from 2 to 8 °C). The gel is metabolized by enzymes into constituent amino acids over 30 days[37,38].

Two other powders-Ankaferd Blood Stopper (Ankaferd Health Products, Istanbul, Turkey) and CEGP-003 (CGBio, Seong-Nam, Republic of Korea)-have been described for use in non-variceal upper GI bleeding, but are not yet approved by the FDA. The former comprises a standardized mixture of five herbs (*urtica dioica*, *vitis vinifera*, *glycyrrhiza glabra*, *alpinia officinarum*, and *thymus vulgaris*)[39,40]. This plant-based agent stimulates the formation of an encapsulated protein network containing fibrinogen, total protein, albumin, and globin, attracting erythrocytes and promoting platelets aggregation[39,40]. The latter, CEGP-003, under development in South Korea, is a powder consisting of hydroxyethylcellulose and epidermal growth factor[41]. Hydroxyethylcellulose, upon contact with water, forms an adhesive gel that acts as a barrier, while the epidermal growth factor activates the synthesis of hyaluronan and aquaporin-3, both promoting wound healing. To date, a single-blinded, prospective randomized study of 72 patients has been completed to assess the efficacy and safety of CEGP-003 in patients with peptic ulcers bleeding[41]. The study found that CEGP-003 had an initial hemostasis rate of 100% compared to epinephrine (89.2%), with rebleeding occurring in 3 out of 35 and 1 out of 37 patients in the CEGP-003 and epinephrine groups, respectively ($P = 0.35$)[41].

A meta-analysis looking at 59 studies (46 on Hemospray, 4 on PuraStat, 5 on EndoClot, 3 on Nexpowder, 1 on CEGP-003) found that the cumulative rates of immediate hemostasis were 93% and overall rebleeding rate was 18% within one week[42]. Immediate hemostasis among the different agents was 93% (95%CI: 91%-95%) for Hemospray, 87% (95%CI: 75%-94%) for EndoClot, 86% (95%CI: 80%-90%) for PuraStat, 96% (95%CI: 91%-99%) for Nexpowder, and 99% (95%CI: 81%-100%) for CEGP-003. When the risk of rebleeding was stratified according to the agent used, it was numerically greater with Hemospray [20% (95%CI: 17%-24%)], compared to the other agents including EndoClot [10% (95%CI: 6%-16%)], PuraStat [7% (95%CI: 1%-27%)], Nexpowder [8% (95%CI: 3%-20%)], and CEGP-003 [9% (95%CI: 3%-23%)] [42]. Adverse events occurred in 2%, including three cases of perforations among 2111 patients. Whether used as monotherapy, combination therapy, or rescue therapy, hemostatic powders provide endoscopists with another method of achieving hemostasis.

TTS DOPPLER PROBE

The endoscopic doppler probe (EDP) is an adjunctive device that can be used for risk stratification in GI bleeding and guidance of hemostasis[3,8,11]. Presently, the VTI Selectable Depth Doppler System (Vascular Technology Inc, Nashua, New Hampshire, United States) stands as the sole FDA-approved device for endoscopic use. It comprises of a portable 1.18 kg AC-powered base unit connected to a single-use 2.5 mm diameter doppler probe emitting a 20-MHz pulsed-wave ultrasound beam (Figure 4)[43]. The probe comes in lengths of 165 cm or 245 cm, and can be used with standard diagnostic or therapeutic forward-viewing endoscopes, as well as side-viewing duodenoscopes and colonoscopes[43].

To use it, a lubricated doppler probe is passed down the accessory channel of an endoscope or colonoscope. It is then applied to the lesion of interest in a tangential orientation to identify blood flow. The probe is moved in various directions to acoustically map the direction of blood flow and guide endoscopic hemostasis. Depending on the lesion, the scanning depth can be adjusted: Shallow (0-1.5 mm) for untreated peptic ulcers or those treated with endoclips, thermal coagulation, or combination of injection with thermal therapy; mid (0-4 mm) for varices, untreated gastric ulcers with adherent clot, or ulcers treated with injection (due to existence of subsurface fluid bleb)[43,44]. Arterial flow typically presents as a spiking, high-pitched sound, while venous blood flow presents as a continuous low-pitch rumble[43,44].

EDP can be especially helpful in the evaluation of lesions with unclear visual bleeding stigmata, such as gastric or duodenal ulcers that can either be classified as Forrest 2b (adherent clot) or Forrest 2c (flat pigmented spot) depending on the endoscopist. While the former is treated per current guidelines, the latter is traditionally not treated endoscopically [43]. Preliminary studies have also demonstrated the use of doppler probe for the diagnosis and treatment of gastric varices, Dieulafoy's lesion, diverticular bleeding, and post-ESD ulcers[45].

With regards to its effectiveness, a meta-analysis of 11 observational studies and 3 interventional studies found that application of doppler endoscopic probe at the index endoscopy reduced overall rebleeding rates [OR 0.27 (95%CI: 0.14-0.54)], need for surgery [OR 0.09 (95%CI: 0.02-0.42)], and improved bleeding-related mortality [OR 0.12 (95%CI: 0.02-0.71)], though it did not affect all-cause mortality [OR 0.40 (95%CI: 0.15-1.06)] [46]. Additionally, EDP can predict risk of rebleeding post-treatment. In patients whose treated lesions exhibited a positive EDP signal, the risk of rebleeding was higher than those with a negative EDP signal [OR 25.96 (95%CI: 6.74-100)] [46]. In cost-analyses, EDP is cost-effective compared to conventional visually guided therapy in acute peptic ulcer bleeding[47,48].

Overall, studies report EDP as a promising tool for risk stratifying lesions at high risk of rebleeding and for guiding hemostatic therapy. Advantages include ease of use without requiring EUS training, real-time evaluation of vasculature with the ability to distinguish between arterial and venous flow, and the ability to estimate depth of subsurface blood vessels. Limitations include variability among endoscopists in Doppler signal interpretation and the potential presence of false artifactual signals (*e.g.*, transmitted cardiac pulsations in the fundus of the stomach).

ENDOSCOPIC-ULTRASOUND

EUS is distinct from TTS doppler probes in that it uses radial or linear array echoendoscopes to delineate the anatomy and subsurface blood vessels. While both use doppler technology to assess blood flow, the TTS doppler probe does so *via*

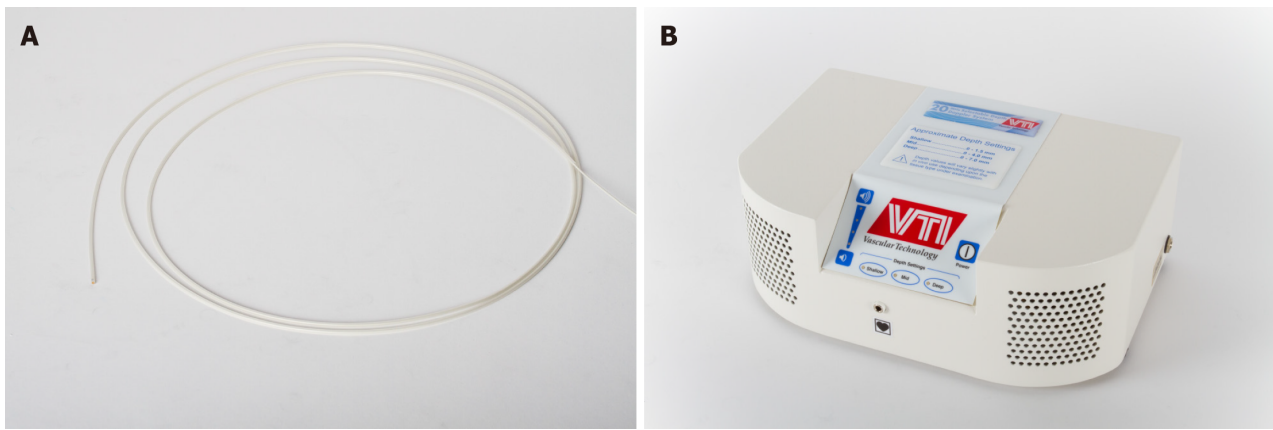


Figure 4 The endoscopic doppler probe. The VTI Selectable Depth Doppler System (created by Vascular Technology, Inc., Nashua, New Hampshire) consists of. A: A single-use 2.5 mm diameter doppler probe; B: A portable AC-powered base unit. Photo courtesy of Vascular Technology, Incorporated. Citation: Vascular Technology, Incorporated. Photo of VTI's Endoscopic Doppler System and Probe. Copyright©Vascular Technology.

acoustic mapping, while EUS applies doppler flow to visualize the blood vessels responsible for GI bleeding. Under EUS-guidance, needles are used to target blood vessel or lesions responsible for bleeding. Cyanoacrylate, polidocanol, embolization coils, thrombin, or ethanol are then injected for hemostasis[49]. EUS has been reported to be an effective method for guiding hemostasis in patients with refractory GI bleeding from ulcers, Dieulafoy's lesions, pancreatic pseudoaneurysms, and GI stromal tumors[50].

Recently, a prospective observational single-center study by Uribarri-González *et al*[51] looked at the usefulness of EUS-guided therapy in patients with non-variceal GI bleeding refractory to two conventional endoscopic therapies. Of the fourteen patients included, nine had Dieulafoy's lesions, and five had submucosal tumors. Six patients (78%) had an absence of re-bleeding after EUS treatment. Advantages of this adjunctive technique include its ability to visualize small blood vessels not seen with radiologic or endoscopic exam, perform EUS-guided angiotherapy, and assess for procedural success real-time by looking for cessation of blood flow. Disadvantages include the need for training in endosonography, cost, lack of efficacy and safety data, limited portability and availability of EUS systems, as well as technical issues such as imaging artifacts from retained intraluminal blood[49].

CONCLUSION

Non-variceal upper GI bleeding remains a common cause of hospitalization and is associated with high mortality rates. Emerging techniques such as OTS clips, hemostatic agents, TTS doppler, and EUS show promise in reducing rebleeding rates and enhancing overall patient outcomes. Further randomized, controlled trials and cost-analyses will be helpful in delineating their specific roles in hemostasis for future clinical applications.

FOOTNOTES

Author contributions: Li XJ drafted the manuscript and prepared figures and tables; Fung BM designed the manuscript outline, prepared figures, and critically reviewed the manuscript. All authors provided critical input and approved the final version of the manuscript.

Conflict-of-interest statement: The authors have no conflicts of interest.

Open-Access: This article is an open-access article that was selected by an in-house editor and fully peer-reviewed by external reviewers. It is distributed in accordance with the Creative Commons Attribution NonCommercial (CC BY-NC 4.0) license, which permits others to distribute, remix, adapt, build upon this work non-commercially, and license their derivative works on different terms, provided the original work is properly cited and the use is non-commercial. See: <https://creativecommons.org/licenses/by-nc/4.0/>

Country of origin: United States

ORCID number: Xue Jing Li 0000-0003-0962-1447; Brian M Fung 0000-0002-2558-5733.

Corresponding Author's Membership in Professional Societies: American College of Gastroenterology; American Gastroenterological Association; American Society for Gastrointestinal Endoscopy; American Association for the Study of Liver Diseases.

S-Editor: Qu XL

L-Editor: A

P-Editor: Zheng XM

REFERENCES

- 1 **Stanley AJ**, Laine L. Management of acute upper gastrointestinal bleeding. *BMJ* 2019; **364**: 1536 [PMID: 30910853 DOI: 10.1136/bmj.1536]
- 2 **Alali AA**, Barkun AN. An update on the management of non-variceal upper gastrointestinal bleeding. *Gastroenterol Rep (Oxf)* 2023; **11**: goad011 [PMID: 36949934 DOI: 10.1093/gastro/goad011]
- 3 **Laine L**, Barkun AN, Saltzman JR, Martel M, Leontiadis GI. ACG Clinical Guideline: Upper Gastrointestinal and Ulcer Bleeding. *Am J Gastroenterol* 2021; **116**: 899-917 [PMID: 33929377 DOI: 10.14309/ajg.0000000000001245]
- 4 **Hayashi T**, Yonezawa M, Kawabara T. The study on staunch clip for the treatment by endoscopy. *Gastroenterol Endosc* 1975; **17**: 92-101 [DOI: 10.11280/gee1973b.17.92]
- 5 **Wang TJ**, Aihara H, Thompson AC, Schulman AR, Thompson CC, Ryou M. Choosing the right through-the-scope clip: a rigorous comparison of rotatability, whip, open/close precision, and closure strength (with videos). *Gastrointest Endosc* 2019; **89**: 77-86.e1 [PMID: 30056253 DOI: 10.1016/j.gie.2018.07.025]
- 6 **Daram SR**, Tang SJ, Wu R, To SD. Benchtop testing and comparisons among three types of through-the-scope endoscopic clipping devices. *Surg Endosc* 2013; **27**: 1521-1529 [PMID: 23292554 DOI: 10.1007/s00464-012-2679-4]
- 7 **ASGE technology committee**, Parsi MA, Schulman AR, Aslanian HR, Bhutani MS, Krishnan K, Lichtenstein DR, Melson J, Navaneethan U, Pannala R, Sethi A, Trikudanathan G, Trindade AJ, Watson RR, Maple JT; ASGE Technology Committee Chair. Devices for endoscopic hemostasis of nonvariceal GI bleeding (with videos). *VideoGIE* 2019; **4**: 285-299 [PMID: 31334417 DOI: 10.1016/j.vgie.2019.02.004]
- 8 **Mullady DK**, Wang AY, Waschke KA. AGA Clinical Practice Update on Endoscopic Therapies for Non-Variceal Upper Gastrointestinal Bleeding: Expert Review. *Gastroenterology* 2020; **159**: 1120-1128 [PMID: 32574620 DOI: 10.1053/j.gastro.2020.05.095]
- 9 **Laine L**, McQuaid KR. Endoscopic therapy for bleeding ulcers: an evidence-based approach based on meta-analyses of randomized controlled trials. *Clin Gastroenterol Hepatol* 2009; **7**: 33-47; quiz 1 [PMID: 18986845 DOI: 10.1016/j.cgh.2008.08.016]
- 10 **Jacques J**, Legros R, Chaussade S, Sautereau D. Endoscopic haemostasis: an overview of procedures and clinical scenarios. *Dig Liver Dis* 2014; **46**: 766-776 [PMID: 25022337 DOI: 10.1016/j.dld.2014.05.008]
- 11 **Nulsen B**, Jensen DM. Hemostasis Techniques for Non-variceal Upper GI Hemorrhage: Beyond Injection and Cautery. *Dig Dis Sci* 2022; **67**: 1431-1441 [PMID: 34105024 DOI: 10.1007/s10620-021-07034-x]
- 12 **Guedes HG**, de Moura EGH. Endoscopic management of complications-Ovesco/stent for management of anastomotic leaks: a narrative review *Ann Esophagus* 2022; **5**: 16-16 [DOI: 10.21037/aoe-21-1]
- 13 **Ovesco Endoscopy**. OTSC Clip. Available from: <https://ovesco.com/otsc-system/otsc-system-set/>
- 14 **U.S. Food & Drug Administration**. Ovesco Endoscopy Ovesco FDA 510k. Available from: https://www.accessdata.fda.gov/cdrh_docs/pdf10/K101428.pdf
- 15 **U.S. Food & Drug Administration**. STERIS Padlock FDA 510k. Available from: https://www.accessdata.fda.gov/cdrh_docs/pdf18/K180689.pdf
- 16 **U.S. Food & Drug Administration**. Class 2 Device Recall US Endoscopy. Available from: <https://www.accessdata.fda.gov/scripts/cdrh/cfdocs/cfres/res.cfm?id=171045>
- 17 **STERIS Healthcare**. Padlock Clip® Defect Closure System. Available from: <https://www.steris.com/healthcare/products/endoscopy-devices/gi-bleed-management-and-irrigation/padlock-clip-defect-closure-system>
- 18 **Goenka MK**, Rodge GA, Tiwary IK. Endoscopic Management with a Novel Over-The-Scope Padlock Clip System. *Clin Endosc* 2019; **52**: 574-580 [PMID: 31766822 DOI: 10.5946/ce.2019.122]
- 19 **Prosst RL**, Kratt T. A randomized comparative trial of OTSC and Padlock for upper GI hemostasis in a standardized experimental setting. *Minim Invasive Ther Allied Technol* 2017; **26**: 65-70 [PMID: 28350273 DOI: 10.1080/13645706.2017.1291523]
- 20 **Faggen AE**, Kamal F, Lee-Smith W, Khan MA, Sharma S, Acharya A, Ahmed Z, Farooq U, Bayudan A, McLean R, Avila P, Dai SC, Munroe CA, Kouanda A. Over-the-Scope Clips Versus Standard Endoscopic Treatment for First Line Therapy of Non-variceal Upper Gastrointestinal Bleeding: Systematic Review and Meta-Analysis. *Dig Dis Sci* 2023; **68**: 2518-2530 [PMID: 36943590 DOI: 10.1007/s10620-023-07888-3]
- 21 **Bapaye J**, Chandan S, Naing LY, Shehadah A, Deliwala S, Bhalla V, Chathuranga D, Okolo PI 3rd. Safety and efficacy of over-the-scope clips versus standard therapy for high-risk nonvariceal upper GI bleeding: systematic review and meta-analysis. *Gastrointest Endosc* 2022; **96**: 712-720.e7 [PMID: 35803307 DOI: 10.1016/j.gie.2022.06.032]
- 22 **Ofofu A**, Ramai D, John F, Barakat M, Sunkara T, Sharma S, Gaduputi V, Adler DG, Reddy M. Over-the-scope-clips as primary and rescue therapy for non-variceal gastrointestinal bleeding: a systematic review and meta-analysis. *Minerva Gastroenterol Dietol* 2019; **65**: 70-76 [PMID: 30417630 DOI: 10.23736/S1121-421X.18.02513-8]
- 23 **Zhong C**, Tan S, Ren Y, Lü M, Peng Y, Fu X, Tang X. Clinical outcomes of over-the-scope-clip system for the treatment of acute upper non-variceal gastrointestinal bleeding: a systematic review and meta-analysis. *BMC Gastroenterol* 2019; **19**: 225 [PMID: 31870315 DOI: 10.1186/s12876-019-1144-4]
- 24 **Abbas D**, Abdallah M, Ahmed K, Abdalla AO, McDonald N, Umar S, Hanson BJ, Bilal M. Analysis of Reported Adverse Events Related to Over-the-Scope Clips: A MAUDE Database Analysis. *Tech Innov Gastrointes Endosc* 2023; **25**: 106-112 [DOI: 10.1016/j.tige.2022.11.005]
- 25 **Kobara H**, Mori H, Fujihara S, Nishiyama N, Chiyo T, Yamada T, Fujiwara M, Okano K, Suzuki Y, Murota M, Ikeda Y, Oryu M, AboEllail M, Masaki T. Outcomes of gastrointestinal defect closure with an over-the-scope clip system in a multicenter experience: An analysis of a successful suction method. *World J Gastroenterol* 2017; **23**: 1645-1656 [PMID: 28321166 DOI: 10.3748/wjg.v23.i9.1645]
- 26 **Mercky P**, Gonzalez JM, Aimore Bonin E, Emungania O, Brunet J, Grimaud JC, Barthet M. Usefulness of over-the-scope clipping system for closing digestive fistulas. *Dig Endosc* 2015; **27**: 18-24 [PMID: 24720574 DOI: 10.1111/den.12295]
- 27 **Dhar J**, Ramai D, Samanta J, Facciorusso A. Hemostatic powders and gels in gastrointestinal endoscopy: current perspective and future recommendations. *Expert Rev Gastroenterol Hepatol* 2023; **17**: 1061-1065 [PMID: 37864554 DOI: 10.1080/17474124.2023.2274913]
- 28 **Cook Medical**. Hemospray® Endoscopic Hemostat. Available from: <https://www.cookmedical.com/products/35a4a7f2-867b-4c81-a983-44ea06277852/>
- 29 **U.S. Food & Drug Administration**. Wilson-Cook Medical, Inc. Hemospray FDA 510K. Available from: https://www.accessdata.fda.gov/cdrh_docs/reviews/DEN170015.pdf
- 30 **Hagel AF**, Albrecht H, Nägel A, Vitali F, Vetter M, Dauth C, Neurath MF, Raithel M. The Application of Hemospray in Gastrointestinal Bleeding during Emergency Endoscopy. *Gastroenterol Res Pract* 2017; **2017**: 3083481 [PMID: 28232848 DOI: 10.1155/2017/3083481]
- 31 **Yau AH**, Ou G, Galorport C, Amar J, Bressler B, Donnellan F, Ko HH, Lam E, Enns RA. Safety and efficacy of Hemospray® in upper

- gastrointestinal bleeding. *Can J Gastroenterol Hepatol* 2014; **28**: 72-76 [PMID: 24501723 DOI: 10.1155/2014/759436]
- 32 **Paoluzi OA**, Troncone E, De Cristofaro E, Sibilia M, Monteleone G, Del Vecchio Blanco G. Hemostatic Powders in Non-Variceal Upper Gastrointestinal Bleeding: The Open Questions. *Medicina (Kaunas)* 2023; **59** [PMID: 36676767 DOI: 10.3390/medicina59010143]
- 33 **EndoClot Plus, Inc.** Endoclot® PHS. Available from: <https://endoclot.com/products.html>
- 34 **U.S. Food & Drug Administration.** EndoClot Plus Co., Ltd Endoclot FDA 510K. Available from: https://www.accessdata.fda.gov/cdrh_docs/pdf19/K190677.pdf
- 35 **Medtronic.** Nexpowder™* Endoscopic Hemostasis System. Available from: <https://www.medtronic.com/covidien/en-us/products/therapeutic-endoscopy/nexpowder-endoscopic-hemostasis-system.html>
- 36 **U.S. Food & Drug Administration.** Nextbiomedical Co., Ltd Nexpowder FDA 510k. Available from: https://www.accessdata.fda.gov/cdrh_docs/pdf20/K202929.pdf
- 37 **U.S. Food & Drug Administration.** D Matrix Medical Technology Purastat FDA 510k. Available from: https://www.accessdata.fda.gov/cdrh_docs/pdf21/K210098.pdf
- 38 **D Matrix Medical Technology.** Purastat. Available from: <https://3dmatrix.com/us/purastat/>
- 39 **Ankaferd.** Ankaferd Blood Stopper. Available from: <https://ankaferd.com/en>
- 40 **Kurt M**, Onal I, Akdogan M, Kekilli M, Arhan M, Sayilir A, Oztas E, Haznedaroglu I. Ankaferd Blood Stopper for controlling gastrointestinal bleeding due to distinct benign lesions refractory to conventional antihemorrhagic measures. *Can J Gastroenterol* 2010; **24**: 380-384 [PMID: 20559581 DOI: 10.1155/2010/896819]
- 41 **Bang BW**, Lee DH, Kim HK, Kwon KS, Shin YW, Hong SJ, Moon JH. CEGP-003 Spray Has a Similar Hemostatic Effect to Epinephrine Injection in Cases of Acute Upper Gastrointestinal Bleeding. *Dig Dis Sci* 2018; **63**: 3026-3032 [PMID: 30054842 DOI: 10.1007/s10620-018-5208-z]
- 42 **Alali AA**, Moosavi S, Martel M, Almadi M, Barkun AN. Topical hemostatic agents in the management of upper gastrointestinal bleeding: a meta-analysis. *Endosc Int Open* 2023; **11**: E368-E385 [PMID: 37102185 DOI: 10.1055/a-1984-6895]
- 43 **Vascular Technology, Incorporated.** Doppler for GI Endoscopy. Available from: <https://vti-online.com/specialties/doppler-gi-endoscopy/>
- 44 **Wong RCK.** How to do Doppler Probe EUS for Bleeding. Radiology Key. Available from: <https://radiologykey.com/how-to-do-doppler-probe-eus-for-bleeding/>
- 45 **Satyavada S**, Davitkov P, Akbar Ali M, Cooper G, Wong RCK, Chak A. Endoscopic Doppler Probe in the Diagnosis and Management of Upper Gastrointestinal Hemorrhage. *ACG Case Rep J* 2018; **5**: e68 [PMID: 30280108 DOI: 10.14309/crj.2018.68]
- 46 **Chapelle N**, Martel M, Bardou M, Almadi M, Barkun AN. Role of the endoscopic Doppler probe in nonvariceal upper gastrointestinal bleeding: Systematic review and meta-analysis. *Dig Endosc* 2023; **35**: 4-18 [PMID: 35598171 DOI: 10.1111/den.14356]
- 47 **Chen VK**, Wong RC. Endoscopic Doppler ultrasound versus endoscopic stigmata-directed management of acute peptic ulcer hemorrhage: a multimodel cost analysis. *Dig Dis Sci* 2007; **52**: 149-160 [PMID: 17109216 DOI: 10.1007/s10620-006-9506-5]
- 48 **Barkun AN**, Adam V, Wong RCK. Use of Doppler Probe in Nonvariceal Upper-Gastrointestinal Bleeding Is Less Costly and More Effective Than Standard of Care. *Clin Gastroenterol Hepatol* 2019; **17**: 2463-2470 [PMID: 30772584 DOI: 10.1016/j.cgh.2019.02.016]
- 49 **Han C**, Ling X, Liu J, Lin R, Ding Z. Management of non-variceal upper gastrointestinal bleeding: role of endoscopic ultrasound-guided treatments. *Therap Adv Gastroenterol* 2022; **15**: 17562848211056148 [PMID: 35126666 DOI: 10.1177/17562848211056148]
- 50 **De Angelis CG**, Cortegoso Valdivia P, Rizza S, Venezia L, Rizzi F, Gesualdo M, Saracco GM, Pellicano R. Endoscopic Ultrasound-Guided Treatments for Non-Variceal Upper GI Bleeding: A Review of the Literature. *J Clin Med* 2020; **9** [PMID: 32245209 DOI: 10.3390/jcm9030866]
- 51 **Uribarri-González L**, Pérez-Aguado G, Arrubla Gamboa A, Vila JJ. EUS-guided therapy of nonvariceal refractory bleeding: A prospective observational study. *Endosc Ultrasound* 2022; **11**: 336-337 [PMID: 35708360 DOI: 10.4103/EUS-D-21-00169]



Published by **Baishideng Publishing Group Inc**
7041 Koll Center Parkway, Suite 160, Pleasanton, CA 94566, USA
Telephone: +1-925-3991568
E-mail: office@baishideng.com
Help Desk: <https://www.f6publishing.com/helpdesk>
<https://www.wjgnet.com>

