



# EMPIRICAL PYRIDOSTIGMINE IN A PATIENT WITH DIFFICULT WEANING FROM MECHANICAL VENTILATION AFTER TRAUMATIC BRAIN INJURY

Tariq Siddiqui<sup>1</sup>, Gustav Strandvik<sup>1,2</sup>, Ayman El-Menyar<sup>1,3</sup>, Sandro Rizoli<sup>1</sup>, Hassan Al-Thani<sup>1</sup>

<sup>1</sup> Department of Surgery, Trauma Surgery, Hamad Medical Corporation, Doha, Qatar

<sup>2</sup> Department of Surgery, Weill Cornell Medical College, Doha, Qatar

<sup>3</sup> Department of Clinical Medicine, Weill Cornell Medical College, Doha, Qatar

**Corresponding author:** Ayman El-Menyar **e-mail:** aymanco65@yahoo.com

Received: 19/02/2024 Accepted: 26/02/2024 Published: 25/03/2024

**Conflicts of Interests:** The Authors declare that there are no competing interests.

**Patient Consent:** The Medical Research Center of Hamad Medical Corporation has granted permission for this case report to be published on condition that no patient-identifiable data (including patient name and photograph) are included (IRB: MRC-04-20-225).

**This article is licensed under a Commons Attribution Non-Commercial 4.0 License**

**How to cite this article:** Siddiqui T, Strandvik G, El-Menyar A, Rizoli S, Al-Thani H. Empirical pyridostigmine in a patient with difficult weaning from mechanical ventilation after traumatic brain injury. *EJCRIM* 2024;11:doi:10.12890/2024\_004363.

## ABSTRACT

We present a 30-year-old male who sustained a mild traumatic brain injury and then was intubated due to deterioration of consciousness. A head CT scan revealed mild brain oedema, a fractured nasal bone and mild left thoracic wall haematoma. Despite complete clinical and radiological normalisation within 36 hours, he failed to wean off the ventilator. The patient was found to have subtle bulbar manifestations including dysphonia, dysarthria, and dysphagia, with recurrent left lung collapse. He responded to an empirical pyridostigmine trial despite negative biochemical tests for myasthenia gravis (MG). The patient was weaned successfully from the ventilator, transferred to a long-term care facility, and then discharged home. Classic symptoms and signs of a disease may be absent, but the presence of dysarthria, dysphagia, transient vocal cord palsy, nasal speech, absent gag reflex and respiratory failure in difficult-to-wean patients, with no definitive diagnosis, may warrant an empirical trial of therapy for suspected MG and for the benefit of any doubt.

## KEYWORDS

Traumatic brain injury, myasthenia gravis, empirical pyridostigmine, mechanical ventilation

## LEARNING POINTS

- "Hidden" cranial injuries may account for subtle bulbar symptoms in victims of traumatic brain injury and should be searched for.
- Myasthenia gravis has been reported in association with trauma, which comes first and is often difficult to ascertain.
- A trial of pyridostigmine may be reasonable in difficult-to-wean patients when all other causes have been excluded for the benefit of the doubt.



## INTRODUCTION

Acute respiratory failure is a common reason for critical care admission, and patients are usually weaned and extubated once the reason for intubation has been resolved. However, some may need reintubation, with an associated mortality risk of 51%. Difficulty weaning from ventilation may be due to several factors, most commonly respiratory or cardiovascular compromise. Rarer causes include pre-existing neuromuscular disorders<sup>[1]</sup>. Myasthenia gravis (MG) patients usually have antibodies directed against the muscle acetylcholine receptor (AChR) or antibodies against muscle-specific kinase (MuSK). Patients with no autoantibodies to AChR and MuSK receptors are known as seronegative MG (SnMG)<sup>[2]</sup>. Myasthenia gravis or MG-like diagnosis has been reported in association with trauma, which comes first and is often difficult to ascertain. However, investigations may be negative for MG, and empirical treatment trials should be considered, particularly if there is a failure to wean off mechanical ventilation. This case report follows the CARE reporting checklist.

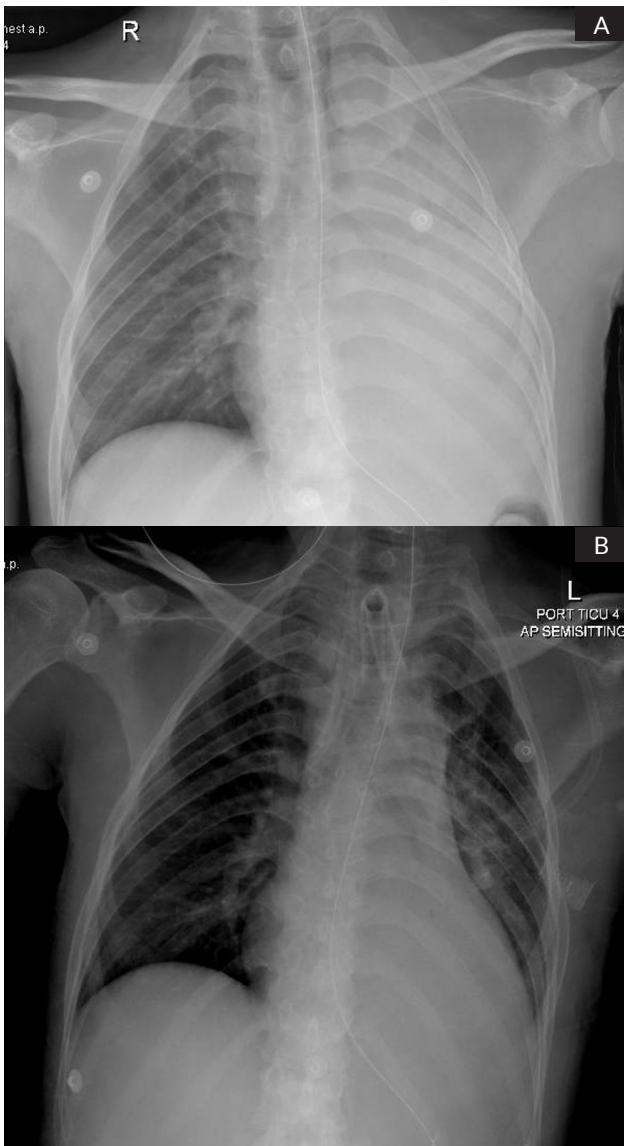


Figure 1. A) Chest X-ray showing left lung collapse; B) Post bronchoscopy and removal of secretions.

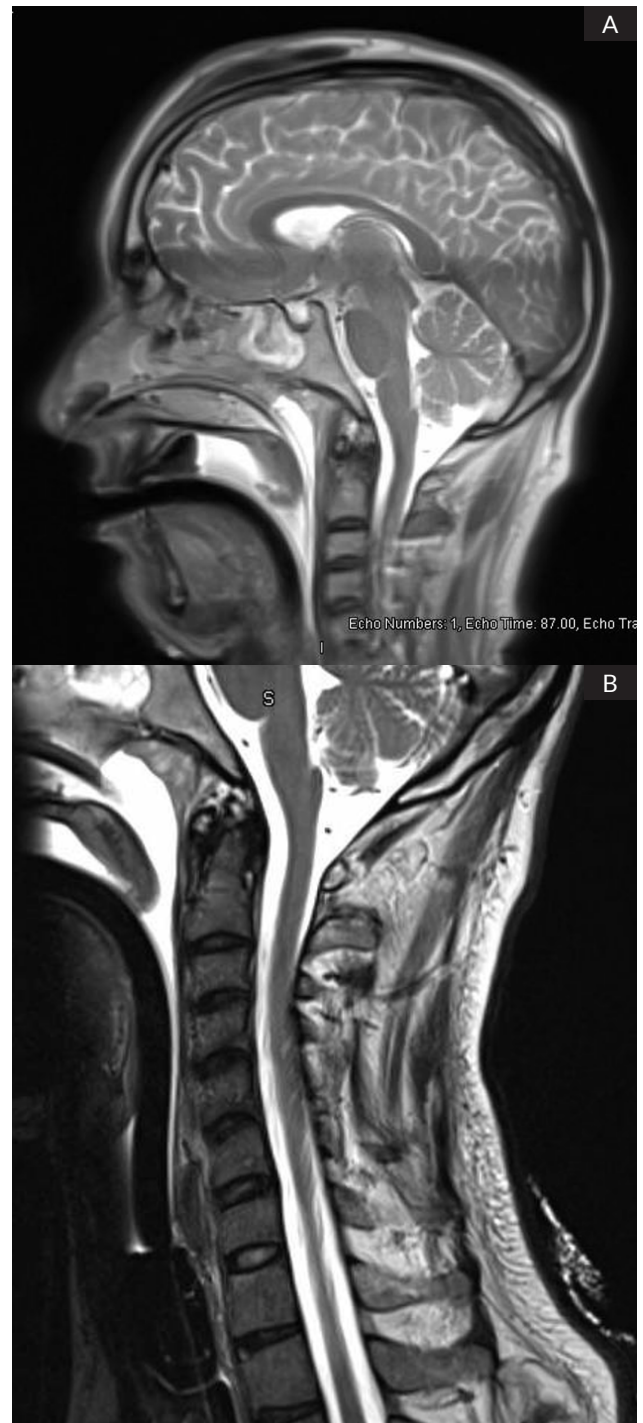


Figure 2. MRI of A) brain and B) spine.

## CASE DESCRIPTION

A 30-year-old male with no past medical history was brought to the emergency department following a 1.5-metre fall. He complained of headache, itchy eyes and generalised body pain and was found to have a weak voice, a pulse rate of 117 bpm, a respiratory rate of 36, blood pressure of 150/94 mmHg and SpO<sub>2</sub> 98% (on nasal cannula oxygen). His Glasgow Coma Score (GCS) was 14, with reactive pupils and normal limb movement. The GCS dropped to 9, and the patient was intubated.

A pan CT scan revealed a temporofrontal subgaleal haematoma, nasal bone fracture and mild cerebral oedema. He was extubated in the evening of day 2 after a successful

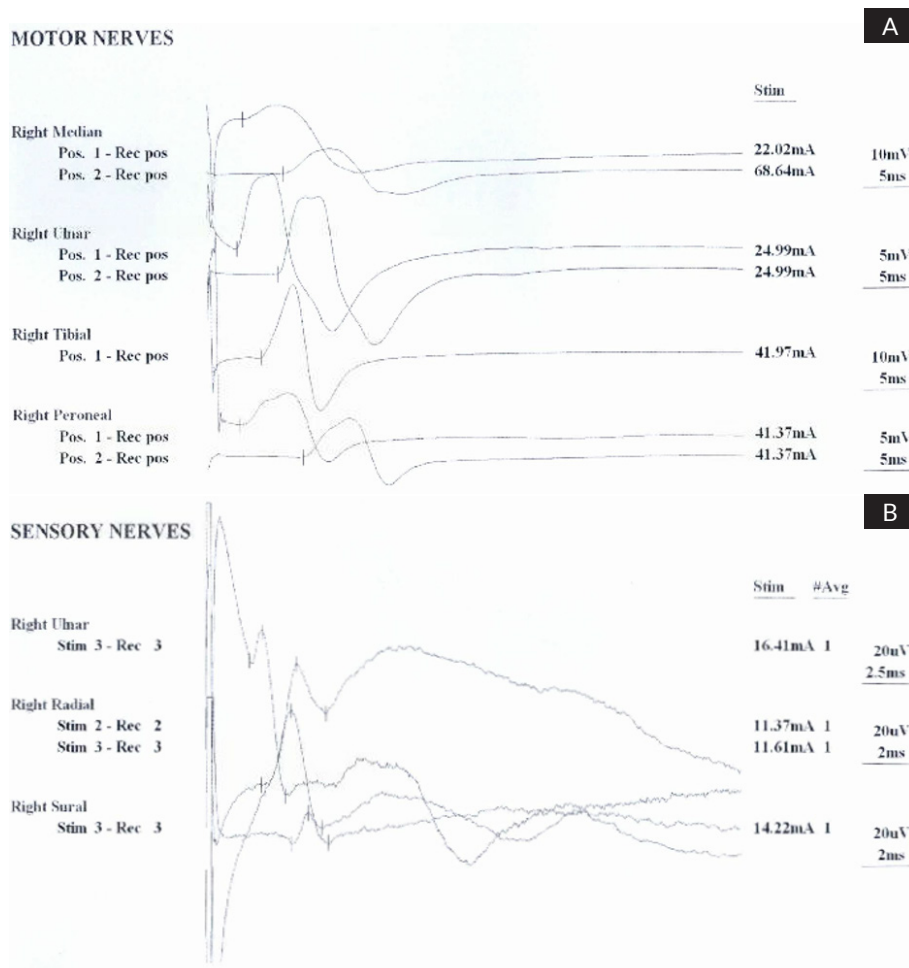


Figure 3. A) Normal motor nerve conduction and EMG of upper and lower limbs; B) Normal sensory nerve conduction and EMG of upper and lower limbs.

spontaneous breathing trial (SBT). Post-extubation, the patient had a weak voice with a GCS of 14. The heart rate was 110 bpm, respiratory rate was 18 b/min and SpO<sub>2</sub> was 100% (FiO<sub>2</sub> was 40%). He quickly became unresponsive with GCS 4 and was reintubated. On the next day, GCS was E4/M6 V(T) (i.e., intubated) with an absent gag reflex. Further investigations of the cervical spine and left hemidiaphragm were normal. He was extubated after an SBT trial with continuous positive airway pressure (CPAP) and a T-piece after a few days. Post-extubation, his GCS was E4V1M6. He was desaturated again after one hour with a high-flow nasal therapy at flow rates of 50 l/min and FiO<sub>2</sub> 40%. A chest X-ray at this point revealed left lung collapse (Fig. 1A and 1B). PCO<sub>2</sub> was again high, and he was reintubated; a percutaneous dilational tracheostomy was performed (day 9 of TICU admission). He received aggressive chest physiotherapy, left lateral position, bronchodilators, and CPAP.

Fibre-optic examination revealed oedema of the epiglottis and sluggish weak movement of the left vocal cord. Repeating a chest CT scan did not reveal any diaphragm injury.

A multidisciplinary team was formed with neurology and pulmonology subspecialties for prolonged weaning. An EEG study to exclude non-convulsive status epilepticus was normal, and polysomnography did not suggest central apnoea. Acetylcholine receptor antibodies and anti-MuSK antibodies were negative; an MRI of the brain and cervical spine showed no significant lesions (Fig. 2).

Physiotherapy with slow weaning on a portable ventilator with transcutaneous EtCO<sub>2</sub> monitoring, as well as muscular effort monitoring, was instituted. The patient suffered recurrent left lung collapse during weaning that was resolved after the bronchoscopic removal of thick mucus plugs. Sixty days later, pyridostigmine 60 mg bid was empirically started. After receiving pyridostigmine, the patient began to tolerate longer periods off the ventilator without lung collapse. Within four days, the patient was tolerating 6 hours off the ventilator per shift. On reducing the dose of pyridostigmine, the patient was placed back on the ventilator because of high carbon dioxide and tachypnoea. Reinstating a higher dose of pyridostigmine resulted in significant improvement again. Gradually, the patient was weaned off the ventilator and was transferred to a high-dependency unit. He required a further three weeks for the management of panic and breathing rehabilitation. He was transferred to the ward 136 days post-admission, on pyridostigmine bromide 60 mg orally every 6 hours.

A repeat nerve simulation test (RNS) did not show any evidence of neuromuscular junction disorder, and no large fibre polyneuropathy (Fig. 3).

The possibility of toxic bulbar palsy (i.e. botulism) was excluded, and the pyridostigmine was tapered gradually. He slowly improved, the tracheostomy was removed, and he was transferred to a long-term facility. He tolerated a full diet, and his speech improved. He was discharged after more than

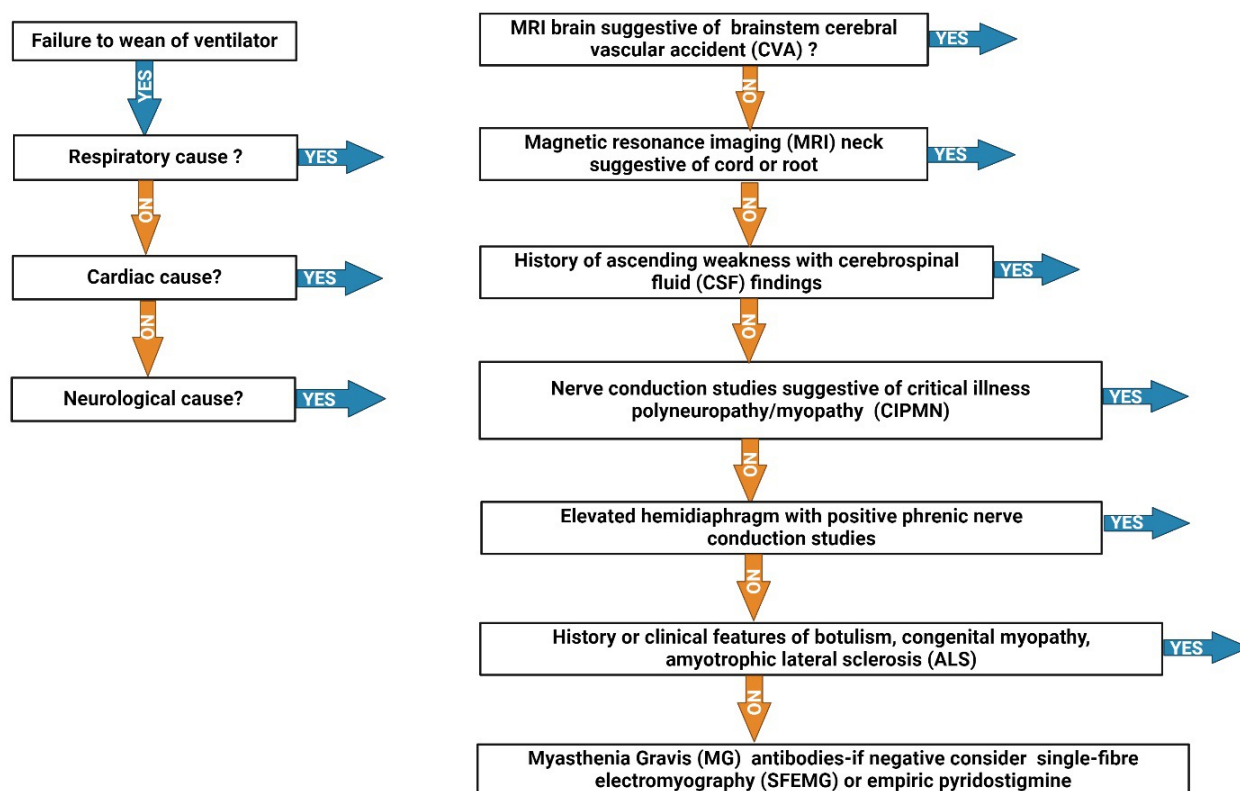


Figure 4. Algorithm for failure to wean off mechanical ventilator: If YES, proceed to appropriate therapy.

four months and was completely well; he left the country for good. One of the trauma teams contacted the patient's family to follow up on his health status and was told that he was not on regular pyridostigmine. Unfortunately, he subsequently collapsed in his country and went into respiratory arrest, for which he was intubated and then passed away.

## DISCUSSION

This is a case of difficult weaning from mechanical ventilation without a definable respiratory or cardiac cause. The patients' response to empirical pyridostigmine suggested a diagnosis of MG despite specific tests being negative. Differential diagnoses are presented in Table 1.

Possible aetiologies	Factors supporting/refuting diagnosis
Guillain-Barre syndrome	Reflexes preserved Cerebrospinal fluid – normal Nerve conduction studies – no conduction blocks
Brain stem stroke	MRI of the brain – normal
Cervical cord compression	MRI of the cervical spine – normal
Phrenic nerve injury	CT of the thorax – normal Phrenic nerve conduction study normal EMG diaphragm normal
Motor neurone disease	Short history No fasciculations Electromyography – normal
Myopathy	Electromyography – normal
Botulism	No pupillary changes No symmetric descending weakness No bradycardia No symmetric neurological deficits
Congenital myasthenia syndrome	No childhood or family history
Critical illness polyneuropathy	Negative

Table 1. Differential Neurological Diagnoses

MG can be a difficult condition to diagnose due to its variable presentation; the fluctuating nature of the weakness often results in initial misdiagnosis. Michalska et al. presented 11 cases of MG, where dysphonia was the only symptom of illness; this was present for several years before the diagnosis was made<sup>[3]</sup>. Bulbar symptoms as the presenting feature are rare presentations of the disease in approximately 6% of patients<sup>[4]</sup>.

Inoue et al. reported a case of MG, which presented solely with bulbar palsy not associated with easy fatigability or limb weakness, but with paresis of the soft palate associated with marked dysphagia and rhinolalia<sup>[5]</sup>.

Our patient had a negative test for antibodies and electromyography. RNS testing was negative; however, the literature suggests that only 70% of patients will be positive with RNS testing<sup>[6]</sup>. Pyridostigmine improved the patient's symptoms and allowed weaning in our case. This unique result led us to believe that our patient suffered from seronegative MG associated with trauma. Sethi et al. described a similar case<sup>[7]</sup>. Llabrés et al. reported three cases of MG who presented with dysphagia as the sole feature of MG. Antibody testing was negative, and repeated nerve stimulation tests were normal<sup>[8]</sup>.

Single-fibre EMG is 95% sensitive and appears to be indispensable in the diagnostic evaluation of seronegative patients with MG in whom repetitive stimulation is normal, but it could not be done in our case for logistic reasons<sup>[9]</sup>. Figure 4 shows the algorithm to follow in case of difficulty in weaning from a mechanical ventilator. We were unable to make a definite diagnosis for this patient as tests for MG were negative. However, we relied on the clinical bulbar manifestations and dramatic response after pyridostigmine use that enables the successful extubation and the development of respiratory distress after pyridostigmine discontinuation. Unfortunately, single-fibre electromyography, which could help in making a definite diagnosis, was not available.

## CONCLUSION

Although ocular features of myasthenia were absent in our patient, the presence of dysarthria, dysphagia, transient vocal cord palsy, nasal speech, absent gag reflex and respiratory failure suggested the clinical diagnosis of MG. Isolated bulbar symptoms may occur in younger patients; these symptoms are potentially reversible with treatment. "Hidden" cranial injuries may account for subtle bulbar symptoms in victims of traumatic brain injury and should be searched for. A trial of pyridostigmine may be reasonable in difficult-to-wean patients when all other causes have been excluded, for the benefit of doubt. However, further studies are needed.

---

## REFERENCES

1. Windisch W, Dellweg D, Geiseler J, Westhoff M, Pfeifer M, Suchi S, et al. Prolonged weaning from mechanical ventilation. *Dtsch Arztebl Int* 2020;**117**:197–204.
2. Lazaridis K, Tzartos SJ. Autoantibody specificities in myasthenia gravis; implications for improved diagnostics and therapeutics. *Front Immunol* 2020;**11**:212.
3. Michalska T, Rowińska-Marcińska K, Strugalska H, Maniecka-Aleksandrowicz B, Emeryk-Szajewska B. Myasthenia preceded by dysphonia. Clinical and electrophysical study. *Neurol Neurochir Pol* 1996;**30**:783–796.
4. Mantegazza R, Baggi F, Antozzi C, Confalonieri P, Morandi L, Bernasconi P, et al. Myasthenia gravis (MG): epidemiological data and prognostic factors. *Ann N Y Acad Sci* 2003;**998**:413–423.
5. Inoue M, Kojima Y, Kinboshi M, Nakagawa T, Kanda M, Shibasaki H. A case of myasthenia gravis presenting solely with bulbar palsy unassociated with easy fatigability. *Rinsho Shinkeigaku* 2013;**53**:229–234.
6. Blanco-Hernández T, Navarré-Gimeno A, Brocalero-Camacho A, Cervelló-Donderis A, López-Trigo J, Ortiz-Sánchez P, et al. Methods for diagnosing seronegative myasthenia gravis. *Rev Neurol* 2008;**46**:360–364.
7. Sethi PK, Batra A, Sethi NK, Torgovnick J, Arsur E. Vocal cord palsy: an uncommon presenting feature of myasthenia gravis. *Ann Indian Acad Neurol* 2011;**14**:42–43.
8. Llabrés M, Molina-Martinez FJ, Miralles F. Dysphagia as the sole manifestation of myasthenia gravis. *J Neurol Neurosurg Psychiatry* 2005;**76**:1297–1300.
9. Sanders DB, Stålberg EV. AAEM minimonograph #25: single-fiber electromyography. *Muscle Nerve* 1996;**19**:1069–1083.