

Protective Effect of Co Q10 and Candesartan on Bleomycin Induced Lung Fibrosis in Rats

Fatima Mohammad Saeed Mahdi *, Mustafa Ghazi Alabbassi **, Muthanna Ibrahim Al-Ezzi **.

**Department of Pharmacology and Toxicology, College of Pharmacy, Mustansiriyah University, M.Sc. program, Iraq.*

***Department of Pharmacology and Toxicology, College of Pharmacy, Alkafeel university, Iraq.*

****Department of Clinical Laboratory Sciences, College of Pharmacy, Mustansiriyah University, Iraq.*

DOI

Article Info:

Received 31 Aug 2020

Accepted 23 Dec 2020

Published 1 Mar 2021

Corresponding Author email:

prof.dr.mustafaghazi@alkafeel.edu.iq

[orcid: https://orcid.org/0000-0002-5622-958](https://orcid.org/0000-0002-5622-958)

Abstract:

Fibrosis of the lungs is the final phase of many lung illnesses. Its characterized by excessive matrix production leading to the normal lung architecture destruction and eventually death. CoQ10 is an essential constituent of membrane oxidoreductase System. It is an intracellularly localized antioxidant

enzyme that is endogenously synthesized in humans. CoQ10 protects cellular components from destruction by free radical-induced oxidative damage. candesartan is a selective antagonist of angiotensin II type 1 receptor (AT1) and is widely employed for treatment of hypertension. Most up to date research shows angiotensin II close involvement with damage and fibrosis process in tissues of organs of circulation.

Objective: This animal study was designed to investigate the effect of Co Q10 and candesartan as antifibrotic agents against pulmonary fibrosis focusing on selected markers involved in pulmonary fibrosis.

Materials and Method: 48 rats divided randomly into four groups, each consisting of 12 male rats. Group I: (Control group), the rats in this group received single injection of 0.2 ml normal saline via intratracheal route. Group II: (The BLM group), received BLM (8.3 U/kg) as a single dose via the intratracheal rout. Group III: (BLM+CoQ10 group) rats receive BLM (8.3 U/kg) as sulfate salt dissolved in 0.1 ml of normal saline via the intratracheal instillation concomitant with 100 mg/kg co Q 10 per day orally for 5 days before and 10 days after BLM injection. Group IV: (BLM+ candesartan group) rats receive BLM (8.3 U/kg) as sulfate salt dissolved in 0.1 ml of normal saline via the intratracheal instillation concomitant with (10 mg/kg) candesartan per day orally for 5 days before and 10 days after BLM injection. The studied serum biomarkers were glutathione, arachidonate 5 lipoxygenase in addition to histopathological examination using trichrome stain.

Results: serum GSH concentration was lower in BLM group in comparison with the control group and the (BLM+ CoQ10) but this difference is not statistically significant. The serum GSH levels showed a significant(P<0.05) elevation in (BLM+ Candesartan) group when compared with the levels in the BLM group. The serum ALOX5 concentration was significantly elevated in BLM group in comparison with the control group (P < 0.05). The serum ALOX5 levels were highly significantly lower in (BLM +CoQ10) (P < 0.01) and very highly significantly lower in the (BLM+ Candesartan) group (P < 0.001) when comparing it

with the levels in the BLM group. furthermore, histologically CoQ10 and candesartan showed reduction in the numbers of inflammation cells and a decrease in the damage to the lung architecture and fibrosis induced by bleomycin.

Conclusion: CoQ10 and candesartan decrease pulmonary fibrosis induced by bleomycin in male rats.

Key words: pulmonary fibrosis, bleomycin, CoQ10, candesartan, glutathione, arachidonate 5 lipoxygenase.

تأثير الحماية للكوكيو 10 والكانديسارتان على التليف الرئوي المحدث عن طريق البليومايسين في الجرذان الذكور

فاطمة محمد سعيد مهدي *، مصطفى غازي العباسي **، مثنى إبراهيم العزي **
*الدراسات العليا، فرع الأدوية والسموم، كلية الصيدلة، الجامعة المستنصرية
**فرع الأدوية والسموم، كلية الصيدلة، الجامعة المستنصرية
***** فرع العلوم المختبرية السريرية، كلية الصيدلة، الجامعة المستنصرية.

الخلاصة:

التليف الرئوي هو المرحلة النهائية لكثير من أمراض الرئة. يتميز بتأليف أنسجة الرئة وندوبها مما يؤدي إلى تدمير بنية الرئة الطبيعية وصعوبة التنفس تدريجياً وأخيراً الموت. الكوكيو عشرة هو أحد المكونات الأساسية في السلسلة التنفسية وهو انزيم مضاد للأوكسدة يصنع داخل الجسم ويلعب دوراً مهماً في حماية بروتينات بيوت الطاقة والفسفوليبيدات ومكونات خلوية أخرى من التأثير المدمر للجذور الحرة. الكانديسارتان هو مضاد انتقائي لمستقبل الانجيوتنسين اثنان النوع الأول ويستخدم لعلاج ارتفاع الضغط في الاوعية الدموية حيث اثبتت الدراسات الحديثة ضلوع الانجيوتنسين الثاني في احداث الضرر وتليف الانسجة في أعضاء الدورة الدموية.

طريقة العمل: تم تقسيم ثمانية واربعون ذكراً من فصيلة فنران ويستر البيضاء عشوائياً إلى أربع مجموعات كل مجموعة مكونة من 12 فار؛ المجموعة 1 مجموعة الضبط تشمل الحيوانات التي اعطيت 0.1 مل من محلول ملحي عن طريق حقنها داخل القصبة الهوائية المجموعة 2 مجموعة البليومايسين تشمل الحيوانات التي اعطيت 8.3 وحدة من البليومايسين كجرعة واحدة داخل القصبة الهوائية 2 المجموعة الثالثة مجموعة الكوكيو عشرة تشمل الحيوانات التي استلمت الكوكيو عشرة بجرعة 100 ملغ لكل كغم لخمس أيام قبل جرعة البليومايسين وعشرة أيام بعدها. المجموعة الرابعة مجموعة الكانديسارتان تلقت الكانديسارتان فموياً بجرعة 10 ملغ لكل كغم لمدة 5 أيام قبل وعشرة بعد جرعة البليومايسين. تم التضحية بجميع الحيوانات وجمع رنتيها للفحص النسيجي وقياس العلامات الحيوية. المؤشرات الحيوية المدروسة هي الجلوتاثيون، أراكيدونات 5 لبيوكسجيناز بالإضافة إلى الفحص النسيجي باستخدام اللوحة الثلاثية. النتائج: اظهرت النتائج ان المعالجة باستخدام مادة ال CoQ10 في المجموعة الثالثة و كانديسارتان في المجموعة الرابعة أدى الى انخفاض ملحوظ ($P < 0.05$) في مستويات المصل من ALOX5 وارتفاع ملحوظ ($P < 0.05$) في المستوى المصلي للجلوتاثيون مقارنة مع المستوى في المجموعة الثانية (مجموعة بليومايسين). كشف الفحص النسيجي أن التليف في المجموعة 2 كان أكثر حدة بشكل ملحوظ وأن تسلسل الخلايا الالتهابية مرتفع إلى حد كبير بالمقارنة مع المجموعة 3 و 4 التي أظهرت القليل فقط من عدم وجود تليف وتسلسل ضئيل للغاية للخلايا الالتهابية، وفي المجموعة 1 بدا طبيعياً مع عدم وجود التليف أو التسلسل الالتهابي. الاستنتاج: CoQ10 وكانديسارتان يخففان التليف الرئوي الناجم عن بليومايسين في فنران ويستر الذكور. الكلمات المفتاحية: التليف الرئوي، البليومايسين، الكوكيو عشرة، الكانديسارتان، الكلوتاثيون، ALOX5.

Introduction

Fibrosis of the lungs (PF) is the final phase of many lung illnesses. Its characterized by excessive matrix production leading to the lung architecture destruction and eventually death [1]. Pulmonary fibrosis occurs when there is damage to the pulmonary tissue and a fibrotic reaction ensues that leads to thickening of the

alveolar walls and obliteration of the alveolar air spaces. Its etiology could be not known or could be one of the [2] various chemical toxins and other injuries well known to cause pulmonary fibrosis [3]. The principle histological marks of pulmonary fibrosis are continuing and non-repaired epithelial injury, proliferation and buildup of myofibroblasts and fibroblasts, and collagen deposition increase [4].

Pulmonary fibrosis is considered as a disease caused by repeated subclinical injury leading to epithelial injury and subsequent destruction of the alveolar-capillary basement membrane [5]. This process promotes the infiltration of fibrotic cells and the activation of (myo)fibroblasts. The usual clearance of inflammatory and mesenchymal cells by phagocytosis and apoptosis is dysregulated in pulmonary fibrosis [6]. This leads to the damage to the architecture of the normal lung and function loss.

Transforming growth factor β (TGF- β) is considered as the most potent profibrotic mediator described until this date which induce pulmonary fibrosis via the recruitment and activation of fibroblasts and monocytes, and promotes ECM production. Lung fibroblast proliferation occurs indirectly by TGF- β 1 through induction of fibroblast growth factor-2 and consequently activating the mitogen-activated protein kinase (MAPK) pathway [7]. additionally, TGF- β promotes fibroblasts to differentiation to myofibroblasts. TGF- β induces ECM formation by induction of ECM gene transcription, including fibronectin, collagen and proteoglycans and by inhibiting the actions of matrix metalloproteinases, elastases and plasminogen activators which leads to the inhibition of degradation of collagen (1).

Bleomycin is a member of a group of antimicrobial and antineoplastic glycopeptides. The agent is widely used to treat a variety of malignant tumors. Although bleomycin generally lacks toxicity in normal hematopoietic cells, a serious adverse reaction associated with the drug is pulmonary toxicity [8]. Bleomycin has been investigated to induce pulmonary fibrosis in animal studies. The bleomycin toxicity is instigated by oxidative damage directly to the pulmonary tissue, which later advances to inflammatory and fibrotic response. The damage is caused by generating

extracellular and intracellular reactive oxygen species (ROS) [9]. BLM can cause DNA strand scission in the attendance of Fe and O₂ elements, leading to double or single strand breaks and resulting in more ROS and reactive nitrogen species (RNS) formation, which explains the antineoplastic effects of bleomycin [10].

Co enzyme Q10 (CoQ10) is a lipid soluble molecule available in the cell membrane of every mammalian cell type [11]. Since CoQ10 can reversibly accept or give 2 electrons to form hydroquinone or benzoquinone, respectively, it is a key component in the mitochondrial electron transport chain playing an important role in the formation of cellular adenosine triphosphate (ATP) [12]. CoQ10 is also an essential constituent of membrane oxidoreductase System. It is an endogenously synthesized intracellular antioxidant enzyme in the human body. CoQ10 protects cellular components from free radical-induced oxidative cell destruction [13].

Candesartan is an angiotensin II type 1 receptor (AT1) selective antagonist and is widely employed in treating hypertension [14]. Studies indicate that angiotensin II has close involvement in damage to tissues and fibrogen formation in the organs of circulation. It's been reported that Angiotensin II promotes proliferation and synthesis of collagen from cardiac fibroblasts this action was inhibited by AT1 antagonists [15]. The fibrosis progression has close relation to a complex network comprised of several chemical mediators, cytokines, growth factors (GF), and biophysical peptides derived from inflammatory immune cells, endothelial cells and alveolar type II cells. Since Ag II is a member of this network, an angiotensin II pathway has been reported to be involved with PF [16]. A high level of ACE has been reported in bronchoalveolar lavage (BAL) fluid from individuals with idiopathic pulmonary fibrosis [17]. Radiation induced lung fibrosis in animal model, revealed that the levels of ACE and

angiotensin II were elevated in pulmonary tissue homogenates [16]. These investigations show that the process of lung fibrosis is induced by a local renin-angiotensin system in the pulmonary tissue. proof that AT1 is situated not just in the cardiac and renal tissues but also in the pulmonary tissue supports this theory. Human pulmonary fibroblasts were elevated by induction of angiotensin II with AT1[18]. Giving AT1 antagonist greatly reduced radiation caused lung fibrosis. All in all, the proof from the following investigations suggest that Ag II is a key factor in the induction of lung fibrosis, and AT1 is an essential receptor for angiotensin II signaling transmission [19]. Moreover, angiotensin II is closely involved with TGF- β 1 formation in fibrosis of the heart and kidney which indicates that Ag II promotes fibrosis in pulmonary fibrosis models by inducing TGF- β 1 production via AT1. Promoting TGF- β 1 synthesis are mediated by the (AT1) receptor in vivo and in vitro [20]. This study aimed to assess the potential protective role of Co Q10 and candesartan as antifibrotic agent against pulmonary fibrosis induced by bleomycin.

Materials and Methods:

Study Design: Forty-eight rats were divided randomly into four groups, each consisting of 12 male rats: Group I: (Control group), the rats in this group received single injection of 0.2 ml normal saline via intratracheal route. Group II: (The BLM group), received BLM (8.3 U/kg) as sulfate salt dissolved in 0.1 ml of normal saline as a single dose via the intratracheal rout. Group III: (BLM+CoQ10 group) rats receive BLM (8.3 U/kg) as sulfate salt dissolved in 0.1 ml of normal saline via the intratracheal instillation concomitant with 100 mg/kg co Q 10 per day orally for 5 days before and 10 days after BLM injection. Group IV: (BLM+ candesartan group) rats receive BLM (8.3 U/kg) as sulfate salt dissolved in 0.1 ml of normal saline via the intratracheal instillation concomitant with

(10 mg/kg) candesartan per day orally for 5 days before and 10 days after BLM injection.

Induction: Acute Pulmonary fibrosis was induced by intratracheal instillation of BLM (8.3 U/kg) as sulfate salt dissolved in 0.1 ml of normal saline to a healthy male albino rat (21). Rats anesthetized using ketamine (45mg/kg) and xylazine (8mg/kg) I.P.) [22]. A midline incision made in the neck, the trachea exposed and BLM instilled. Rats should be kept in vertical position and rotated several times to ensure uniform distribution of BLM within the lung tissues. The incision should be surgically sutured and povidone iodine applied topically to the wound [21].

Sample Collection and Preparation: A blood sample collected by using heart puncture, put in plain gel tube and centrifugation at 3000x for fifteen minutes. The serum was stored at -80°C in preparation for ELISA analysis where glutathione and ALOX5 were measured in serum according to manufacturer instruction (Mybiosource - USA), then sacrificed the rats by using ketamine and xylazine for anesthesia, then removed the lungs and washed by distilled water, then the lung tissue kept in 10%formaline to prep for trichrome stain.

Statistical Analysis: The statistical analysis was done via utilizing the 16.0 version of SPSS. Every single result was described as mean \pm standard deviation (SD). To differentiate between group results, the One-way ANOVA test was utilized, and a post hoc LSD test followed. For the data when the $P < 0.05$ the Statistically significant differences were confirmed, when $P < 0.01$ high significant difference and when the $P < 0.001$ very high significant differences was considered.

Results:

Glutathione: The descriptive statistics for serum GSH conc. which is described as mean \pm SD (table 1). BLM group (78.06 \pm 8.89, μ g /ml) showed non-significant difference when compared with control group and the (BLM+ CoQ10)

group (83.15±5.47, 82.31±3.81 µg/ml, respectively) (P >0.05). The serum GSH levels showed a significant elevation in (BLM+ Candesartan) group (86.91±3.52 µg/ml; P >0.05) when comparing it with the levels in the BLM group

(78.06±8.89µg/ml; P >0.05). serum GSH concentration showed non-significant differences (P >0.05) in both (BLM +CoQ10) and (BLM+ Candesartan) group in compare with the control group. as shown in figure (1).

Table (1): Effect of CoQ10 and Candesartan on glutathione GSH level in BLM induced lung toxicity

| Group | GSH (µg/ml) Mean ± SD |
|-----------------------------|-----------------------|
| Group I (Control) | 83.15±5.47 |
| Group II (BLM) | 78.06±8.89* |
| Group III (BLM+ CoQ10) | 82.31±3.81 |
| Group IV (BLM+ Candesartan) | 86.91±3.52 |

Each value expressed as mean ±SD. The statistical analysis done by using one-way ANOVA followed by LSD test.

* significant difference (*p* < 0.05) when comparing BLM group with (BLM + Candesartan) group.

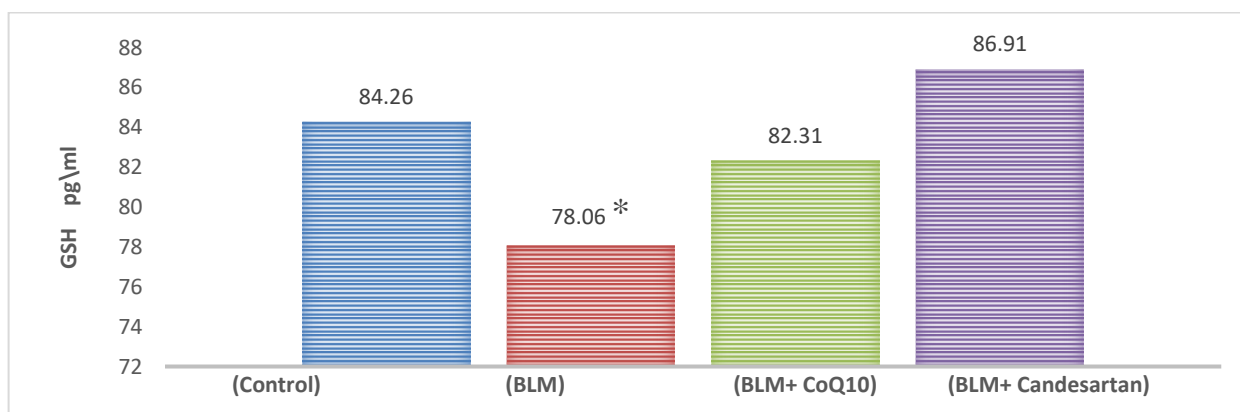


Figure (1): Effect of CoQ10 and Candesartan on serum GSH level in BLM induced lung toxicity values are expressed as mean ±SD. The statistical analysis was performed by applying one-way ANOVA followed by LSD test.

* significant difference (*p* < 0.05)

high significant difference (*p* < 0.01)

Group I (Control), Group II (BLM), Group III (BLM+ CoQ10), Group IV (BLM+ Candesartan)

ALOX5: The descriptive statistics for serum ALOX5 concentration which is represented as mean ± SD (table 2) was significantly higher in BLM group (1.07±0.39, ng/ml) when compared with the control group (0.73±0.22, ng/ml; P < 0.05). The serum ALOX5 levels were significantly lower in (BLM

+CoQ10) (0.61±0.31pg/ml; P < 0.01) and significantly less in the (BLM+ Candesartan) group (0.39±0.08pg/ml; P < 0.001) when compared with the levels in the BLM group (0.68±0.19). serum ALOX5 concentration showed non-significant differences (P >0.05) in both (BLM +CoQ10) and (BLM+ Candesartan) group in compare with

the control group. as shown in figure (2).

Table (2): Effect of CoQ10 and Candesartan on ALOX5 level in BLM induced lung toxicity

| Group | ALOX5(ng/ml) |
|-----------------------------|--------------|
| Group I (Control) | 0.73±0.22 |
| Group II (BLM) | 1.07±0.39*# |
| Group III (BLM+ CoQ10) | 0.61±0.31 |
| Group IV (BLM+ Candesartan) | 0.39±0.08 |

Values are expressed as mean ±SD. The statistical analysis done by applying one-way ANOVA followed by LSD test.

* significant difference (p < 0.05) when comparing BLM with control group.

high significant difference (p < 0.01) when comparing (BLM + CoQ10) and (BLM + Candesartan) group with BLM group.

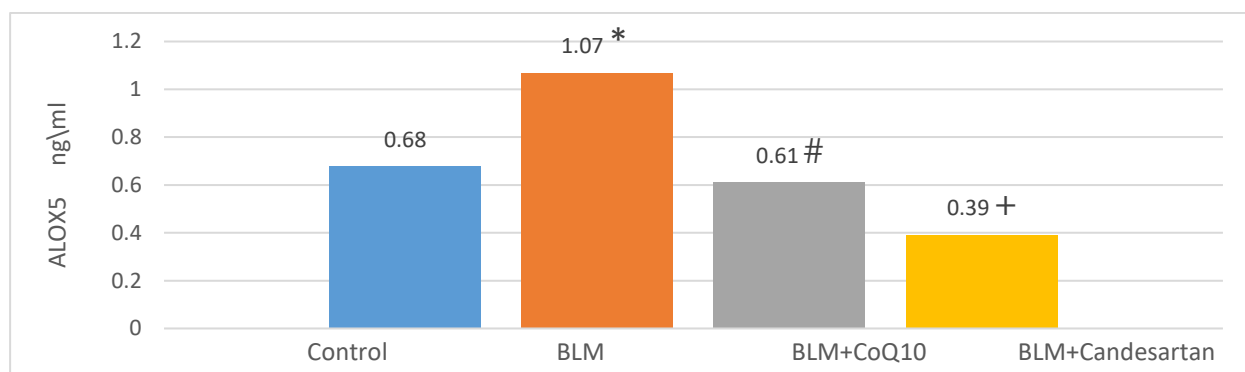


Figure (2): Effect of CoQ10 and Candesartan on serum ALOX5 level in BLM induced lung toxicity all values are expressed as mean ±SD. The statistical analysis done by applying one-way ANOVA followed by LSD test.

* significant difference (p < 0.05)

high significant difference (p < 0.01)

Group I (Control), Group II (BLM), Group III (BLM+ CoQ10), Group IV (BLM+ Candesartan)

Histological changes CoQ10 and Candesartan both showed reduce in the collagenous fibers production in BLM pulmonary toxicity. All groups results are shown below:

A. Control group: the lung tissue in control group appear normal with no collagen fibers as in figure (3-A).

B. BLM group: the lung tissue in BLM group showed a moderate to severe inflammation and moderate peribronchial fibrosis (3-B).

C. (BLM+CoQ10) group: the lung tissue in this group showed a

moderate to severe inflammation and moderate peribronchial fibrosis the cardiac tissue in this group showed only mild inflammation and a mild peribronchial fibrosis as in figure (3-C).

D. (BLM +Candesartan) group: the lung tissue in this group appear to have a moderate to severe inflammation and moderate peribronchial fibrosis as shown in figure (3-D).

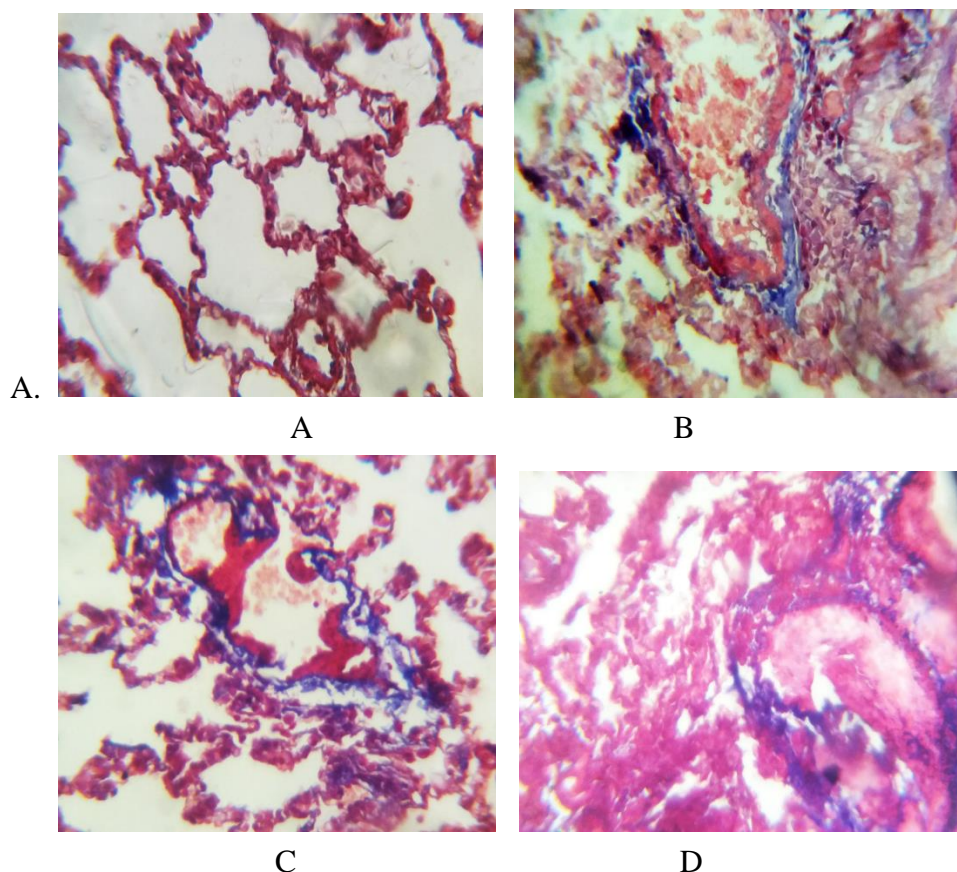


Figure (3): microscopic image of fibrosis in lung tissue with trichrome stain X400 (A) control (B) bleomycin group (C) CoQ10 treated group (D) candesartan treated group.

Discussion:

Glutathione is part of the thiol redox system. Redox systems keep the reducing state of the cell by electron transfer. glutathione is commonly referred to as the main cellular antioxidant, however the role of GSH is more than just an antioxidant, it also has many other essential cellular functions, including xenobiotic detoxification, cell proliferation modulation, storage and transport of cysteine and redox status maintenance [23]. GSH levels is used as the main indication of cellular redox state since the GSH pool is roughly three to four folds more abundant than other major redox couples [24, 25].

This study revealed that BLM decrease the level of the antioxidant GSH and that both CoQ10 and candesartan caused significant increase ($P < 0.05$) in plasma GSH level. Chen *et al* and Mcmillan *et al* (2016),

showed that treatment with bleomycin causes a decrease in the GSH levels in the blood since bleomycin induces injury by increasing oxidative stress [26, 27] which agrees with our results. Thanh *et al* (2016), Lone *et al* (2017), showed that CoQ10 reversed the decrease in GSH levels as a result of oxidative damage which agrees with our findings [28]. Muda *et al* (2005), Tamuli *et al* (2015), Uduman *et al* (2016) demonstrated that GSH levels increase with candesartan treatment [29-31].

Arachidonate 5-lipoxygenase is a member of the lipoxygenase family of enzymes. It forms leukotrienes [32] substrates as well as forming various other biologically active products from essential fatty acids. ALOX-5 plays an essential part in asthma and inflammation. This enzyme promotes bronchiole constriction in response to cysteinyl leukotrienes which leads asthma. It promotes neutrophilic inflammation as

well^[33]. Leukotrienes are arachidonic acid metabolites and they are important regulators of lung fibrosis. The production of LTB₄ and cysteinyl LT (cysLT) are catalyzed by ALOX-5. LTB₄ plays a great part in the host defense system against invasion by foreign bodies and infection. LTB₄ is regarded as a cause of various inflammatory disorders, and it is synthesized by alveolar cells in patients with idiopathic pulmonary fibrosis. This enzyme is responsible for converting arachidonic acid into the leukotrienes LTB₄ and LTC₄. These leukotrienes have inflammatory and fibrotic properties and are upregulated in the lungs of IPF patients^[34]. This study revealed that BLM increased the level of the inflammatory mediator ALOX-5 and that both CoQ10 and candesartan caused significant reduction ($P < 0.05$) in plasma ALOX-5 level. BLM was shown to increase oxidative stress and thus cause an increase in the levels of inflammatory mediators like ALOX-5. This was confirmed by Wiley *et al* (2019)^[35]. Tsai *et al* (2011), showed significant reduction of ALOX-1 level by oral CoQ10 supplementation, they support that CoQ10 has significant antioxidant and protective effects on cell injury^[36]. to our knowledge this is the first study on the effect of Co Q10 and candesartan on ALOX-5 levels.

The pulmonary tissue in the control group of this study is normal showing the absence of inflammatory cell infiltration and no fibrosis. the BLM group showed moderate to severe infiltration of inflammatory cells and fibrotic lesions. On the other hand, both (BLM + CoQ10) and (BLM + Candesartan) groups showed only mild inflammatory cell infiltration and mild fibrosis. Swaisgood *et al*(2000), showed that BLM causes changes on normal morphology of pulmonary cells and mononuclear cells infiltration due to the action of oxidative stress that considered as an indication for pulmonary injury and dysfunction^[37]. zaghoul *et al*(2017), showed that BLM 5mg /kg single dose

causes the deposition of fibrotic tissue in the lungs^[21]. In this study both BLM + CoQ10 and BLM + Candesartan groups showed little to no fibrosis and very mild inflammatory cell infiltration. These finding are in agreement with Mohamed *et al*(2019), that reported therapy of coQ10 removed histopathological changes produced by methotrexate so exerting an antifibrotic effect^[38].Oto *et al*(2013), showed that coQ10 treatment had a preventive role on BLM induced pulmonary fibrosis and alterations^[39].

Conclusion:

this study showed that both CoQ10 and candesartan have a good pulmonary protective and antifibrotic effect against bleomycin pulmonary toxicity by different mechanisms.

Acknowledgments: the investigator thanks Al-Mustansiriyah University (www.uomustansiriyah.edu.iq) for the supporting this study.

References

- 1- Wuyts WA, Agostini C, Antoniou KM, Bouros D, Chambers RC, Cottin V, et al. The pathogenesis of pulmonary fibrosis: a moving target. *Eur Respir J.* 2013;41(5):1207-18.
- 2- Uhal BD, Kyong Kim J, Li X, Molina-Molina MJ. Crosstalk in human idiopathic pulmonary fibrosis: autocrine mechanisms in myofibroblasts and macrophages. *Curr Pharm Des.* 2007;13(12):1247-56.
- 3- Wilson M, Wynn TJ. Pulmonary fibrosis: pathogenesis, etiology and regulation. 2009;2(2):103.
- 4- Selman M, King TE, Pardo AJ. Idiopathic pulmonary fibrosis: prevailing and evolving hypotheses about its pathogenesis and implications for therapy. *Ann Intern Med.* 2001;134(2):136-51.
- 5- Strieter RM, Mehrad B. New mechanisms of pulmonary fibrosis. *Chest.* 2009;136(5):1364-70.

- 6- Thannickal VJ, Horowitz JC. Evolving concepts of apoptosis in idiopathic pulmonary fibrosis. *Proc Am Thorac Soc.* 2006;3(4):350-6.
- 7- Khalil N, Xu YD, O'Connor R, Duronio VJJoBC. Proliferation of pulmonary interstitial fibroblasts is mediated by transforming growth factor- β 1-induced release of extracellular fibroblast growth factor-2 and phosphorylation of p38 MAPK and JNK. 2005;280(52):43000-9.
- 8- Reinert T, Baldotto CSdR, Nunes FAP, Scheliga AAdSJJoCR. Bleomycin-induced lung injury. 2013;2013.
- 9- Allawzi A, Elajaili H, Redente EF, Nozik-Grayck E. Oxidative Toxicology of Bleomycin: Role of the Extracellular Redox Environment. *Curr Opin Toxicol.* 2019;13:68-73.
- 10- Hay J, Shahzeidi S, Laurent G. Mechanisms of bleomycin-induced lung damage. *Arch Toxicol.* 1991;65(2):81-94.
- 11- Tsai K-L, Huang Y-H, Kao C-L, Yang D-M, Lee H-C, Chou H-Y, et al. A novel mechanism of coenzyme Q10 protects against human endothelial cells from oxidative stress-induced injury by modulating NO-related pathways. 2012;23(5):458-68.
- 12- Linnane AW, Kios M, Vitetta LJM. Coenzyme Q10—Its role as a prooxidant in the formation of superoxide anion/hydrogen peroxide and the regulation of the metabolome. *Mitochondrion.* 2007;7:S51-S61.
- 13- Singh U, Devaraj S, Jialal I. Coenzyme Q10 supplementation and heart failure. *Nutr Rev.* 2007;65(6 Pt 1):286-93.
- 14- Ardiana F, Lestari ML, Indrayanto G. Candesartan cilexetil. *Profiles of Drug Substances, Excipients and Related Methodology.* 37: Elsevier; 2012. p. 79-112.
- 15- Hara H, Takeda N, Komuro I. Pathophysiology and therapeutic potential of cardiac fibrosis. *Inflamm Regen.* 2017;37(1):13.
- 16- Otsuka M, Takahashi H, Shiratori M, Chiba H, Abe S. Reduction of bleomycin induced lung fibrosis by candesartan cilexetil, an angiotensin II type 1 receptor antagonist. *Thorax.* 2004;59(1):31-8.
- 17- Rivera-Ortega P, Molina-Molina M. Interstitial Lung Diseases in Developing Countries. *Ann Glob Health.* 2019;85(1).
- 18- Marshall RP, McANULTY RJ, Laurent GJJAjor, medicine cc. Angiotensin II is mitogenic for human lung fibroblasts via activation of the type 1 receptor. *Am J Respir Crit Care Med.* 2000;161(6):1999-2004.
- 19- Molteni A, Moulder JE, Cohen EF, Ward WF, Fish BL, Taylor JM, et al. Control of radiation-induced pneumopathy and lung fibrosis by angiotensin-converting enzyme inhibitors and an angiotensin II type 1 receptor blocker. *Int J Radiat Biol.* 2000;76(4):523-32.
- 20- Murphy AM, Wong AL, Bezuhly M. Modulation of angiotensin II signaling in the prevention of fibrosis. *Fibrogenesis Tissue Repair.* 2015;8(1):7.
- 21- Zaghoul MS, Abdel-Salam RA, Said E, Suddek GM, Salem HA-RJEjob, sciences a. Attenuation of Bleomycin-induced pulmonary fibrosis in rats by flavocoxid treatment. *Egyptian Journal of Basic and Applied Sciences.* 2017;4(4):256-63.
- 22- Walters DM, Kleeberger SRJCPip. Mouse models of bleomycin-induced pulmonary fibrosis. 2008;40(1):5.46. 1-5.. 17.
- 23- Ferguson GD, Bridge WJ. The glutathione system and the related thiol network in *Caenorhabditis elegans*. *Redox Biol.* 2019;24:101171.
- 24- Murray LA, Chen Q, Kramer MS, Hesson DP, Argentieri RL, Peng X, et al. TGF-beta driven lung fibrosis is macrophage dependent and blocked by

- Serum amyloid P. *The International Journal of Biochemistry & Cell Biology*. 2011;43(1):154-62.
- 25- Gaucher C, Boudier A, Bonetti J, Clarot I, Leroy P, Parent M. Glutathione: Antioxidant Properties Dedicated to Nanotechnologies. *Antioxidants (Basel)*. 2018;7(5):62.
- 26- Chen J, Shi Y, He L, Hao H, Wang B, Zheng Y, et al. Protective roles of polysaccharides from *Ganoderma lucidum* on bleomycin-induced pulmonary fibrosis in rats. *Int J Biol Macromol*. 2016;92:278-81.
- 27- McMillan DH, van der Velden JL, Lahue KG, Qian X, Schneider RW, Iberg MS, et al. Attenuation of lung fibrosis in mice with a clinically relevant inhibitor of glutathione-S-transferase pi. *JCI Insight*. 2016;1(8).
- 28- Lone Y, Bhide M, Koiri RK. Amelioratory effect of coenzyme Q10 on potential human carcinogen Microcystin-LR induced toxicity in mice. *Food Chem Toxicol*. 2017;102:176-85.
- 29- Tamuli S, Kakati S, Das SJIJoPS, Research. Comparative studies of efficacy and effect on oxidative stress of atenolol and candesartan in the hypertensive patients of North East India. 2015;6(4).
- 30- Muda P, Kampus P, Zilmer M, Ristimae T, Fischer K, Zilmer K, et al. Effect of antihypertensive treatment with candesartan or amlodipine on glutathione and its redox status, homocysteine and vitamin concentrations in patients with essential hypertension. *J Hypertens*. 2005;23(1):105-12.
- 31- Uduman S, Thattakudian MS, Reddy RB, Punuru P, Chakka G, Karunakaran GJAips. Protective role of ramipril and candesartan against myocardial ischemic reperfusion injury: a biochemical and transmission electron microscopical study. *Advances in Pharmacological and Pharmaceutical Sciences* 2016;2016.
- 32- Fouad AA, Al-Sultan AI, Refaie SM, Yacoubi MT. Coenzyme Q10 treatment ameliorates acute cisplatin nephrotoxicity in mice. *Toxicology*. 2010;274(1-3):49-56.
- 33- Mashima R, Okuyama T. The role of lipoxygenases in pathophysiology; new insights and future perspectives. *Redox Biol*. 2015;6:297-310.
- 34- Alabbassi MG. The Possible Protective Effects of Zileuton against Pulmonary Fibrosis Induced by Amiodarone in Male Rats. *Journal of Natural Sciences Research*
- 35- Wiley CD, Brumwell AN, Davis SS, Jackson JR, Valdovinos A, Calhoun C, et al. Secretion of leukotrienes by senescent lung fibroblasts promotes pulmonary fibrosis. *JCI Insight*. 2019;4(24).
- 36- Tsai KL, Chen LH, Chiou SH, Chiou GY, Chen YC, Chou HY, et al. Coenzyme Q10 suppresses oxLDL-induced endothelial oxidative injuries by the modulation of LOX-1-mediated ROS generation via the AMPK/PKC/NADPH oxidase signaling pathway. *Mol Nutr Food Res*. 2011;55 Suppl 2(S2):S227-40.
- 37- Swaisgood CM, French EL, Noga C, Simon RH, Ploplis VA. The development of bleomycin-induced pulmonary fibrosis in mice deficient for components of the fibrinolytic system. *Am J Pathol*. 2000;157(1):177-87.
- 38- Mohamed DI, Khairy E, Tawfek SS, Habib EK, Fetouh MA. Coenzyme Q10 attenuates lung and liver fibrosis via modulation of autophagy in methotrexate treated rat. *Biomed Pharmacother*. 2019;109:892-901.
- 39- Oto G, Ekin S, Çelikezen FÇ, Yener Z, Tanrıtanır P, Özdemir H, et al. cytoprotective effects of boric acid and coenzyme q 10 therapy on induced pulmonary fibrosis in response to intratracheal administration of bleomycin in rats. 2013.