

Oesophagostomum stephanostomum causing parasitic granulomas in wild chimpanzees (*Pan troglodytes verus*) of Taï National Park, Côte d'Ivoire

Jenny E. Jaffe^{1,2,3}  | Sonja Metzger^{1,2} | Kerstin Mätz-Rensing⁴ |
Alexis Ribas⁵  | Roman M. Wittig^{1,6}  | Fabian H. Leendertz^{2,7} 

¹Taï Chimpanzee Project, Centre Suisse de Recherches Scientifiques, Abidjan, Côte d'Ivoire

²Epidemiology of Highly Infectious Pathogens, Robert Koch Institute, Berlin, Germany

³Department of Veterinary Medicine, Freie Universität, Berlin, Germany

⁴German Primate Center, Leibniz Institute for Primate Research, Göttingen, Germany

⁵Parasitology Section, Department of Biology, Healthcare and Environment, Faculty of Pharmacy and Food Science; Institut de Recerca de la Biodiversitat (IRBio), University of Barcelona, Barcelona, Spain

⁶Ape Social Mind Lab, Institute of Cognitive Sciences Marc Jeannerod, Bron, France

⁷Helmholtz Institute for One Health, Greifswald, Germany

Correspondence

Jenny E. Jaffe, Taï Chimpanzee Project, Centre Suisse de Recherches Scientifiques, Abidjan, Côte d'Ivoire.

Email: jennyjaffedvm@gmail.com

Funding information

Robert Koch Institut; Max-Planck-Gesellschaft

Abstract

Nematodes belonging to the genus *Oesophagostomum* frequently infect wild chimpanzees (*Pan troglodytes*) across widely separated field sites. Nodular lesions (granulomas) containing *Oesophagostomum* are commonly seen in the abdomen of infected chimpanzees post-mortem. At Taï National Park, Côte d'Ivoire, previous studies have identified larvae of a variety of *Oesophagostomum* spp. in wild chimpanzee stool, based on sequencing of larval DNA, and nodular lesions associated with *Oesophagostomum*, identified morphologically to the genus level but not sequenced. Here we present three recent cases of parasitic granulomas found post-mortem in chimpanzees at Taï. We complement descriptions of gross pathology, histopathology and parasitology with PCR and sequencing of DNA isolated from the parasitic nodules and from adult worms found inside the nodules. In all three cases, we identify *Oesophagostomum stephanostomum* as the causative agent. The sequences from this study were identical to the only other published sequences from nodules in nonhuman primates—those from the wild chimpanzees of Gombe, Tanzania.

KEYWORDS

host-parasite interactions, nodular worms, oesophagostomiasis, parasitic granuloma, primates, Strongylida

1 | INTRODUCTION

Oesophagostomum infections have been found in humans, great apes and monkeys. These strongyle nematodes, also termed “nodular worms,” have a life cycle where hosts are infected by ingesting L3 larvae. These burrow into the wall of the intestine where they become encapsulated within

inflammatory nodules. Within these nodules, they feed on the inflammatory cells and mature to L4 larvae or (juvenile) adult worms, then migrate back to the lumen of the intestine. The adult worms in the large intestine produce eggs which are shed with the stool. In the environment, the eggs can go to L3 larvae within a few days (CDC, 2017; Polderman & Blotkamp, 1995; Polderman et al., 2010). In Africa,

Abbreviations: ATL Buffer, name of Tissue Lysis Buffer in QIAGEN DNA extraction kit; BLAST, basic local alignment search tool (software tool); bp, base pair; DNA, deoxyribonucleic acid; dUTP, deoxyuridine triphosphate; ITS-2, internal transcribed spacer 2; NAP Buffer, nucleic acid preservation buffer; PBS, phosphate buffered saline; PCR, polymerase chain reaction; RNA, ribonucleic acid; rRNA, ribosomal RNA.

This is an open access article under the terms of the [Creative Commons Attribution-NonCommercial](https://creativecommons.org/licenses/by-nc/4.0/) License, which permits use, distribution and reproduction in any medium, provided the original work is properly cited and is not used for commercial purposes.

© 2024 The Author(s). *American Journal of Primatology* published by Wiley Periodicals LLC.

Oesophagostomum bifurcum mainly infects humans and monkeys, and *O. stephanostomum* is most commonly found in apes and monkeys. *Oesophagostomum aculeatum* is mainly found in Asian monkeys and apes (Ilik et al., 2023; Polderman et al., 2010).

Oesophagostomum infections have been identified through parasitology of stool samples in wild chimpanzees from Tanzania, Uganda, Cameroon, Gabon, Rwanda, and Côte d'Ivoire, as well as in a wide range of sympatric primates (Cibot et al., 2015; Ilik et al., 2023; Kooriyama et al., 2012; Metzger, 2015; Ota et al., 2015; Sirima et al., 2021; Terio et al., 2018). When sequencing of stool samples was performed, results showed chimpanzees can be infected with *O. stephanostomum* and *O. bifurcum* (Cibot et al., 2015; Ota et al., 2015; Sirima et al., 2021), sometimes even co-existing in the same individuals (Krief et al., 2010). There is a large genetic diversity within African primate *Oesophagostomum*, with *O. stephanostomum* and *O. bifurcum* both divided into several variants/haplotypes/genotypes (Ilik et al., 2023; Ota et al., 2015; Sirima et al., 2021). There are even additional lineages that do not cluster with published sequences; some cannot be categorized as either *O. stephanostomum* or *O. bifurcum* (Ghai et al., 2014; Metzger, 2015; Ota et al., 2015).

Historically, *Oesophagostomum* infections have frequently been described in zoo and laboratory primates, where light infections are asymptomatic, and heavier infections can lead to weight loss, diarrhea, and nodular lesions capable of causing septicemia, acute and chronic peritonitis with peritoneal adhesions and obstructions (Ruch, 1959; Toft, 1986).

In recent decades, nodules associated with *Oesophagostomum* have been described in the western chimpanzees (*Pan troglodytes verus*) of Taï; eastern chimpanzees (*Pan troglodytes schweinfurthii*) in Kibale, Uganda; central chimpanzees (*Pan troglodytes troglodytes*) in Conkouati-Ndouli National Park, Congo; in a western lowland gorilla (*Gorilla gorilla gorilla*) from Gabon (all preceding cases described in Krief et al., 2008); in mountain gorillas (*Gorilla beringei beringei*) in Rwanda (Sleeman et al., 2000); and in eastern chimpanzees and olive baboons (*Papio anubis*) in Gombe, Tanzania (Terio et al., 2011, 2018). In some chimpanzee populations (Taï and Kibale, see Krief et al., 2008), these lesions do not appear to have significant health consequences. In others, both wild and captive, the nodules can be associated with morbidity and mortality. In Gabon, nodular lesions have been linked to deaths of four captive central chimpanzees, while a fifth recovered after surgical removal of the nodules (Ngoubangoye et al., 2021). Other fatal infections in nonhuman primates have been typically reported in captivity after transport, likely due to "cross infections under unsanitary, crowded shipping conditions," as reported in rhesus macaques (*Macaca mulatta*), a hamadryas baboon (*Papio hamadryas*) and gorillas (*Gorilla gorilla*) (Ruch, 1959). Research in Gombe suggests that though some wild eastern chimpanzees tolerate the commonly found nodular lesions, a moderate to high number of parasitic nodules (indicating higher parasite burden) can lead to poor body condition and diarrhea (Terio et al., 2011, 2018). Observations amongst wild eastern chimpanzees in Mahale, Tanzania, indicate infections with *O. stephanostomum* can be associated with diarrhea, malaise and emaciation (Huffman et al., 1997).

The parasite causing nodular disease was identified to species level, *O. stephanostomum*, by morphological observation in a captive central chimpanzee in Congo and a western lowland gorilla in Gabon (Krief et al., 2008). In the eastern chimpanzees of Gombe, the involvement of *O. stephanostomum* was confirmed by sequencing of the ITS-2 fragment (Terio et al., 2018).

For the western chimpanzees in Taï, the parasite associated with the nodular lesions had been identified as *Oesophagostomum* sp. but the species had not been determined (Krief et al., 2008). Microscopy of fecal cultures provided evidence that *Oesophagostomum* was very common in Taï chimpanzees, with sequences from cultured *Oesophagostomum* larvae showing considerable variety (Metzger, 2015). Analysis of these sequences showed unambiguous identification as *O. stephanostomum* for four larvae, while others could not be clearly classified as either *O. stephanostomum* or *O. bifurcum*.

During recent fieldwork in Taï, three adult chimpanzees were found dead with abdominal nodules observed during necropsy. These findings were the impetus to fill in some remaining gaps in knowledge by identifying the nematode causing nodules in the Taï chimpanzees at the species level. Here we combine findings from gross pathology, histopathology, and morphology of the helminths causing the nodules, in addition to the sequences obtained from these worms and the nodules.

2 | MATERIALS AND METHODS

Fieldwork was conducted with the Taï Chimpanzee Project located at the Taï National Park, Côte d'Ivoire (5°52' N, 7°20' E), between May 2019 and October 2020, observing western chimpanzees (*Pan troglodytes verus*) from the well-habituated East, South and North chimpanzee groups (Wittig & Boesch, 2019). For this study, three chimpanzees found dead from natural causes in early 2020 were included, based on abdominal nodules found on gross pathology: an adult female (AF1) and two adult males (AM1 and AM2). See Table 1 for details. All three chimpanzees necropsied were individually recognized adults. Carcasses were necropsied in the field on the site where they were found, between 4 and 24 h after the estimated time of death. Complete gross necropsies were performed by a clinical veterinarian trained in appropriate biosafety precautions and primate necropsy techniques (for details, see Gräßle et al., 2023). The intestines were examined in situ, not linearized. Sections of brain, lung, heart, stomach, large intestine, small intestine, kidney, liver, spleen, and lymph nodes (axillary and mesenteric) were collected, as available, and fixed in 10% neutral buffered formalin. Selected tissues were saved both in dry cryotubes and in NAP buffer (Camacho-Sanchez et al., 2013). Formalin-fixed tissues were routinely processed for histopathology, embedded in paraffin, sections cut at 4 µm and stained with hematoxylin-eosin. Tissues were reviewed histologically and photographed by a veterinary pathologist.

Sections of abdominal nodules were dissected from the three chimpanzees and saved both in dry cryotubes and in NAP Buffer and stored in liquid nitrogen for 4-8 weeks and then at -80°C. From two nodules (AF1 and AM2) whole nematodes were obtained and saved in ethanol, and later transferred to formalin due to biosecurity concerns.

TABLE 1 Numbers of nodules observed post-mortem and details for each case.

ID	Sex	Age (years)	Community	Number of nodules observed (size range)	Other significant findings	Body condition	Date of necropsy
AF1	F	±40	East	4 (10–30 mm diam)	Kidney disease	Very poor	8 Jan 2020
AM1	M	16	South	5 (5–10 mm diam)	Anthrax	Good	11 Mar 2020
AM2	M	15	South	5 (5–10 mm diam)	Anthrax	Good	15 Mar 2020

Note: Other significant findings = most likely cause of death.

Abbreviations: AF, adult female; AM, adult male.

These two entire nematodes were studied under an optical microscope by a parasitologist; after measurements, the apical end was cut for en face views. A second, independent parasitologist (Hideo Hasegawa from Oita University, Japan) reviewed photos and descriptions. These two helminths were then sent back to the Robert Koch Institute (Berlin, Germany), where DNA was extracted for further analysis.

DNA was extracted from the nodules using a commercially available kit (QIAamp Viral RNA Mini Kit for Tissue; Qiagen) following the manufacturer's instructions.

For the two helminths that had been saved in formalin, an adapted protocol was used. A different extraction kit (DNeasy Blood & Tissue; Qiagen) was used following the manufacturer's instructions, but with a pretreatment where the samples were washed with 1 mL PBS twice to remove the fixative, then once the ATL buffer was added, the sample was incubated at 98°C for 15 min, then cooled and lysed by a tissue lyser (3x20s) before continuing the standard protocol.

The ribosomal internal transcribed spacer 2 gene (ITS-2) was targeted using primers NC1, NC2 and *Oesophagostomum*-specific primer OesophITS2-21 in a semi-nested PCR as previously described (Ghai et al., 2014).

External PCR was performed in 10 µL volumes using 0.05 µL of high-fidelity Platinum *Taq* polymerase (Thermo Fisher Scientific, Waltham, MA, USA), 1 µL 10X PCR buffer (Thermo Fisher Scientific), 1 µL dUTPs, 0.5 µL MgCl₂, 5 pmol of each primer (NC1 and NC2), and 2 µL of template. Reactions were cycled in a GeneTouch Thermal Cycler (Bioer) with the following temperature profile: 95°C for 5 min; 45 cycles of 95°C for 30 s, 50°C for 30 s, 72°C for 30 s; and a final extension at 72°C for 10 min.

Internal PCR was performed in similar volumes as with the external PCR, using different primers (OesophITS2-21 and NC2), and 2 µL of template (the product of the external PCR). Reactions were cycled with the following temperature profile: 95°C for 5 min; 45 cycles of 95°C for 30 s, 55°C for 30 s, 72°C for 30 s; and a final extension at 72°C for 10 min. Known *Oesophagostomum* sp. positive DNA extracts and negative controls (sterile water substituted for DNA extract) were included in each run.

The resulting amplicons were visualized on agarose gel and purified using the PureLink Quick Gel Extraction Kit and BigDye (both Thermo Fisher Scientific). Sanger sequencing was performed by an automated sequencer at the sequencing facility of the Robert Koch Institute (Berlin, Germany). Strands were sequenced in both directions using primers OesophITS2-21 and NC2 for inner nest products, and NC1 and NC2 for outer nest products.

Forward and reverse sequences were hand-edited and aligned to resolve ambiguous bases using Geneious Prime 2020.2.3 (<https://www.geneious.com>). Sequences were trimmed to the shortest sequence, i.e. trimming primer sequences and, where necessary, trimming low-quality reads. Sequences obtained were compared to each other and to known species of *Oesophagostomum* in GenBank using BLAST. Accession numbers for the sequences from this study, deposited in NCBI GenBank, are OR832859, OR832860 and OR832861.

The Ministère de l'Enseignement Supérieur et de la Recherche Scientifique, the Ministère de Eaux et Forêts in Côte d'Ivoire and the Office Ivoirien des Parcs et Réserves provided research permissions. This research adhered to the legal requirements of Côte d'Ivoire and complied with the American Society of Primatologists (ASP) Principles for the Ethical Treatment of Nonhuman Primates.

3 | RESULTS

3.1 | Gross pathology

Granulomatous nodules were observed along the intestinal tract and abdominal wall of the three chimpanzees examined (Table 1 and Figure 1). In AF1 and AM2, live whitish cylindrical worms with tapered ends were found within the nodules (see Section 4.1 for detailed description). The nodules varied between 5 and 30 mm in maximum diameter; were bean-shaped; had black, beige or reddish walls; and contained beige liquid pus. In these three chimpanzees, only few nodules (4 or 5) were observed, though possibly there were more that went undetected as the intestines were examined in situ.

4 | HISTOPATHOLOGY

All three animals had chronic colitis with granulomatous inflammation in the colon wall and serosa (Figure 2). The granulomatous nodules expanded into the colon wall and were characterized by a central cavity containing cell detritus and sections of nematodes with a thick smooth eosinophilic cuticle, platymyarian musculature, lateral cords, large intestine, and reproductive tract. The parasites were surrounded by an inflammatory cell infiltrate consisting of macrophages, neutrophils and eosinophils. The external capsule consisted of connective tissue.

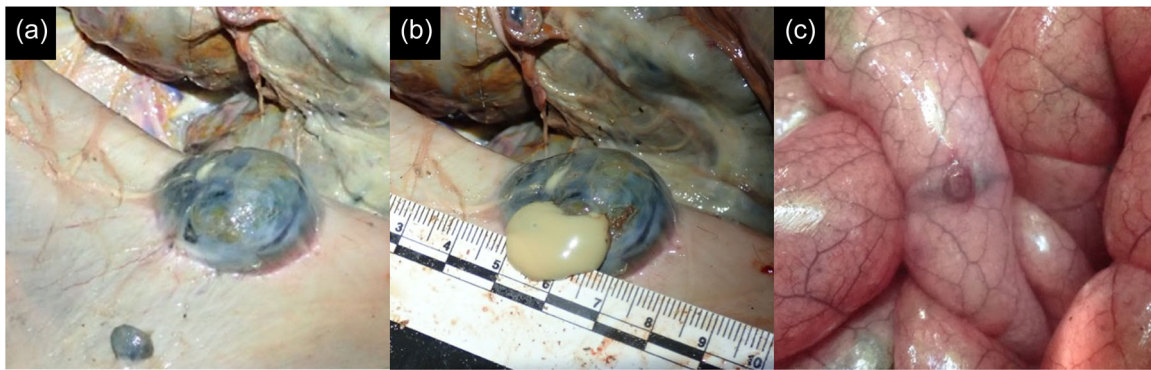


FIGURE 1 Gross pathology of abdominal *Oesophagostomum* nodules. (a) Two black-walled nodules in peritoneum abdominal wall from AF1. (b) Larger nodule (approximately 30 mm in diameter) from (a) after incision, with liquid beige pus visible. (c) Nodule in interstitial tract from AM1.

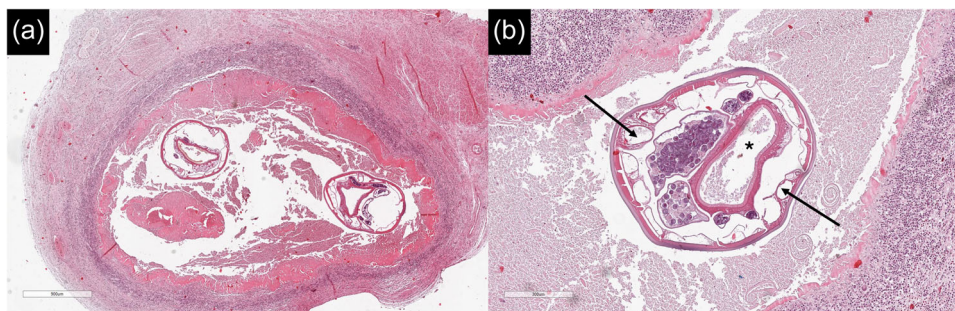


FIGURE 2 Histopathology of *Oesophagostomum* nodules. (a) AM1: Overview of granulomatous nodule expanding in the colon wall. Central cavity contains cell detritus and sections of nematodes. Scale bar=900 µm. (b) AM1: Nematode, up to 600–900 µm in diameter with a thick smooth eosinophilic cuticle, platymyarian musculature, vacuolated lateral cords (arrows), intestine (asterisk), and reproductive tract, surrounded by a mantle of mixed inflammatory cells. Scale bar=300 µm.

4.1 | Morphology

Two entire nematodes were obtained from the abdominal nodules of AF1 and AM2. Both individuals were non-gravid adult females (total body length 28 mm/23 mm; maximum width 890 µm/996 µm; total length of esophagus 1336 µm/995 µm; anus to tip of the tail 190 µm/208 µm; vulva to the tip of the tail 649 µm/970 µm). Approximately 40 flat elements were present in the external corona radiata. These individuals were morphologically consistent with *O. stephanostomum*, based on *O. bifurcum* having a shorter female body length (maximum 14 mm; Blotkamp et al., 1993; Glen & Brooks, 1985) and a much lower number of elements of the external corona radiata (Chabaud & Durette-Desset, 1974; Glen & Brooks, 1985).

4.2 | Sequencing

4.2.1 | Identification and classification

ITS-2 sequences obtained measured 225 bp (AF1 and AM1) and 177 bp (AM2; shorter due to trimming of low-quality reads). These sequences matched (100%) *O. stephanostomum* sequences in GenBank. According to Gasser et al. (1999), there are five (2.3%)

nucleotide differences between the sequences of *O. stephanostomum* and *O. bifurcum* in the ITS-2 region. For all five positions, our sequences matched the *O. stephanostomum* nucleotides (Gasser et al., 1999), confirming the species identification. The sequence is identical to representative sequences for *O. stephanostomum* haplogroups OH1-4, 8, 13, and 14 (see the phylogenetic tree by Sirima et al., 2021); broadly, it falls within the *O. stephanostomum* Type I group (Ilik et al., 2023).

4.2.2 | Comparison amongst Tai *Oesophagostomum* sp. sequences

The ITS-2 sequences from the individual nodules from each chimpanzee (AF1, AM1, AM2) and from the adult worm found within a nodule (from AF1) were identical to each other, and 99.6% to 100% similar to sequences from four *O. stephanostomum* larvae cultured from stool from three different chimpanzees (UTA, IBR and SUM) in the Metzger (2015) study (GenBank accession numbers PP235524-PP235526 and PP235528). The sequences from UTA and IBR larvae differed by one base pair from the two sequences from SUM larvae, which were identical to those from the current study. The larval cultures from Metzger (2015), also produced five sequences from

Oesophagostomum sp. larvae which could not be clearly categorized as *O. stephanostomum* or *O. bifurcum*, either by the Gasser et al. (1999) criteria described above or by using BLAST. Rather, they fit within the third lineage described by Ghai et al. (2014), termed haplogroups OH36-37 in Sirima et al. (2021), and clade 5 by Yalcindag et al. (2021). These larval sequences (from chimpanzees IBR, ZYO, COC, OLI, and ROM) were respectively 92.9%, 93.3%, 93.8%, 93.8%, and 97.3% identical to the *O. stephanostomum* sequence from the present study (GenBank accession numbers PP235521-PP235523, PP235527, and PP235529).

4.2.3 | Comparison with *Oesophagostomum* sequences from other field sites

The sequence from this study was 98%–100% similar to *O. stephanostomum* reported from apes and monkeys in Kenya (Mbutia et al., 2021), Uganda (Cibot et al., 2015; Ghai et al., 2014; Krief et al., 2010; Ota et al., 2015), Gabon (Makouloutou et al., 2014; Sirima et al., 2021), Cameroon (Hamad et al., 2014; Ilik et al., 2023; Sirima et al., 2021), Democratic Republic of the Congo (Medkour et al., 2021; Narat et al., 2015) and Tanzania (Gasser et al., 1999; Terio et al., 2018). The sequences from the eastern chimpanzees in Gombe (Terio et al., 2018) are the only other published *O. stephanostomum* sequences obtained from granulomas and are 100% identical to those obtained from the present study.

5 | DISCUSSION

On gross pathology, the western chimpanzees in Taï appear to have fewer detectable nodules than the eastern chimpanzees in Gombe (Terio et al., 2018). Only four or five per chimpanzee were seen in this study and “up to ten” in the three Taï cases mentioned in the Krief et al. (2008) study. In both studies, the findings of granulomas in the Taï chimpanzees were seen as incidental, as the chimpanzees died of other causes (anthrax and chronic kidney disease in this study). In the 12 chimpanzees studied in Gombe, where oesophagostomiasis has been associated with morbidity and mortality, four were categorized as having “moderate,” six having “numerous,” while only two had “few” nodules. Though these qualitative values are not easily comparable, one individual categorized as having “few” nodules had at least four indicated by arrows in the accompanying illustration of the gross pathology (Terio et al., 2018). The small sample sizes in all studies mean that no definite significance can be attributed to the number of nodules seen. Still, in the small number of cases detailed, the Taï chimpanzees had fewer nodules, but the sequence obtained from the nodules was identical to those from the Gombe chimpanzees. Host and environmental ecology attributes may contribute toward severity of clinical signs (i.e., number and size of granulomas in intestinal wall), not only parasite variability within the *O. stephanostomum* species. The granulomas are formed when the immune system of the host cannot stop the larvae from invading the

intestinal wall (Giorgio et al., 2020). However, in lab primates, larvae in nonimmune animals leave the nodules within a few days, causing minimal tissue damage, while in older animals with previous exposure the granulomas can persist for long periods. More severe signs in primates occur during higher infection pressure and when the immune system is suppressed, as can be the case during transport or captivity (Polderman et al., 2010; Ruch, 1959). Seasonality, concurrent infections and medicinal plant use may also affect severity of clinical signs (Huffman et al., 1997).

Important to note is that all ITS-2 sequences obtained from nodules, from these three Taï chimpanzees and from four Gombe chimpanzees, were clearly attributable to *O. stephanostomum* and 100% identical, while sequences obtained from larvae in Taï stool (Metzger, 2015) show that these chimpanzees also carry similar *Oesophagostomum* sp. which cannot be easily categorized as *O. stephanostomum* or *O. bifurcum* (92.9%–97.3% identical to the sequences obtained from the nodules). Other studies show chimpanzees can host both *O. stephanostomum* and *O. bifurcum* at the same time (Krief et al., 2010). Our results add to the small body of literature confirming only *O. stephanostomum* as the causative species for the granulomas in apes, despite multiple species of *Oesophagostomum* being detected in stool. For Taï and Gombe, the ITS-2 sequences of the parasites causing the granulomas are identical. However, using longer sequences than the 225 bp obtained in this study may uncover more variants (as in Ilik et al., 2023). Sequencing from a much larger number of nodules would provide statistical evidence toward which variants and species most commonly cause the nodules.

The parasite species causing granulomas was both morphologically and genetically identified in this study and in Terio et al. (2018), and only morphologically in a western lowland gorilla in Gabon and a central chimpanzee in Congo (Krief et al., 2008). Unfortunately, the only other recent study describing granulomas in apes, Ngoubangoye et al. (2021), which records fatal *Oesophagostomum* infections in captive central chimpanzees in Gabon, does not confirm the parasite species, only the genus. Utilizing molecular diagnostics more broadly should help determine if only *O. stephanostomum* causes granulomatous disease in nonhuman primates, and if only certain genetic variants do so for specific hosts, as seems to be the case for *O. bifurcum* (Gasser et al., 2006). The findings from this study enhance our understanding of the pathophysiology and etiology of this parasitic infection. A more complete picture could be formed with additional data from other field sites, comparing clinical signs, post-mortem results and sequences from nodular lesions and stool (or larvae/worms obtained from nodules or stool).

AUTHOR CONTRIBUTIONS

Jenny E. Jaffe: Conceptualization (lead); data curation (lead); formal analysis (lead); investigation (lead); methodology (lead); resources (supporting); visualization (lead); writing—original draft (lead); writing—review and editing (lead). **Sonja Metzger:** Data curation (supporting); formal analysis (supporting); investigation (supporting); methodology (supporting); resources (supporting); writing—review and editing (supporting). **Kerstin Mätz-Rensing:** Investigation (supporting);

methodology (supporting); visualization (supporting); writing—review and editing (supporting). **Alexis Ribas**: Formal analysis (supporting); investigation (supporting); methodology (supporting); writing—review and editing (supporting). **Roman M. Wittig**: Conceptualization (supporting); data curation (supporting); funding acquisition (lead); project administration (lead); resources (lead); supervision (lead); writing—review and editing (supporting). **Fabian H. Leendertz**: Conceptualization (supporting); data curation (supporting); formal analysis (supporting); funding acquisition (lead); methodology (supporting); project administration (lead); resources (lead); supervision (lead); writing—review and editing (supporting).

ACKNOWLEDGMENTS

We thank the Ministère de l'Enseignement Supérieur et de la Recherche Scientifique, the Ministère de Eaux et Forêts in Côte d'Ivoire and the Office Ivoirien des Parcs et Réserves for allowing us to carry out this study. We thank the Centre Suisse de Recherches Scientifiques in Côte d'Ivoire and the staff of the Taï Chimpanzee Project for their support, specifically Vincent Yoro, JC Blaihyo, Narcisse Gré, Olivier Solo, Mathieu Malherbe, Kayla Kolff, Aisha Bründl, Mathilde Grampp and Frauke Olthoff. As well, thanks to those who helped with the import and permits of samples: Christina Kompo, Zoro Goné Bi, Emmanuel Couacy-Hymann and Ariane Düx. Invaluable support for laboratory analysis at the Robert Koch Institute was provided by Andreas Sachse, Kevin Merkel, Milen Sterev and especially Sébastien Calvignac-Spencer. Hideo Hasegawa was kind enough to lend unique expertise regarding the morphological identification and description of the nematodes obtained from the abscesses, and John Evans provided helpful comments on the manuscript. Core funding for the Taï Chimpanzee Project has been provided by the Max Planck Society since 1997. Open Access funding enabled and organized by Projekt DEAL.

CONFLICT OF INTEREST STATEMENT

The authors declare no conflict of interest.

DATA AVAILABILITY STATEMENT

The data that support the findings of this study are available from the corresponding author upon reasonable request. GenBank accession numbers for the sequences from the present study are OR832859-OR832861. For comparison, the *Oesophagostomum* sp. sequences from the earlier Taï study (Metzger, 2015) were also deposited, under accession numbers PP235521-PP235529.

ORCID

Jenny E. Jaffe  <http://orcid.org/0000-0001-6157-337X>

Alexis Ribas  <http://orcid.org/0000-0002-1256-3316>

Roman M. Wittig  <http://orcid.org/0000-0001-6490-4031>

Fabian H. Leendertz  <http://orcid.org/0000-0002-2169-7375>

REFERENCES

- Blotkamp, J., Krepel, H. P., Kumar, V., Baeta, S., Noordende, J. M. V., & Polderman, A. M. (1993). Observations on the morphology of adults and larval stages of *Oesophagostomum* sp. isolated from man in Northern Togo and Ghana. *Journal of Helminthology*, 67(1), 49–61. <https://doi.org/10.1017/S0022149X00012840>
- Camacho-Sanchez, M., Burraco, P., Gomez-Mestre, I., & Leonard, J. A. (2013). Preservation of RNA and DNA from mammal samples under field conditions. *Molecular Ecology Resources*, 13(4), 663–673. <https://doi.org/10.1111/1755-0998.12108>
- CDC. (2017). *Centers for Disease Control and Prevention—DPDx Oesophagostomiasis*. <https://www.cdc.gov/dpdx/oesophagostomiasis/index.html>
- Chabaud, A. G., & Durette-Desset, M. C. (1974). Description d'un nouveau *Oesophagostomum*, parasite d'Hyemoschus au Gabon, et remarques sur le genre *Oesophagostomum*. *Bulletin Du Museum National D'Histoire Naturelle Bulletin Du Muséum National d'Histoire, Zoologie*, 123, 1415–1424.
- Cibot, M., Guillot, J., Lafosse, S., Bon, C., Seguya, A., & Krief, S. (2015). Nodular worm infections in wild non-human primates and humans living in the Sebitoli area (Kibale National Park, Uganda): Do high spatial proximity favor zoonotic transmission. *PLoS Neglected Tropical Diseases*, 9(10), e0004133. <https://doi.org/10.1371/journal.pntd.0004133>
- Gasser, R. B., Gruijter, J. M., & Polderman, A. M. (2006). Insights into the epidemiology and genetic make-up of *Oesophagostomum bifurcum* from human and non-human primates using molecular tools. *Parasitology*, 132(4), 453–460. <https://doi.org/10.1017/S0031182005009406>
- Gasser, R. B., Woods, W. G., Huffman, M. A., Blotkamp, J., & Polderman, A. M. (1999). Molecular separation of *Oesophagostomum stephanostomum* and *Oesophagostomum bifurcum* (Nematoda: Strongyloidea) from non-human primates. *International Journal for Parasitology*, 29(7), 1087–1091. [https://doi.org/10.1016/S0020-7519\(99\)00037-5](https://doi.org/10.1016/S0020-7519(99)00037-5)
- Ghai, R. R., Chapman, C. A., Omeja, P. A., Davies, T. J., & Goldberg, T. L. (2014). Nodule worm infection in humans and wild primates in Uganda: Cryptic species in a newly identified region of human transmission. *PLoS Neglected Tropical Diseases*, 8(1), e2641. <https://doi.org/10.1371/journal.pntd.0002641>
- Giorgio, S., Gallo-Francisco, P. H., Roque, G. A. S., & Flóro e Silva, M. (2020). Granulomas in parasitic diseases: The good and the bad. *Parasitology Research*, 119(10), 3165–3180. <https://doi.org/10.1007/s00436-020-06841-x>
- Glen, D. R., & Brooks, D. R. (1985). Phylogenetic relationships of some strongylate nematodes of primates. *Proceedings of the Helminthological Society of Washington*, 52(2), 227–236.
- Gräßle, T., Crockford, C., Eichner, C., Girard-Buttoz, C., Jäger, C., Kirilina, E., Lipp, I., Düx, A., Edwards, L., Jauch, A., Kopp, K. S., Paquette, M., Pine, K., Haun, D. B. M., McElreath, R., Anwander, A., Gunz, P., Morawski, M., Friederici, A. D., ... Wittig, R. M. (2023). Sourcing high tissue quality brains from deceased wild primates with known socio-ecology. *Methods in Ecology and Evolution*, 14(8), 1906–1924. <https://doi.org/10.1111/2041-210X.14039>
- Hamad, I., Keita, M. B., Peeters, M., Delaporte, E., Raoult, D., & Bittar, F. (2014). Pathogenic eukaryotes in gut microbiota of Western lowland gorillas as revealed by molecular survey. *Scientific Reports*, 4, 6417. <https://doi.org/10.1038/srep06417>
- Huffman, M. A., Gotoh, S., Turner, L. A., Hamai, M., & Yoshida, K. (1997). Seasonal trends in intestinal nematode infection and medicinal plant use among chimpanzees in the Mahale Mountains, Tanzania. *Primates*, 38(April), 111–125.
- llík, V., Kreisinger, J., Modrý, D., Schwarz, E. M., Tagg, N., Mbohli, D., Nkombou, I. C., Petrželková, K. J., & Pařčo, B. (2023). High diversity and sharing of strongylid nematodes in humans and great apes cohabiting an unprotected area in Cameroon. *PLoS Neglected Tropical Diseases*, 17(8), e0011499. <https://doi.org/10.1371/journal.pntd.0011499>
- Kooriyama, T., Hasegawa, H., Shimozuru, M., Tsubota, T., Nishida, T., & Iwaki, T. (2012). Parasitology of five primates in Mahale Mountains National Park, Tanzania. *Primates*, 53(4), 365–375. <https://doi.org/10.1007/s10329-012-0311-9>

- Krief, S., Jamart, A., Mahé, S., Leendertz, F. H., Mätz-Rensing, K., Crespeau, F., Bain, O., & Guillot, J. (2008). Clinical and pathologic manifestation of oesophagostomosis in African great apes: Does self-medication in wild apes influence disease progression? *Journal of Medical Primatology*, 37(4), 188–195. <https://doi.org/10.1111/j.1600-0684.2008.00285.x>
- Krief, S., Vermeulen, B., Lafosse, S., Kasenene, J. M., Nieguitsila, A., Berthelemy, M., L'Hostis, M., Bain, O., & Guillot, J. (2010). Nodular worm infection in wild chimpanzees in Western Uganda: A risk for human health. *PLoS Neglected Tropical Diseases*, 4(3), e630. <https://doi.org/10.1371/journal.pntd.0000630>
- Makouloutou, P., Mbehang Nguema, P., Fujita, S., Takenoshita, Y., Hasegawa, H., Yanagida, T., & Sato, H. (2014). Prevalence and genetic diversity of *Oesophagostomum stephanostomum* in wild lowland gorillas at Moukalaba-Doudou National Park, Gabon. *Helminthologia*, 51(2), 83–93. <https://doi.org/10.2478/s11687-014-0214-y>
- Mbuthia, P., Murungi, E., Owino, V., Akinyi, M., Eastwood, G., Nyamota, R., Lekolool, I., & Jeneby, M. (2021). Potentially zoonotic gastrointestinal nematodes co-infecting free ranging non-human primates in Kenyan urban centres. *Veterinary Medicine and Science*, 7(3), 1023–1033. <https://doi.org/10.1002/vms3.424>
- Medkour, H., Castaneda, S., Amona, I., Fenollar, F., André, C., Belais, R., Mungongo, P., Muyembé-Tamfum, J. J., Levasseur, A., Raoult, D., Davoust, B., & Mediannikov, O. (2021). Potential zoonotic pathogens hosted by endangered bonobos. *Scientific Reports*, 11(1), 1–16. <https://doi.org/10.1038/s41598-021-85849-4>
- Metzger, S. (2015). Gastrointestinal helminthic parasites of habituated wild chimpanzees (*Pan troglodytes verus*) in the Tai NP, Côte d'Ivoire—Including characterization of cultured helminth developmental stages using genetic markers [Doctoral dissertation, Freie Universität Berlin]. <https://doi.org/10.17169/refubium-17695>
- Narat, V., Guillot, J., Penneç, F., Lafosse, S., Grüner, A. C., Simmen, B., Bokika Ngawolo, J. C., & Krief, S. (2015). Intestinal helminths of wild bonobos in Forest-Savanna Mosaic: Risk assessment of cross-species transmission with local people in the Democratic Republic of the Congo. *EcoHealth*, 12(4), 621–633. <https://doi.org/10.1007/s10393-015-1058-8>
- Ngoubangoye, B., Boundenga, L., Dibakou, S. E., Tsoumbou, T. A., Kinga, C. M., Prugnolle, F., Fouchet, D., & Pontier, D. (2021). Surgical treatment of *Oesophagostomum* spp. nodular infection in a chimpanzee at the CIRMF Primatology Center, Gabon. *Case Reports in Veterinary Medicine*, 2021, 6617416. <https://doi.org/10.1155/2021/6617416>
- Ota, N., Hasegawa, H., McLennan, M. R., Kooriyama, T., Sato, H., Pepsworth, P. A., & Huffman, M. A. (2015). Molecular identification of *Oesophagostomum* spp. from 'village' chimpanzees in Uganda and their phylogenetic relationship with those of other primates. *Royal Society Open Science*, 2(11), 150471. <https://doi.org/10.1098/rsos.150471>
- Polderman, A., Eberhard, M., Baeta, S., Gasser, R., Van Lieshout, L., Magnussen, P., Olsen, A., Spannbrucker, N., Ziem, J., & Horton, J. (2010). The rise and fall of oesophagostomiasis in man. *Advances in Parasitology*, 71, 93–155. [https://doi.org/10.1016/S0065-308X\(10\)71002-2](https://doi.org/10.1016/S0065-308X(10)71002-2)
- Polderman, A. M., & Blotkamp, J. (1995). *Oesophagostomum* infections in humans. *Parasitology Today*, 11(12), 451–456. [https://doi.org/10.1016/0169-4758\(95\)80058-1](https://doi.org/10.1016/0169-4758(95)80058-1)
- Ruch, T. C. (1959). *Diseases of laboratory primates*. W.B. Saunders.
- Sirima, C., Bizet, C., Hamou, H., Červená, B., Lemarcis, T., Esteban, A., Peeters, M., Mpoudi Ngole, E., Mombo, I. M., Liégeois, F., Petrželková, K. J., Boussinesq, M., & Locatelli, S. (2021). Soil-transmitted helminth infections in free-ranging non-human primates from Cameroon and Gabon. *Parasites & Vectors*, 14(1), 354. <https://doi.org/10.1186/s13071-021-04855-7>
- Sleeman, J. M., Meader, L. L., Mudakikwa, A. B., Foster, J. W., & Patton, S. (2000). Gastrointestinal parasites of mountain gorillas (*Gorilla gorilla beringei*) in the Parc National des Volcans, Rwanda. *Journal of Zoo and Wildlife Medicine*, 31(3), 322–328. [https://doi.org/10.1638/1042-7260\(2000\)031\[0322:GPOMGG\]2.0.CO;2](https://doi.org/10.1638/1042-7260(2000)031[0322:GPOMGG]2.0.CO;2)
- Terio, K. A., Kinsel, M. J., Raphael, J., Mlengeya, T., Lipende, I., Kirchhoff, C. A., Gilagiza, B., Wilson, M. L., Kamenya, S., Estes, J. D., Keele, B. F., Rudicell, R. S., Liu, W., Patton, S., Collins, A., Hahn, B. H., Travis, D. A., & Lonsdorf, E. V. (2011). Pathologic lesions in chimpanzees (*Pan troglodytes schweinfurthii*) from Gombe National Park, Tanzania, 2004–2010. *Journal of Zoo and Wildlife Medicine*, 42(4), 597–607. <https://www.ncbi.nlm.nih.gov/pmc/articles/pmc3693847/>
- Terio, K. A., Lonsdorf, E. V., Kinsel, M. J., Raphael, J., Lipende, I., Collins, A., Li, Y., Hahn, B. H., Travis, D. A., & Gillespie, T. R. (2018). Oesophagostomiasis in non-human primates of gombe national park, Tanzania. *American Journal of Primatology*, 80(1), e22572. <https://doi.org/10.1002/ajp.22572>
- Toft, J. D. (1986). The pathoparasitology of nonhuman primates: A review. In K. Benirschke (Ed.), *Primates. Proceedings in Life Sciences* (pp. 601–602). Springer. https://doi.org/10.1007/978-1-4612-4918-4_45
- Wittig, R. M., & Boesch, C. (2019). Demography and life history of five chimpanzee communities in Tai National Park. In C. Boesch, & R. Wittig (Eds.), *The chimpanzees of the Tai forest: 40 years of research* (pp. 125–140). Cambridge University Press.
- Yalcindag, E., Stuart, P., Hasegawa, H., Streit, A., Doležalová, J., Morrogh-Bernard, H., Cheyne, S. M., Nurcahyo, W., & Foitová, I. (2021). Genetic characterization of nodular worm infections in Asian apes. *Scientific Reports*, 11(1), 7226. <https://doi.org/10.1038/s41598-021-86518-2>

How to cite this article: Jaffe, J. E., Metzger, S., Mätz-Rensing, K., Ribas, A., Wittig, R. M., & Leendertz, F. H. (2024). *Oesophagostomum stephanostomum* causing parasitic granulomas in wild chimpanzees (*Pan troglodytes verus*) of Tai National Park, Côte d'Ivoire. *American Journal of Primatology*, 86, e23652. <https://doi.org/10.1002/ajp.23652>