



# Milestone Operations in Heart Valve and Aortic Replacement: Anniversaries Worth Remembering

Uberto Bortolotti, MD<sup>1</sup>  Igor Vendramin, MD<sup>1</sup> Aldo D. Milano, MD, PhD<sup>2</sup> Ugolino Livi, MD<sup>1</sup>

<sup>1</sup> Cardiothoracic Department, University Hospital, Udine, Italy

<sup>2</sup> Division of Cardiac Surgery, University Hospital, Bari, Italy

**Address for correspondence** Uberto Bortolotti, MD, Cardiothoracic Department, Division of Cardiac Surgery, P. le S.M. Misericordia 15, 33100 Udine, Italy (e-mail: uberto48@gmail.com).

Aorta (Stamford)

## Abstract

Seventy years ago, in 1952, Charles A. Hufnagel implanted a caged-ball prosthesis into the descending thoracic aorta, to treat a patient with aortic valve insufficiency. In 1962, 60 years ago, the first aortic homograft was implanted in a subcoronary position by Donald N. Ross and Brian G. Barratt-Boyes. Forty years ago, in 1982, the first anticalcification treatment was introduced in commercially manufactured porcine bioprostheses. All such important or even milestone events should be remembered, since they witness efforts made by those who have significantly influenced the clinical history of aortic and valvular diseases.

## Keywords

- ▶ cardiac surgery
- ▶ aortic surgery
- ▶ aortic valve replacement
- ▶ history

*Study the past if you would define the future*

– Confucius

## Introduction

Celebrating anniversaries of important surgical procedures performed in the past is not just a simple historical exercise. Rather, this is the right way to remember events witnessing the courage and ingenuity of pioneers who attempted what at present are considered almost routine undertakings. This is particularly true when we consider the enormous progress reached in cardiac surgery in the current era. Indeed, we should never forget that many of the operations and devices employed at present derive from old ideas, often initially neglected, and subsequently successfully revitalized in recent years.<sup>1</sup> The year 2022 marks some significant anniversaries in aortic and heart valve surgery, which are briefly remembered in the following review (▶ **Table 1**).

## Pioneering the Treatment of Aortic Insufficiency

Seventy years ago, in 1952, Charles A. Hufnagel performed the first implantation of a caged-ball prosthesis into the descending aorta in a patient with native aortic valve insufficiency.<sup>2</sup> The device was made of a tubular chamber of methylmethacrylate containing a hollow ball. It was inserted into both cut ends of an excised segment of the aorta and fixed in place using flexible rings around the grooves at both ends of the tube.

This was obviously a palliative operation, since valve replacement with orthotopic prosthesis implantation would have become possible only some 8 years later after the clinical application of the heart-lung machine. Nevertheless, this operation provided satisfactory results in some patients up to 6 years of follow-up in the authors' series.<sup>3</sup> The Hufnagel prosthesis was intended as a sort of aortic-assist device, since it did not replace the aortic valve, but it proved useful in assisting patients with significant aortic valve incompetence, reducing considerably the amount of regurgitation. Nevertheless, a pathological report by Fishbein and

received

June 18, 2022

accepted after revision

April 7, 2023

DOI <https://doi.org/>

10.1055/s-0044-1779499.

ISSN 2325-4637.

© 2024. The Author(s).

This is an open access article published by Thieme under the terms of the Creative Commons Attribution-NonDerivative-NonCommercial-License, permitting copying and reproduction so long as the original work is given appropriate credit. Contents may not be used for commercial purposes, or adapted, remixed, transformed or built upon. (<https://creativecommons.org/licenses/by-nc-nd/4.0/>)

Thieme Medical Publishers, Inc., 333 Seventh Avenue, 18th Floor, New York, NY 10001, USA

**Table 1** Anniversary of some historical events celebrated in 2022

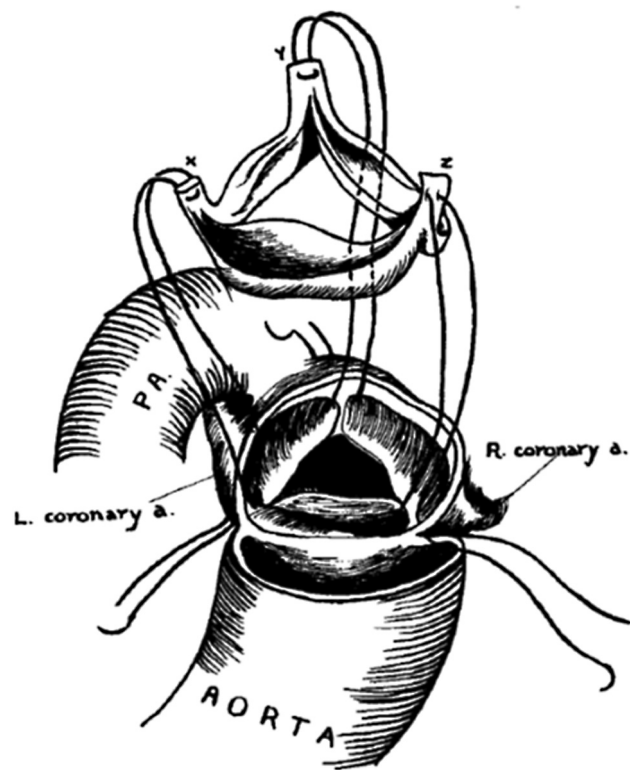
Event	Authors, Ref.#	Year
First implant of a caged-ball prosthesis into the descending aorta	Hufnagel and Harvey <sup>2</sup>	1952
Description of the technique for aortic homograft insertion	Duran and Gunning <sup>8</sup>	1962
First implantation of an aortic homograft in subcoronary position	Ross <sup>9</sup> and Barratt-Boyes <sup>11</sup>	1962
First use of a homograft as combined aortic valve and aortic root replacement	Somerville and Ross <sup>12</sup>	1972
First anticalcification treatment used in manufacture of biological prostheses	Wright et al <sup>21</sup>	1982

Roberts has indicated that a Hufnagel prosthesis, explanted at necropsy up to 13 years' postimplant, was still functioning well without any sign of thrombosis or ball variance.<sup>4</sup>

The advent of extracorporeal circulation and the availability of the first mechanical caged-ball prostheses made the Hufnagel principle outdated.<sup>5,6</sup> However, in 1993, it was revitalized by Cale et al who implanted mechanical prostheses into the thoracic aorta in patients with failing aortic bioprostheses, who were considered inoperable, achieving good medium-term survival.<sup>7</sup>

### Homografts for Aortic Valve and Root Replacement

Sixty years ago, in 1962, Duran and Gunning described the technique for implanting an aortic homograft to replace the aortic valve.<sup>8</sup> They used three guiding commissural stitches followed by running sutures to fix the homograft in subcoronary position (►Fig. 1). This technique was the same utilized by Donald N. Ross in London, United Kingdom, in the

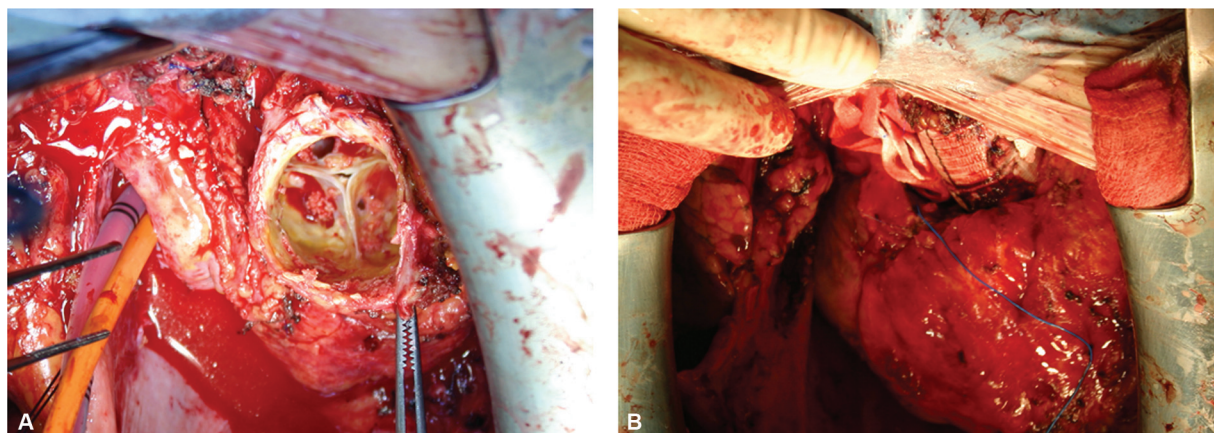


**Fig. 1** Technique of implantation of an aortic homograft showing the fixation and anchoring points as described by Duran and Gunning.<sup>8</sup> (Reproduced with permission of Duran and Gunning 1962.<sup>8</sup>)

same year to implant the first aortic homograft,<sup>9</sup> and interestingly, both procedures were published in the same issue of *The Lancet*. The operation was successfully carried out in a 43-year-old man with calcific aortic stenosis and the author concluded that: "Owing to the small selection of prepared homografts available, the one inserted was rather smaller than was considered desirable. A little redundancy of cusp substance is desirable to allow for possible shrinkage and retraction." During surgery also an atrial septal defect was closed and the patient was kept on anticoagulants and steroids to reduce the inflammatory reaction.<sup>9</sup> Information regarding follow-up of this patient is available from a review by Hopkins et al<sup>10</sup> according to whom the patient survived approximately 3 years without evident aortic valve dysfunction; he died of cardiac failure related to the advanced stage of the initial disease at time of operation. In the same year and only 1 week later, independently from Ross' operation, Brian G. Barratt-Boyes in Auckland, New Zealand, started to implant homografts in patients with aortic stenosis and incompetence.<sup>11</sup> The technique employed was similar to that previously described with some modifications. After 3-stay sutures were passed through the native aortic ring and the left ventricular outflow tract, "the valve was then lowered into position and inverted down into the cavity of the left ventricle so that the aortic ring presented as the most superficial part of the prosthesis, and the three sutures were tied."<sup>11</sup> Then after finishing the proximal suture line, the graft was pulled upward into its final position and the uppermost points of each cusp attachment were sutured to the aortic wall just above the recipient's cusp remnant, completing the procedure with continuous sutures of the graft aortic wall with the remnants of the host cusps.<sup>11</sup>

Some years later, Somerville and Ross<sup>12</sup> reported an initial series of patients in whom a homograft was used in patients with congenital malformations characterized by obstruction to the left ventricular outflow. In such cases the valved homograft was used to replace the aortic valve and the aortic root with subsequent reimplantation of the coronary ostia; the first of such operations was performed by Ross in 1972 to replace an infected Starr-Edwards prosthesis.<sup>12</sup>

These operations contributed to the great initial success of homografts as replacement for diseased aortic valves; later, once commercially manufactured mechanical and biological prostheses were made available, homografts became less attractive mainly due to problems in procurement and availability and in some cases for technical difficulties encountered during implant. Also, homografts have shown a



**Fig. 2** (A) Intraoperative view of a calcified homograft used as aortic valve and root replacement. Total calcification of the homograft root and of the aortic annulus prevented isolated aortic valve replacement. (B) The entire homograft had to be explanted and replaced with a mechanical conduit of a complex redo modified Bentall procedure.

limited durability, and redo procedures generally represent a technical challenge. This is particularly true, especially when they are used as root replacement, since in most cases the homograft aorta becomes calcified, rendering a repeat modified Bentall procedure extremely cumbersome and hazardous<sup>13</sup> (► **Fig. 2**). Currently, the use in such and similar cases of a sutureless bioprosthesis represents a valid and low-risk alternative solution.<sup>14</sup>

Interestingly, also users of aortic homografts have taken advantage of the Hufnagel experience. The initial successful experimental studies of Murray et al,<sup>15</sup> reported in 1956, who implanted a homograft in the descending aorta of dogs after creating aortic regurgitation, were replicated by Beall et al in 1961.<sup>16</sup> Such results stimulated others to pursue the clinical application of this procedure. Bigelow et al<sup>17</sup> reported in 1964 an initial series of patients with aortic regurgitation in whom a homograft aortic cylinder containing the aortic valve was implanted into the descending aorta after suture of the coronary ostia; there was evidence that the valve functioned up to 8 years and, in patients who died after discharge, death was related to progression of uncorrected cardiac lesions.

Homografts are still used today but are mainly employed in the setting of acute infective endocarditis.<sup>18</sup>

### Increasing Durability of Bioprosthetic Valves

Several clinical and pathological studies have demonstrated that structural deterioration due to progressive tissue mineralization is the leading cause of porcine bioprosthetic failure<sup>19,20</sup>; as a consequence, methods that could prevent or at least retard or minimize cusp calcification would contribute to enhance valve durability.

In 1982, 40 years ago, the first calcium-retarding treatment was introduced in the manufacture of porcine bioprostheses. The T<sub>6</sub> process, consisting of the detergent sodium dodecyl sulphate, was demonstrated to reduce tissue mineralization in animal experiments and was first employed in the production of the Hancock II valve where T<sub>6</sub> was added during tissue processing.<sup>21</sup> The clinical results

obtained with this new-generation bioprosthesis were extremely promising,<sup>22</sup> stimulating other companies to test the efficacy of different methods and treatments to find the most effective anticalcification agents. All such clinical and experimental experiences have provided a current generation of extremely reliable stented porcine bioprostheses with a documented long-term performance and durability up to 15 to 20 years of follow-up.<sup>23,24</sup>

### Conclusion

Each of the previously described moments are to be considered as real milestones that have influenced the history of heart valve and aortic disease and are worth to be always remembered. All young generations of cardiac surgeons should be aware of such historical developments, which will stimulate them to pursue similarly successful achievements.

#### Funding

None.

#### Conflict of Interest

The authors declare no conflict of interest related to this article.

#### Acknowledgments

None.

### References

- De Martino A, Falcetta G, Milano AD, Bortolotti U. Modern concepts from old ideas in manufacture of cardiac valve prostheses. *Indian J Thorac Cardiovasc Surg* 2020;36(05):502–505
- Hufnagel CA, Harvey WP. The surgical correction of aortic regurgitation preliminary report. *Bull- Georget Univ Med Cent* 1953;6(03):60–61
- Hufnagel CA, Gomes MN. Late follow-up of ball-valve prostheses in the descending thoracic aorta. *J Thorac Cardiovasc Surg* 1976; 72(06):900–909
- Fishbein MC, Roberts WC. Late postoperative anatomic observations after insertion of Hufnagel caged-ball prosthesis in descending thoracic aorta. *Chest* 1978;65:6–11

- 5 De Martino A, Milano AD, Thiene G, Bortolotti U. Diamond anniversary of mechanical heart valve prostheses. A tale of cages, balls and discs. *Ann Thorac Surg* 2020;110(04):1427–1433
- 6 De Martino A, Milano AD, Barbera MD, Thiene G, Bortolotti U. The caged-ball prosthesis 60 years later. Historical review of a cardiac surgery milestone. *Tex Heart Inst J* 2022;49(02):e207267
- 7 Cale ARJ, Sang CTM, Campanella C, Cameron EWJ. Hufnagel revisited: a descending thoracic aortic valve to treat prosthetic valve insufficiency. *Ann Thorac Surg* 1993;55(05):1218–1221
- 8 Duran CG, Gunning AJ. A method for placing a total homologous aortic valve in the subcoronary position. *Lancet* 1962;2(7254):488–489
- 9 Ross DN. Homograft replacement of the aortic valve. *Lancet* 1962;2(7254):487
- 10 Hopkins RA, St Louis J, Corcoran PC. Ross' first homograft replacement of the aortic valve. *Ann Thorac Surg* 1991;52(05):1190–1193
- 11 Barratt-Boyes BG. Homograft aortic valve replacement in aortic incompetence and stenosis. *Thorax* 1964;19(02):131–150
- 12 Somerville J, Ross D. Homograft replacement of aortic root with reimplantation of coronary arteries. Results after one to five years. *Br Heart J* 1982;47(05):473–482
- 13 Ravenni G, Pratali S, Sciotti G, Bortolotti U. Total calcification of an aortic homograft used as aortic root replacement. *J Cardiovasc Med (Hagerstown)* 2011;12(03):191–192
- 14 Vendramin I, Lechiancole A, Piani D, et al. Use of sutureless and rapid deployment prostheses in challenging reoperations. Review of the current evidence. *J Cardiovasc Dev Dis* 2021;8(07):74
- 15 Murray G, Roschlau W, Loughheed W. Homologous aortic-valve-segment transplants as surgical treatment for aortic and mitral insufficiency. *Angiology* 1956;7(05):466–471
- 16 Beall AC Jr, Morris GC Jr, Cooley DA, De Bakey E. Homotransplantation of the aortic valve. *J Thorac Cardiovasc Surg* 1961;42:497–506
- 17 Bigelow WG, Yao JK, Aldridge HE, Heimbecker RO, Murray GDW. Clinical homograft valve transplantation. *J Thorac Cardiovasc Surg* 1964;48:333–345
- 18 Solari S, Mastrobuoni S, De Kerchove L, et al. Over 20 years experience with aortic homograft in aortic valve replacement during acute infective endocarditis. *Eur J Cardiothorac Surg* 2016;50(06):1158–1164
- 19 Milano A, Bortolotti U, Talenti E, et al. Calcific degeneration as the main cause of porcine bioprosthetic valve failure. *Am J Cardiol* 1984;53(08):1066–1070
- 20 Bortolotti U, Milano AD, Valente M, Thiene G. The stented porcine bioprosthesis. A 50-year journey through hopes and realities. *Ann Thorac Surg* 2019;108(01):304–308
- 21 Wright JTM, Eberhardt CE, Gibbs ML, Saul T, Gilpin CB. Hancock II – an improved bioprosthesis. In: Cohn LH, Gallucci V, eds. *Cardiac Bioprostheses*. New York, NY: Yorke Med Books; 1982: 425–424
- 22 Bortolotti U, Milano A, Mazzaro E, Thiene G, Talenti E, Casarotto D. Hancock II porcine bioprosthesis: excellent durability at intermediate-term follow-up. *J Am Coll Cardiol* 1994;24(03):676–682
- 23 Celiento M, Blasi S, De Martino A, Pratali S, Milano AD, Bortolotti U. The Mosaic mitral valve bioprosthesis: a long-term clinical and hemodynamic follow-up. *Tex Heart Inst J* 2016;43(01):13–19
- 24 Celiento M, Ravenni G, Tomei L, Pratali S, Milano AD, Bortolotti U. Excellent durability of the Mosaic aortic bioprosthesis at extended follow up. *J Heart Valve Dis* 2018;27(01):97–103