

## EDITORIAL COMMENT

# Integrated Imaging to Investigate Low-Flow Alarms of Left Ventricular Assist Devices\*



Alberto Aimo, MD,<sup>a</sup> Giacomo Bianchi, MD, PhD,<sup>b</sup> Giuseppe Vergaro, MD, PhD<sup>a,c</sup>

With the ongoing shortage of available organs for heart transplantation, mechanical circulatory support devices have been increasingly used to manage acute and chronic heart failure that is refractory to medical therapy (1). In particular, the introduction of left ventricular (LV) assist devices (LVADs) has revolutionized this field, by extending life as either a bridge to transplantation or a destination therapy (1). Although first-generation devices provided pulsatile flow, current LVAD devices produce continuous flow and are further classified according to their impeller technology (i.e., axial or centrifugal). Normal components include the pump, inflow and outflow cannulas, a driveline, and an external controller. Clinical trials and real-world experience have revealed the possibility of many potentially life-threatening complications (2). These complications can be categorized as LVAD-specific and LVAD-associated complications, and many of them can result in severe patient morbidity and mortality (2). LVAD-specific complications include device malfunctioning or failure, pump thrombosis, and suction events, whereas LVAD-

associated complications include bleeding, cerebrovascular events, infection, right ventricular failure, arrhythmias, and aortic regurgitation (2).

The evaluation and management of patients with LVAD require a team-based approach, and consultation with an LVAD specialist is recommended (3).

LVAD dysfunction may be indicated by device alarm systems sensing a low pump flow, possibly associated with LVAD power spikes, ventricular arrhythmias, or clinical evidence of pulmonary congestion or tissue hypoperfusion. The first step in evaluating the patient with alarms reported by the LVAD controller is the assessment of clinical status, to determine the treatment priority and the setting where the patient should be treated (i.e., medical department or intensive care unit).

One of the complications that can generate a low-flow alarm is pump thrombosis. Thrombosis of the device can occur in any of its parts (inflow cannula, rotor, outflow cannula, and distal anastomosis zone) and recognizes different causes depending on the zone. At the inflow level, thrombosis can be determined by inadequate myectomy at the time of device implantation or by positioning against the interventricular septum. At the impeller level, it is influenced by the design of the pump itself (axial vs. centrifugal, fully magnetic levitation vs. magnetic rotation with blood displacement) and by operational rotations per minute. At the outflow graft level, thrombosis can occur by twisting, kinking, or *ab extrinseco* compression, as well as by fibrin platelet thrombosis.

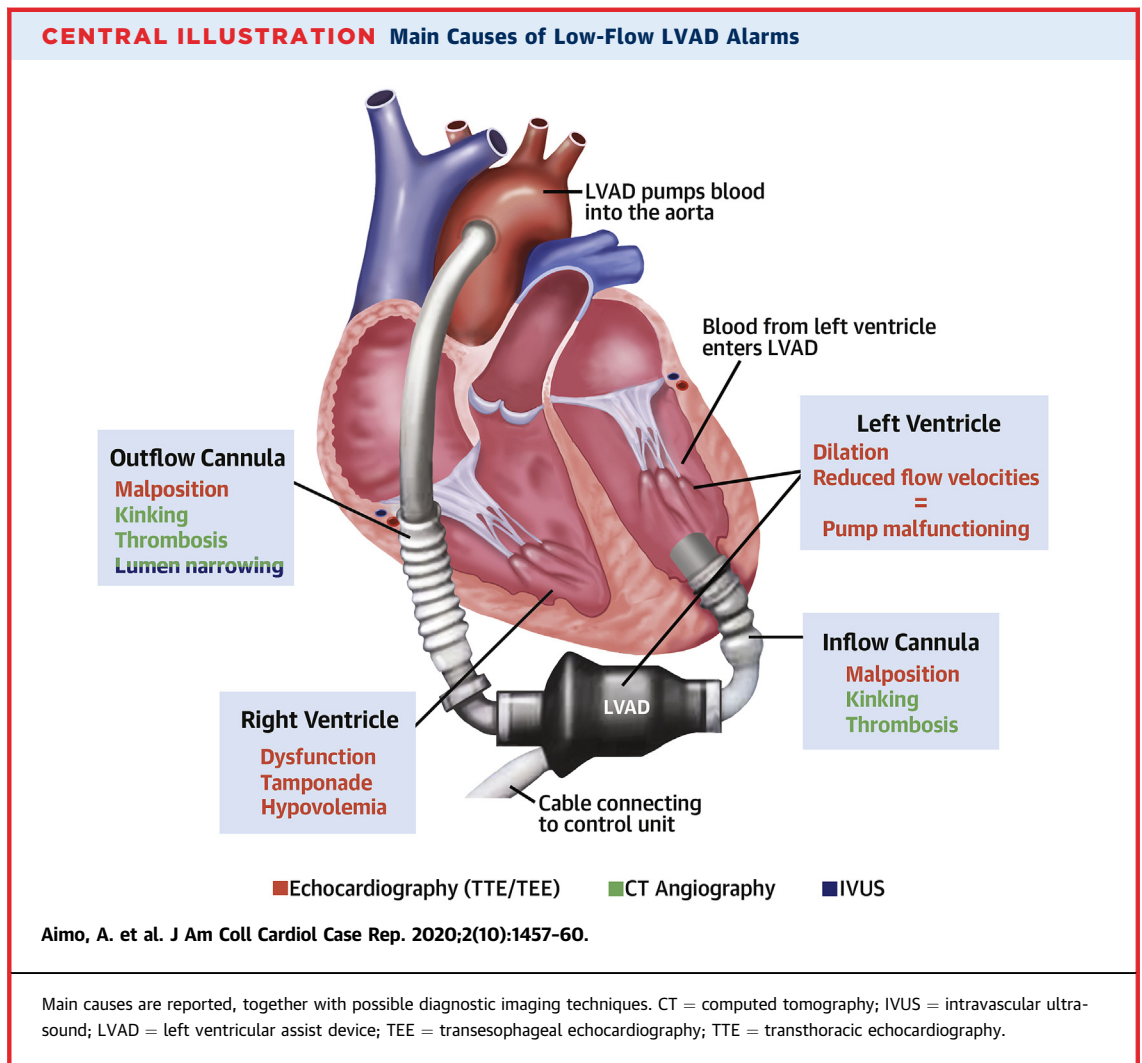
In suspected pump thrombosis, laboratory examination is crucial because it can predict pump thrombosis at an early stage, before machine alarms sound or imaging is obtained (4). Combining an elevated lactate dehydrogenase (LDH) and plasma-free

---

\*Editorials published in *JACC: Case Reports* reflect the views of the authors and do not necessarily represent the views of *JACC: Case Reports* or the American College of Cardiology.

From the <sup>a</sup>Institute of Life Sciences, Scuola Superiore Sant'Anna, Pisa, Italy; <sup>b</sup>Division of Adult Cardiac Surgery, Fondazione Toscana Gabriele Monasterio, Massa, Italy; and the <sup>c</sup>Division of Cardiology and Cardiovascular Medicine, Fondazione Toscana Gabriele Monasterio, Pisa, Italy. The authors have reported that they have no relationships relevant to the contents of this paper to disclose.

The authors attest they are in compliance with human studies committees and animal welfare regulations of the authors' institutions and Food and Drug Administration guidelines, including patient consent where appropriate. For more information, visit the *JACC: Case Reports* [author instructions page](#).



hemoglobin reading with other common markers for hemolysis, such as reduced levels of hemoglobin, hematocrit, and haptoglobin and increased indirect bilirubin levels, is strongly suggestive of ongoing hemolysis from pump thrombosis.

Multimodality imaging is then crucial to refine or rule out the pump thrombosis and its location. Chest radiography allows assessment of the position of the inflow cannula and the presence of pulmonary congestion secondary to insufficient unloading (from outflow obstruction). Transthoracic echocardiography (TTE) is the primary imaging modality to facilitate pre-LVAD management and for post-implantation monitoring because it is noninvasive, is widely available, and can be performed at the bedside (5). A comprehensive LVAD evaluation consists of standard TTE with a focus on biventricular size and function, valvular function, velocities in the

inflow and outflow conduits, contribution of the native left ventricle and LVAD to systemic flow, pulmonary pressures, and evidence of LV recovery (5). Investigators have proposed performing baseline TTE 2 weeks after implantation and then routinely every 3 to 6 months and as clinically indicated (5). If echocardiographic evaluation is technically difficult despite the use of a contrast agent, transesophageal echocardiography is usually performed when LVAD dysfunction or other complications are suspected (5).

Cardiac computed tomography (CT) angiography can be used if there is persistent clinical concern for inflow-outflow graft thrombosis or malposition in the setting of a nondiagnostic echocardiogram (6). CT angiography allows an accurate evaluation of LVAD cannulas. Unlike echocardiography, CT angiography is not limited by acoustic windows and lacks acoustic shadowing. Furthermore, LVAD cannulas can be

interrogated from multiple views, thus permitting direct visualization (6). The sensitivity and specificity of CT angiography to detect cannula thrombosis or inflow cannula malposition by using intraoperative findings as the gold standard are as high as 85% and 100%, respectively (7). Possible limitations of CT angiography are the need for radiation exposure and the risk of nephrotoxicity from iodinated contrast agents (5). Additionally, when there is evidence of outflow graft lumen narrowing in the portion covered by the bend relief, CT angiography does not allow the clinician to discriminate between intraluminal thrombosis and extrinsic compression by biodebris between the bend relief and the outflow graft, although treatment of these 2 conditions is radically different (e.g., anticoagulation vs. percutaneous stenting within the graft) (8). Narrowing of the outflow graft lumen is not a rare occurrence; it was found in 14% of patients in a recent case series (8). Apart from direct surgical revision of the device, luminal thrombosis and extrinsic compression can be differentiated by invasive graft examination with intravascular ultrasound (8).

In this issue of *JACC: Case Reports*, Asawaer et al. (9) reappraised the topics of LVAD complications and the choice of imaging techniques for identification of these complications. They reported the case of a 66-year-old man who underwent HeartMate II (Abbott Laboratories, Abbott Park, Illinois) LVAD implantation in 2013 for end-stage ischemic heart failure and who recently presented with exertional dyspnea and low-flow, high-power LVAD alarms. Laboratory examinations showed an international normalized ratio lower than the therapeutic range and elevated LDH levels, 2 findings that were compatible with (but by no means specific for) thrombotic events. This prompted the treating physicians to start anticoagulation therapy with bivalirudin, which did not prevent further LDH elevation. Echocardiography revealed inflow and outflow velocities ranging around the upper reference limit (2 m/s) (10). The patient underwent pump exchange through a left

subcostal incision, but outflow cannula velocity rose to 3.5 m/s immediately after the exchange. At this point, CT angiography revealed an obstruction of the outflow cannula secondary to kinking and twisting, which were apparently attributed to device replacement. Interestingly, evaluation of the explanted pump showed thrombosis of the inflow stator region, which was considered the original cause of the low-flow alarm (9).

Asawaer et al. (9) should be commended for presenting this interesting case and also for providing a simple diagnostic flowchart for the use of imaging techniques to assess patients with low-flow alarms. A schematic depiction of the main causes of low-flow LVAD alarms is provided in the **Central Illustration**. The first-line imaging examination is TTE, which may be augmented by the use of ultrasound contrast agents or transesophageal echocardiographic evaluation. Echocardiography should allow the clinician to evaluate cannula position, flow velocities, and biventricular size and function. The **Central Illustration** shows the following possibilities: malposition of the inflow or outflow cannula, right ventricular dysfunction, indirect evidence of pump malfunctioning (increased LV size with reduced flow velocities), pericardial tamponade, or inconclusive findings (particularly increased flow velocities with an unclear mechanism). In the last case, problems with the inflow or outflow cannulas (thrombosis, malpositioning, or kinking) can be readily detected by CT angiography. As stated earlier, CT angiography does not allow discrimination between intraluminal thrombosis and extrinsic compression of the outflow graft. Therefore, intravascular ultrasound evaluation or direct surgical revision of the device is warranted.

---

**ADDRESS FOR CORRESPONDENCE:** Dr. Giuseppe Vergaro, Division of Cardiology and Cardiovascular Medicine, Fondazione Toscana Gabriele Monasterio, Via Moruzzi, 1, 56124 Pisa, Italy. E-mail: [vergaro@ftgm.it](mailto:vergaro@ftgm.it).

---

## REFERENCES

1. Kadakia S, Moore R, Ambur V, Toyoda Y. Current status of the implantable LVAD. *Gen Thorac Cardiovasc Surg* 2016;64:501-8.
2. Long B, Robertson J, Koefman A, Brady W. Left ventricular assist devices and their complications: a review for emergency clinicians. *Am J Emerg Med* 2019;37:1562-70.
3. Cook JL, Colvin M, Francis GS, et al. Recommendations for the use of mechanical circulatory support: ambulatory and community patient care: a scientific statement from the American Heart Association. *Circulation* 2017;135:e1145-58.
4. Bartoli CR, Ghotra AS, Pachika AR, Birks EJ, McCants KC. Hematologic markers better predict left ventricular assist device thrombosis than echocardiography or pump parameters. *Thorac Cardiovasc Surg* 2014;62:414-8.
5. Estep JD, Stainback RF, Little SH, et al. The role of echocardiography and other imaging modalities in patients with left ventricular assist devices. *J Am Coll Cardiol Intv* 2010;3:1049-64.
6. Barac YD, Nevo A, Schroder JN, et al. LVAD Outflow graft role in pump thrombosis. *ASAIO J* 2020;66:128-31.
7. Raman SV, Sahu A, Merchant AZ, et al. Noninvasive assessment of left ventricular assist devices with cardiovascular computed tomography and impact on management. *J Heart Lung Transplant* 2010;29:79-85.

8. Trankle CR, Grizzard JD, Shah KB, et al. Left ventricular assist device outflow graft compression: incidence, clinical associations and potential etiologies. *J Card Fail* 2019;25:545-52.

9. Asawaer M, Kadir S, Albulushi A, Castleberry AW, Chatzizisis YS. Left ventricular

assist device outflow cannula obstruction: importance of multimodality imaging. *J Am Coll Cardiol Case Rep* 2020;2:1454-6.

10. Stainback RF, Estep JD, Agler DA, et al. Echocardiography in the management of patients with left ventricular assist devices: recommenda-

tions from the American Society of Echocardiography. *J Am Soc Echocardiogr* 2015;28:853-909.

---

**KEY WORDS** cardiac assist devices, cardiomyopathy, computed tomography