

12-1-2023

## Pelvic infection caused by periodontitis: A case report

Cuihong Tian  
*Edith Cowan University*

Hongle Yan

Ping Tang

Jinqiu Shi

Maolian Liang

*See next page for additional authors*

Follow this and additional works at: <https://ro.ecu.edu.au/ecuworks2022-2026>



Part of the [Medicine and Health Sciences Commons](#)

---

[10.1016/j.crwh.2023.e00563](https://doi.org/10.1016/j.crwh.2023.e00563)

Tian, C., Yan, H., Tang, P., Shi, J., Liang, M., Wan, Y., . . . Qin, C. (2023). Pelvic infection caused by periodontitis: A case report. *Case Reports in Women's Health*, 40, article e00563. <https://doi.org/10.1016/j.crwh.2023.e00563>


This Journal Article is posted at Research Online.

<https://ro.ecu.edu.au/ecuworks2022-2026/3545>

---

**Authors**

Cuihong Tian, Hongle Yan, Ping Tang, Jinqiu Shi, Maolian Liang, Yanyan Wan, Weiping Li, Xizhuo Sun, and Chenglu Qin



## Pelvic infection caused by periodontitis: A case report

Cuihong Tian<sup>a,b,c,d,1</sup>, Hongle Yan<sup>c,1</sup>, Ping Tang<sup>e</sup>, Jinqiu Shi<sup>f</sup>, Maolian Liang<sup>f</sup>, Yanyan Wan<sup>g</sup>, Weiping Li<sup>c,h</sup>, Xizhuo Sun<sup>i,\*\*</sup>, Chenglu Qin<sup>f,\*</sup>

<sup>a</sup> Clinical Research Center, Luohu Clinical College of Shantou University Medical College, Shenzhen, Guangdong 518001, China

<sup>b</sup> Clinical Research Center, First Affiliated Hospital of Shantou University Medical College, Shantou, Guangdong 515041, China

<sup>c</sup> Department of Cardiology, First Affiliated Hospital of Shantou University Medical College, Shantou, Guangdong 515041, China

<sup>d</sup> Center for Precision Health, Edith Cowan University, Perth, WA 6027, Australia

<sup>e</sup> Department of General Practice, Luohu Clinical College of Shantou University Medical College, Shenzhen, Guangdong 518001, China

<sup>f</sup> Department of Obstetrics and Gynecology, Luohu Clinical College of Shantou University Medical College, Shenzhen, Guangdong 518001, China

<sup>g</sup> Department of Science and Education, Luohu Clinical College of Shantou University Medical College, Shenzhen, Guangdong 518001, China

<sup>h</sup> Department of Information, First Affiliated Hospital of Shantou University Medical College, Shantou, Guangdong 515041, China

<sup>i</sup> Department of Oncology Immunology, Luohu Hospital Group, Shenzhen, Guangdong 518001, China

### ARTICLE INFO

#### Keywords:

Periodontitis  
Periodontal pathogen  
Hematogenous dissemination  
Pelvic infection  
Metagenomic next-generation sequencing (mNGS)

### ABSTRACT

Oral bacteria in patients with periodontitis can disseminate into the bloodstream via broken oral epithelial cells, causing odontogenic maxillofacial infections, brain abscesses and endocarditis. However, pelvic infection caused by periodontitis is rare. The case of a 48-year-old woman with a long history of recurrent periodontal infections, who complained of abdominal distention and pain for 14 days after dental implantation, is reported here. Pelvic ultrasound and magnetic resonance imaging signaled multiple inflammatory encapsulated effusions in the posterior uterus, which were removed by laparoscopic surgery and tested with metagenomic next-generation sequencing (mNGS). Through mNGS, numerous oral pathogens, including *Filifactor alocis*, were identified in the pelvic effusions. The patient was subsequently diagnosed with a pelvic infection originating from periodontitis, and recovered after undergoing surgery and targeted antibacterial treatment. Thus, the possibility of extrabuccal complications in patients with a history of periodontitis or invasive oral procedures merits closer attention.

### 1. Introduction

Periodontitis, a chronic inflammatory disease caused by pathogenic bacteria in dental plaque invading periodontal tissue, can cause redness and swelling of the gingiva, pyorrhea of the periodontal pocket, and pathologic destruction of the alveolar bone and periodontal ligament. It is the main reason for tooth loss in adults [1]. Periodontitis mainly occurs in people over 35 years old (who account for approximately one-third of the global population), and its prevalence increases to 70% in individuals over 65 years of age [2].

In addition to chronic inflammation of periodontal tissue,

periodontal pathogenic bacteria can also be responsible for extrabuccal infections, such as brain abscesses, empyema and endocarditis, after entering the bloodstream through broken oral epithelial cells [3]. However, pelvic infection caused by oral pathogenic bacteria is rare, often resulting in delayed or incorrect diagnosis and treatment. A case of pelvic infection secondary to periodontitis is reported in this article, in order to enhance understanding for clinicians of this uncommon complication in patients with a common disease.

**Abbreviations:** mNGS, metagenomic next-generation sequencing; MRI, magnetic resonance imaging.

\* Correspondence to: C. Qin, Department of Obstetrics and Gynecology, Luohu Clinical College of Shantou University Medical College, No. 3019 Chunfeng Road, Luohu District, Shenzhen, Guangdong 518001, China.

\*\* Correspondence to: X. Sun, Department of Oncology Immunology, Luohu Hospital Group, No. 3019 Chunfeng Road, Luohu District, Shenzhen, Guangdong 518001, China.

E-mail addresses: [xizhuomd@163.com](mailto:xizhuomd@163.com) (X. Sun), [clqin@163.com](mailto:clqin@163.com) (C. Qin).

<sup>1</sup> Cuihong Tian and Hongle Yan contributed equally to this work.

<https://doi.org/10.1016/j.crwh.2023.e00563>

Received 2 October 2023; Received in revised form 7 November 2023; Accepted 8 November 2023

Available online 10 November 2023

2214-9112/© 2023 The Authors. Published by Elsevier B.V. This is an open access article under the CC BY-NC-ND license (<http://creativecommons.org/licenses/by-nc-nd/4.0/>).

## 2. Case Presentation

A 48-year-old woman with a history of recurrent periodontitis for several years and dental implantation for one month (but no history of oral sex) was admitted to hospital with 14-day abdominal distention and pain. In the month leading to her admission, she experienced progressive abdominal enlargement and gained approximately 5 kg in weight, but denied experiencing fever, diarrhea or other discomfort. Clinical examination conducted at a local hospital revealed a white blood cell level of  $12.08 \times 10^9/L$ , C-reactive protein level of 51.13 mg/l, and the presence of multiple pelvic exudations and effusions visualized by abdominal computed tomography scan. The evidence indicated a potential pelvic infection, but despite treatment with successive antibacterial drugs, including metronidazole, piperacillin-tazobactam and doxycycline for 8 days, there was no significant improvement.

The patient was therefore admitted to a general hospital. Laboratory test data collected throughout her treatment are shown in Table 1. Bacterial cultures of both blood and vaginal secretions yielded negative results. Further, pelvic ultrasound revealed pelvic effusion (Fig. 1a). Pelvic magnetic resonance imaging (MRI) then displayed multiple inflammatory encapsulated effusions, with the largest measuring 116 mm in length (Fig. 1b, c). After ruling out surgical contraindications, a laparoscopic procedure involving pelvic abscess removal, bilateral salpingectomy and abdominal adhesiolysis was performed under general anesthesia.

During intraoperative observation, it was noted that the greater omentum and intestinal tube were densely adhered and encased within a confined pelvic cavity. Upon isolating the adhesion along the abdominal wall, a substantial amount of yellow, friable and easily bleeding purulent material and pus were evident (Fig. 2). Subsequently, a gynecologist promptly aspirated the pus, collected pus samples for bacteria culture and metagenomic next-generation sequencing (mNGS), and sequentially excised the purulent tissues from the pelvic and abdominal regions. The abdominal cavity was then irrigated repeatedly with normal saline and metronidazole, and a negative-pressure drainage tube was placed to remove pus.

The results of bacteria cultures of blood, pelvic pus, vaginal and cervical secretions were negative, while mNGS showed that the dominant pathogenic bacteria in the pus were *Filifactor alocis*, *Porphyromonas gingivalis*, *Campylobacter rectus*, *Fusobacterium nucleatum* and *Actinomyces israelii* (Table 2), most of which are primarily found in the oral cavity. Accordingly, the patient was diagnosed with pelvic infection stemming from periodontitis via blood transmission. Following surgery and treatment with piperacillin-tazobactam and metronidazole, the patient recovered and was subsequently discharged from hospital.

## 3. Discussion

Most bacteria found in dental plaque are normal oral colonization bacteria, which have minimal adverse effects on human health. Only a small number of bacteria, such as *Actinobacillus actinomycetemcomitans*, *Porphyromonas gingivalis* and *Fusobacterium nucleatum*, are significantly associated with periodontal disease. These periodontal pathogens can

**Table 1**  
Hematological test results.

	Day 1*	Day 7	Day 15	Day 20	Day 23
WBC ( $\times 10^9/L$ )	12.08	14.53	12.03	Normal	Normal
PCT (ng/mL)	Normal	/	Normal	/	/
CRP (mg/L)	51.13	67.60	63	32	9
ALB (g/L)	/	/	23.1	30.8	32.2
D-D (mg/L FEU)	/	/	26.88	6.80	7.52

Abbreviations: ALB, albumin; CRP, C-reactive protein; D-D, D dimer; PCT, procalcitonin; WBC, white blood cell.

\* The date when this patient firstly complained of abdominal distention and pain was considered as Day 1.

lead to complications such as aspiration pneumonia, gastrointestinal infection, pleural infection and infective endocarditis, where they can invade broken oral epithelial cells and blood if not prevented and managed in a timely and effective manner [3,4]. In addition, women with periodontitis are at higher risk of stillbirth, miscarriage and fetal death than those without periodontitis [5].

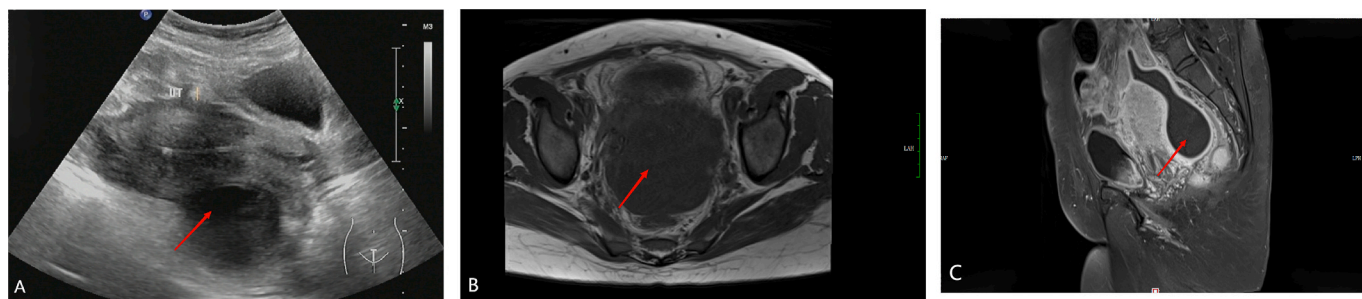
Bacterial culture is regarded as the gold standard for diagnosis of bacterial infection. However, the detection rate is determined by the bacterial load, microbial viability and prior antibiotic use [6]. As a result, recognizing periodontal pathogens through bacterial culture proves challenging, presenting a considerable hurdle in clinical diagnosis and treatment. In this case, bacterial culture of pelvic pus was performed but yielded negative results, which may have resulted from the following factors. Firstly, the bacterial load in pus may not have achieved the threshold for bacterial culture. Secondly, this patient had received anti-bacterial drugs, including metronidazole, piperacillin-tazobactam and doxycycline, for 8 days. As a result, the patient did not have confirmation of the diagnosis.

mNGS, a high-throughput sequencing technique, can determine pathogens of disease by detecting DNA, RNA and other genetic materials of bacteria, fungi, viruses and other microorganisms, and comparing them with nucleic acid sequences of known microorganisms in the database. Although mNGS is expensive, time-consuming, and must also sequence the human host, as a hypothesis-free, unbiased and quantitative mode of testing, it can identify entire microbiota, including rare and potentially pathogenic microorganisms, without the need for culture [7]. mNGS was first clinically applied in 2014, for the clinical diagnosis of neuroleptospirosis in a 14-year-old critically ill boy with meningoencephalitis [8]. Since then, mNGS has been successfully applied for clinical purposes, ranging from characterization of antibiotic resistance to analysis of human host response (transcriptomic) data to predict causes of infection and evaluate disease risk. At present, this emerging technology has proven valuable for patients with fever of unknown origin, critical illnesses and immunodeficiency.

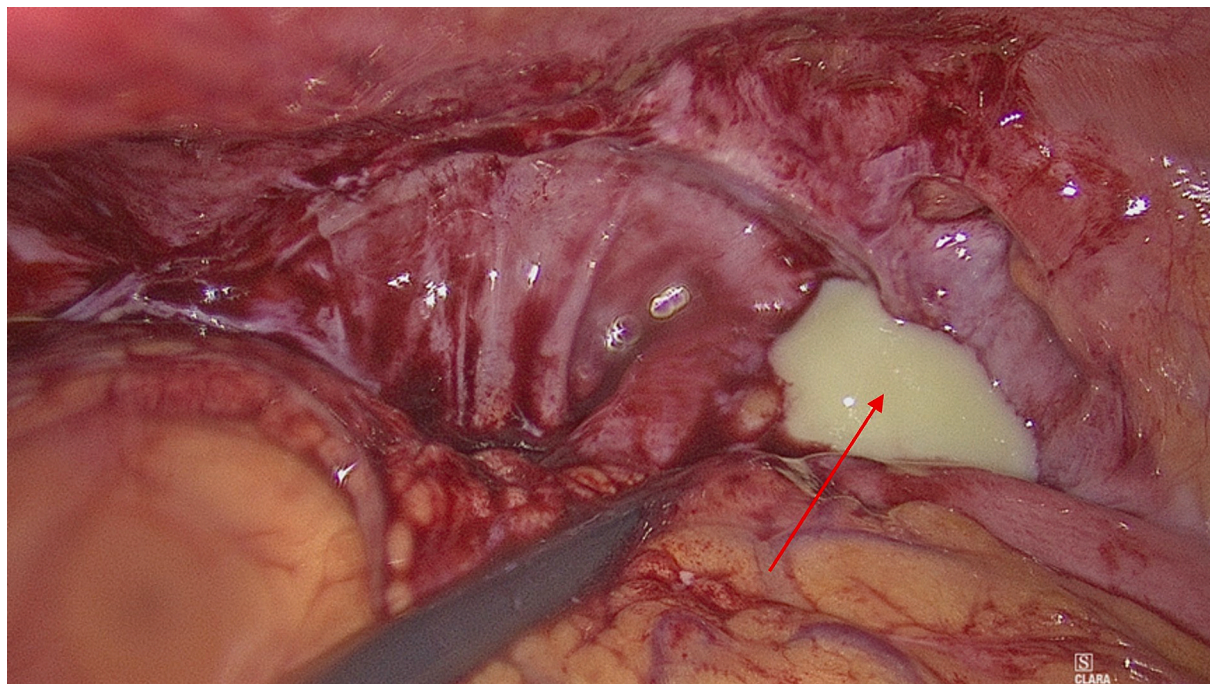
In this case, mNGS was applied to identify the pathogenic microorganisms by detecting and analyzing the nucleic acid sequences of microorganisms in pelvic pus. It was discovered that the predominant pathogenic bacteria responsible for the pelvic effusion in the patient were *Filifactor alocis*, *Porphyromonas gingivalis* and other oral pathogens. No other sources of infection except for periodontitis were identified. In addition, this patient denied a history of oral sex, and bacterial cultures in both vaginal and cervical secretions were negative, which excluded the possibility of a sexual route and upwards spread via genital mucosa. Therefore, based on the above evidence, the patient was diagnosed with a pelvic infection originating from periodontitis through hematogenous dissemination.

Most of the pathogenic bacteria identified by mNGS in the pelvic pus of this patient were oral anaerobes. *Filifactor alocis*, first isolated from the gingival crevice of patients with gingivitis and periodontitis in 1985, is an emerging pathogenic bacterium that plays an important role in the occurrence and development of periodontal disease [9]. *Porphyromonas gingivalis*, mainly residing in the human oral cavity, can contribute to periodontal infections such as gingivitis, periodontitis and pulpitis, as well as extrabuccal infections, including genitourinary tract infections, cavernous sinus thrombophlebitis and osteomyelitis [10]. *Actinomyces israelii* is the major component of the dental plaque flora in healthy populations, and is associated with dental caries, pulpitis and odontogenic abscesses. Primarily parasitic in the oral cavity, *Actinomyces israelii* can cause adjacent facial and neck infections through broken skin, as well as pectoral actinomycosis when inhaled [11].

Periodontal pathogenic bacteria can invade the bloodstream, causing bacteremia and other systemic infections when periodontitis is accompanied by damaged oral epithelial cells and bleeding gums [12]. In addition to broken oral epithelium, periodontal pathogenic bacteria can also access the bloodstream by adhering to and invading intact oral epithelial cells. Additionally, co-culturing *Filifactor alocis* with



**Fig. 1.** Pelvic ultrasound (A), transverse section of basin MRI (B) and sagittal section of basin MRI (C). The red arrows show a pelvic effusion. (For interpretation of the references to colour in this figure legend, the reader is referred to the web version of this article.)



**Fig. 2.** Laparoscopic exploration. The red arrow shows a pelvic effusion. (For interpretation of the references to colour in this figure legend, the reader is referred to the web version of this article.)

**Table 2**  
The mNGS reports of pus.

Genus				Species	
Types	Name	Sequence number	Relevant abundance (%)	Name	Sequence number
G+	<i>Filifactor</i>	1,421,314	38.28	<i>Filifactor alocis</i>	1,421,314
G-	<i>Porphyromonas</i>	558,468	15.04	<i>Porphyromonas gingivalis</i>	555,085
G-	<i>Campylobacter</i>	448,525	12.08	<i>Campylobacter rectus</i>	333,248
G-	<i>Fusobacterium</i>	264,055	7.11	<i>Fusobacterium nucleatum</i>	130,017
G+	<i>Actinomyces</i>	71,858	1.94	<i>Actinomyces israelii</i>	63,254
G-	<i>Prevotella</i>	46,289	1.25	<i>Prevotella loescheii</i>	21,225

Note: G+, Gram-positive bacteria; G-, Gram-negative bacteria; Sequence number: the number of sequences matched to the pathogen, which is related to the load of the pathogen itself, the amount of nucleic acid extraction and the proportion of human sequences in the specimen. The more the sequences are, the higher confidence that the pathogen has been detected in the specimen. Relevant abundance: the proportion of a microorganism in the same type of microorganism detected in the entire specimen. The higher the abundance, the higher proportion of it in the same type of microorganism.

*Porphyromonas gingivalis* further enhances the ability of *Filifactor alocis* to adhere to and invade oral epithelial cells [13]. The mNGS analysis in this case, of a patient with a history of recurrent periodontitis and dental implantation, revealed an abundance of both *Filifactor alocis* and *Porphyromonas gingivalis* in the pelvic pus. This would be the primary factor linking periodontitis to the development of pelvic infection.

It was unfortunate that consent was not given for vaginal, cervical and dental plaque samples to be taken for mNGS. The condition was diagnosed as pelvic infection caused by periodontitis because no other extrabuccal infectious foci were found in the patient, and she recovered after the pelvic abscess-removal surgery and anti-anaerobic treatment. The case report underscores the significance of recognizing periodontitis

as a potential cause of extrabuccal infections, especially in patients who have a history of periodontitis or invasive oral procedures. The report also emphasizes the role of mNGS in identifying rare pathogens, where it is superior to conventional etiological examinations such as bacterial culture, and offers valuable insights into the diagnosis and treatment of such cases.

#### 4. Conclusion

In summary, the pelvis effusions in this case are believed to result from periodontal pathogens spreading through the bloodstream, based on the patient's dental implantation history and the results of mNGS. Potential extrabuccal complications in patients with a history of periodontitis or invasive oral procedures merit closer attention.

#### Contributors

Cuihong Tian contributed to acquiring and interpreting the data and drafting the manuscript.

Hongle Yan contributed to acquiring and interpreting the data, undertaking the literature review and applying to the ethics committee.

Ping Tang contributed to revising the article critically for important intellectual content.

Jinqiu Shi contributed to patient care and acquiring and interpreting the data.

Maolian Liang contributed to patient care and revising the article critically for important intellectual content.

Yanyan Wan contributed to acquiring and interpreting the data and revising the article critically for important intellectual content.

Weiping Li contributed to revising the article critically for important intellectual content.

Xizhuo Sun contributed to conception of the case report, drafting the manuscript and revising the article critically for important intellectual content.

Chenglu Qin contributed to patient care, drafting the manuscript and revising the article critically for important intellectual content.

All authors approved the final submitted manuscript.

#### Funding

This work did not receive any specific grant from funding agencies in the public, commercial, or not-for-profit sectors.

#### Ethical approval

This work was reviewed and approved by the Scientific Research Ethics Committee at Luohu Clinical College of Shantou University Medical College, Shenzhen, China, approval number (2023-LHQRMYY-KYLL-033).

#### Patient consent

Written informed consent was obtained from the patient for publication of this case report and accompanying images.

#### Provenance and peer review

This article was not commissioned and was peer reviewed.

#### Acknowledgements

We would like to express our deep appreciation to Dr. Michael Stein, a Higher Degree Research (HDR) Communication Adviser at Edith Cowan University, Australia, who carefully reviewed and polished the manuscript. Special appreciation also goes to Xuerui Tan, a professional doctor and professor in Clinical Research Center, First Affiliated Hospital of Shantou University Medical College, China, who assisted the analysis and interpretation of this case.

#### Conflict of interest statement

The authors declare that they have no conflict of interest regarding the publication of this case report.

#### References

- [1] R.G. Fischer, R. Lira Junior, B. Retamal-Valdes, L.C. Figueiredo, Z. Malheiros, B. Stewart, et al., Periodontal disease and its impact on general health in Latin America. Section V: treatment of periodontitis, *Braz. Oral Res.* 34 (2020), e026, <https://doi.org/10.1590/1807-3107bor-2020.vol34.0026>.
- [2] A.J. Righolt, M. Jevdjevic, W. Marcenes, S. Listl, Global-, regional-, and country-level economic impacts of dental diseases in 2015, *J. Dent. Res.* 97 (2018) 501–507, <https://doi.org/10.1177/0022034517750572>.
- [3] L. Winning, F.T. Lundy, B. Blackwood, D.F. McAuley, I. El Karim, Oral health care for the critically ill: a narrative review, *Crit. Care* 25 (2021) 353, <https://doi.org/10.1186/s13054-021-03765-5>.
- [4] M.A. Nazir, Prevalence of periodontal disease, its association with systemic diseases and prevention, *Int. J. Health Sci. (Qassim)* 11 (2017) 72–80.
- [5] F.S. Ludovichetti, A.G. Signoriello, E.A. Gobbato, A. Artuso, E. Stellini, S. Mazzoleni, Can periodontal disease affect conception? A literature review, *Reprod. Fertil.* 2 (2021) R27–R34, <https://doi.org/10.1530/RAF-20-0043>.
- [6] C. Qin, S. Zhang, Y. Zhao, X. Ding, F. Yang, Y. Zhao, Diagnostic value of metagenomic next-generation sequencing in sepsis and bloodstream infection, *Front. Cell. Infect. Microbiol.* 13 (2023) 1117987, <https://doi.org/10.3389/fcimb.2023.1117987>.
- [7] W. Gu, S. Miller, C.Y. Chiu, Clinical metagenomic next-generation sequencing for pathogen detection, *Annu. Rev. Pathol.* 14 (2019) 319–338, <https://doi.org/10.1146/annurev-pathmechdis-012418-012751>.
- [8] M.R. Wilson, S.N. Naccache, E. Samayoa, M. Biagtan, H. Bashir, G. Yu, et al., Actionable diagnosis of neuroleptospirosis by next-generation sequencing, *N. Engl. J. Med.* 370 (2014) 2408–2417, <https://doi.org/10.1056/NEJMoa1401268>.
- [9] B. Jia, A.R. Raphenya, B. Alcock, N. Wagelchner, P. Guo, K.K. Tsang, et al., CARD 2017: expansion and model-centric curation of the comprehensive antibiotic resistance database, *Nucleic Acids Res.* 45 (2017) D566–d73, <https://doi.org/10.1093/nar/gkw1004>.
- [10] A. Tanner, M.F. Maiden, K. Lee, L.B. Shulman, H.P. Weber, Dental implant infections, *Clin. Infect. Dis.* 25 (Suppl. 2) (1997) S213–S217, <https://doi.org/10.1086/516243>.
- [11] J.F. Morris, D.L. Sewell, Necrotizing pneumonia caused by mixed infection with *Actinobacillus actinomycetemcomitans* and *Actinomyces israelii*: case report and review, *Clin. Infect. Dis.* 18 (1994) 450–452, <https://doi.org/10.1093/clinids/18.3.450>.
- [12] L. Forner, T. Larsen, M. Kilian, P. Holmstrup, Incidence of bacteremia after chewing, tooth brushing and scaling in individuals with periodontal inflammation, *J. Clin. Periodontol.* 33 (2006) 401–407, <https://doi.org/10.1111/j.1600-051X.2006.00924.x>.
- [13] A.W. Aruni, F. Roy, H.M. Fletcher, *Filifactor alocis* has virulence attributes that can enhance its persistence under oxidative stress conditions and mediate invasion of epithelial cells by *Porphyromonas gingivalis*, *Infect. Immun.* 79 (2011) 3872–3886, <https://doi.org/10.1128/IAI.05631-11>.