

12-1-2023

Parapapillary β BM and γ zones played different roles in axial elongation among young adolescents using optical coherence tomography

Yin Guo

Jiayan Li

Feifei Tian

Rui Hou

Lijuan Liu

See next page for additional authors

Follow this and additional works at: <https://ro.ecu.edu.au/ecuworks2022-2026>



Part of the [Medicine and Health Sciences Commons](#)

[10.1167/iovs.64.15.34](https://doi.org/10.1167/iovs.64.15.34)

Guo, Y., Li, J., Tian, F., Hou, R., Liu, L., Duan, J., . . . Wu, L. (2023). Parapapillary β BM and γ zones played different roles in axial elongation among young adolescents using optical coherence tomography. *Investigative Ophthalmology & Visual Science*, 64(15), article 34. <https://doi.org/10.1167/iovs.64.15.34>

This Journal Article is posted at Research Online.
<https://ro.ecu.edu.au/ecuworks2022-2026/3544>

Authors

Yin Guo, Jiayan Li, Feifei Tian, Rui Hou, Lijuan Liu, Jiali Duan, Ang Ji, Youxin Wang, Xiuhua Guo, Deqiang Zheng, Wei Wang, and Lijuan Wu

Parapapillary β_{BM} and γ Zones Played Different Roles in Axial Elongation Among Young Adolescents Using Optical Coherence Tomography

Yin Guo,¹ Jiayan Li,² Feifei Tian,³ Rui Hou,² Lijuan Liu,⁴ Jiali Duan,⁵ Ang Ji,¹ Youxin Wang,² Xiuhua Guo,² Deqiang Zheng,² Wei Wang,^{6,7} and Lijuan Wu²

¹Department of Ophthalmology, Beijing Haidian Hospital, Haidian Section of Peking University Third Hospital, Beijing, China

²Department of Epidemiology and Health Statistics, School of Public Health, Capital Medical University, Beijing, China

³Daxing District Center for Disease Control and Prevention, Beijing, China

⁴Beijing Institute of Ophthalmology, Beijing Tongren Hospital, Capital Medical University, Beijing, China

⁵Beijing Center for Disease Prevention and Control, Beijing, China

⁶Centre for Precision Health, Edith Cowan University, Perth, WA, Australia

⁷School of Medical and Health Sciences, Edith Cowan University, Perth, WA, Australia

Correspondence: Lijuan Wu, Capital Medical University, No. 10 Xitoutiao, Youanmen Wai Street, Fengtai District, Beijing, China; xiaowu@ccmu.edu.cn.

Wei Wang, School of Medical and Health Sciences, Edith Cowan University, Perth 6027, Australia; wei.wang@ecu.edu.au.

YG and JL contributed equally as co-first authors.

Received: July 15, 2023

Accepted: November 17, 2023

Published: December 22, 2023

Citation: Guo Y, Li J, Tian F, et al. Parapapillary β_{BM} and γ zones played different roles in axial elongation among young adolescents using optical coherence tomography. *Invest Ophthalmol Vis Sci*. 2023;64(15):34. <https://doi.org/10.1167/iovs.64.15.34>

PURPOSE. To evaluate the influencing factors of parapapillary β_{BM} and γ zones incidence in young adolescents and to explore their associations with axial length progression.

METHODS. In this prospective cohort study, 976 seventh-grade students from nine secondary schools in Beijing, China, were enrolled and followed up 1 year later. Parapapillary β_{BM} zone was defined as retinal pigment epithelium loss while Bruch's membrane was present. Parapapillary γ zone was defined as the absence of retinal pigment epithelium and Bruch's membrane. Logistic regression model was used to analyze the influencing factors of β_{BM} and γ zone incidence. A linear mixed model was used to analyze the associations between parapapillary zones and axial elongation.

RESULTS. Of the 976 participants, 139 (14.2%) had only β_{BM} zone, 398 (40.8%) had only γ zone, and 171 (17.5%) had both. At follow-up, the incidence of β_{BM} zone was 11.5% (76/659), and the incidence of γ zone was 9.7% (39/404). Optic disc tilt, thinner subfoveal choroid, and longer axial length at baseline showed a higher risk of γ zone incidence. The absence of γ zone at baseline showed a faster axial length progression. When the baseline axial length was 25 mm or longer, the β_{BM} zone was also related to the axial elongation.

CONCLUSIONS. The γ zone was associated with axial length progression, and the β_{BM} zone was also associated with the axial length progression when the axial length exceeded 25 mm, which was consistent with the notion that excessive axial length growth not only is the extension of the eyeball but also has its own pathologic changes.

Keywords: axial length, parapapillary zones, optical coherence tomography, adolescent

Myopia has become a major growing public health problem.¹ The World Health Organization estimated that half of the world's population could have myopia and 9.8% will have high myopia by 2050.² Myopia demonstrates various fundus features, such as peripapillary atrophy, optic disc tilt and torsion, and fundus tessellation.³⁻⁵ In addition, myopia is associated with a variety of eye disorders, and the risk increases with the degree of myopia. For each additional 1-diopter increase of myopia, the risk of myopic maculopathy, open-angle glaucoma, posterior subcapsular cataract, and retinal detachment increased by 58%, 20%, 21%, and 30%, respectively.⁶

Parapapillary zones are common in myopia. In studies based on fundus images, Kim et al.⁷ reported that the axial length elongation and refractive changes were faster when there was no parapapillary β zone at baseline within optic

disc changes; Moon and Lim³ also showed that a smaller parapapillary β zone at baseline showed a faster myopia progression. In addition, it is reported that parapapillary zones had a significant association with myopic maculopathy progression.⁸⁻¹⁰

With the application of optical coherence tomography, the parapapillary β zone was further divided into the β_{BM} zone and γ zone. The parapapillary β_{BM} zone is characterized by the presence of Bruch's membrane (BM) and the absence of retinal pigment epithelium (RPE), and the γ zone is defined by the absence of the BM and RPE.¹¹ It is reported that the β_{BM} and γ zone may have different etiologies, which emphasizes the clinical importance of distinguishing the β_{BM} and γ zones.¹²⁻¹⁴ Some studies have suggested that the β_{BM} zone is associated mostly with glaucoma, while the γ zone is dependent mostly on axial length.¹⁵⁻¹⁸ A cross-sectional

study showed that a longer width of the parapapillary γ zone was associated with longer axial length.¹⁹ A study conducted in 46 eyes showed that the axial length of eyes with the parapapillary γ zone was longer than that of eyes without parapapillary zones at final visit.¹¹ However, most of these studies were cross-sectional, and only a few studies have explored the relationship based on population with parapapillary zones classified into the β_{BM} zone and γ zone.

The effect of the parapapillary β_{BM} zone and γ zone on axial length progression may be inconsistent. Therefore, we conducted the present study to assess the influencing factors of parapapillary β_{BM} zone and γ zone incidence among young adolescents and explore the relationships between parapapillary zones and axial length progression.

METHODS

Study Population

The school-based longitudinal study was conducted in Beijing, China, using multistage random cluster sampling. In 2017, six districts (Changping District, Daxing District, Fengtai District, Huairou District, Shijingshan District, and Tongzhou District) were randomly selected from 16 districts in Beijing, and nine schools were selected randomly from the six districts. Grade 7 students in these nine schools who underwent a spectral-domain optical coherence tomography (SD-OCT) scan were included, and those who had glaucoma, eye trauma, or other eye diseases; had a history of ocular surgery; wore an orthokeratology lens; and did not sign informed consent from their parents were excluded. Follow-up was performed 1 year later. We also excluded participants with missing axial length data at any one visit. All parents of participants signed written informed consent. The study was approved by the Ethics Committee of Beijing Tongren Hospital, Capital Medical University (TRECKY2019-136).

Examinations

The participants underwent axial length examination, fundus photography, and a SD-OCT scan at baseline and follow-up visits. Axial length of only the right eye was measured by optical low-coherence reflectometry (Lenstar 900 Optical Biometer; Haag-Streit, Koeniz, Switzerland) in a semidark room.

Nonmydriatic digital fundus photography (45°; CR-2; Canon, Inc., Tokyo, Japan) was performed for optic disc evaluation. The fundus images were measured using ImageJ software (National Institutes of Health, Bethesda, MD, USA). The method of Littmann and axial length measurements were used to correct the magnification caused by the optic media.^{20,21} We applied the formula of (axial length [mm] - 1.82) / 21.92 to calculate Littmann's magnification factor. The optic disc and parapapillary β zone were identified and delineated to obtain the area. Fundus photographs could not clearly distinguish between the β_{BM} zone and the γ zone. The parapapillary β zone with clearly visible large choroidal vessels and sclera was identified. The horizontal diameter, vertical diameter, smallest diameter, and largest diameter of the optic disc were also measured. Optic disc tilt was defined as the optic disc largest diameter/smallest diameter >1.3, and optic disc torsion was defined as the angle between the longest diameter and vertical diameter of the optic disc >15 degrees.

SD-OCT was performed to obtain OCT images of the macula and optic disc (Spectralis; Heidelberg Engineering,

Heidelberg, Germany). The measurement was described in detail by Tian et al.²² As parapapillary zones mostly located in the temporal margin,⁹ we obtained only one horizontal section image through the center of the optic disc in each eye. The parapapillary β_{BM} zone was defined as RPE loss while BM was present. The parapapillary γ zone was defined as the absence of RPE and BM. The status of the participants was classified into (1) eyes without the parapapillary β_{BM} zone and γ zone, (2) eyes with only the parapapillary β_{BM} zone, (3) eyes with only the parapapillary γ zone, and (4) eyes with the parapapillary β_{BM} zone and γ zone (Fig.). In eyes with only the parapapillary β_{BM} zone in OCT images, the area of the parapapillary β zone obtained in fundus images was considered the parapapillary β_{BM} zone area. Consistently, in eyes with only the parapapillary γ zone in OCT images, the area of the parapapillary β zone obtained in fundus images was considered the parapapillary γ zone area. Fundus photographs could not clearly distinguish between the β_{BM} zone and the γ zone, and eyes with the parapapillary β_{BM} zone and γ zone in OCT images could not obtain the area of the β_{BM} zone and γ zone, respectively. Retinal thickness was defined as the distance from the internal limiting membrane to the interface between photoreceptor outer segments and the RPE. Choroidal thickness was measured as the distance from the RPE to the choroidoscleral interface. Measurements were made using Eye Explorer 5.3.3.0 (Heidelberg Engineering). If automatic layer segmentation error occurred, a trained ophthalmologist (YG) performed manual segmentation. To determine intrameasurement variability, one ophthalmologist (YG) randomly selected 100 OCT images and measured again 2 weeks later. For choroidal and retinal thickness measurements, intrameasurement variability due to variation in this measurer was greater than 0.93 (intragroup correlation coefficient [ICC]).²² For parapapillary β_{BM} zone and γ zone measurements, we used κ analyses and confirmed stable repeatability. A total of 100 OCT images were randomly selected by two experienced ophthalmologists (YG and LJJ), respectively, to determine whether the parapapillary β_{BM} zone and γ zone were present or not. The κ coefficient of the two measurements was above 0.80, indicating a good reproducibility.

The questionnaire included demographic information (such as age, sex) and parental information (such as parental myopia and level of education). The questionnaire also included information regarding outdoor activities and near-work activities (such as screen time excluding TV and reading and writing time). Total time spent on weekdays and weekends was summed and divided by 7 to get the average time per day (hours per day). Time spent playing outdoors was obtained using questions such as "How much time does your child spend outdoors? (such as time to run, play, walk, play football, and play basketball outside)." Children were also asked how much time they spent on playing smartphones, tablets, or computers. Watching television was classified as a midrange activity and not included as near work.²³ Children were also asked about the time for doing homework, reading extracurricular books, drawing or practicing calligraphy, and so forth on the way to school, during lunch breaks, and after school. The questionnaire was completed by students and their parents. Height and weight were measured by an ultrasonic height/weight survey meter (NHN-318; Omron, Kyoto, Japan). Body mass index (BMI) was calculated as the ratio of weight (expressed in kilograms) divided by height (expressed in meters) squared.

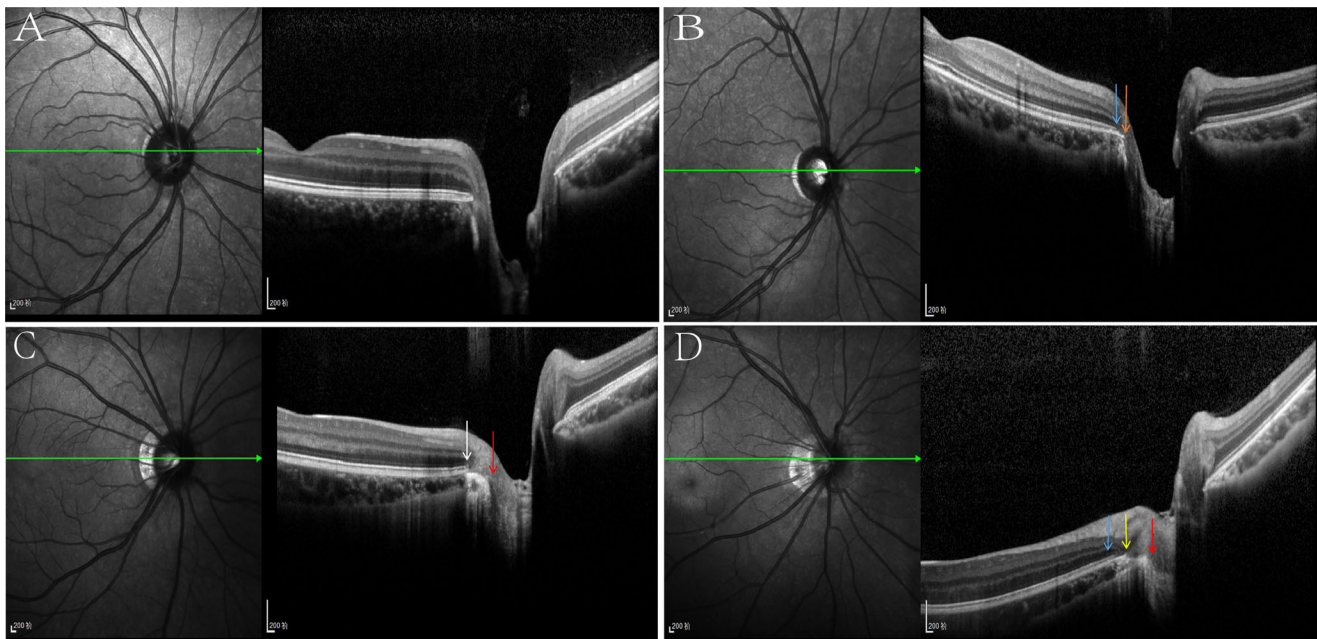


FIGURE. Optical coherence tomogram of the optic nerve head. (A) Eyes without the parapapillary β_{BM} zone and γ zone. (B) Eyes with only the parapapillary β_{BM} zone. *Blue arrow:* beginning of the RPE; *orange arrow:* temporal Bruch's membrane opening and optic disc border. (C) Eyes with only the parapapillary γ zone. *White arrow:* beginning of the RPE and BM opening; *red arrow:* optic disc border. (D) Eyes with the parapapillary β_{BM} zone and γ zone. *Blue arrow:* beginning of the RPE; *yellow arrow:* Bruch's membrane opening; *red arrow:* optic disc border.

Statistical Analysis

For variables with missing values, multiple imputations with chained equations were used to assign missing covariates to avoid the bias caused by missing values. Subfoveal choroid thickness (19.4%) had the highest rate of missing values. Other covariates had less than 1% missing values. Comparisons of variables before and after multiple imputations are shown in Supplemental Material (see Supplementary Table S1). The Shapiro–Wilk test was used to verify the normal distribution of continuous variables. The continuous variable of normal distribution was represented as mean \pm SD and the nonnormal distribution as the median (interquartile range [IQR]). The categorical variable was expressed as number (percentage). Kruskal–Wallis tests were used to compare continuous variables nonnormally distributed between multiple groups, and the χ^2 test was used to compare categorical variables.

We used a logistic regression model to analyze the relationship between demographic information (sex, BMI, parental higher education, parental myopia), behavioral factors (screen time excluding TV, reading and writing time, outdoor activity), and ocular parameters (area of optic disc, optic disc tilt, optic disc torsion, subfoveal retina thickness, subfoveal choroid thickness, axial length at baseline), and parapapillary β_{BM} and γ zones incidence. Considering the possible collinearity, the horizontal diameter, vertical diameter, smallest diameter, and largest diameter of the optic disc were not included as independent variables. The incidence of the parapapillary β_{BM} zone was calculated as the proportion of participants who developed a parapapillary β_{BM} zone at follow-up to those who did not have the β_{BM} zone at baseline. Similarly, the incidence of the parapapillary γ zone was calculated as the proportion of participants who developed a parapapillary γ zone at follow-up to those who did not have a γ zone at baseline. Odds ratios (ORs) and their 95% confidence intervals (CIs) are presented. In addition, we used a linear mixed model to assess the relationship

between parapapillary zones and axial elongation, with a random intercept for class. To evaluate the effect of the parapapillary β_{BM} zone and γ zone on myopia progression at different axial lengths at baseline, we divided axial length into <23 mm, 23 to <24 mm, 24 to <25 mm, and ≥ 25 mm, and a linear mixed model was performed on four subgroups, respectively.

For the changes in parapapillary β_{BM} zone area, we included eyes that had only the β_{BM} zone in OCT images at baseline and follow-up for restricted cubic splines visualization. Eyes with only the γ zone in OCT images at baseline and follow-up were used for visualization of changes in the parapapillary γ zone area. We also plotted restricted cubic splines of axial length annual growth with the baseline parapapillary area using data from participants with only the β_{BM} or γ zone at baseline. All P values were 2-sided and were considered statistically significant when the values were <0.05 . All P values were two-sided <0.05 was considered statistically significant with two-sided. Statistical analysis was performed using SAS 9.4 (SAS Institute, Cary, NC, USA) and R 4.2.3 (R Foundation for Statistical Computing, Vienna, Austria).

RESULTS

Of 1443 students, 186 were excluded due to eye disease and orthokeratology wear, 243 were excluded due to missing baseline or follow-up axial length, and 38 were excluded due to undetected or poor-quality OCT images. In total, 976 students were eventually included in the analysis. The median follow-up was 365 days (IQR, 353–366). We compared the baseline characteristics of the included and excluded participants, and there were no significant differences in sex, BMI, and parental myopia (Supplementary Table S2). Of the 976 participants, 542 (55.5%) were boys and 434 (44.5%) were girls, with a median age of 12.82 years (IQR, 12.54–13.08) (Table 1). The median axial length was

TABLE 1. Demographic Characteristics of Participants According to Axial Length at Baseline

Parameter	Overall	<23 mm	23 to <24 mm	24 to <25 mm	≥25 mm	P
N	976	98	281	299	298	
Sex						
Male	542 (55.5)	28 (28.6)	141 (50.2)	173 (57.9)	200 (67.1)	<0.001
Female	434 (44.5)	70 (71.4)	140 (49.8)	126 (42.1)	98 (32.9)	
Age, median [IQR], y	12.82 [12.54, 13.08]	12.78 [12.54, 12.99]	12.79 [12.54, 13.05]	12.85 [12.54, 13.13]	12.83 [12.55, 13.12]	0.340
BMI, median [IQR], kg/m ²	20.45 [17.89, 24.17]	20.73 [17.50, 24.22]	20.08 [17.91, 22.96]	20.37 [17.85, 23.65]	21.20 [18.00, 25.20]	0.089
Area of optic disc, median [IQR], mm ²	3.23 [2.79, 3.69]	2.83 [2.49, 3.33]	3.20 [2.77, 3.63]	3.23 [2.85, 3.75]	3.38 [2.92, 3.86]	<0.001
Optic disc horizontal diameter, median [IQR], mm	1.86 [1.71, 2.03]	1.79 [1.63, 1.92]	1.89 [1.74, 2.04]	1.87 [1.69, 2.05]	1.86 [1.70, 2.04]	0.001
Optic disc vertical diameter, median [IQR], mm	2.28 [2.12, 2.44]	2.11 [1.98, 2.27]	2.23 [2.09, 2.35]	2.30 [2.14, 2.45]	2.37 [2.22, 2.54]	<0.001
Optic disc smallest diameter, median [IQR], mm	1.77 [1.64, 1.94]	1.73 [1.55, 1.83]	1.80 [1.68, 1.96]	1.78 [1.62, 1.96]	1.77 [1.64, 1.94]	0.005
Optic disc largest diameter, median [IQR], mm	2.35 [2.18, 2.52]	2.17 [2.02, 2.34]	2.28 [2.14, 2.42]	2.38 [2.20, 2.55]	2.45 [2.30, 2.61]	<0.001
Optic disc tilt	529 (54.2)	43 (43.9)	105 (37.4)	172 (57.5)	209 (70.1)	<0.001
Optic disc torsion	226 (23.2)	32 (32.7)	69 (24.6)	67 (22.4)	58 (19.5)	0.054
Subfoveal retina thickness, median [IQR], μm	214.00 [203.75, 224.00]	208.34 [201.00, 217.00]	213.00 [203.00, 224.00]	213.00 [203.00, 224.00]	217.50 [206.00, 228.75]	<0.001
Subfoveal choroid thickness, median [IQR], μm	271.86 [231.00, 315.90]	315.90 [286.92, 342.13]	296.00 [258.00, 329.41]	269.00 [234.00, 313.00]	232.00 [199.25, 269.75]	<0.001
Screen time excluding TV, median [IQR], h	0.57 [0.29, 0.93]	0.51 [0.29, 0.86]	0.57 [0.21, 0.93]	0.52 [0.29, 0.92]	0.57 [0.29, 0.93]	0.789
Reading and writing time, median [IQR], h	2.59 [1.94, 3.36]	2.56 [1.91, 3.24]	2.67 [1.86, 3.39]	2.56 [1.93, 3.43]	2.61 [2.00, 3.30]	0.932
Outdoor activity, median [IQR], h	1.05 [0.64, 1.52]	1.06 [0.64, 1.55]	1.12 [0.79, 1.60]	0.98 [0.62, 1.43]	1.02 [0.60, 1.50]	0.025
Parental higher education						
None	385 (39.4)	43 (43.9)	139 (49.5)	113 (37.8)	90 (30.2)	<0.001
One	211 (21.6)	14 (14.3)	59 (21.0)	81 (27.1)	57 (19.1)	
Both	380 (38.9)	41 (41.8)	83 (29.5)	105 (35.1)	151 (50.7)	
Parental myopia						
None	468 (48.0)	54 (55.1)	162 (57.7)	147 (49.2)	105 (35.2)	<0.001
One	359 (36.8)	35 (35.7)	94 (33.5)	112 (37.5)	118 (39.6)	
Both	149 (15.3)	9 (9.2)	25 (8.9)	40 (13.4)	75 (25.2)	
Parapapillary atrophy						
None	268 (27.5)	45 (45.9)	139 (49.5)	64 (21.4)	20 (6.7)	<0.001
Only β _{BM} zone	139 (14.2)	30 (30.6)	38 (13.5)	44 (14.7)	27 (9.1)	
Only γ zone	398 (40.8)	19 (19.4)	74 (26.3)	140 (46.8)	165 (55.4)	
Both	171 (17.5)	4 (4.1)	30 (10.7)	51 (17.1)	86 (28.9)	

Values are presented as number (%) unless otherwise indicated.

TABLE 2. Logistic Regression Analysis of the Incidence of Parapapillary β_{BM} Zone and Parapapillary γ Zone

Variable	Parapapillary β_{BM} Zone			Parapapillary γ Zone		
	OR	95% CI	P	OR	95% CI	P
Sex (reference: male)	1.106	0.653–1.874	0.708	1.816	0.781–4.225	0.166
BMI	0.958	0.902–1.017	0.163	0.947	0.861–1.042	0.263
Area of optic disc	1.288	0.897–1.849	0.170	1.255	0.701–2.248	0.444
Optic disc tilt	1.657	0.961–2.857	0.069	3.712	1.674–8.232	0.001
Optic disc torsion	0.910	0.487–1.700	0.767	0.396	0.138–1.137	0.085
Subfoveal retina thickness	1.000	0.989–1.010	0.937	0.999	0.985–1.014	0.899
Subfoveal choroid thickness	0.996	0.991–1.001	0.106	0.986	0.977–0.994	0.001
Screen time excluding TV	0.809	0.506–1.295	0.377	0.729	0.351–1.515	0.397
Reading and writing time	1.027	0.821–1.285	0.813	0.982	0.686–1.405	0.920
Outdoor activity	0.914	0.621–1.344	0.647	0.682	0.352–1.323	0.258
Parental higher education (reference: none)						
One	1.478	0.762–2.867	0.248	0.546	0.195–1.529	0.250
Both parents	0.971	0.518–1.819	0.926	0.516	0.188–1.42	0.200
Parental myopia (reference: none)						
One	1.496	0.844–2.651	0.167	0.747	0.314–1.782	0.511
Both parents	2.039	0.996–4.177	0.051	0.691	0.185–2.58	0.582
Axial length at baseline	1.145	0.879–1.490	0.316	2.248	1.438–3.514	<0.001

Statistically significant values ($P < 0.05$) are shown in bold.

24.30 mm (IQR, 23.61–25.17) at baseline. Of the 976 participants, 268 (27.5%) had neither a β_{BM} nor a γ -zone, 139 (14.2%) had only a β_{BM} zone, 398 (40.8%) had only a γ -zone, and 171 (17.5%) had both. The median axial length was 24.55 mm (IQR, 23.82–25.44) at follow-up. Of the 659 participants who did not have a parapapillary β_{BM} zone at baseline, 76 developed a β_{BM} zone at follow-up, and of the 404 individuals who did not have a parapapillary γ zone at baseline, 39 developed a γ zone at follow-up (Supplementary Table S3).

There were 13 participants with poor OCT image quality at the follow-up visit, and a total of 963 participants were included in the analysis of influence factors of parapapillary

β_{BM} zone and γ zone incidence. Optic disc tilt (OR, 3.712; 95% CI, 1.674–8.232; $P = 0.001$), thinner subfoveal choroid (OR, 0.986; 95% CI, 0.977–0.994; $P = 0.001$), and longer axial length at baseline (OR, 2.248; 95% CI, 1.438–3.514; $P < 0.001$) showed a higher risk of parapapillary γ zone incidence (Table 2). Influencing factors of parapapillary β_{BM} zone incidence were not identified. There was no significant relationship between axial length at baseline and change of parapapillary zone area in eyes with only the parapapillary γ zone or β_{BM} zone at baseline and follow-up (for eyes with only the parapapillary γ zone at baseline and follow-up: $P = 0.561$, P for nonlinearity = 0.704; for eyes with only the parapapillary β_{BM} zone at baseline and follow-

TABLE 3. Associations of Demographic Information, Behavioral Factors, and Ocular Parameters with 1-Year Axial Elongation

Variables	Multivariate Model 1*			Multivariate Model 2†			Multivariate Model 3‡		
	Estimate	95% CI	P	Estimate	95% CI	P	Estimate	95% CI	P
Sex (reference: male)							−0.004	−0.022 to 0.015	0.708
BMI							−0.003	−0.005 to −0.001	0.008
Area of optic disc				−0.015	−0.027 to −0.002	0.019	−0.014	−0.027 to −0.002	0.023
Optic disc tilt				−0.012	−0.033 to 0.008	0.236	−0.012	−0.032 to 0.009	0.256
Optic disc torsion				0.008	−0.013 to 0.03	0.433	0.010	−0.011 to 0.031	0.348
Subfoveal retina thickness				−0.00023	−0.00057 to 0.00012	0.192	−0.00023	−0.00057 to 0.00011	0.187
Subfoveal choroid thickness				−0.00017	−0.00034 to 0.00001	0.061	−0.00014	−0.00031 to 0.00003	0.113
Screen time excluding TV							−0.008	−0.022 to 0.007	0.295
Reading and writing time							0.007	−0.001 to 0.015	0.080
Outdoor activity							0.004	−0.01 to 0.018	0.542
Parental higher education (reference: none)									
One							0.009	−0.014 to 0.033	0.440
Both parents							−0.015	−0.036 to 0.007	0.174
Parental myopia (reference: none)									
One							0.028	0.008 to 0.047	0.005
Both parents							0.038	0.011 to 0.065	0.006
Parapapillary atrophy (reference: absence)									
Only β_{BM} zone	−0.020	−0.049 to 0.009	0.176	−0.017	−0.046 to 0.013	0.264	−0.016	−0.045 to 0.013	0.287
Only γ zone	−0.032	−0.056 to −0.009	0.007	−0.034	−0.06 to −0.009	0.009	−0.034	−0.059 to −0.008	0.010
Both	−0.037	−0.066 to −0.008	0.013	−0.040	−0.073 to −0.007	0.017	−0.039	−0.072 to −0.007	0.018
Axial length at baseline	0.030	0.022 to 0.039	<0.001	0.031	0.022 to 0.041	<0.001	0.030	0.021 to 0.040	<0.001

* Multivariate model 1: adjusted for axial length at baseline.

† Multivariate model 2: adjusted for optic disc area, optic disc tilt, optic disc torsion, subfoveal retina thickness, subfoveal choroid thickness, and axial length at baseline.

‡ Multivariate model 3: adjusted for sex, BMI, optic disc area, optic disc tilt, optic disc torsion, subfoveal retina thickness, subfoveal choroid thickness, screen time excluding TV, reading and writing time, outdoor activity, parental higher education, parental myopia, and axial length at baseline.

Statistically significant values ($P < 0.05$) are shown in bold.

TABLE 4. Associations of Parapapillary Atrophy With 1-Year Axial Elongation in Subgroups

Axial Length at Baseline (mm)	Parapapillary Atrophy (Reference: Absence)	Axial Length Progression			
		No.	Estimate	95% CI	<i>P</i>
<23	Only β_{BM} zone	30	0.003	-0.055 to 0.061	0.921
	Only γ zone	19	0.029	-0.054 to 0.112	0.487
	Both	4	0.093	-0.054 to 0.240	0.207
23 to <24	Only β_{BM} zone	38	-0.012	-0.068 to 0.045	0.684
	Only γ zone	74	-0.035	-0.086 to 0.017	0.189
	Both	30	-0.045	-0.114 to 0.024	0.205
24 to <25	Only β_{BM} zone	44	-0.002	-0.064 to 0.060	0.950
	Only γ zone	140	-0.031	-0.083 to 0.021	0.244
	Both	51	-0.043	-0.108 to 0.022	0.196
≥ 25	Only β_{BM} zone	27	-0.093	-0.163 to -0.023	0.010
	Only γ zone	165	-0.092	-0.151 to -0.033	0.002
	Both	86	-0.088	-0.155 to -0.022	0.009

Statistically significant values ($P < 0.05$) are shown in bold.

up: $P = 0.355$, P for nonlinearity = 0.753) (Supplementary Fig. S1).

To explore the risks associated with axial elongation, we examined sex, BMI, optic disc area, optic disc tilt, optic disc torsion, subfoveal retina thickness, subfoveal choroid thickness, screen time excluding TV, reading and writing time, outdoor activity, parental higher education, parental myopia, parapapillary zones, and axial length at baseline through a linear mixed model (Table 3). Lower BMI (β , -0.003; 95% CI, -0.005 to -0.001; $P = 0.008$), smaller optic disc area (β , -0.014; 95% CI, -0.027 to -0.002; $P = 0.023$), parental myopia (one myopic parent: β , 0.028; 95% CI, 0.008–0.047; $P = 0.005$; both parents with myopia: β , 0.038; 95% CI, 0.011–0.065; $P = 0.006$), and longer axial length at baseline (β , 0.030; 95% CI, 0.021–0.040; $P < 0.001$) were factors associated with a rapid rate of axial length growth. The absence of the parapapillary γ zone at baseline showed a faster axial length progression (β , -0.034; 95% CI, -0.059 to -0.008; $P = 0.010$). There was no significant relationship between the parapapillary β_{BM} or γ zone area and axial length growth (for eyes with only the parapapillary γ zone: $P = 0.081$, P for nonlinearity = 0.939; for eyes with only the parapapillary β_{BM} zone: $P = 0.498$, P for nonlinearity = 0.911) (Supplementary Fig. S2).

Participants were binned according to axial length at baseline. After adjusting for sex, BMI, optic disc area, optic disc tilt, optic disc torsion, subfoveal retina thickness, subfoveal choroid thickness, screen time excluding TV, reading and writing time, outdoor activity, parental higher education, parental myopia, and axial length at baseline, the parapapillary β_{BM} zone was also related to the progress of axial length when the baseline axial length was 25 mm or longer (β , -0.093; 95% CI, -0.163 to -0.023; $P = 0.010$) (Table 4).

DISCUSSION

In our study, the prevalence of total parapapillary β zone was 72.5% with a median age of 12.82 years, which was similar to the results of previous studies. A school-based study of 294 sixth-grade children in Beijing showed a parapapillary β zone prevalence of 69% in 2016.²⁴ Horizontal parapapillary β zone prevalence was 75.96% (556/732) in children aged 8

to 11 years from six primary schools in Sanhe, Hebei, China, in 2016.²⁵ The prevalence of the parapapillary β zone among students with a spherical equivalent refraction less than 0.5 D in Shanghai University in 2016 was 79.9%.²⁶ In addition, 139 (14.2%) had only the β_{BM} zone, 398 (40.8%) had only the γ zone, and 171 (17.5%) had both in our study. A 2-year follow-up study of children in Korea showed that 31 of 46 eyes (67.39%) had only the γ zone, 11 (23.91%) had both the β_{BM} and the γ zone, and none had only the β_{BM} zone.¹¹ The prevalence in this study was slightly higher than that in our study, possibly because the study population was myopic children with a spherical equivalence refraction ≤ -0.75 D.

We found that optic disc tilt, thinner subfoveal choroid, and longer axial length at baseline showed a higher risk of parapapillary γ zone incidence. However, we found no statistically significant association between the baseline axial length and the incidence of the β_{BM} zone. In a cross-sectional study, Miki et al.²⁷ found that the γ zone significantly correlated with axial length, while the β_{BM} zone did not correlate with axial length in non-highly myopic individuals. In a histomorphometric study of 65 eyes, the β_{BM} zone was associated with glaucoma but not with longer axial length. The γ zone was associated with longer axial length, but it was not significantly associated with glaucomatous optic neuropathy.²⁸

In addition, we found that after adjusting for sex, BMI, optic disc area, optic disc tilt, optic disc torsion, subfoveal retina thickness, subfoveal choroid thickness, screen time excluding TV, reading and writing time, outdoor activity, parental higher education, parental myopia, and axial length at baseline, the presence of the parapapillary γ zone had a slower axial length progression. This indicates that the emergence of the parapapillary γ zone is no longer a stage of rapid progression of axial length. Interestingly, when the axial length was 25 mm or longer, the presence of the β_{BM} zone was also associated with a slower growth of axial length. Similarly, Miki et al.²⁷ found an association between parapapillary γ zone and axial length and no association between β_{BM} zone and axial length in the non-myopic population. However, in a subsequent cross-sectional study, Miki et al.²⁹ reported that the parapapillary β_{BM} zone and γ zone are both related to axial length

in highly myopic participants. The β_{BM} zone was considered as age-related atrophy of RPE in older participants, as well as pathologic axial elongation in young highly myopic participants.

Until now, clinical studies have not been able to determine the effect of the parapapillary β_{BM} zone on axial length progression because they have included primarily cross-sectional investigations or small sample sizes or they did not divide the β_{BM} and γ zones based on OCT. In a retrospective longitudinal observational study, Moon et al.³ showed that the smaller parapapillary β zone based on fundus photography at baseline showed a faster myopia progression in participants with myopia. Our study also found that eyes with the parapapillary β_{BM} zone or γ zone present had a slower axial length growth in participants with a 25-mm or longer axial length. This suggests that the absence of a parapapillary β_{BM} zone or γ zone might be used as a parameter to predict the potential for further axial length progression when axial length is 25 mm or longer.

The mechanism of myopic axial elongation has not been fully uncovered. One of the theories has suggested that BM is the main structure making the axial length longer.¹³ The process of axial elongation occurs by production and enlargement of BM.³⁰ BM opening (BMO) may shift in direction to the macula, leading to an overhanging of BM into the intrapapillary region at the nasal optic disc, the absence of BM at the temporal side, and the presence of the γ zone.³¹ During axial elongation, the stress to the optic disc will be more marked in the temporal region than in the nasal region. The developmental mechanism of the β_{BM} zone may be the following process. Lee et al.¹¹ suggested that with axial elongation, the attachment between the inner structure of the retina and the outer walls is weaker than that between the RPE and BM. If the growth of the outer wall is too large to be compensated by shifting, the RPE may slide. This process may lead to the occurrence of a parapapillary β_{BM} zone. Consequently, a theoretical basis exists to suggest that when the axial length increases to a certain extent, the β_{BM} zone is related to axial length growth. Our results are similar to the hypothesis proposed by Lee et al.¹¹ This supports the notion that excessive axial elongation has its own pathology changes.³²

The incidence of the parapapillary γ zone was associated with thinner subfoveal choroidal thickness. The association between the γ zone and subfoveal choroidal thickness may be due to an association between subfoveal choroidal thickness and axial length.¹⁹ The Beijing Eye Study 2011 showed that subfoveal choroidal thickness decreased with longer axial length.³³ However, there was no significance in the relationship between subfoveal choroid thickness and axial length progression during the follow-up in our study. One possible reason is the short follow-up time. Similarly, a 1-year follow-up study showed an increase in axial length was not significantly related to subfoveal choroidal thickness.³⁴ Other studies with longer follow-up time showed that the subfoveal choroid thickness is associated with increased axial length.^{35,36}

There are some limitations in this study: first, the study period was limited. Therefore, caution should be exercised when considering the long-term effect of parapapillary zones on the growth of axial length. Second, the parapapillary β_{BM} zone and γ zone were evaluated on the basis of subjective measurements, which may have led to certain measurement errors. However, we used κ analyses and confirmed stable repeatability. The κ coefficient of

the two measurements was above 0.80, indicating a good reproducibility. Third, we obtained only a horizontal section image through the center of the optic disc in each eye using optical coherence tomography, which may have led to an underestimation of the parapapillary β_{BM} zone and γ zone prevalence. However, the parapapillary β_{BM} zone and γ zone are mostly located in the temporal margin,⁹ where most of the parapapillary β_{BM} zone and γ zone can be found.

In conclusion, the parapapillary γ zone was associated with axial length progression for young adolescents, and the parapapillary β_{BM} zone was also associated with axial length progression when the axial length exceeded 25 mm, which was consistent with the notion that excessive axial length growth not only is the extension of the eyeball but also has its own pathologic changes.

Acknowledgments

The authors thank the school and the students for their support and participation, as well as ophthalmologists and optometrists for their contribution.

Supported by the National Natural Science Foundation of China (81602909) and the Project from Beijing Municipal Education Commission (11000022T000000479091). The funding organizations had no role in the design or conduct of this research.

Disclosure: **Y. Guo**, None; **J. Li**, None; **F. Tian**, None; **R. Hou**, None; **L. Liu**, None; **J. Duan**, None; **A. Ji**, None; **Y. Wang**, None; **X. Guo**, None; **D. Zheng**, None; **W. Wang**, None; **L. Wu**, None

References

- Burton MJ, Ramke J, Marques AP, et al. The Lancet Global Health Commission on Global Eye Health: vision beyond 2020. *Lancet Glob Health*. 2021;9(4):e489–e551.
- Holden BA, Fricke TR, Wilson DA, et al. Global prevalence of myopia and high myopia and temporal trends from 2000 through 2050. *Ophthalmology*. 2016;123(5):1036–1042.
- Moon Y, Lim HT. Relationship between peripapillary atrophy and myopia progression in the eyes of young school children. *Eye*. 2021;35(2):665–671.
- Samarawickrama C, Mitchell P, Tong L, et al. Myopia-related optic disc and retinal changes in adolescent children from Singapore. *Ophthalmology*. 2011;118(10):2050–2057.
- Sung MSM, Kang YSM, Heo HM, et al. Characteristics of optic disc rotation in myopic eyes. *Ophthalmology*. 2016;123(2):400–407.
- Bullimore MA, Ritchey ER, Shah S, et al. The risks and benefits of myopia control. *Ophthalmology*. 2021;128(11):1561–1579.
- Kim M, Choung H, Lee KM, et al. Longitudinal changes of optic nerve head and peripapillary structure during childhood myopia progression on OCT. *Ophthalmology*. 2018;125(8):1215–1223.
- Yan YN, Wang YX, Yang Y, et al. Ten-year progression of myopic maculopathy: the Beijing Eye Study 2001–2011. *Ophthalmology*. 2018;125(8):1253–1263.
- Fang Y, Yokoi T, Nagaoka N, et al. Progression of myopic maculopathy during 18-year follow-up. *Ophthalmology*. 2018;125(6):863–877.
- Guo Y, Liu L, Tang P, et al. Progression of myopic maculopathy in Chinese children with high myopia: a long-term follow-up study. *Retina*. 2021;41(7):1502–1511.
- Lee KM, Choung H, Kim M, et al. Change of β -zone parapapillary atrophy during axial elongation: boramae

- myopia cohort study report 3. *Invest Ophthalmol Vis Sci*. 2018;59(10):4020–4030.
12. Dai Y, Jonas JB, Huang H, et al. Microstructure of parapapillary atrophy: beta zone and gamma zone. *Invest Ophthalmol Vis Sci*. 2013;54(3):2013–2018.
 13. Wang YX, Panda-Jonas S, Jonas JB. Optic nerve head anatomy in myopia and glaucoma, including parapapillary zones alpha, beta, gamma and delta: histology and clinical features. *Prog Retin Eye Res*. 2021;83:100933.
 14. Vianna JR, Malik R, Danthurebandara VM, et al. Beta and gamma peripapillary atrophy in myopic eyes with and without glaucoma. *Invest Ophthalmol Vis Sci*. 2016;57(7):3103–3111.
 15. Shang K, Hu X, Dai Y. Morphological features of parapapillary beta zone and gamma zone in chronic primary angle-closure glaucoma. *Eye*. 2019;33(9):1378–1386.
 16. Jonas JB, Wang YX, Zhang Q, et al. Macular Bruch's membrane length and axial length. The Beijing Eye Study. *PLoS ONE*. 2015;10(8):e136833.
 17. Kim M, Kim T, Weinreb RN, et al. Differentiation of parapapillary atrophy using spectral-domain optical coherence tomography. *Ophthalmology*. 2013;120(9):1790–1797.
 18. Yoo YJ, Lee EJ, Kim T. Intereye difference in the microstructure of parapapillary atrophy in unilateral primary open-angle glaucoma. *Invest Ophthalmol Vis Sci*. 2016;57(10):4187–4193.
 19. Jonas JB, Wang YX, Zhang Q, et al. Parapapillary gamma zone and axial elongation-associated optic disc rotation: the Beijing Eye Study. *Invest Ophthalmol Vis Sci*. 2016;57(2):396–402.
 20. Bennett AG, Rudnicka AR, Edgar DF. Improvements on Littmann's method of determining the size of retinal features by fundus photography. *Graefes Arch Clin Exp Ophthalmol*. 1994;32(6):361–367.
 21. Littmann H. Zur Bestimmung der wahren Größe eines Objektes auf dem Hintergrund des lebenden Auges. *Klin Monbl Augenheilkd*. 1982;180(4):286–289.
 22. Tian F, Zheng D, Zhang J, et al. Choroidal and retinal thickness and axial eye elongation in Chinese junior students. *Invest Ophthalmol Vis Sci*. 2021;62(9):26.
 23. Ip JM, Saw SM, Rose KA, et al. Role of near work in myopia: findings in a sample of Australian school children. *Invest Ophthalmol Vis Sci*. 2008;49(7):2903–2910.
 24. Guo Y, Liu LJ, Tang P, et al. Parapapillary gamma zone and progression of myopia in school children: the Beijing Children Eye Study. *Invest Ophthalmol Vis Sci*. 2018;59(3):1609–1616.
 25. Zhang JS, Li J, Wang JD, et al. The association of myopia progression with the morphological changes of optic disc and beta-peripapillary atrophy in primary school students. *Graefes Arch Clin Exp Ophthalmol*. 2022;260(2):677–687.
 26. Chen Q, He J, Yin Y, et al. Impact of the morphologic characteristics of optic disc on choroidal thickness in young myopic patients. *Invest Ophthalmol Vis Sci*. 2019;60(8):2958–2967.
 27. Miki A, Ikuno Y, Weinreb RN, et al. Measurements of the parapapillary atrophy zones in en face optical coherence tomography images. *PLoS One*. 2017;12(4):e175347.
 28. Jonas JB, Jonas SB, Jonas RA, et al. Parapapillary atrophy: histological gamma zone and delta zone. *PLoS One*. 2012;7(10):e47237.
 29. Miki A, Ikuno Y, Weinreb RN, et al. En face optical coherence tomography imaging of beta and gamma parapapillary atrophy in high myopia. *Ophthalmol Glaucoma*. 2019;2(1):55–62.
 30. Jonas JB, Ohno-Matsui K, Jiang WJ, et al. Bruch membrane and the mechanism of myopization: a new theory. *Retina*. 2017;37(8):1428–1440.
 31. Zhang Q, Xu L, Wei WB, et al. Size and shape of Bruch's membrane opening in relationship to axial length, gamma zone, and macular Bruch's membrane defects. *Invest Ophthalmol Vis Sci*. 2019;60(7):2591–2598.
 32. Jonas JB. Optic disk size correlated with refractive error. *Am J Ophthalmol*. 2005;139(2):346–348.
 33. Wei WB, Xu L, Jonas JB, et al. Subfoveal choroidal thickness: the Beijing Eye Study. *Ophthalmology*. 2013;120(1):175–180.
 34. Jin P, Zou H, Xu X, et al. Longitudinal changes in choroidal and retinal thicknesses in children with myopic shift. *Retina*. 2019;39(6):1091–1099.
 35. Hansen MH, Li XQ, Larsen M, et al. Five-year change in choroidal thickness in relation to body development and axial eye elongation: the CCC2000 Eye Study. *Invest Ophthalmol Vis Sci*. 2019;60(12):3930–3936.
 36. Read SA, Alonso-Caneiro D, Vincent SJ, et al. Longitudinal changes in choroidal thickness and eye growth in childhood. *Invest Ophthalmol Vis Sci*. 2015;56(5):3103–3112.