



# Significant association between circumvallate placenta, placental abruption and acute chorioamnionitis in preterm birth: A 23-year retrospective cohort study

D.G. Stuijt<sup>a</sup>, M. Bos<sup>a,b</sup>, P.G.J. Nikkels<sup>c</sup>, R. Wolterbeek<sup>d</sup>, L.E. van der Meeren<sup>a,e,\*</sup>

<sup>a</sup> Department of Pathology, Leiden University Medical Centre, 2333 ZA, Leiden, the Netherlands

<sup>b</sup> Department of Obstetrics and Gynaecology, Leiden University Medical Centre, 2333 ZA, Leiden, the Netherlands

<sup>c</sup> Department of Pathology, University Medical Centre Utrecht, Utrecht, the Netherlands

<sup>d</sup> Department of Biomedical Data Sciences, Leiden University Medical Centre, 2333 ZA, Leiden, the Netherlands

<sup>e</sup> Department of Pathology, Erasmus Medical Centre, Rotterdam, the Netherlands

## ARTICLE INFO

### Keywords:

Placenta  
Placental abruption  
Acute chorioamnionitis  
Circumvallate placenta  
Twin pregnancy

## ABSTRACT

**Aim:** circumvallate placenta, placental abruption and acute chorioamnionitis separately are associated with unfavourable clinical outcomes. We aimed to determine the prevalence and define whether an association exists between the three abnormalities.

**Methods:** 16,042 placenta pathology reports between 1997 and 2020 from a tertiary care centre in the Netherlands were retrospectively analysed. For the statistical analysis, the chi-square test and bootstrapping were used to evaluate an association.

**Results:** In our cohort the prevalence of circumvallate placenta is 2.2 %, placental abruption cases 4.0 % and acute chorioamnionitis 20.6 %. We observed a statistically significant association between all three placental abnormalities: circumvallate placenta, placental abruption and acute chorioamnionitis. In addition, there was also an association between circumvallate placenta and acute chorioamnionitis.

**Conclusion:** Our results show that combined presence of circumvallate placenta, placental abruption and acute chorioamnionitis are associated in preterm birth ( $p = 0.001$ ). A remarkable finding is that the combination of all three abnormalities (circumvallate placenta, placental abruption and acute chorioamnionitis) was not observed in term pregnancies  $>37$  weeks.

## 1. Introduction

Circumvallate placenta, placental abruption and acute chorioamnionitis separately are all associated with unfavourable clinical outcome. Circumvallate placenta has been associated with a higher incidence of vaginal bleeding, placental abruption, and premature rupture of membranes, resulting in preterm delivery [1]. Complications associated with placental abruption include preterm labour and perinatal mortality [2,3]. In infants, the presence of acute chorioamnionitis is associated with early onset sepsis, pneumonia, and meconium aspiration syndrome [4].

Circumvallate placenta is an abnormal insertion of the membranes that do not insert at the margin of the placenta. The chorionic plate is smaller than the basal plate, with a raised edge due to accumulation of fibrin and folding of the membranes (Fig. 2, left) [5–7]. It is a rare

finding and prevalence is estimated around 1–7% [8,9]. It is hypothesised that insufficient implantation and division of the membranes is a predisposing factor of circumvallate placenta. After expansion and growth of the chorion leaves the internal margin and membrane insertion is pushed towards the inner margin [20].

An important differential diagnosis without unfavourable clinical outcome is circummarginate placenta or placenta extrachorialis marginalis/marginata (Fig. 2, right). Circummarginate placenta is an abnormal membrane insertion without a raised edge and folding of the membranes. So far, we did not find literature that reports a recurrence rate of both circumvallate and circummarginate placenta. In addition, we did not find an increased risk of abruption in circummarginate placenta either.

Clinically, placental abruption is the partial or complete detachment of the placenta prior to delivery that correlates with the pathologic

\* Corresponding author. Department of Pathology, Leiden University Medical Centre, 2333 ZA, Leiden, the Netherlands.

E-mail address: [L.van\\_der\\_Meeren@lumc.nl](mailto:L.van_der_Meeren@lumc.nl) (L.E. van der Meeren).

<https://doi.org/10.1016/j.placenta.2023.12.018>

Received 11 May 2023; Received in revised form 28 November 2023; Accepted 14 December 2023

Available online 27 December 2023

0143-4004/© 2023 The Authors. Published by Elsevier Ltd. This is an open access article under the CC BY license (<http://creativecommons.org/licenses/by/4.0/>).

diagnosis of retroplacental hematoma. Its incidence varies depending on the selection of the clinical cohort, ranging between 0.22 % in preterm birth and 39.6 % with a previous placental abruption [2,10,11]. Histologic acute chorioamnionitis is the acute neutrophilic inflammation of the chorion and amnion depends on gestational age and varies between 3.9 % and 20 % in term deliveries [12,13].

The association between circumvallate placenta and a higher incidence of placental abruption is known [1,5] and the association between placental abruption and acute chorioamnionitis has also been described in the literature [14–16]. However, a combined association between all three placental abnormalities: circumvallate placenta, placental abruption and acute chorioamnionitis has not been evaluated yet.

We performed a retrospective evaluation of 16,656 placental pathology reports. The objective of this study was to determine whether there is a correlation between all three abnormalities: circumvallate placenta, placental abruption and acute chorioamnionitis. Secondly, we wanted to investigate if there is an association between circumvallate and acute chorioamnionitis, since there is no previous published data on this presumed association. Additionally, we wanted to determine the prevalence of circumvallate placenta in our cohort.

## 2. Materials and methods

We evaluated a deidentified data set 16,656 placentas that were sent between 1997 and 2020 to the pathology department of the University Medical Centre Utrecht for pathological examination for clinical purposes. Placentas were sent to the pathology department with a wide range of clinical indications such as pre-term birth, fetal growth restriction, pre-eclampsia, pregnancy induced hypertension, gestational diabetes, pre-term premature rupture of membranes, asphyxia of the new born or intra uterine fetal demise (IUFD). The evaluation was consistent with international ethical and professional guidelines (the Declaration of Helsinki and the International Conference on Harmonization Guidelines for Good Clinical Practice). All placentas with ‘circumvallate placenta’, ‘acute chorioamnionitis’ and ‘placental abruption’ with synonym ‘retroplacental hematoma’ in all trimesters between 1997 and December 2020 were identified. The following information was obtained from a deidentified data set: gestational age in weeks; multiple birth as singleton, twins and triplets/quadruplets; macroscopic or histologic presence of circumvallate placenta, macroscopic and/or histological diagnosis of placental abruption and histological diagnosis of acute chorioamnionitis. Circumvallate placenta was macroscopically evaluated by an experienced perinatal pathologist (PN) and diagnosed when an abnormal membrane insertion with a raised fibrin edge with a white discolouration was present. In cases with an uncertain macroscopic diagnosis, additional samples were taken for histologic evaluation. Placental abruption was macroscopically diagnosed when retroplacental or marginal hematoma was present. Microscopically a hematoma, intervillous haemorrhage with subsequent infarct or necrosis of the parenchyma were present. Patterns of ascending intrauterine infection was histologically diagnosed [8]. Low- and high grade acute chorioamnionitis was included. Chronic chorioamnionitis was not evaluated in this analysis. After 2016, the “Amsterdam” criteria consensus statement was used [17]. Placental weight was categorized in 6 groups according to their percentile, as follows: group 1 (weight less than P10); group 2 (P10–P25); group 3 (P25–P50); group 4 (P50–P75); group 5 (P75–P90); group 6 (weight equal or greater than percentile 90). Placentas labelled as “normal” in the databased were categorized as group 4. Placental weight percentiles were based on the values stated from Pinar et al. [18]. All placentas were macroscopically and microscopically evaluated by a specialized perinatal pathologist (PN).

We excluded 614 from the 16,656 cases, according to the following exclusion criteria: duplicated data, fetal material or other tissue than placenta (uterus, uterine tubes, appendix). The data from the remaining 16,042 placentas was used for the analysis.

### 2.1. Statistical analysis

Statistical analysis was performed using IBM SPSS Statistics for Windows, version 24.0. Armonk, NY: IBM Corp., 198 Chicago IL. Data are presented using n/N (%) and *p*-values.

### 2.2. Analysis of separate placental abnormalities

Circumvallate placenta, placental abruption and acute chorioamnionitis were characterized according to gestational age, singleton or twin pregnancy (monochorionic/dichorionic) and placental weight.

Differences in the distribution of clinical variables separately from the pregnancies among the different disease groups, such as pregnancy duration (preterm/term), multiple pregnancies (singleton/twins/triplets or quadruplets), chorionicity of multiple births (monochorial/dichorial) and placental weight, were analysed using chi-square tests.

### 2.3. Association between placental abnormalities

To identify a correlation among circumvallate placenta, placental abruption and acute chorioamnionitis we performed an overall chi-square test for mutual independence (all variables are independent of one another) followed by three chi-square tests each testing joint independence i.e., whether a joint classification (four categories) of two abnormalities is independent of the binary (two categories) classification of the third [19].

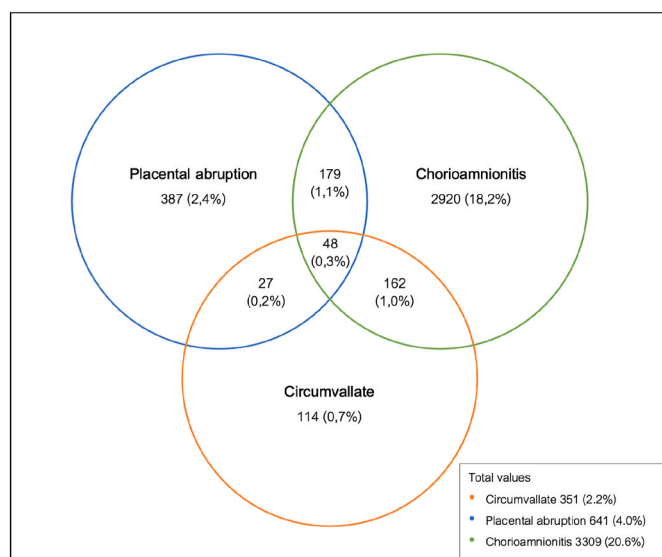
The overall chi-square test (degrees of freedom = 4) rejected the hypothesis of mutual independence for the occurrences of the three placenta abnormalities. From this result we further investigated joint independence of two abnormalities versus the third. Each category of one abnormality was combined with each category of another abnormality resulting in a new variable with four categories. The third variable has two categories to show that each of the three joint categorical systems of two abnormalities shows a higher observed number than expected of the third abnormality when one or both of the joint abnormalities is present.

In addition, we performed a bootstrap analysis to examine the hypothesis whether the population prevalence (*P*) of the simultaneous occurrence of the three abnormalities equals the multiplication of the separate prevalence of the three abnormalities, i.e., whether  $P(\text{Circumvallate} \& \text{Acute chorioamnionitis} \& \text{Abruption}) / (\text{Circumvallate} * P(\text{Acute chorioamnionitis}) * P(\text{Abruption})) = 1$ , in which case there would be independence. This was examined by calculating a 95 % confidence interval for this population ratio based on a 1000 bootstrap samples from which 1000 sample ratios were calculated. A chi-square test was performed in a 4x2-table for each of the three hypotheses regarding joint independence.

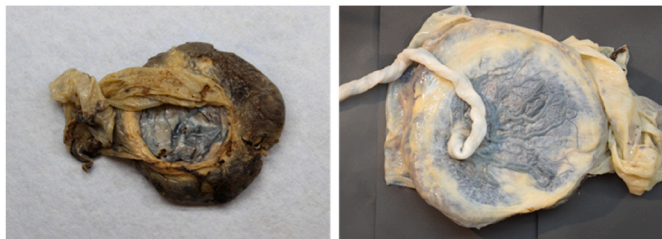## 3. Results

From the 16,042 placentas, there were 351 cases of circumvallate placenta (2.2 %), 641 cases of placental abruption (4.0 %), and 3309 cases of acute chorioamnionitis (20.6 %) as shown in Fig. 1. Placental abruption and circumvallate placenta were present in 27 cases (0.2 %). There was a statistically significant association between preterm birth (before 36 + 6 weeks) and circumvallate placenta and placental abruption as a separate variable ( $p < 0.001$ ), as shown in Table 2. Both placental abruption and acute chorioamnionitis was significantly associated ( $p = 0.001$ ) in preterm birth with presence in 179 (1.1 %) cases (Table 2). Acute chorioamnionitis and circumvallate placenta was present in 162 cases (1.0 %) and was also significant with *p*-value 0.001 (Fig. 1).

The number of placentas with all three abnormalities (circumvallate placenta, placental abruption and acute chorioamnionitis) was 48 cases (0.3 %), as shown in Fig. 1. The bootstrap analysis indicated that the combined presence of circumvallate placenta, placental abruption and



**Fig. 1.** Absolute and relative frequencies of cases of circumvallate placenta, placental abruption and acute chorioamnionitis in the studied population. Venn diagram of the studied population of 16,042 placentas, where the absolute and relative frequencies of the groups from Tables 1 and 2 are depicted. 12,204 placentas were negative to circumvallate placenta, placental abruption or acute chorioamnionitis, which served as the control group for the analyses.



**Fig. 2.** Macroscopy of circumvallate placenta with an abnormal membrane insertion with a raised edge and fibrin (left). Placenta circummarginatum (right) with without a raised edge and folding of the membranes.

acute chorioamnionitis are significantly associated in preterm birth with an estimation that equals 16.59 with 95 % CI between 12.85 and 20.97 for the population ratio. Chi-Square  $p < 0.001$  (Supplementary Table 1). The combination of all three abnormalities (circumvallate placenta, placental abruption and acute chorioamnionitis) was not found in term pregnancies (Table 2). Placentas in our cohort were in general lower in weight (below P50) in all groups (Table 2).

### 3.1. Evaluation of monochorionic and dichorionic placentas

Placental abruption is more frequently found in dichorionic placentas (85,7 %) compared to monochorionic placentas (14,3 %). Acute chorioamnionitis is present in 20,3 % of the monochorionic placentas and 79,7 % of the dichorionic placentas. Circumvallate placenta is also more present in dichorionic placentas (83,3 %) than monochorionic placentas (20,3 %). The combined analysis of the three abnormalities shows a similar pattern, and is more frequently found dichorionic placentas, 87,5 % versus 12,5 % (Table 2).

## 4. Discussion

In this study, we investigated whether there is an association between circumvallate placenta, placental abruption and acute chorioamnionitis. Secondly, we investigated if there is a correlation

between circumvallate placenta and acute chorioamnionitis. Thirdly, we determined the prevalence of the three placental abnormalities in our clinical cohort.

As previously described in the literature, our results confirmed that circumvallate placenta and placental abruption are associated. In addition to this, we observed an association between all three abnormalities: circumvallate placenta, placental abruption and acute chorioamnionitis. Interestingly, we also found an association between circumvallate placenta and acute chorioamnionitis, which was not reported in the literature yet.

We observed the combination of abruption and acute chorioamnionitis in preterm birth, which is in concordance with the current literature [16]. We hypothesize that the inflammation resulting in acute chorioamnionitis is due to the irritation of the friction that is caused by the abnormal insertion of the fibrin-rich edge of the membranes in circumvallate placenta. Especially with a chronic retroplacental or marginal placenta bleeding that may result in deposition of blood and fibrin with siderophages at the margin of the placenta. Unfortunately, it was not possible to evaluate Perl staining for iron deposition in this electronically evaluated cohort. Another hypothesis was suggested by Turowski et al. that insufficient implantation and division of the membranes is a predisposing factor of circumvallate placenta. After expansion and growth of the chorion leaves the internal margin and membrane insertion is pushed towards the inner margin [20]. Regarding the prevalence of the studied placental abnormalities, the percentage of placental abruption (4.0 %) and acute chorioamnionitis (20.6 %) is similar to the prevalence in other studies. In addition, circumvallate placenta is rare and the prevalence is estimated around 1–7% [8,9] depending on the selection of the clinical cohort. In our study with the analysis of over 16,000 placentas over a 23-year period, we observed a percentage of 2.2 %.

### 4.1. Findings in monochorionic and dichorionic placentas

For twins there is a focus on complications specific for twins such as twin-twin transfusion syndrome (TTTS), twin anemia polycythemia sequence (TAPS). This is a first impression to evaluate the prevalence of histologic abnormalities in twin pregnancies.

We observed that placental abruption and acute chorioamnionitis separately is more frequently found in dichorionic placenta compared to monochorionic placenta. Analysis of the combined abnormalities is not significantly different (Table 2), which can be explained by the small sample size of these groups, respectively 4 monochorionic versus 24 dichorionic cases with abruption and 62 monochorionic placentas versus 243 dichorionic placentas with acute chorioamnionitis. In singleton placentas we observed placental abruption and acute chorioamnionitis more frequent in premature deliveries. It is known that monochorionic pregnancies are at increased risk of complications of a shared placenta such as TTTS that result in premature delivery for other reasons than the three abnormalities we described. This might be one of the explanations that circumvallate placenta, placental abruption and acute chorioamnionitis are found more frequently in singleton and dichorionic placentas.

### 4.2. Strengths and limitations

A limitation of this study is that our data is from a retrospective study of 23 years, hence there is missing data. Also, this evaluation based on a hospital population in a university hospital may have led to selection bias of the cases. This may overestimate the prevalence and the percentage may not represent the population-based prevalence. We evaluated a deidentified dataset with limited variables, therefore we did not have access to individual maternal and pregnancy related parameters and were unable to control for potential confounding in the analyses. The most affected category is placental weight, which may explain why this variable doesn't follow a normal distribution in our population. We

**Table 1**

Comparison of pregnancy characteristics of independent variables: circumvallate placenta, placental abruption and acute chorioamnionitis in 16,042 placentas from 1997 to 2020.

	Circumvallate (+)		Abruption (+)		Acute chorioamnionitis (+)		Circumvallate (-) Abruption (-) Acute chorioamnionitis (-)	
	n = 114 (0.7 %) No. (%)	p-value	n = 387 (2.4 %) No. (%)	p-value	n = 2920 (18.2 %) No. (%)	p-value	n = 12,204 (76.1 %) No. (%)	
All preterm cases (<36+6w)	94 (85.5)	< 0.001	310 (82.2)	< 0.001	1577 (56.2)	0.034	6732 (58.4)	
All term cases (>37w)*	16 (14.5)		67 (17.8)		1229 (43.8)		4794 (41.6)	
Missing	4		10		114		678	
Singleton (all GA)	108 (94.7)	0.017	358 (92.5)	<	2606 (89.2)	<	10,420 (85.4)	
Multiples (all GA)*	6 (5.3)		26 (6.7)	0.001	298 (10.2)	0.001	1667 (13.7)	
Chorionicity twin (all GA)* pregnancies	0 (0)		3 (0.8)		16 (0.5)		117 (1.0)	
Monochorionic	1 (16.7)	0.292	4 (14.3)	0.012	62 (20.3)	<	655 (37.5)	
Dichorionic	5 (83.3)		24 (85.7)		243 (79.7)	0.001	1091 (62.5)	
Placental weight								
< 10th	25 (34.7)	0.324	79 (22.5)	<	518 (27.3)	<	3483 (42.4)	
P10–P25	11 (15.3)		42 (12.0)	0.001	184 (9.7)	0.001	956 (11.7)	
P25–P50	1 (1.4)		27 (7.7)		69 (3.6)		194 (2.4)	
P50–P75	26 (36.1)		141 (40.2)		630 (33.2)		2169 (26.4)	
P75–P90	3 (4.2)		19 (5.4)		97 (5.1)		335 (4.1)	
> 90th	6 (8.3)		43 (12.3)		401 (21.1)		1068 (13.0)	
Missing	42		36		1021		3999	

Chi-Square tests were performed to compare the variables (rows) from the studied groups with the control group (rightmost column).

(+) = present; (-) = not present; w = weeks.

\* all term cases (circumvallate placenta and/or acute chorioamnionitis and/or abruption) are singletons. In the group without abnormalities 2 placentas are dichorionic placentas.

**Table 2**

Comparison of pregnancy characteristics of combined groups of circumvallate placenta, abruption and acute chorioamnionitis in 16,042 placentas from 1997 to 2020.

	Circumvallate (+) Abruption (+) Acute chorioamnionitis (-)		Circumvallate (-) Abruption (+) Acute chorioamnionitis (+)		Circumvallate (+) Abruption (-) Acute chorioamnionitis (+)		Circumvallate (+) Abruption (+) Acute chorioamnionitis (+)		Circumvallate (-) Abruption (-) Acute chorioamnionitis (-)	
	n = 27 (0.2 %) No. (%)	p-value	n = 179 (1.1 %) No. (%)	p-value	n = 162 (1.0 %) No. (%)	p-value	n = 48 (0.3 %) No. (%)	p-value	n = 12,204 (76.1 %) No. (%)	
All preterm (<36+6w)	26 (96.3)	< 0.001	162 (91.0)	< 0.001	152 (95.6)	< 0.001	48 (100)	< 0.001	6732 (58.4)	
All term cases (>37w)*	1 (3.7)		16 (9.0)		7 (4.4)		0 (0.0)		4794 (41.6)	
Missing	0		1		3		0		678	
Singleton (all GA)	25 (92.6)	0.550	164 (91.6)	0.063	143 (88.3)	0.207	40 (83.3)	0.711	10,420 (85.4)	
multiples (all GA)*	2 (7.4)		14 (7.8)		16 (9.9)		7 (14.6)		1667 (13.7)	
Chorionicity twin pregnancies	0 (0.0)		1 (0.6)		3 (1.9)		1 (2.1)		117 (1.0)	
Monochorionic	0 (0.0)	0.273	2 (13.3)	0.054	3 (15.8)	0.051	1 (12.5)	0.145	655 (37.5)	
Dichorionic	2 (100)		13 (86.7)		16 (84.2)		7 (87.5)		1091 (62.5)	
Placental weight										
< 10th	4 (18.2)		17 (10.6)		10 (13.2)		4 (11.4)		3483 (42.4)	
P10–P25	0 (0.0)		7 (4.3)		10 (13.2)		3 (8.6)		956 (11.7)	
P25–P50	0 (0.0)		20 (12.4)		1 (1.3)		1 (2.9)		194 (2.4)	
P50–P75	10 (45.5)	0.016	77 (47.8)	< 0.001	33 (43.4)	< 0.001	16 (45.7)	0.001	2169 (26.4)	
P75–P90	2 (9.1)		16 (9.9)		5 (6.6)		1 (2.9)		335 (4.1)	
> 90th	6 (27.3)		24 (14.9)		17 (22.4)		10 (28.6)		1068 (13.0)	
Missing	5		18		86		13		3999	

Chi-Square tests were performed to compare the variables (rows) from the studied groups with the control group (rightmost column).

(+) = present; (-) = not present; w = weeks.

did not have information about subsequent pregnancies to evaluate the recurrence rate of circumvallate placenta and retroplacental haemorrhage in this cohort.

The large sample size of our cohort (n = 16,042) is a strength of the evaluation, which determines more precise and reliable results. As described in the methods section, our studied population are pregnancies with a clinical indication for placental examination. All placentas were macroscopically and microscopically evaluated by one experienced perinatal pathologist (PN) which reduces the interobserver variability, however, this aspect might be viewed as a limitation. Therefore, the information provided in this study can be of clinical relevance for pathologists who receive such cases.

## 5. Conclusion

The prevalence of abnormalities in our cohort of 16,042 placenta was 2.2 % for circumvallate placenta, 4.0 % for placental abruption and 20.6 % for acute chorioamnionitis. Our results show that combined presence of circumvallate placenta, placental abruption and acute chorioamnionitis are statistically significant associated in preterm birth (p = 0.001). In addition, a striking observation is the combination of all three abnormalities (circumvallate placenta, placental abruption and acute chorioamnionitis) was not found in term pregnancies >37 weeks.

## Declaration of competing interest

The authors declare that they have no known competing financial interests or personal relationships that could have appeared to influence the work reported in this article.

## Appendix A. Supplementary data

Supplementary data to this article can be found online at <https://doi.org/10.1016/j.placenta.2023.12.018>.

## References

- [1] S. Suzuki, Clinical significance of pregnancies with circumvallate placenta, *J. Obstet. Gynaecol. Res.* 34 (1) (2008 Feb) 51–54.
- [2] M. Tikkanen, M. Nuutila, V. Hiilesmaa, J. Paavonen, O. Ylikorkala, Clinical presentation and risk factors of placental abruption, *Acta Obstet. Gynecol. Scand.* 85 (6) (2006 Jun) 700–705.
- [3] S. Rasmussen, L.M. Irgens, K. Dalaker, *Acta Obstetrica et Gynecologica Scandinavica* Outcome of pregnancies subsequent to placental abruption: a risk assessment, *C Acta Obstet Gynecol Scand* 79 (2000) 496–501.
- [4] J. Alexander, Chorioamnionitis and the prognosis for term infants, *Obstet. Gynecol.* 94 (2) (1999 Aug) 274–278.
- [5] H. Taniguchi, S. Aoki, K. Sakamaki, K. Kurasawa, M. Okuda, T. Takahashi, et al., Circumvallate placenta: associated clinical manifestations and complications—a retrospective study, *Obstet Gynecol Int* 2014 (2014) 1–5.
- [6] O.Y. Celik, M. Obut, A. Keles, M.G. Calik, G. Dagdeviren, A. Yucel, et al., Outcomes of pregnancies diagnosed with circumvallate placenta, and use of uterine artery pulsatility index and maternal serum alpha-fetoprotein for prediction of adverse outcomes, *Eur. J. Obstet. Gynecol. Reprod. Biol.* 262 (2021 Jul 1) 57–61.
- [7] K. Benirschke, P. Kaufmann, *Pathology of the Human Placenta*. Pathology of the Human Placenta, Springer, New York, 1995. New York, NY.
- [8] [Internet]R.N. Baergen, G.J. Burton, C.G. Kaplan (Eds.), *Benirschke's Pathology of the Human Placenta*, Springer International Publishing, Cham, 2022. Available from: <https://link.springer.com/10.1007/978-3-030-84725-8>.
- [9] H. Fox, C.W. Elston, *Pathology of the placenta* [Internet], *Major Probl. Pathol.* 7 (1978) 1–491. Available from: <http://www.ncbi.nlm.nih.gov/pubmed/207935>.
- [10] C v Ananth, G.S. Berkowitz, D.A. Savitz, R.H. Lapinski, *Placental Abruption and Adverse Perinatal Outcomes* [Internet]. Available from: <https://jamanetwork.com/>.
- [11] L. Ruiter, A.C.J. Ravelli, I.M. de Graaf, B.W.J. Mol, E. Pajkrt, Incidence and recurrence rate of placental abruption: a longitudinal linked national cohort study in The Netherlands Presented as a poster at the 35th annual meeting of the Society for Maternal-Fetal Medicine, San Diego, CA, Feb. 2-7, 2015, in: *American Journal of Obstetrics and Gynecology*, Mosby Inc., 2015, pp. 573.e1–573.e8.
- [12] S.L. Woodd, A. Montoya, M. Barreix, L. Pi, C. Calvert, A.M. Rehman, et al., Incidence of maternal peripartum infection: a systematic review and meta-analysis, *PLoS Med.* vol. 16 (2019). Public Library of Science.
- [13] C.J. Kim, R. Romero, P. Chaemsaitong, N. Chaiyasit, B.H. Yoon, Y.M. Kim, Acute chorioamnionitis and funisitis: definition, pathologic features, and clinical significance, *Am. J. Obstet. Gynecol.* 213 (2015) S29–S52. Mosby Inc.
- [14] S. Suzuki, M. Igarashi, Y. Inde, H. Miyake, Abnormally shaped placentae in twin pregnancy, *Arch. Gynecol. Obstet.* 281 (1) (2010 Jan) 65–69.
- [15] A. Rana, H. Sawhney, S. Gopalan, D. Panigrahi, R. Nijhawan, Abruption placenta and chorioamnionitis - microbiological and histologic correlation, *Acta Obstet. Gynecol. Scand.* 78 (5) (1999 May) 363–366.
- [16] C.A. Nath, C.v. Ananth, J.C. Smulian, S. Shen-Schwarz, L. Kaminsky, Histologic evidence of inflammation and risk of placental abruption, *Am. J. Obstet. Gynecol.* 197 (3) (2007) 319.e1–319.e6.
- [17] T.Y. Khong, E.E. Mooney, I. Ariel, N.C.M. Balmus, T.K. Boyd, M.A. Brundler, et al., Sampling and definitions of placental lesions Amsterdam placental workshop group consensus statement, in: *Archives of Pathology and Laboratory Medicine*, College of American Pathologists, 2016, pp. 698–713.
- [18] H. Pinar, C.J. Sung, C.E. Oyer, D.B. Singer, Reference values for singleton and twin placental weights, *Pediatr. Pathol. Lab. Med.* 16 (6) (1996) 901–907.
- [19] A.M. Mood, F.A. Graybill, D.C. Boes, *Introduction to the Theory of Statistics*, third ed., McGraw-Hill, New York, NY, 1974, p. 564.
- [20] M. Vogel, G. Turowski, *Clinical Pathology of the Placenta*, The Gruyter, 2019.