

REVIEW

Cardiac magnetic resonance in advanced heart failure

Francesca Coraducci MD¹  | Giulia De Zan MD² | Damiano Fedele MD^{3,4} |
 Pietro Costantini MD⁵  | Andrea Igoren Guaricci MD, PhD⁶ | Anna Giulia Pavon MD⁷  |
 Arco Teske MD, PhD² | Maarten Jan Cramer MD, PhD² | Lysette Broekhuizen MD, PhD² |
 Dirk Van Osch MD, PhD² | Ibrahim Danad MD, PhD² | Birgitta Velthuis MD, PhD⁸ |
 Dominika Suchá MD, PhD⁸ | Ivo van der Bilt MD, PhD^{2,9} | Carmine Pizzi MD^{3,4} |
 Antonio Dello Russo MD, PhD¹ | Marish I.F.J. Oerlemans MD, PhD² | Linda W. van
 Laake MD, PhD² | Pim van der Harst MD, PhD² | Marco Guglielmo MD^{2,9} 

¹Marche Polytechnic University, Ancona, Italy

²Division Heart and Lung, Cardiology Department, University Medical Centre Utrecht, Utrecht, The Netherlands

³Cardiology Unit, Cardiac Thoracic and Vascular Department, IRCCS Azienda, Ospedaliero-Universitaria di Bologna, Bologna, Italy

⁴Department of Medical and Surgical Sciences - DIMEC, University of Bologna, Bologna, Italy

⁵Department of Radiology, Ospedale Universitario Maggiore della Carità di Novara, University of Eastern Piedmont, Novara, Italy

⁶Department of Emergency and Organ Transplantation, Institute of Cardiovascular Disease, University Hospital Policlinico of Bari, Bari, Italy

⁷Division of Cardiology, Cardiocentro Ticino Institute Ente Ospedaliero Cantonale, Lugano, Switzerland

⁸Division of Radiology, University Medical Center Utrecht, Utrecht, The Netherlands

⁹Cardiology Department, HAGA Ziekenhuis, Den Haag, The Netherlands

Correspondence

Marco Guglielmo, University Medical Centre Utrecht, Division Heart and Lung, Cardiology Department, Utrecht, The Netherlands.
 Email: M.guglielmo@umcutrecht.nl

Abstract

Heart failure (HF) is a chronic and progressive disease that often progresses to an advanced stage where conventional therapy is insufficient to relieve patients' symptoms. Despite the availability of advanced therapies such as mechanical circulatory support or heart transplantation, the complexity of defining advanced HF, which requires multiple parameters and multimodality assessment, often leads to delays in referral to dedicated specialists with the result of a worsening prognosis. In this review, we aim to explore the role of cardiac magnetic resonance (CMR) in advanced HF by showing how CMR is useful at every step in managing these patients: from diagnosis to prognostic stratification, hemodynamic evaluation, follow-up and advanced therapies such as heart transplantation. The technical challenges of scanning advanced HF patients, which often require troubleshooting of intracardiac devices and dedicated scans, will be also discussed.

KEYWORDS

advanced heart failure, advanced multimodality cardiac imaging, cardiac magnetic resonance

This is an open access article under the terms of the [Creative Commons Attribution](https://creativecommons.org/licenses/by/4.0/) License, which permits use, distribution and reproduction in any medium, provided the original work is properly cited.

© 2024 The Author(s). *Echocardiography* published by Wiley Periodicals LLC.

1 | INTRODUCTION

Heart failure (HF) is a cardiovascular disease with one of the highest burdens on the worldwide population.¹ It is defined by the European Society of Cardiology (ESC), the American Heart Association (AHA), and the American College of Cardiology (ACC) guidelines HF as a clinical syndrome where both signs and symptoms must be present, caused by structural or functional abnormality of the heart leading to impaired ventricular filling or ejection of blood.^{1,2}

The AHA/ACC guidelines also recognize different stages of HF progression: Stage A is defined as “at risk” of HF, stage B is defined as “pre-HF,” stage C as “symptomatic HF,” and stage D as “advanced HF.”²

Up to 10% of the general population with HF progress to stage D.³ In the United States, it is estimated that by 2030, more than 8 million people will be affected by advanced HF.^{4,5}

Scientific societies like ESC, AHA, and ACC agree that the definition of advanced HF relies on the presence of invalidating symptoms and recurrent hospitalizations despite conventional treatments, like guideline-directed medical therapy (GDMT), devices, and surgery, to the point that advanced therapies, such as cardiac transplantation, mechanic circulatory support (MCS), or palliation, are needed. Moreover, there must be evidence of severe functional impairment, that can be assessed by six-minute walking test (6MWT) < 300m, peak VO₂ < 12–14 mL/kg/min or <50% of predicted value, and severe cardiac dysfunction defined by severely reduced ejection fraction (EF) (<30%), presence of high filling left ventricular (LV) pressures at right heart catheterization or echocardiography, or isolated right ventricle (RV) failure. To be noted is that according to those guidelines, a reduced LVEF is common but not mandatory to consider the diagnosis of advanced HF.⁶ The RV also plays a crucial role in the pathophysiology of HF, and therefore, an isolated RV failure could lead to advanced HF diagnosis.

Moreover, in the event of HF with LV dysfunction, a compromised RV can be indicative of a more advanced LV illness and, therefore, a worse prognosis.

Advanced HF is a rapidly evolving subset of HF, and an early referral to dedicated specialists is the key to improving prognosis. At the same time, there is still some complexity in the definition and classification of advanced HF that may lead to a late referral.⁷

In this regard, cardiac imaging plays a key role: it helps recognizing the sliding of HF stage C to stage D, it guides the timing and modality of advanced treatments, and eventually it assesses their efficacy.

In this review, we aim to tackle the role of cardiac magnetic resonance (CMR) in managing advanced HF patients. Specifically, CMR capability in volume and function assessment, pressure and flow measurements, tissue characterization, and the latest advancement to overcome previous limitations to such techniques as its use in implantable devices will be addressed.

2 | VOLUMES AND FUNCTION

Left ventricular ejection fraction (LVEF) is a critical parameter in describing patients with advanced HF since it is used in many risk

scores for advanced HF.⁸ To be noted, not all patients with advanced HF have cardiac dysfunction in terms of a low LVEF.

Indeed, in a retrospective study on a cohort of 936 adult patients from the Rochester Epidemiology Program in Minnesota, among patients with advanced HF there was a similar distribution of patients between heart failure with reduced ejection fraction (HFrEF) (42% of the cohort) and heart failure with preserved ejection fraction (HFpEF) (43%). Moreover, there was no significant difference in survival according to the EF subtype, even though patients with HFpEF had lower cardiovascular mortality than HFrEF patients.⁶

It is widely known that different methods of LVEF and volume assessment have different performances.⁹ LVEF analysis in CMR is based on Simpson's disk summation method (Figure 1). First, a series of short-axis images over multiple phases of the cardiac cycle are acquired to obtain a “cine” image. Once “cine” images are available, left ventricular end-diastolic and end-systolic areas are traced (manually or automatically, depending on each software) and multiplied to the distance among each slice, obtaining the volume of every disk. Therefore, the ventricle volume in both systole and diastole is obtained without using any geometrical assumption that can lead to the wrong estimation of the EF.

A CMR substudy of the CHRISTMAS trial demonstrated in the early 2000 that measurements of LVEF obtained with different techniques are not interchangeable and, therefore, not universal. Bellenger et al. analyzed the LVEF of 52 patients with HF with transthoracic echocardiography (TTE), both Teicholz and Simpson biplane method, CMR and radionuclide ventriculography and found out significant differences in the mean LVEF among the techniques.¹⁰ More recently, a retrospective study by Clark et al. compared LVEF assessment through two-dimensional TTE and CMR in 767 patients. Significant concordance between the two techniques was observed for patients with normal LVEF (TTE assessment confirmed by CMR in 90.6% patients) while their concordance for reduced LVEF patients was reduced to 64.6%.¹¹

On the contrary, recent evidence derived from the United Kingdom (UK) biobank confirmed excellent inter and intraobserver variability for CMR LVEF and volume assessment, although there is evidence that there can be variability between different software systems in LVEF and volumes.^{12,13}

These discrepancies have a relevant clinical impact. Indeed, in 52 patients considered for implantable cardioverter defibrillator (ICD) implantation who underwent both CMR and TTE, with a threshold for ICD indication set at LVEF ≤35%, CMR led to reclassification in 21% of patients in the ICD indication group. It also showed that CMR was more reproducible both in terms of intra and interobserver variability than echocardiography.¹⁴

Regarding ICD implantation for primary prevention, data from the Cardiac Magnetic Resonance for Prophylactic Implantable Cardioverter Defibrillator Therapy in Ischemic Cardiomyopathy (DERIVATE-ICM) registry shows that the measurement of LVEF on CMR may have an additional prognostic advantage over the measurement of LVEF at TTE in predicting major adverse cardiac events

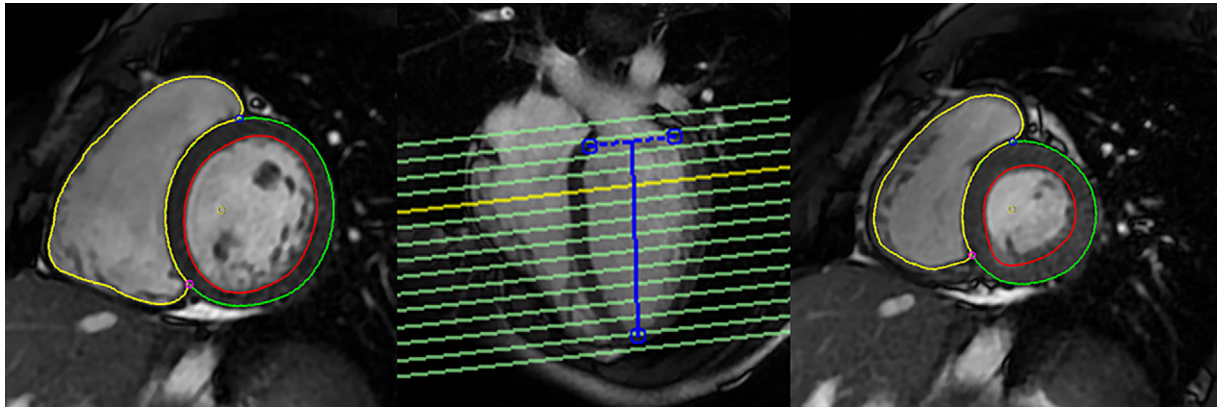


FIGURE 1 CMR short axis stacks of cine images for ejection fraction calculation. Left: diastolic contours (RV: yellow, LV epicardium: green; LV endocardium: red). Middle: all short axis slices. Right: systolic contours. In Simpson's disc summation method, this process is repeated for each slice to obtain the volume. CMR: cardiac magnetic resonance; RV: right ventricle; LV left ventricle.

(MACE), both when used alone and in a combined model with late gadolinium enhancement (LGE).

Moreover, when CMR-derived LVEF is used in a combined score with LGE, it allows the identification of a subset of patients not reaching the criteria for ICD implantation due to TTE-derived LVEF $\geq 35\%$, but who are actually at increased risk of MACE.^{15–17}

In patients with ischemic cardiomyopathy (ICM), CMR LVEF measurement is known to be related to MACE, but also CMR right ventricular ejection fraction (RVEF) has been demonstrated as an independent predictor of adverse events, highlighting the central role of CMR in the measurement of volumes and ejection fraction.¹⁸

In the context of the right ventricle, the assessment of volume and function through 2D echocardiography encounters limitations due to its reliance on measurements derived from the apical 4-chamber view, which offers a restricted perspective of the RV. In contrast, CMR provides a more comprehensive evaluation by measuring right ventricle volumes in the short axis, thereby encompassing the entirety of the RV. To overcome this problem, emerging methodologies like 3D echocardiography analysis exhibit enhanced efficacy relative to traditional 2D approaches, particularly when compared to CMR, for Ejection Fraction (EF) measurements.^{19–21}

The automation of CMR LVEF analysis with deep learning methods is an established tool that showed precision and reproducibility.^{22,23} Also, machine learning analysis is showing promising results, making the CMR even more trustworthy.²⁴

Regarding volume assessment, left atrial volume indexed for body surface area (LAVi) is proven to be an independent predictor of mortality in patients undergoing CMR for all causes,²⁵ and there is evidence that LAVi measured by TTE is prognosis-related in patients with HF.²⁶

3 | FLOWS, 4D FLOW AND HAEMODYNAMIC

The gold standard in evaluating valvular heart disease is echocardiography, that has a better depiction of valvular anatomy and mechanism of dysfunction. Nevertheless, CMR often plays a pivotal role in this

field. Through phase contrast (PC) sequences it can provide accurate data about flow estimation, such as direction and velocity and regurgitant volume can be assessed with both direct and indirect methods allowing also the detection of indirect signs of severity like chamber remodeling or reduction in ejection fraction.^{27–30}

Uretsky et al compared the American Society of Echocardiography (ASE) algorithm for the quantification of primary degenerative mitral regurgitation (MR) with CMR and reverse remodeling after mitral repair surgery, they found out that the ASE algorithm and CMR values were often discordant and that only CMR-assessed severe MR was an independent predictor for reverse remodeling after surgery, meaning that, even though echocardiography is the gold standard in choosing the timing of surgical intervention in mitral valve regurgitation, CMR can be important in the decision-making process.³¹ Further studies are needed to better characterize this conflicting data and introduce CMR into the daily clinical practice of managing valvular heart disease patients and selecting surgical timing.

Secondary mitral regurgitation (MR) has a high prevalence among patients with advanced HF: latest research on percutaneous treatment of secondary MR led to some conflicting evidence, turning the spotlight on the dysfunctional ventricle rather than the valve pathology “per se” giving birth to the concept of “proportionate” or “disproportionate” mitral regurgitation. Regarding that, Cavalcante et al.³² studied the association between the severity of secondary MR in patients with ischemic heart disease and the myocardial infarct size measured as the percentage of the whole LV mass interested by LGE. They found that the estimated hazard ratio for ischemic MR was higher for larger myocardial infarct size, suggesting that MR assessment should be performed from a wider point of view including scar size.

In the diagnostic algorithm of HF, hemodynamic impairment evaluation is also crucial. Pulmonary transit time (PTT) corresponds to the time for a contrast bolus to pass from the right- to the left-sided circulation. Theoretically, this measurement can give information about the functional status of both ventricles and lung congestion. PTT can be measured by either noninvasive imaging, such as contrast-enhanced echocardiography, radionuclide imaging, cardiac computer

tomography, and CMR, or by direct heart catheterization. Recently, a study published by Houard³³ et al. evaluated the performance of PTT by first-pass perfusion CMR in patients with HFrEF and compared its ability to predict mortality and HF hospitalization against other well-known prognostic indicators in HF. PTT by CMR was significantly longer in HFrEF and showed high correlation with New York Heart Association (NYHA) class, LV and RV volumes and EF, and with global longitudinal strain (GLS). PTT was also an independent predictor of long-term mortality and HF hospitalization. Its prognostic value was more pronounced in comparison to RV and LV strain and EF on CMR. As a result, PPT might serve as a useful parameter to stratify prognosis in HF patients, with the advantage of being simple and quick to obtain from any CMR routine exam with first-pass perfusion scans.³³

Since pulmonary hypertension (PH) can be associated with HF and usually leads to pulmonary artery (PA) dilatation, the ratio between PA and aorta (PA:Ao ratio) diameter has proven, when higher than 0.83, to correlate to a worse prognosis in patients with HFpEF, representing an easily CMR-derived parameter to assess the presence of PH.³⁴

An emerging technology is the analysis of 4D flow by CMR. The main novelty of 4D flow is the ability to encode velocity in three directions and over time,^{35,36} through a 3D phase contrast sequence, allowing the measurement of flow at any chosen point of a 3D volume and at any chosen time. This interesting technique leads to the possibility of studying wall shear stress, flow, and vortex and has potential applications in the evaluation of diastolic dysfunction³⁷ and valvular heart diseases.³⁸

4D flow is particularly useful in solving some of the problems encountered with the 2D measurement of flow through atrioventricular (AV) valves. Indeed, the latter has shown to be less precise compared to indirect evaluation based on volumes of the ventricle and flow measurement across the pulmonary or aortic valve, mostly because the complex dynamics of the annulus through the cardiac cycle makes it difficult to choose the right plane for the analysis of 2D flow.³⁸ Nevertheless, indirect quantification can also be of limited precision, especially when dealing with multivalvular disease. 4D flow has shown to be reliable and reproducible when compared to echocardiography in the assessment of tricuspid regurgitation (TR) in healthy subjects and patients with congenital heart disease and in evaluating aortic regurgitation.^{39–41} This reliability in grading the severity of valvular regurgitation, together with the accuracy of CMR in measuring left ventricular volumes, could be extremely useful in choosing the right timing of surgery, but further studies correlating surgical timing with CMR 4D flow parameters are needed.

Moreover, different studies confirmed how 4D flow CMR is useful for estimating right catheterization (RHC) derived parameters such as mean pulmonary arterial pressure (mPAP) or pulmonary artery wedge pressure (PAWP). In patients with various type of pulmonary hypertension, RHC-measured mPAP has shown better correlation with the persistency of 4D flow-derived vortices in the pulmonary artery across the cardiac cycle rather than echocardiography-derived mPAP.^{42,43} PAWP was proven to be correlated with left atrial peak inflow acceleration.⁴⁴

Despite the potential usefulness of these techniques further studies are needed in the specific context of advanced HF.

4 | TISSUE TRACKING

Measurement of myocardial deformation analysis by CMR is evolving in recent years. At first, the myocardial tagging technique used to be performed: a single breath-hold ECG-gated spoiled gradient echo (GRE) sequences “saturates” (nulls) the myocardium in a “grid” pattern allowing the observer to follow the “saturation/desaturation” bands through the cardiac cycle and visualize how the myocardium deforms through systole and diastole. However, this technique is very time-consuming, difficult to standardize, and needs dedicated sequences in a CMR exam. Therefore, myocardial tagging lost its attractiveness as the newer technology of feature tracking (FT) spread (Figure 2).⁴⁵

Differently from the speckle tracking (STE) technique on TTE, FT CMR does not rely on intramyocardial features but tracks the border between blood and endocardium,⁴⁶ thus it can be applied to standard “cine” sequences during postprocessing.

In an interesting study by Lange, Shuster et al.,⁴⁷ LV-GLS and left atrium strain by FT CMR were found to correlate with MACE, with the latest being an independent predictor of mortality in ischemic cardiomyopathy.

Interesting evidence is emerging from the analysis of RV strain via FT CMR, as it showed promising results in predicting the risk of MACE in patients with nonischemic dilated cardiomyopathy (NICM) and in a subset of patients with NICM and HF stage C or D.^{48,49}

Regarding the right ventricle important data is available for early detection of cardiomyopathies⁵⁰ such as phospholamban (PLN) cardiomyopathy and arrhythmogenic right ventricular cardiomyopathy.⁵¹ These studies suggest the power of abnormal STE (like apical post systolic shortening in PLN cardiomyopathy or abnormal deformation in the subtricuspidal region for arrhythmogenic right ventricular cardiomyopathy (ARVC)) as a parameter to detect early asymptomatic onset of the disease in mutation carriers or as a prognostic marker for ventricular arrhythmias and progression of the disease that often leads to advanced HF.^{51,52}

In this peculiar subset of patients FT CMR strain was deeply analyzed: CMR FT RV GLS and RV circumferential strain showed reduced value in patient with arrhythmic complications, but it did not demonstrate any additional value when adjusted for RVEF and LVEF.⁵³

Unfortunately, as previously shown for STE,⁵⁴ there is poor correlation between different software vendors and it is not advisable to compare absolute results for RV strain when obtained from different software. In particular, a study comparing four different vendors in ARVC patients showed that each software was able to distinguish between preclinical status and overt disease status of the disease, which is promising for the methodology per se, but there was poor correlation between the different labels.⁵⁵

Moreover, CMR FT on the right ventricle shows some disadvantages in terms of reproducibility among different software

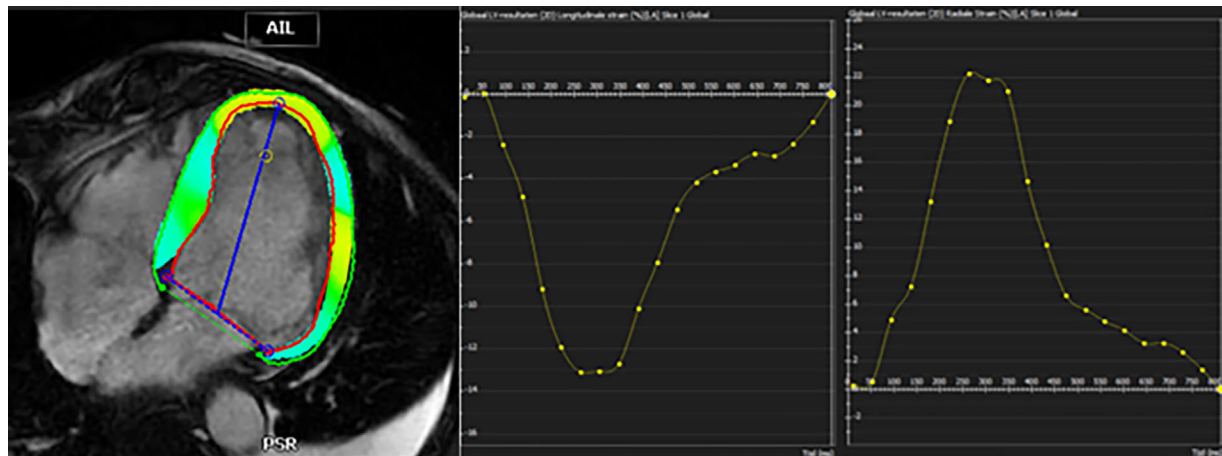


FIGURE 2 CMR example of the feature tracking module. Left: Long axis LV contours with longitudinal strain displayed with colors. Middle: Longitudinal strain curve. Right: Radial strain curve. (CMR: cardiac magnetic resonance; LV: left ventricle).

vendors and among different scanners, field strength a types of “cine” sequences.^{54,56}

Final comparison study in ARVC patients between STE RV strain and FT CMR RV strain did not show agreement between the two methods and failed to find a “conversion factor.”⁵⁷

Regarding the main issue of comparing different types of software in myocardial deformation index, extensive work has been done by Bogaert et al., they analyzed CMR FT LV-GLS and GRS in a wide range of patients (comprehending patients with severely reduced EF, ICM and dilated cardiomyopathy (DCM) patients) showing that the different software showed poor agreement with manual contouring measurement and that also GRS and GLS values are not interchangeable among vendors even though every vendor’s software showed good reproducibility inter observer and intra observer.^{58,59}

Beyond cardiomyopathies and prediction of progression of the disease, CMR FT RV strain was studied as a marker of pulmonary pressure, for example, Rolf et al. utilized RV strain by FT CMR as a surrogate of RV-LV interactions in patients with chronic thromboembolic pulmonary hypertension [CTEPH] they found out that RV global longitudinal strain and global circumferential strain (GCS) correlate with effective arterial elastance (E_{ea}) when measured by RHC as the ratio between mPAP and right ventricular stroke volume index, resulting as an indicator of afterload rather than contractility.⁶⁰

Furthermore, atrial function can be assessed through FT CMR. The left atrium deformation curve is divided into three phases: the reservoir phase reflecting the atrial relaxation and enlargement during ventricular systole, the conduit phase reflecting the passive filling of the atrium and the booster phase reflecting the atrial kick. Among these different phases, an interesting study showed how, in patients with DCM and HF, the left atrial conduit strain had a stronger prognostic value than LVEF, LAVi, or LV-GLS.⁶¹

Moreover, in patients with HFpEF, with diastolic dysfunction being the main pathological substrate, atrial strain by FT CMR has shown to be an independent predictor of the risk of incident HF admission or death.⁶²

Eventually, it is commonly acknowledged that RV-free wall strain (RV FWS) by STE echocardiography is an independent predictor of RV dysfunction after left ventricular assisted device (LVAD) placement. Further studies are needed to understand if RV FWS by FT CMR has the same prognostic value.⁶³

5 | TISSUE CHARACTERIZATION

CMR has the unique feature of tissue characterization by using late gadolinium enhancement (LGE) sequences and parametric mapping techniques.

Gadolinium (Gd) is a paramagnetic contrast agent, and its washout time is longer in tissues with an increase in extracellular space, such as with fibrosis or edema (Figure 3).

Moreover, Gd has the property to shorten the T1 relaxation time of the protons surrounding it. Therefore, the fibrotic/edematous tissue, where Gd tends to accumulate, has a reduced T1 time.

LGE sequences are acquired 10 min after contrast injection and consist of T1-weighted GRE or steady-state free precession (SSFP) sequences with a nonselective 180° inversion recovery (IR) pulse that allows nulling of the signal from healthy myocardium. The time from the IR pulse to the moment when the healthy myocardium signal is nulled is called inversion time and is patient-specific.^{45,64}

Parametric mapping is a technique that allows the building of a customizable color-coded map of the native T1 or T2 relaxation time of the myocardium in each voxel. Among the several ways to obtain it, the modified Look–Locker technique (MOLLI) is the most efficient (Figure 4). Parametric mapping, both for T1 and T2 maps, is a powerful technique that gives information about the composition of the myocardial tissue. High T1 mapping values usually reflect an increase of the fibrotic or oedematous component, while the elevation of T2 mapping values depends on a higher water concentration of the tissue. With T1 mapping after Gd administration, the extracellular volume (ECV) is also measurable.⁴⁵

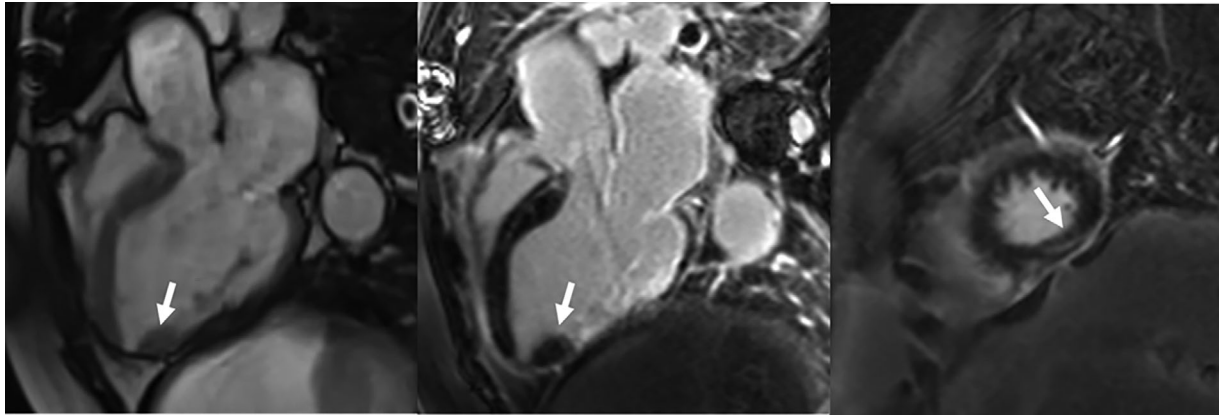


FIGURE 3 Possible complications in advanced heart failure. CMR images of an advanced heart failure patient with ischemic cardiomyopathy due to a transmural posterior myocardial infarction and with evidence of thrombus in the posterior apex of the LV (white arrow). Left: Cine three-chambers view. Middle: LGE three-chambers view, with evidence of transmural myocardial infarction to the posterior wall. Right: LGE apical short-axis slice. (CMR: cardiac magnetic resonance, LGE: late gadolinium enhancement; LV left ventricle).

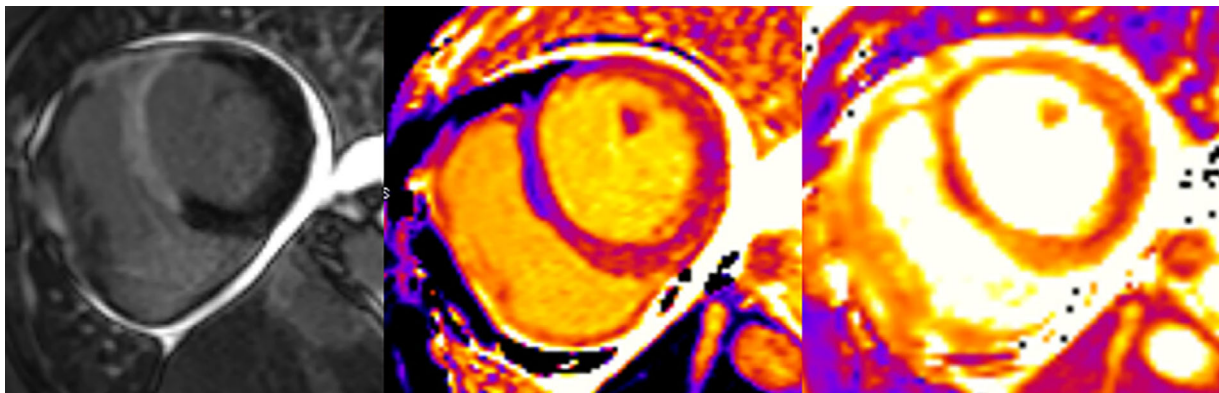


FIGURE 4 CMR images of an advanced heart failure patient with biopsy-proven giant cell myocarditis and mild pericardial effusion adjacent to the lateral wall of the LV. Left: Short axis basal slice, LGE visible at the anterior septum, RV and anterior wall. Middle: Basal slice T1 map showing high T1 values in the anterior septum, RV and anterior wall of the LV. Right: Basal slice T2 map showing high T2 values in the same region. (CMR: cardiac magnetic resonance; LGE: late gadolinium enhancement; LV: left ventricle; RV: right ventricle).

With regard to HF patients, LGE and parametric mapping are relevant players in assessing the etiology of HF but also in risk stratification and prognosis assessment.⁶⁵

Especially in ICM, LVEF and LGE via CMR provide valuable patient-specific information translating into a better assessment of prognosis and the risk of MACE compared to only LVEF.^{14–16} The NICM-SCAR study prospectively analyzed 1020 patients with NICM (average EF 33%, with around 35% of patients with NYHA class > II) with CMR and found out that CMR-derived LVEF and scar were both independent predictors of death for all causes, death for cardiovascular causes and HF hospitalization. Nevertheless, scar assessment outperformed LVEF in the three endpoints and had an incremental prognostic value for sudden cardiac death.⁶⁶ As a matter of fact, the DANISH trial outlined the scarce benefits in terms of long-term mortality for all causes with primary prevention ICD implantation based on the solely LVEF in patients with HF_rEF but without coronary artery disease.⁶⁷

In addition, results from a large multicenter study confirmed that the presence of LGE in NICM is associated with augmented risk for all causes mortality, sudden cardiac death, and a need for advanced HF therapies like heart transplantation or LVAD placement.⁶⁸ Also, a meta-analysis demonstrated that LGE is an independent predictor of all causes of mortality and major arrhythmic events in NICM patients.⁶⁹

Therefore, primary prevention ICD implantation indications are about to move from an “LVEF only” strategy to a more comprehensive assessment of the patient, giving a more important role to the presence or absence of LGE.

Halliday et al. deepened the relationship between LGE and NICM, correlating not only the presence of LGE but also its extent and location with prognosis. Their investigation revealed that even minimal amounts of LGE markedly elevate the risk of all-cause mortality, with marginal incremental risk associated with greater LGE volumes. As for

LGE localization, patients with LGE distribution exclusively at the free LV wall had similar mortality risk to those without LGE while patients with septal LGE showed to be at higher risk compared to the former. Among all, the highest risk was conferred by the presence of both LV free wall and septal LGE.⁷⁰

Nonetheless, the study may contain possible biases. First, the septal LGE should rise more awareness since it can more frequently lead to clinical consequences due to the crucial interaction between LV and RV during contraction. Second, the population of the study might come with inhomogeneity as 30% of the included patients have a postmyocarditis DCM with a different arrhythmogenic risk profile. Therefore, further studies are needed to understand the consequences of LGE location.

Convincing evidence in NICM is also coming from parametric mapping. Interestingly, in patients with NICM but without LGE, T1 mapping and ECV fraction are emerging as prognostic indicators.⁷¹ Besides, ECV alone is an independent predictor of arrhythmic burden⁷² and HF development⁷³ in these patients. The analysis of parametric mapping, mostly native T1 relaxation time, can undercover the presence of diffuse myocardial fibrosis that cannot be highlighted by LGE and, therefore, it can add prognostic value when dealing with cardiomyopathic patient (like amyloidosis) or with HF patients.⁷⁴ Moreover, in patient with HF and light chain cardiac amyloidosis the ECV mapping in myocardium and also in the liver and in the spleen can perform as an index of response to hematologic therapy, with baseline level of ECV in liver and in the myocardium, as well as the change after 6 months of therapy, being predictors for mortality.⁷⁵

6 | CMR IN HEART TRANSPLANT PATIENTS

Heart transplantation (HTx) is the gold standard of care for advanced HF patients when no contraindications are present.¹ The median survival after HTx is 12 years, with one-year survival being around 90%. It is well-known that the first few months after HTx are crucial in determining the long-term outcome.⁷⁶ In this delicate period the main threats are acute primary graft dysfunction and acute cardiac allograft rejection.⁷⁷ After this time, the main complications are related to cardiac allograft vasculopathy (CAV) leading to allograft failure, infectious diseases, malignancy and renal failure. CMR can have a potential role in managing these patients.

The gold standard for the diagnosis of acute cardiac allograft rejection (ACAR) is still endomyocardial biopsy (EBM),⁷⁸ but emerging data support CMR as a noninvasive surrogate of EMB. A promising study from St Vincent Hospital in Sydney randomized 40 patients to CMR or EBM for the diagnosis of ACAR and found that CMR-based surveillance with T1, T2 mapping and ECV, in the first-year post-transplant is noninferior to the standard of care with EMB. Moreover, only 6% of patients in the CMR arm requested a confirmative EBM due to unclear reports or logistic reasons, meaning that 94% of EBM could be avoided.⁷⁹ Considering that EBM could lead to a false negative due to sampling errors⁸⁰ or to complications,⁸¹ CMR is a feasible alternative in this tricky phase after HTx.

CMR is also important in long-term prognostication and management of CAV. In a study conducted by Minnesota Medical Center, stress CMR with Regadenoson has proven to be safe and effective in stratifying the risk of CAV.⁸² Besides perfusion, the presence of LGE was also associated with CAV. Moreover, a study by Shenoy et al. reported that the presence of LGE in HTx patients was independently associated with death for all causes or MACE. In addition, the extent was also of importance: every 1 % increase in LGE was associated with a 6% increase in risk of all causes of death and MACE.⁸³

Independent predictors of death and MACE after HTx are also CMR FT, LV-GLS (even if adjusted for LGE),⁸⁴ while T1 mapping and CMR-derived ECV are independent predictors of cardiac and noncardiac outcomes.⁸⁵

7 | CMR IN LVAD PATIENTS

LVAD is a pillar in the therapy of advanced HF and lately some major technological improvements led to a significant increase in the number of patients implanted with LVAD as destination therapy.⁸⁶

CMR in LVAD patients is contraindicated,¹ nevertheless, there are some aspects that are worth mentioning. In a case report of three patients who underwent an LVAD explantation a CMR analysis after the explantation reported an area of apical dyskinesia and fibrosis where the inflow cannula was placed allowing a more comprehensive study of the status of the heart after the explant.⁸⁷

Moreover, it is known that non pulsatile blood flow can cause hemocompatibility-related adverse events like stroke or nonsurgical bleeding⁸⁸ and also that continuous flow-related shear forces in the aorta can promote aortic root dilatation and aortic valve cusps fusion with the chronic increase in aortic transvalvular gradient leading to aortic regurgitation in this patient.^{89,90}

In this area, the CMR feature of 4D flow offers some interesting perspectives: Benk et al, from the University of Friburg in Germany, created an aortic phantom (replicating the elastic properties of the aortic vessel with a special resin) into which they placed an LVAD outflow graft, simulating different possible grafting techniques and different possible LVAD flows, and found that an outflow cannula with a larger anastomosis orifice to the ascending aorta, together with a lower LVAD speed, reduced adverse flow patterns in the aortic root, showing the promise of being able to find the best way to prevent hemocompatibility related adverse events.⁹⁰ In addition, a study from the University of Minnesota was able to use PC-MRI to study aortic flow and simulate the best position for an outflow cannula to avoid transporting embolic particles to the brain.⁹¹

8 | SCANNING PATIENTS WITH CARDIAC IMPLANTABLE ELECTRONIC DEVICES

Patients with advanced HF can often have cardiac implantable electronic devices (CIEDs) or other extracardiac elements for device-based therapy. The Food and Drug Administration approved a classification

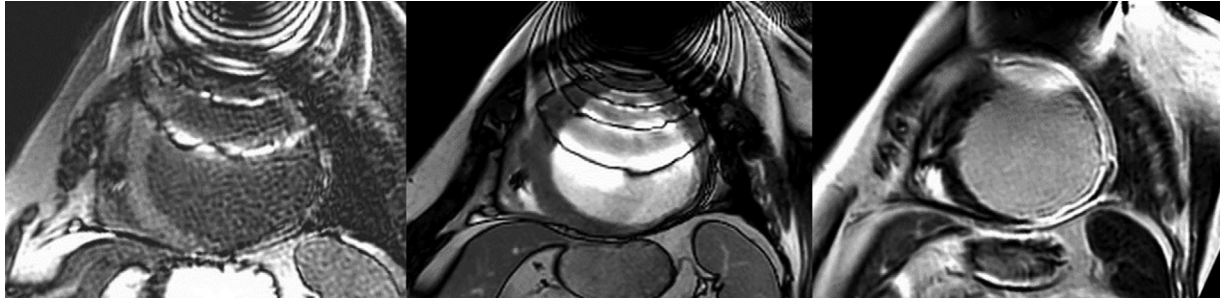


FIGURE 5 Ferromagnetic artifact during CMR acquisition. CMR images of an advanced heart failure patient with ischemic cardiomyopathy due to a previous posterior-lateral myocardial infarction with susceptibility artifact mimicking hyperintensity in the anterior wall on T1 mapping images and LGE images. Left: Mapping image. Middle: bSSFP cine image. Right: LGE image. (CMR: cardiac magnetic resonance, LGE: late gadolinium enhancement).

of all cardiac devices into three categories to estimate their risk when undergoing a CMR scan: CMR safe, conditional or unsafe. Devices falling into the first category require no precaution during the scan, the second ones are safe only under the very specific conditions provided in the labeling, and the third ones represent an absolute contraindication to a CMR examination.⁹²

The main safety concern with this magnetic field is the pulling and torquing forces that can be imparted on ferromagnetic objects; therefore, scanning in the first six weeks after the implant of a CIED is contraindicated due to the risk of displacement of the newly implanted catheters and generator.⁹³

The static magnetic field has been reported to potentially cause a “power on reset” effect that may, although very infrequently, reprogram the CIEDs from an asynchronous mode to an inhibited-pacing mode (i.e., from VOO to VVI) that may lead oversensing and pacing inhibition during the MRI scan.⁹⁴

The radiofrequency (RF) field is a temporary magnetic field that can induce an electrical current in the lead of the CIED, the so-called “antenna effect,”⁹⁵ which can heat the tip of the lead and damage the surrounding tissues (lead-tip heating phenomenon).⁹⁶ The heating can be diminished by blood flow. Therefore, epicardial leads are more dangerous to scan.⁹⁷ Furthermore, balanced SSFP sequences are the most dangerous in terms of a lead-tip heating phenomenon because they often use large flip angles that can lead to higher RF energy deposits in the patient.⁹⁸

The gradient magnetic fields are magnetic fields that are continuously switched on and off during the scan since they are used for spatial encoding. Similarly to what happens with RF fields, this temporary magnetic field can induce an electrical current that stimulates peripheral nerves (so-called peripheral nerve stimulation phenomenon) or interfere with the pacing and sensing functions.⁹⁹

To perform the scan, following international guidelines on CMR examination on patients with CIED as well as local protocols is advisable.^{98,100} In the event of a life-threatening arrhythmia, it is important to remember that ICD shock in the scanner area could fail due to possible interference of the magnetic static field on the ICD capacitor.¹⁰¹

Although the above-mentioned pitfalls to be aware of, with due precautions scanning patients with CIED is generally safe and it is becoming gradually more common in clinical practice. Nowadays, the main issue with CMR and CIEDs is the efficacy of the exam. Since CIEDs are composed of ferromagnetic elements, they can induce artifacts in the image, making the scan less useful for diagnostic purposes (Figure 5).

The image artifacts can be grouped into two main categories: the first one is susceptibility artifacts, derived from the local field inhomogeneity due to the presence of ferromagnetic materials, seen generally as signal void or hyperintensity and image distortion in the inversion recovery and SSFP sequences like LGE. The second category comprehends all the artifacts arising from the deterioration of the RF pulses.⁹²

There are many strategies to mitigate these effects of CIEDs on CMR, like increasing the distance between the generator and the heart by lifting the left arm,¹⁰² using deep learning techniques to overcome the artifacts,¹⁰³ or using smaller voxels, and smaller echo times with shorter RF pulses and larger receiver bandwidth in the frequency encoded direction.⁹⁸

A technique that showed the best results in correcting the artifacts is the use of wideband inversion pulses for IR or saturation recovery (SR) sequences. When applying these sequences, the CIEDs cause an off-resonance that undermines the presequence pulse preparation (like IR or SR), making the images very difficult to read.⁹⁸ Using a wider spectral bandwidth was proposed by Rashid et al.^{104,105} and has been proven to be effective in clinical practice.^{105,106}

Other devices can be used as therapy in advanced HF, such as cardiac contractility modulators and interatrial shunt devices.¹⁰⁷ The interatrial shunt devices are mainly used in HFpEF to reduce left atrial pressures and are marked as MR conditional.^{108,109} A cardiac contractility modulator is a transvenous device with a catheter to the right interventricular septum (IVS) that delivers high voltage impulses in the RV during the absolute refractory period, improving the calcium handling of the myocytes; this device is MR conditional only at 1.5 T for the head and the extremities.^{98,110}

In conclusion, the timing of scans poses challenges when managing CMR and advanced HF patients. There are instances where HF patients may find it difficult to tolerate extended periods of supine positioning or prolonged breath-holding requirements during scanning procedures. Additionally, adherence to the specific guidelines for MRI conditional devices often necessitates prolonged scanning durations. Nevertheless, MRI scanning techniques are evolving, and a novel scanning protocol that is ultrafast and with a single breath-hold has been developed, even though not yet widely available.¹¹¹

9 | CONCLUSION

In this review, we have highlighted the promising and evolving field of CMR when used in advanced HF patients. CMR allows careful and reliable assessment of volume and function, reducing inter- and intraobserver variability. This may be relevant to the implementation of risk scores, which are widely used to stratify patients with advanced HF. In addition, CMR opens a new era with FT analysis, providing additional information from myocardial deformation measures that may help in prognostic assessment and guidance of advanced HF therapies. Although echocardiography remains the gold standard in valvular heart disease, irreplaceable for its unique ability to understand the mechanism of valvular heart disease and its wide availability, flow analysis with CMR phase contrast sequences is becoming standard in clinical routine, also for its ability to add tissue characterization to the understanding of valvular heart disease 4D flow is an interesting novelty in the field of CMR, which is currently expanding and adding value to the available research; further studies are needed to introduce 4D flow into clinical practice. LGE and parametric mapping are well-known techniques that have a unique role in assessing the etiology of HF and stratifying the risk of arrhythmias and HF episodes. In addition, CMR can be useful in heart transplant patients to assess early graft dysfunction and is becoming easier and safer to use in patients with CIEDs. For the monitoring of heart transplant and CIEDs patients, and to advance the integration of CMR into daily clinical practice, future studies are required. There is still a long way to go for CMR in the field of advanced HF, but the future of this modality is certainly exciting.

CONFLICT OF INTEREST STATEMENT

The authors declare no conflicts of interest.

INSTITUTIONAL REVIEW BOARD STATEMENT

Not applicable

INFORMED CONSENT STATEMENT

Not applicable

DATA AVAILABILITY STATEMENT

No new data were created or analyzed in this study.

ORCID

Francesca Coraducci MD  <https://orcid.org/0009-0008-5893-1293>

Pietro Costantini MD  <https://orcid.org/0000-0002-5365-7028>

Anna Giulia Pavon MD  <https://orcid.org/0000-0002-8001-1476>

Marco Guglielmo MD  <https://orcid.org/0000-0003-1718-9949>

REFERENCES

- McDonagh TA, Metra M, Adamo M, et al. ESC Scientific Document Group. 2021 ESC Guidelines for the diagnosis and treatment of acute and chronic heart failure. *Eur Heart J*. 2021;42(36):3599-3726. doi:10.1093/eurheartj/ehab368 Erratum in: *Eur Heart J*. 2021 Oct 14
- Heidenreich PA, Bozkurt B, Aguilar D, et al. 2022 AHA/ACC/HFSA Guideline for the Management of Heart Failure: a Report of the American College of Cardiology/American Heart Association Joint Committee on Clinical Practice Guidelines. *Circulation*. 2022;145(18):e895-e1032. doi:10.1161/CIR.0000000000001063 Epub 2022 Apr 1. Erratum in: *Circulation*. 2022 May 3;145(18):e1033. Erratum in: *Circulation*. 2023 Apr 4;147(14):e674.
- Crespo-Leiro MG, Metra M, Lund LH, et al. Advanced heart failure: a position statement of the Heart Failure Association of the European Society of Cardiology. *Eur J Heart Fail*. 2018;20(11):1505-1535. doi:10.1002/ejhf.1236
- Fang JC, Ewald GA, Allen LA, et al. Heart Failure Society of America Guidelines Committee. Advanced (stage D) heart failure: a statement from the Heart Failure Society of America Guidelines Committee. *J Card Fail*. 2015;21(6):519-534. doi:10.1016/j.cardfail.2015.04.013
- Fang N, Jiang M, Fan Y. Ideal cardiovascular health metrics and risk of cardiovascular disease or mortality: a meta-analysis. *Int J Cardiol*. 2016;214:279-283.
- Dunlay SM, Roger VL, Killian JM, et al. Advanced heart failure epidemiology and outcomes: a population-based study. *JACC Heart Fail*. 2021;9(10):722-732. doi:10.1016/j.jchf.2021.05.009
- Truby LK, Rogers JG. Advanced heart failure: epidemiology, diagnosis, and therapeutic approaches. *JACC Heart Fail*. 2020;8(7):523-536. doi:10.1016/j.jchf.2020.01.014
- Levy WC, Mozaffarian D, Linker DT, et al. The Seattle Heart Failure Model: prediction of survival in heart failure. *Circulation*. 2006;113(11):1424-1433.
- Printezi MI, Yousif LIE, Kamphuis JAM, et al. LVEF by multigated acquisition scan compared to other imaging modalities in cardiology: a systematic review. *Curr Heart Fail Rep*. 2022;19(3):136-145. doi:10.1007/s11897-022-00544-3
- Bellenger NG, Burgess MI, Ray SG, et al. Comparison of left ventricular ejection fraction and volumes in heart failure by echocardiography, radionuclide ventriculography and cardiovascular magnetic resonance; are they interchangeable? *Eur Heart J*. 2000;21(16):1387-1396. doi:10.1053/ehj.2000.2011
- Clark J, Ionescu A, Chahal CAA, et al. Interchangeability in left ventricular ejection fraction measured by echocardiography and cardiovascular magnetic resonance: not a perfect match in the real world. *Curr Probl Cardiol*. 2023;48(8):101721. doi:10.1016/j.cpcardiol.2023.101721
- Petersen SE, Aung N, Sanghvi MM, et al. Reference ranges for cardiac structure and function using cardiovascular magnetic resonance (CMR) in Caucasians from the UK Biobank population cohort. *J Cardiovasc Magn Reson*. 2017;19:18.
- Mansell DS, Frank EG, Kelly NS, et al. Comparison of the within-reader and inter-vendor agreement of left ventricular circumferential strains and volume indices derived from cardiovascular magnetic resonance imaging. *PLoS One*. 2020;15(12):e0242908. doi:10.1371/journal.pone.0242908
- Joshi SB, Connelly KA, Jimenez-Juan L, et al. Potential clinical impact of cardiovascular magnetic resonance assessment of ejection fraction on eligibility for cardioverter defibrillator implantation.

- J Cardiovasc Magn Reson.* 2012;14(1):69. doi:10.1186/1532-429X-14-69
15. Pontone G, Guaricci AI, Andreini D, Solbiati A, Guglielmo M. Prognostic benefit of cardiac magnetic resonance over transthoracic echocardiography for the assessment of ischemic and nonischemic dilated cardiomyopathy patients referred for the evaluation of primary prevention implantable cardioverter-defibrillator therapy. *Circ Cardiovasc Imaging.* 2016;9(10):e004956. doi:10.1161/CIRCIMAGING.115.004956
 16. Pontone G, Guaricci AI, Fusini L, Baggiano A, Guglielmo M cardiac magnetic resonance for prophylactic implantable-cardioverter defibrillator therapy in ischemic cardiomyopathy: the DERIVATE-ICM International Registry. *JACC Cardiovasc Imaging.* 2023;16(11):1387-1400. doi:10.1016/j.jcmg.2023.03.015
 17. Guaricci AI, Masci PG, Muscogiuri G, et al. CarDiac magnEtic Resonance for prophylactic Implantable-cardioVerter defibrillAtor ThErapy in Non-Ischaemic dilated CardioMyopathy: an international Registry. *Europace.* 2021;23(7):1072-1083. doi:10.1093/europace/ueaa401
 18. Al'Aref SJ, Altibi AM, Malkawi A, et al. Cardiac magnetic resonance for prophylactic implantable-cardioverter defibrillator therapy international study: prognostic value of cardiac magnetic resonance-derived right ventricular parameters substudy. *Eur Heart J Cardiovasc Imaging.* 2023;24(4):472-482. doi:10.1093/ehjci/jeac124
 19. Badano LP, Addetia K, Pontone G, et al. Advanced imaging of right ventricular anatomy and function. *Heart.* 2020;106(19):1469-1476. doi:10.1136/heartjnl-2019-315178
 20. Hoffmann R, von Bardeleben S, ten Cate F, et al. Assessment of systolic left ventricular function: a multi-centre comparison of cineventriculography, cardiac magnetic resonance imaging, unenhanced and contrast-enhanced echocardiography. *Eur Heart J.* 2005;26(6):607-616. doi:10.1093/eurheartj/ehi083
 21. Otani K, Nabeshima Y, Kitano T, Takeuchi M. Accuracy of fully automated right ventricular quantification software with 3D echocardiography: direct comparison with cardiac magnetic resonance and semi-automated quantification software. *Eur Heart J Cardiovasc Imaging.* 2020;21:787-795.
 22. Ruijsink B, Puyol-Anton E, Oksuz I, et al. Fully automated, quality-controlled cardiac analysis from CMR: validation and large-scale application to characterize cardiac function. *J Am Coll Cardiol Img.* 2020;13:684-695.
 23. Hatipoglu S, Mohiaddin RH, Gatehouse P, et al. Performance of artificial intelligence for biventricular cardiovascular magnetic resonance volumetric analysis in the clinical setting. *Int J Cardiovasc Imaging.* 2022;38(11):2413-2424. doi:10.1007/s10554-022-02649-1
 24. Bhuva AN, Bai W, Lau C, et al. A multicenter, scan-rescan, human and machine learning CMR study to test generalizability and precision in imaging biomarker analysis. *Circ Cardiovasc Imaging.* 2019;12(10):e009214. doi:10.1161/CIRCIMAGING.119.009214
 25. Khan MA, Yang EY, Zhan Y, et al. Association of left atrial volume index and all-cause mortality in patients referred for routine cardiovascular magnetic resonance: a multicenter study. *J Cardiovasc Magn Reson.* 2019;21:4.
 26. Tamura H, Watanabe T, Nishiyama S, et al. Increased left atrial volume index predicts a poor prognosis in patients with heart failure. *J Card Fail.* 2011;17(3):210-216. doi:10.1016/j.cardfail.2010.10.006
 27. Myerson SG. CMR in evaluating valvular heart disease: diagnosis, severity, and outcomes. *JACC Cardiovasc Imaging.* 2021;14(10):2020-2032. doi:10.1016/j.jcmg.2020.09.029
 28. Vermes E, Iacuzio L, Levy F, et al. Role of cardiovascular magnetic resonance in native valvular regurgitation: a comprehensive review of protocols, grading of severity, and prediction of valve surgery. *Front Cardiovasc Med.* 2022;9:881141. doi:10.3389/fcvm.2022.881141
 29. Costantini P, Perone F, Siani A, et al. Multimodality imaging of the neglected valve: role of echocardiography, cardiac magnetic resonance and cardiac computed tomography in pulmonary stenosis and regurgitation. *J Imaging.* 2022;8(10):278. doi:10.3390/jimaging8100278
 30. Myerson SG, d'Arcy J, Christiansen JP, et al. Determination of clinical outcome in mitral regurgitation with cardiovascular magnetic resonance quantification. *Circulation.* 2016;133(23):2287-2296. doi:10.1161/CIRCULATIONAHA.115.017888
 31. Uretsky S, Animashaun IB, Sakul S, et al. American society of echocardiography algorithm for degenerative mitral regurgitation: comparison with CMR. *JACC Cardiovasc Imaging.* 2022;15(5):747-760. doi:10.1016/j.jcmg.2021.10.006
 32. Cavalcante JL, Kusunose K, Obuchowski NA, et al. Prognostic impact of ischemic mitral regurgitation severity and myocardial infarct quantification by cardiovascular magnetic resonance. *JACC Cardiovasc Imaging.* 2020;13(7):1489-1501. doi:10.1016/j.jcmg.2019.11.008
 33. Houard L, Amzulescu MS, Colin G, et al. Prognostic value of pulmonary transit time by cardiac magnetic resonance on mortality and heart failure hospitalization in patients with advanced heart failure and reduced ejection fraction. *Circ Cardiovasc Imaging.* 2021;14(1):e011680. doi:10.1161/CIRCIMAGING.120.011680
 34. Karakus G, Kammerlander AA, Aschauer S, et al. Pulmonary artery to aorta ratio for the detection of pulmonary hypertension: cardiovascular magnetic resonance and invasive hemodynamics in heart failure with preserved ejection fraction. *J Cardiovasc Magn Reson.* 2015;17(1):79. doi:10.1186/s12968-015-0184-3
 35. Myerson SG. Heart valve disease: investigation by cardiovascular magnetic resonance. *J Cardiovasc Magn Reson.* 2012;14:7. doi:10.1186/1532-429X-14-7
 36. Gorecka M, Bissell MM, Higgins DM, Garg P, Plein S, Greenwood JP. Rationale and clinical applications of 4D flow cardiovascular magnetic resonance in assessment of valvular heart disease: a comprehensive review. *J Cardiovasc Magn Reson.* 2022;24(1):49. doi:10.1186/s12968-022-00882-0
 37. Ashkir Z, Myerson S, Neubauer S, Carlhäll CJ, Ebbers T, Raman B. Four-dimensional flow cardiac magnetic resonance assessment of left ventricular diastolic function. *Front Cardiovasc Med.* 2022;9:866131. doi:10.3389/fcvm.2022.866131
 38. Kon MW, Myerson SG, Moat NE, Pennell DJ. Quantification of regurgitant fraction in mitral regurgitation by cardiovascular magnetic resonance: comparison of techniques. *J Heart Valve Dis.* 2004;13(4):600-607.
 39. Driessen MMP, Schings MA, Sieswerda GT, et al. Tricuspid flow and regurgitation in congenital heart disease and pulmonary hypertension: comparison of 4D flow cardiovascular magnetic resonance and echocardiography. *J Cardiovasc Magn Reson.* 2018;20(1):5. doi:10.1186/s12968-017-0426-7
 40. Feneis JF, Kyubwa E, Atianzar K, et al. 4D flow MRI quantification of mitral and tricuspid regurgitation: reproducibility and consistency relative to conventional MRI. *J Magn Reson Imaging.* 2018;48(4):1147-1158. doi:10.1002/jmri.26040
 41. Chelu RG, van den Bosch AE, van Kranenburg M, et al. Qualitative grading of aortic regurgitation: a pilot study comparing CMR 4D flow and echocardiography. *Int J Cardiovasc Imaging.* 2016;32(2):301-307. doi:10.1007/s10554-015-0779-7
 42. Ramos JG, Wieslander B, Fyrdahl A, et al. Pulmonary hypertension by catheterization is more accurately detected by cardiovascular magnetic resonance 4D-flow than echocardiography. *JACC Cardiovasc Imaging.* 2023;16(4):558-559. doi:10.1016/j.jcmg.2022.09.006
 43. Borhani A, Porter KK, Umair M, et al. Quantifying 4D flow cardiovascular magnetic resonance vortices in patients with pulmonary hypertension: a pilot study. *Pulm Circ.* 2023;13(4):e12298. doi:10.1002/pul2.12298
 44. Reiter G, Kovacs G, Reiter C, et al. Left atrial acceleration factor as a magnetic resonance 4D flow measure of mean pulmonary artery

- wedge pressure in pulmonary hypertension. *Front Cardiovasc Med.* 2022;9:972142. doi:10.3389/fcvm.2022.972142
45. *Cardiovascular MR manual*, Plein Greenwood, Springer.
 46. Claus P, Omar AMS, Pedrizzetti G, Sengupta PP, Nagel E. Tissue tracking technology for assessing cardiac mechanics: principles, normal values, and clinical applications. *JACC Cardiovasc Imaging.* 2015;8(12):1444-1460. doi:10.1016/j.jcmg.2015.11.001
 47. Lange T, Gertz RJ, Schulz A, et al. Impact of myocardial deformation on risk prediction in patients following acute myocardial infarction. *Front Cardiovasc Med.* 2023;10:1199936. doi:10.3389/fcvm.2023.1199936
 48. Cittar M, Cipriani A, Merlo M, et al. Prognostic significance of feature-tracking right ventricular global longitudinal strain in non-ischemic dilated cardiomyopathy. *Front Cardiovasc Med.* 2021;8:765274. doi:10.3389/fcvm.2021.765274
 49. Liu T, Gao Y, Wang H, et al. Association between right ventricular strain and outcomes in patients with dilated cardiomyopathy. *Heart.* 2021;107(15):1233-1239. doi:10.1136/heartjnl-2020-317949
 50. Taha K, Kirkels FP, Teske AJ, et al. Echocardiographic deformation imaging for early detection of genetic cardiomyopathies: JACC review topic of the week. *J Am Coll Cardiol.* 2022;79(6):594-608. doi:10.1016/j.jacc.2021.11.045
 51. Taha K, Te Rijdt WP, Verstraelen TE, et al. Early mechanical alterations in phospholamban mutation carriers: identifying subclinical disease before onset of symptoms. *JACC Cardiovasc Imaging.* 2021;14(5):885-896. doi:10.1016/j.jcmg.2020.09.030
 52. Mast TP, Taha K, Cramer MJ, et al. The prognostic value of right ventricular deformation imaging in early arrhythmogenic right ventricular cardiomyopathy. *JACC Cardiovasc Imaging.* 2019;12(3):446-455. doi:10.1016/j.jcmg.2018.01.012
 53. Bourfiss M, Prakken NHJ, James CA, et al. Prognostic value of strain by feature-tracking cardiac magnetic resonance in arrhythmogenic right ventricular cardiomyopathy. *Eur Heart J Cardiovasc Imaging.* 2022;24(1):98-107. doi:10.1093/ehjci/jeac030
 54. Bourfiss M, Vigneault DM, Aliyari Ghasebeh M, et al. Feature tracking CMR reveals abnormal strain in preclinical arrhythmogenic right ventricular dysplasia/cardiomyopathy: a multisite feasibility and clinical implementation study. *J Cardiovasc Magn Reson.* 2017;19(1):66. doi:10.1186/s12968-017-0380-4
 55. Farsalinos KE, Daraban AM, Ünlü S, Thomas JD, Badano LP, Voigt JU. Head-to-head comparison of global longitudinal strain measurements among nine different vendors: the EACVI/ASE inter-vendor comparison study. *J Am Soc Echocardiogr.* 2015;28(10):1171-1181. doi:10.1016/j.echo.2015.06.011
 56. Bourfiss M, Steensma BR, Te Riele ASJM, Leiner T, Velthuis BK, Raaijmakers AJE. Feature-tracking cardiac magnetic resonance of the right ventricle: effect of field strength, resolution and imaging sequence. *Eur J Radiol.* 2021;138:109671. doi:10.1016/j.ejrad.2021.109671
 57. Taha K, Bourfiss M, Te Riele ASJM, et al. A head-to-head comparison of speckle tracking echocardiography and feature tracking cardiovascular magnetic resonance imaging in right ventricular deformation. *Eur Heart J Cardiovasc Imaging.* 2021;22(8):950-958. doi:10.1093/ehjci/jeaa088
 58. Pierpaolo P, Rolf S, Manuel BP, et al. Left ventricular global myocardial strain assessment: are CMR feature-tracking algorithms useful in the clinical setting? *Radiol Med.* 2020;125(5):444-450. doi:10.1007/s11547-020-01159-1
 59. Barreiro-Pérez M, Curione D, Symons R, Claus P, Voigt JU, Bogaert J. Left ventricular global myocardial strain assessment comparing the reproducibility of four commercially available CMR-feature tracking algorithms. *Eur Radiol.* 2018;28(12):5137-5147. doi:10.1007/s00330-018-5538-4
 60. Rolf A, Keller T, Wolter JS, et al. Right ventricular strain by magnetic resonance feature tracking is largely afterload-dependent and does not reflect contractility: validation by combined volumetry and invasive pressure tracings. *Diagn Basel Switz.* 2022;12:3183.
 61. Raafs AG, Vos JL, Henkens MTHM, et al. Left atrial strain has superior prognostic value to ventricular function and delayed-enhancement in dilated cardiomyopathy. *JACC Cardiovasc Imaging.* 2022;15(6):1015-1026. doi:10.1016/j.jcmg.2022.01.016
 62. Chirinos JA, Sardana M, Ansari B, et al. Left atrial phasic function by cardiac magnetic resonance feature-tracking is a strong predictor of incident cardiovascular events. *Circ Cardiovasc Imaging.* 2018;11:e007512.
 63. Grant AD, Smedira NG, Starling RC, Marwick TH. Independent and incremental role of quantitative right ventricular evaluation for the prediction of right ventricular failure after left ventricular assist device implantation. *J Am Coll Cardiol.* 2012;60(6):521-528. doi:10.1016/j.jacc.2012.02.073
 64. Aquaro GD, De Gori C, Faggioni L, et al. Diagnostic and prognostic role of late gadolinium enhancement in cardiomyopathies. *Eur Heart J Suppl.* 2023;25(Suppl C):C130-C136. doi:10.1093/eurheartjsupp/suad015
 65. Contaldi C, Dellegrottaglie S, Mauro C, et al. Role of cardiac magnetic resonance imaging in heart failure. *Heart Fail Clin.* 2021;17(2):207-221. doi:10.1016/j.hfc.2021.01.001
 66. Klem I, Klein M, Khan M, et al. Relationship of LVEF and myocardial scar to long-term mortality risk and mode of death in patients with nonischemic cardiomyopathy. *Circulation.* 2021;143(14):1343-1358. doi:10.1161/CIRCULATIONAHA.120.048477
 67. Køber L, Thune JJ, Nielsen JC, et al. DANISH Investigators. Defibrillator implantation in patients with nonischemic systolic heart failure. *N Engl J Med.* 2016;375(13):1221-1230. doi:10.1056/NEJMoa1608029
 68. Alba AC, Gaztañaga J, Foroutan F, et al. Prognostic value of late gadolinium enhancement for the prediction of cardiovascular outcomes in dilated cardiomyopathy: an international, multi-institutional study of the MINICOR group. *Circ Cardiovasc Imaging.* 2020;13(4):e010105. doi:10.1161/CIRCIMAGING.119.010105
 69. Becker MAJ, Cornel JH, van de Ven PM, van Rossum AC, Allaart CP, Germans T. The prognostic value of late gadolinium-enhanced cardiac magnetic resonance imaging in nonischemic dilated cardiomyopathy: a review and meta-analysis. *JACC Cardiovasc Imaging.* 2018;11(9):1274-1284. doi:10.1016/j.jcmg.2018.03.006
 70. Halliday BP, Baksi AJ, Gulati A, et al. Outcome in dilated cardiomyopathy related to the extent, location, and pattern of late gadolinium enhancement. *JACC Cardiovasc Imaging.* 2019;12(8 Pt 2):1645-1655. doi:10.1016/j.jcmg.2018.07.015
 71. Li S, Zhou D, Sirajuddin A, et al. T1 mapping and extracellular volume fraction in dilated cardiomyopathy: a prognosis study. *JACC Cardiovasc Imaging.* 2022;15(4):578-590. doi:10.1016/j.jcmg.2021.07.023
 72. Rubiś PP, Dziewięcka EM, Banyś P, et al. Extracellular volume is an independent predictor of arrhythmic burden in dilated cardiomyopathy. *Sci Rep.* 2021;11(1):24000. doi:10.1038/s41598-021-03452-z
 73. Cadour F, Quemeneur M, Biere L, et al. Prognostic value of cardiovascular magnetic resonance T1 mapping and extracellular volume fraction in nonischemic dilated cardiomyopathy. *J Cardiovasc Magn Reson.* 2023;25(1):7. doi:10.1186/s12968-023-00919-y
 74. Costantini P, Ostillio E, Groenhoff L, et al. Aortic stenosis and amyloidosis: role of MRI and CT in the diagnosis of a sneaky association. *Curr Radiol Rep.* 2023;11:153-159. doi:10.1007/s40134-023-00419-y
 75. Ioannou A, Patel RK, Martinez-Naharro A, et al. Tracking multiorgan treatment response in systemic AL-amyloidosis with cardiac magnetic resonance derived extracellular volume mapping. *JACC Cardiovasc Imaging.* 2023;16(8):1038-1052. doi:10.1016/j.jcmg.2023.02.019

76. Singh TP, Mehra MR, Gauvreau K. Long-term survival after heart transplantation at centers stratified by short-term performance. *Circ Heart Fail.* 2019;12(11):e005914. doi:10.1161/CIRCHEARTFAILURE.118.005914
77. Radovancevic B, Konuralp C, Vrtovec B, et al. Factors predicting 10-year survival after heart transplantation. *J Heart Lung Transplant.* 2005;24(2):156-159. doi:10.1016/j.healun.2003.11.399
78. Costanzo MR, Dipchand A, Starling R, Anderson A, Chan M. International Society of Heart and Lung Transplantation Guidelines. The International Society of Heart and Lung Transplantation Guidelines for the care of heart transplant recipients. *J Heart Lung Transplant.* 2010;29(8):914-956. doi:10.1016/j.healun.2010.05.034
79. Anthony C, Imran M, Pouliopoulos J, et al. Cardiovascular magnetic resonance for rejection surveillance after cardiac transplantation. *Circulation.* 2022;145(25):1811-1824. doi:10.1161/CIRCULATIONAHA.121.057006
80. Fishbein MC, Kobashigawa J. Biopsy-negative cardiac transplant rejection: etiology, diagnosis, and therapy. *Curr Opin Cardiol.* 2004;19(2):166-169. doi:10.1097/00001573-200403000-00018
81. Saraiva F, Matos V, Gonçalves L, Antunes M, Providência LA. Complications of endomyocardial biopsy in heart transplant patients: a retrospective study of 2117 consecutive procedures. *Transplant Proc.* 2011;43(5):1908-1912. doi:10.1016/j.transproceed.2011.03.010
82. Kazmirczak F, Nijjar PS, Zhang L, et al. Safety and prognostic value of regadenoson stress cardiovascular magnetic resonance imaging in heart transplant recipients. *J Cardiovasc Magn Reson.* 2019;21(1):9. doi:10.1186/s12968-018-0515-2
83. Hughes A, Okasha O, Farzaneh-Far A, et al. Myocardial fibrosis and prognosis in heart transplant recipients. *Circ Cardiovasc Imaging.* 2019;12(10):e009060. doi:10.1161/CIRCIMAGING.119.009060
84. Shenoy C, Romano S, Hughes A, et al. Cardiac magnetic resonance feature tracking global longitudinal strain and prognosis after heart transplantation. *JACC Cardiovasc Imaging.* 2020;13(9):1934-1942. doi:10.1016/j.jcmg.2020.04.004
85. Chaikriangkrai K, Abbasi MA, Sarnari R, et al. Prognostic value of myocardial extracellular volume fraction and T2-mapping in heart transplant patients. *JACC Cardiovasc Imaging.* 2020;13(7):1521-1530. doi:10.1016/j.jcmg.2020.01.014
86. Varshney AS, DeFilippis EM, Cowger JA, Netuka I, Pinney SP, Givertz MM. Trends and outcomes of left ventricular assist device therapy: JACC focus seminar. *J Am Coll Cardiol.* 2022;79(11):1092-1107
87. Moon JC, Sievers B, Pennell DJ, Yacoub MH, Mohiaddin RH. Myocardial scarring caused by left ventricular assist device (LVAD) insertion demonstrated by cardiovascular magnetic resonance. *J Cardiovasc Magn Reson.* 2003;5(2):361-363. doi:10.1081/jcmr-120019417
88. Grinstein J, Belkin MN, Kalantari S, Bourque K, Salerno C, Pinney S. Adverse hemodynamic consequences of continuous left ventricular mechanical support: JACC review topic of the week. *J Am Coll Cardiol.* 2023;82(1):70-81. doi:10.1016/j.jacc.2023.04.045
89. Jorde UP, Uriel N, Nahumi N, et al. Prevalence, significance, and management of aortic insufficiency in continuous flow left ventricular assist device recipients. *Circ Heart Fail.* 2014;7(2):310-319. doi:10.1161/CIRCHEARTFAILURE.113.000878
90. Shad R, Kaiser AD, Kong S, et al. Patient-specific computational fluid dynamics reveal localized flow patterns predictive of post-left ventricular assist device aortic incompetence. *Circ Heart Fail.* 2021;14(7):e008034. doi:10.1161/CIRCHEARTFAILURE.120.008034
91. Amili O, MacIver R, Coletti F. Magnetic resonance imaging based flow field and lagrangian particle tracking from a left ventricular assist device. *J Biomech Eng.* 2020;142(2):021007. doi:10.1115/1.4043939
92. Symons R, Zimmerman SL, Bluemke DA. CMR and CT of the patient with cardiac devices: safety, efficacy, and optimization strategies. *JACC Cardiovasc Imaging.* 2019;12(5):890-903. doi:10.1016/j.jcmg.2018.09.030
93. Stühlinger M, Burri H, Vernooy K, Garcia R, Lenarczyk R, Sultan A. EHRA consensus on prevention and management of interference due to medical procedures in patients with cardiac implantable electronic devices. *Europace.* 2022;24(9):1512-1537. doi:10.1093/europace/euac040
94. Higgins JV, Sheldon SH. "Power-on resets" in cardiac implantable electronic devices during magnetic resonance imaging. *Heart Rhythm.* 2015;12(3):540-544. doi:10.1016/j.hrthm.2014.10.039
95. Nordbeck P, Fidler F, Friedrich MT, et al. Reducing RF-related heating of cardiac pacemaker leads in MRI: implementation and experimental verification of practical design changes. *Magn Reson Med.* 2012;68:1963-1972.
96. Nordbeck P, Ertl G, Ritter O. Magnetic resonance imaging safety in pacemaker and implantable cardioverter defibrillator patients: how far have we come? *Eur Heart J.* 2015;36(24):1505-1511. doi:10.1093/eurheartj/ehv086
97. Langman DA, Goldberg IB, Finn JP, Ennis DB. Pacemaker lead tip heating in abandoned and pacemaker-attached leads at 1.5 Tesla MRI. *J Magn Reson Imaging.* 2011;33(2):426-431. doi:10.1002/jmri.22463
98. Kim D, Collins JD, White JA, et al. SCMR expert consensus statement for cardiovascular magnetic resonance of patients with a cardiac implantable electronic device. *J Cardiovasc Magn Reson.* 2024;26(1):100995. doi:10.1016/j.jocmr.2024.100995
99. Rahsepar AA, Zimmerman SL, Hansford R, et al. The relationship between MRI radiofrequency energy and function of nonconditional implanted cardiac devices: a prospective evaluation. *Radiology.* 2020;295(2):307-313.
100. Bhuya A, Charles-Edwards G, Ashmore J, et al. Joint British Society consensus recommendations for magnetic resonance imaging for patients with cardiac implantable electronic devices. *Heart.* 2024;110(4):e3. doi:10.1136/heartjnl-2022-320810
101. Roguin A, Schwitter J, Vahlhaus C, et al. Magnetic resonance imaging in individuals with cardiovascular implantable electronic devices. *EP Europace.* 2008;10(3):336-346. doi:10.1093/europace/eun021
102. Vuorinen AM, Lehmonen L, Karvonen J, Holmström M, Kivistö S, Kaasalainen T. Reducing cardiac implantable electronic device-induced artefacts in cardiac magnetic resonance imaging. *Eur Radiol.* 2023;33(2):1229-1242. doi:10.1007/s00330-022-09059-w
103. Penso M, Babbaro M, Moccia S, et al. Cardiovascular magnetic resonance images with susceptibility artifacts: artificial intelligence with spatial-attention for ventricular volumes and mass assessment. *J Cardiovasc Magn Reson.* 2022;24(1):62. doi:10.1186/s12968-022-00899-5
104. Rashid S, Rapacchi S, Vaseghi M, et al. Improved late gadolinium enhancement MR imaging for patients with implanted cardiac devices. *Radiology.* 2014;270(1):269-274. doi:10.1148/radiol.13130942
105. Singh A, Kawaji K, Goyal N, et al. Feasibility of cardiac magnetic resonance wideband protocol in patients with implantable cardioverter defibrillators and its utility for defining scar. *Am J Cardiol.* 2019;123(8):1329-1335. doi:10.1016/j.amjcard.2019.01.018
106. Hilbert S, Weber A, Nehrke K, et al. Artefact-free late gadolinium enhancement imaging in patients with implanted cardiac devices using a modified broadband sequence: current strategies and results from a real-world patient cohort. *Europace.* 2018;20(5):801-807. doi:10.1093/europace/eux016
107. Fudim M, Abraham WT, von Bardeleben RS, et al. Device therapy in chronic heart failure: JACC state-of-the-art review. *J Am Coll Cardiol.* 2021;78(9):931-956. doi:10.1016/j.jacc.2021.06.040
108. Litwin SE, Borlaug BA, Komtebedde J, Shah SJ. Update on atrial shunt therapy for treatment of heart failure. *Struct Heart.* 2022;6(6):100090. doi:10.1016/j.shj.2022.100090
109. (accessed 18 february 2024). <https://corviamedical.com/corvia-atrial-shunt-system/#mri>

110. (accessed 18 february 2024). <https://impulse-dynamics.com/?s=MR+safety>
111. Gómez-Talavera S, Fernandez-Jimenez R, Fuster V, et al. Clinical validation of a 3-dimensional ultrafast cardiac magnetic resonance protocol including single breath-hold 3-dimensional sequences. *JACC Cardiovasc Imaging*. 2021;14(9):1742-1754. doi:10.1016/j.jcmg.2021.02.031

How to cite this article: Coraducci F, De Zan G, Fedele D, et al. Cardiac magnetic resonance in advanced heart failure. *Echocardiography*. 2024;41:e15849. <https://doi.org/10.1111/echo.15849>