

## BRIEF COMMUNICATION

# Preserving the ability to discriminate between left and right; A case study

Carla Ruis<sup>1,2</sup>  | Pierre A. Robe<sup>2</sup> | H. Chris Dijkerman<sup>1</sup>

<sup>1</sup>Helmholtz Institute, Experimental Psychology, Utrecht University, Utrecht, The Netherlands

<sup>2</sup>Department of Neurology and Neurosurgery, University Medical Centre Utrecht, Utrecht, The Netherlands

**Correspondence**

Carla Ruis, Helmholtz Institute, Experimental Psychology, Utrecht University, Heidelberglaan 1, Utrecht 3584 CS, The Netherlands.

Email: [c.ruis@uu.nl](mailto:c.ruis@uu.nl)

**Abstract**

Left-right orientation, a function related to the parietal lobe, is important for many daily activities. Here, we describe a left-handed patient with a right parietal brain tumour. During awake surgery, electric stimulation of the right inferior parietal lobe resulted in mistakes in his left-right orientation. Postoperatively our patient had no problems in discriminating left right. This case report shows that monitoring of left-right orientation during awake brain tumour surgery is feasible so that this function can be preserved.

**KEYWORDS**

brain tumour, craniotomy, left right orientation, parietal lobe

## INTRODUCTION

In comparison to surgery with general anaesthesia, awake brain surgery is associated with lower risks of neurological and language deficits on the one hand and more extensive tumour resection on the other hand (Bu et al., 2021; Hamer et al., 2012).

Historically, the focus was on language and motor functions during awake brain surgery, other cognitive functions are underexposed (Ruis, 2018). One such function that has received little attention in cognitive monitoring during awake craniotomies, is the ability to distinguish left from right. It is well-known that brain lesions can disrupt this ability, causing left-right disorientation (van Stralen et al., 2018). Together with finger agnosia, dyscalculia and dysgraphia, it constitutes Gerstmann's syndrome (Gerstmann, 1940). This syndrome is often related to left inferior parietal lobe damage. The ability to distinguish left and right is important for several aspects of daily functioning, considering for example performing navigation tasks (van der Ham et al., 2020).

To our knowledge so far, monitoring the ability to distinguish left from right during awake surgery has not yet been reported, while preserving this ability can have a great clinical impact. Here we describe a left-handed patient with a right parietal brain tumour who underwent awake surgery twice and showed consistent errors on a left-right orientation task during electrical stimulation of the right inferior parietal lobe.

This is an open access article under the terms of the [Creative Commons Attribution](https://creativecommons.org/licenses/by/4.0/) License, which permits use, distribution and reproduction in any medium, provided the original work is properly cited.

© 2023 The Authors. *Journal of Neuropsychology* published by John Wiley & Sons Ltd on behalf of The British Psychological Society.

## CASE

Our case is a 55-year-old, left-handed car mechanic. He was diagnosed with a brain tumour in the right parietal lobe (glioblastoma WHO grade 4, IDH wildtype) in 2020, for which awake brain surgery followed at the University Medical Center Utrecht. The patient recovered well after surgery, was able to perform daily activities and underwent a standard chemotherapy and radiation treatment (Stupp protocol). He then returned to work for a few hours a day. About 1 year after surgery, a Magnetic Resonance Imaging (MRI) scan suspected a potential recurrence of the tumour. A second awake craniotomy was planned. Two days before surgery, a comprehensive neuropsychological assessment was administered (see [Table 1](#) for an overview of his scores on the neuropsychological assessment). This neuropsychological assessment consisted of a set of more standardized tests to get an impression of overall cognitive functioning, and of a set of tests that could be used during surgery to monitor specific functions related to the location of the tumour. Preoperative administration of tests that can be used during surgery has two important purposes; patients can get familiar with the tasks and at the same time a baseline measurement is taken. At the moment of the preoperative neuropsychological assessment, our case experienced less strength in his left hand. Besides that, sensibility on his left side seemed to be decreased. Because of these complaints, he needed more help with daily activities. Neuropsychological tests revealed impairments in fine motor skills, sensibility, and proprioception. Furthermore, there were signs of finger gnosis, although the patient's performance may also have been affected by sensibility problems. In addition, optic ataxia was seen. Working memory and verbal fluency were also impaired. Other functions, like object naming, memory, inhibition, reading, clock reading, and calculation were unimpaired. Tests for visual perception showed a good acuity, but our case had problems in discriminating shapes, sizes and hues. Other visual functions (e.g. fragmented numbers) were unimpaired. There were no indications of neglect. Left-right orientation was also investigated and tested by using items based on the Berger Right-Left Discrimination Test (Ofte & Hugdahl, 2002). Line drawings of a human figure were presented. Body orientation could be front or back, for our case we only used the back orientation. Arms could be above or below the head and could be crossing the body midline or not. In each stimulus, one hand of the figure was red and our case was asked whether this was the right or the left hand. Stimuli were presented on an iPad as a Keynote presentation, four line drawings of a human figure per slide (see [Figure 1](#)). The patient was instructed to respond as quickly but also as accurately as possible. His test performance was fast and faultless (12/12), without moments of doubt.

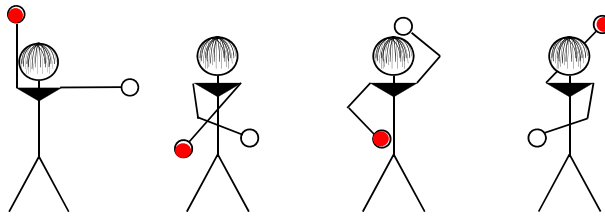
## RESULTS

Two days after the neuropsychological assessment, surgery took place under local anaesthesia and with cognitive monitoring. The aims of the awake brain tumour surgery were to confirm the diagnosis of tumour recurrence and to achieve a maximum resection of the MRI-evidenced changes, with preservation of different cognitive functions as much as possible to maintain the highest quality of life. Tests for motor functions (arm, hand, mouth), sensory functions (shoulder, arm, hand), visuoperception and left-right orientation were alternated. Tests were practised preoperatively, but because the position of the patient was now lying instead of sitting, each test was practised again at the beginning of the surgery, before the resection, to make sure he knew what was expected and he got used to being tested in this position. Motor functions were tested by asking the patient to make simple hand movements. Sensory functions were tested by gently stroking the patient's hand, arm and shoulder. To test visuoperception patient was asked to count dots, displayed on an iPad. Left-right orientation was tested the same way as preoperatively (see above). The iPad was held by the clinical neuropsychologist, about 30 to 40 cm from the patient's head. At the patient's request the position of the iPad could be adjusted, so that presented stimuli could be perceived in the most optimal way. Stimuli were elicited by manually tapping on the iPad by the clinical neuropsychologist. During surgery, the patient was constantly able to perform the tests. There was no interference from the language of speech disorders (e.g. speech arrest).

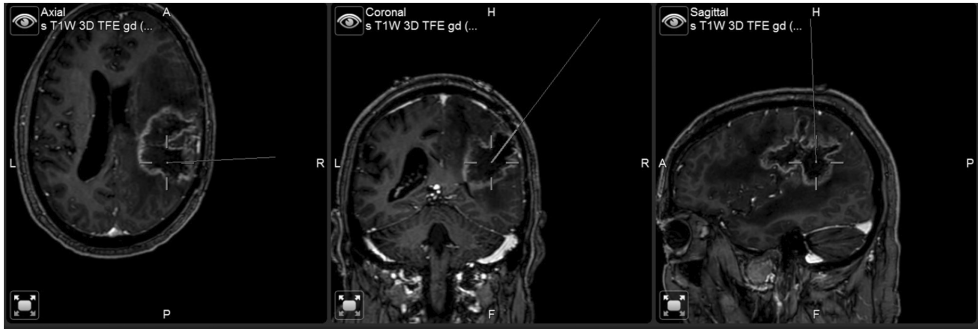TABLE 1 Overview of the scores on the preoperative neuropsychological assessment.

Task	Raw score (percentile)
Orientation in time, place and person	4/5, 4/5 and 3/3 (date was not correct and name of department was not correct)
Boston naming test	76/87 (25–50)
Visual association test	6/6 (>29)
Frontal assessment battery	
Go-no-go task	3/3
Fluency task	
Letters (D-A-T)	5-7-7 (7)
Animals	14 (7)
Digit Span (Wechsler Adult Intelligence Scale IV)	13 (1)
Cortical vision screening test	
Symbol acuity test	36/36
Shape discrimination test	7/8
Size discrimination test	0/2
Shape detection test	8/8
Hue discrimination test	0/4
Scattered dot counting test	3/4
Fragmented numbers test	8/8
Face perception test	8/8
Crowding test	4/4
Clock reading	
Analogue	5/5
Digital	5/5
Calculation (subtraction)	5/5
Fine motor skills	Right hand: unimpaired Left hand: opening and closing hand is possible but takes time, not able to make an okay sign, not able to tick the thumb with fingers
Sensibility	Right hand: unimpaired Left hand: does not feel gentle stroking that is noticed on the right hand
Finger gnosis	Right hand: unimpaired Left hand: cannot tell which finger is touched
Proprioception	Right side thumb: unimpaired Left side thumb, wrist, elbow: makes several mistakes
Optic ataxia	Right side: unimpaired Left side: needs to correct himself when grabbing
Left right orientation	12/12

During electric stimulation of the right inferior parietal lobe (see Figure 2), left-right orientation was impaired. Our case made mistakes and/or needed much more time to decide whether the red dot indicated the left or right hand (see Table 2). Electric stimulation (bipolar stimulations, 2mAmps, 50Hz, continuous trains of stimualtions subcortically or 3s cortically) at this specific subcortical region, in the depth of the right angular gyrus, was repeated four times right after the initiation of the task, a few minutes in between each time (in the meantime, other functions were monitored by stimulation at other spots). Each time errors and/or delayment of his answer were triggered by the stimulations. This contrasted with the lack of errors or hesitations on this test at all other surgical locations during the



**FIGURE 1** Stimuli (based on the Berger Right Left Discrimination Test) presented to our case. Body orientation was always back, meaning you see the drawn person on his back. The patient was asked whether the red dot indicated the left or right hand of the drawn figure.



**FIGURE 2** Electrical stimulation of the right inferior parietal lobe that resulted in making mistakes performing a left-right discrimination test.

**TABLE 2** Number of correct responses to the stimuli presented during stimulation of the right inferior parietal lobe.

First time of stimulation	8/12
Second time of stimulation	7/8
Third time of stimulation	6/8
Fourth time of stimulation	10/12+ slower response

debulking of the tumour. At those moments, our case was perfectly able to perform this task quickly and without making mistakes. Of note, these errors occurred when stimulating the parietal lobe within the limits of the suspected tumour recurrence, as determined on the T1 + gadolinium MRI neuronavigation images. In agreement with the patient, the surgeon did not pursue the tissue resection beyond this functional limit.

Pathological analysis of the resected tissue was consistent with a mixed image of tumour recurrence and radiotherapy effects. Five months after surgery, a postoperative neuropsychological assessment took place. Overall, in comparison to the preoperative neuropsychological assessment, no significant differences in cognitive functioning were seen. Left-right orientation was tested again and was almost faultless at that time (11/12).

## DISCUSSION

To maintain a good quality of life, mapping language and motor functions during awake brain surgery is not sufficient, other cognitive functions should also be taken into account (Duffau, 2021). Especially in patients with a tumour in the parietal lobe, this is important as this area subserves a wide range of

specific cognitive functions, such as body schema or spatial cognition (Duffau, 2021). Another specific cognition function, initially mostly assigned to body schema and later to mental manipulations (Mayer et al., 1999), and related to the parietal lobe, is left-right orientation. Making mistakes in distinguishing left and right in for example planning a route may have time-consuming consequences, but does not automatically lead to dangerous situations. However, in some industries, like health care or aviation, such mistakes may have serious consequences (Gormley & Brydges, 2016).

Monitoring left-right orientation during awake surgery has, to our knowledge, not been reported yet. Although enormous individual differences are reported in a healthy population in the ability to discriminate between left and right (both subjectively and objectively; Yamashita, 2022), our patient had never experienced problems at this level and moreover, preoperatively his performance was faultless. Therefore, it was even more important to maintain this skill, as part of maintaining a good quality of life. Our results show that it is possible to effectively monitor the ability to identify left and right during awake surgery and, as a result, to preserve this cognitive function. Moreover, our case shows that such function can be present within the radiological limits of the tumour (especially, as in this case, when a combination of tumour recurrence and of radiation therapy effects contribute to the picture).

The errors evoked reliably by stimulating the right inferior parietal cortex, are consistent with previous reports that the inferior parietal cortex is important for left-right orientation. While earlier reports particularly link this function to the left inferior parietal cortex (see for example Rusconi & Cubelli, 2019), other studies suggest that the right parietal cortex is involved when there is an element of mental rotation to the task (Ratcliff, 1979). With our patient, we only used the back condition, which does not require mental rotation to identify the left or right hand. Our case report shows that left-right orientation can also be linked to right parietal processing without a mental rotation component. This is consistent with a recent meta-analysis of the four components of Gerstmann syndrome that showed that for left-right orientation, in addition to left parietal foci, the right posterior parietal cortex (in particular the anterior and middle intraparietal sulcus and the parieto-occipital sulcus) was involved (Shahab et al., 2022). In addition, a study by van Stralen et al. (2018) reported that problems with left-right orientation are also associated with cortical lesions in the right hemisphere, especially the insula. However, the left-handedness of our patient may also have played a role, because left-handers are less lateralized (also for specific functions such as body perception) than right-handers (Johnstone et al., 2021).

Although the errors that our case made at the left-right orientation test appear to be based on a disorder in left-right orientation, we cannot fully rule out the role of subtle language distortions or visuospatial disorders in his performance. The left-handedness of this case may have played a role in the localization of language functions. However, during the patient's first operation, naming was tested at the gyrus angularis and no disorders in language functions were seen at that time. Furthermore, we did not observe any alteration of speech this second time (no problems in spontaneous speech and understanding of instructions). At the end of the resection, naming and visual functions were tested. Our patient had an almost perfect score on the naming test and a faultless score on a test measuring visuospatial functions.

In conclusion, the parietal lobe is related to many specific cognitive functions. In order to maintain the best quality of life in brain tumour patients, impairment in such functions should be prevented. This case report shows that monitoring of left-right orientation is feasible during awake brain surgery and that this cognitive function can be preserved.

## AUTHOR CONTRIBUTIONS

**Carla Ruis:** Conceptualization; investigation; resources, writing – original draft; writing – review and editing. **Pierre A. Robe:** Conceptualization; investigation; resources, writing – original draft; writing – review and editing. **H. Chris Dijkerman:** Conceptualization; writing – original draft; writing – review and editing.

## ACKNOWLEDGEMENTS

No funding was received for conducting this study.

## CONFLICT OF INTEREST STATEMENT

None declared.

## DATA AVAILABILITY STATEMENT

The data that support the findings of this study are available from the corresponding author upon reasonable request.

## ORCID

Carla Ruis  <https://orcid.org/0000-0003-0801-8937>

## REFERENCES

- Bu, L. H., Zhang, J., Lu, J. F., & Wu, J. S. (2021). Glioma surgery with awake language mapping versus generalized anesthesia: A systematic review. *Neurosurgical Review, 44*(4), 1997–2011.
- Duffau, H. (2021). New philosophy, clinical pearls, and methods for intraoperative cognition mapping and monitoring “à la carte” in brain tumor patients. *Neurosurgery, 88*(5), 919–930.
- Gerstmann, J. (1940). Syndrome of finger agnosia, disorientation for right and left, agraphia and acalculia: Local diagnostic value. *Archives of Neurology and Psychiatry, 44*(2), 398–408.
- Gormley, G., & Brydges, R. (2016). Difficulty with right–left discrimination: A clinical problem? *Canadian Medical Association Journal, 188*(2), 98–99.
- Hamer, P. D. W., Robles, S. G., Zwinderman, A. H., Duffau, H., & Berger, M. S. (2012). Impact of intraoperative stimulation brain mapping on glioma surgery outcome: A meta-analysis. *Journal of Clinical Oncology, 30*(20), 2559–2565.
- Johnstone, L. T., Karlsson, E. M., & Carey, D. P. (2021). Left-handers are less lateralized than right-handers for both left and right hemispheric functions. *Cerebral Cortex, 31*(8), 3780–3787.
- Mayer, E., Martory, M. D., Pegna, A. J., Landis, T., Delavelle, J., & Annoni, J. M. (1999). A pure case of Gerstmann syndrome with a subangular lesion. *Brain, 122*(6), 1107–1120.
- Ofte, S. H., & Hugdahl, K. (2002). Rightleft discrimination in male and female, young and old subjects. *Journal of Clinical and Experimental Neuropsychology, 24*(1), 82–92.
- Ratcliff, G. (1979). Spatial thought, mental rotation and the right cerebral hemisphere. *Neuropsychologia, 17*(1), 49–54. [https://doi.org/10.1016/0028-3932\(79\)90021-6](https://doi.org/10.1016/0028-3932(79)90021-6)
- Ruis, C. (2018). Monitoring cognition during awake brain surgery in adults: A systematic review. *Journal of Clinical and Experimental Neuropsychology, 40*(10), 1081–1104.
- Rusconi, E., & Cubelli, R. (2019). The making of a syndrome: The English translation of Gerstmann's first report. *Cortex, 117*, 277–283. <https://doi.org/10.1016/j.cortex.2019.03.021>
- Shahab, Q. S., Young, I. M., Dadario, N. B., Tanglay, O., Nicholas, P. J., Lin, Y. H., Fonseka, R. D., Yeung, J. T., Bai, M. Y., Teo, C., Doyen, S., & Sughrue, M. E. (2022). A connectivity model of the anatomic substrates underlying Gerstmann syndrome. *Brain Communications, 4*(3), fcac140.
- van der Ham, I. J., Claessen, M. H., Evers, A. W., & van der Kuil, M. N. (2020). Large-scale assessment of human navigation ability across the lifespan. *Scientific Reports, 10*(1), 1–12.
- van Stralen, H. E., Dijkerman, H. C., Biesbroek, J. M., Kuijf, H. J., van Gemert, H. M. A., Sluiter, D., Kappelle, L. J., & van Zandvoort, M. J. (2018). Body representation disorders predict left right orientation impairments after stroke: A voxel-based lesion symptom mapping study. *Cortex, 104*, 140–153.
- Yamashita, H. (2022). Investigating individual differences in left-right confusion among healthy Japanese young adults. *Culture and Brain, 10*, 1–16.

**How to cite this article:** Ruis, C., Robe, P. A., & Dijkerman, H. C. (2024). Preserving the ability to discriminate between left and right; A case study. *Journal of Neuropsychology, 18*(Suppl. 1), 85–90. <https://doi.org/10.1111/jnp.12348>