

Impact of ≥ 0.1 -mm free resection margins on local intramural residual cancer after local excision of T1 colorectal cancer




Authors

Kim M. Gijsbers^{1,2}, Lisa van der Schee¹, Tessa van Veen¹, Annemarie M. van Berkel³, Femke Boersma⁴, Carolien M. Bronkhorst⁵, Paul D. Didden¹, Krijn J.C. Haasnoot¹, Anne M. Jonker⁶, Koen Kessels⁷, Nikki Knijn⁸, Ineke van Lijnschoten⁹, Clinton Mijnaals¹⁰, Anya N. Milne¹¹, Freek C.P. Moll¹², Ruud W.M. Schrauwen¹³, Ramon-Michel Schreuder¹⁴, Tom J. Seerden¹⁵, Marcel B.W.M. Spanier¹⁶, Jochim S. Terhaar Sive Droste¹⁷, Emma Witteveen¹⁸, Wouter H. de Vos tot Nederveen Cappel¹⁹, Frank P. Vleggaar¹, Miangela M. Laclé²⁰, Frank ter Borg^{*,2}, Leon M.G. Moons^{*,1}, Dutch T1 CRC Working Group

Institutions

- 1 Department of Gastroenterology & Hepatology, University Medical Center Utrecht, Utrecht, The Netherlands
- 2 Department of Gastroenterology & Hepatology, Deventer Hospital, Deventer, The Netherlands
- 3 Department of Gastroenterology & Hepatology, Noordwest Hospital, Alkmaar, The Netherlands
- 4 Department of Gastroenterology & Hepatology, Gelre Hospital, Apeldoorn, The Netherlands
- 5 Pathology-DNA, Jeroen Bosch Hospital, Den Bosch, The Netherlands
- 6 Department of Pathology, Gelre Hospital, Apeldoorn, The Netherlands
- 7 Department of Gastroenterology & Hepatology, St. Antonius Hospital, Nieuwegein, The Netherlands
- 8 Pathology-DNA, Rijnstate Hospital, Arnhem, The Netherlands
- 9 Department of Pathology, PAMM, Eindhoven, The Netherlands
- 10 Department of Pathology, Amphia Hospital, Breda, The Netherlands
- 11 Pathology-DNA, St. Antonius Hospital, Nieuwegein, The Netherlands
- 12 Department of Pathology, Isala Clinics, Zwolle, The Netherlands
- 13 Department of Gastroenterology & Hepatology, Bernhoven, Uden, The Netherlands
- 14 Department of Gastroenterology & Hepatology, Catharina Hospital, Eindhoven, The Netherlands
- 15 Department of Gastroenterology & Hepatology, Amphia Hospital, Breda, The Netherlands
- 16 Department of Gastroenterology & Hepatology, Rijnstate Hospital, Arnhem, The Netherlands
- 17 Department of Gastroenterology & Hepatology, Jeroen Bosch Hospital, Den Bosch, The Netherlands

- 18 Department of Pathology, Noordwest Hospital, Alkmaar, The Netherlands
- 19 Department of Gastroenterology & Hepatology, Isala Clinics, Zwolle, The Netherlands
- 20 Department of Pathology, University Medical Center Utrecht, Utrecht, The Netherlands

submitted 30.6.2021

accepted after revision 15.11.2021

Bibliography

Endosc Int Open 2022; 10: E282–E290

DOI 10.1055/a-1736-6960

ISSN 2364-3722

© 2022. The Author(s).

This is an open access article published by Thieme under the terms of the Creative Commons Attribution-NonDerivative-NonCommercial License, permitting copying and reproduction so long as the original work is given appropriate credit. Contents may not be used for commercial purposes, or adapted, remixed, transformed or built upon. (<https://creativecommons.org/licenses/by-nc-nd/4.0/>)

Georg Thieme Verlag KG, Rüdigerstraße 14,
70469 Stuttgart, Germany

Corresponding author

Leon M.G. Moons, Dept Gastroenterology & Hepatology,
University Medical Center Utrecht, 3508 GA Utrecht, The
Netherlands

Fax: +0570-501420

l.m.g.moons@umcutrecht.nl

ABSTRACT

Background and study aims A free resection margin (FRM) > 1 mm after local excision of a T1 colorectal cancer (CRC) is known to be associated with a low risk of local intramural residual cancer (LIRC). The risk is unclear, however, for FRMs between 0.1 to 1 mm. This study evaluated the risk of LIRC after local excision of T1 CRC with FRMs between 0.1 and 1 mm in the absence of lymphovascular inva-

* These authors contributed equally

sion (LVI), poor differentiation and high-grade tumor budding (Bd2–3).

Patients and methods Data from all consecutive patients with local excision of T1 CRC between 2014 and 2017 were collected from 11 hospitals. Patients with a FRM ≥ 0.1 mm without LVI and poor differentiation were included. The main outcome was risk of LIRC (composite of residual cancer in the local excision scar in adjuvant resection specimens or local recurrence during follow-up). Tumor budding was also assessed for cases with a FRM between 0.1 and 1 mm.

Results A total of 171 patients with a FRM between 0.1 and 1 mm and 351 patients with a FRM > 1 mm were included. LIRC occurred in five patients (2.9%; 95% confidence interval [CI] 1.0–6.7%) and two patients (0.6%; 95% CI 0.1–2.1%), respectively. Assessment of tumor budding showed Bd2–3 in 80% of cases with LIRC and in 16% of control cases. Accordingly, in patients with a FRM between 0.1 and 1 mm without Bd2–3, LIRC was detected in one patient (0.8%; 95% CI 0.1–4.4%).

Conclusions In this study, risks of LIRC were comparable for FRMs between 0.1 and 1 mm and > 1 mm in the absence of other histological risk factors.

Introduction

Submucosal invasive colorectal cancers (T1 CRCs) are increasingly treated by local excision, followed by endoscopic follow-up in case of low risk of lymph node metastasis (LNM) or local intramural residual cancer (LIRC). The risks for a complicated course (9.2% to 19.2%) and mortality (0.6% to 1.9%) after elective bowel resection underscore the importance of balancing the risk of LNM and LIRC on the one hand and of completion surgery on the other hand [1, 2]. The risk of LNM and LIRC can be assessed with several models, which in addition to lymphovascular invasion (LVI), poor differentiation, and high-grade tumor budding (Bd2–3), include a free resection margin (FRM) [3, 4]. However, the definition of a FRM differs between guidelines from > 1 mm to > 0.1 mm [5–8].

Several studies have shown that, in the absence of other histological risk factors, the risk of LIRC is $< 2\%$ in tumors with a FRM > 1 mm [9–11]. The 1-mm FRM cut-off in several guidelines is based on studies showing an increased risk of LIRC (7% to 17%) in case of a resection margin < 1 mm [12–14]. However, the reported outcomes are presumably overestimations of the risk of a FRM between 0.1 and 1 mm, as these studies did not distinguish between a positive (R1) resection margin and a FRM between 0.1 and 1 mm. Instead, these groups were combined for analysis and compared to a group with FRMs > 1 mm. Moreover, not all studies excluded T1 CRCs with poor differentiation, LVI or high-grade tumor budding, and the presence of these risk factors makes it impossible to discriminate the risk of LIRC for a FRM between 0.1 and 1 mm only. In contrast to the referenced papers, there are a few studies with small sample sizes that did investigate the risk of LIRC in FRMs between 0.1 and 1 mm and showed a pooled risk of LIRC of 4.2% (0%–37.5%) [10, 15–18].

Based on current literature, it is difficult to estimate the risk of LIRC in patients with a T1 CRC with a FRM between 0.1 and 1 mm in the absence of other histological risk factors. It is, however, of crucial importance to know this risk in order to inform patients about the benefit of completion surgery during shared decision making. The aim of this study, therefore, was to evaluate the risk of LIRC after local excision of T1 CRC in patients with

a resection margin between 0.1 and 1 mm in the absence of other histological risk factors.

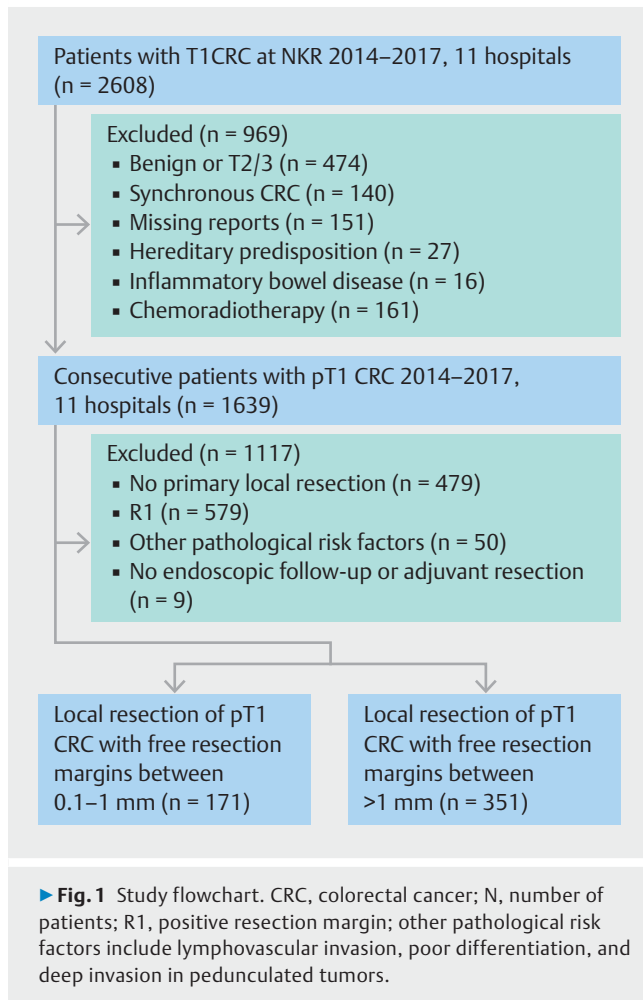
Patients and methods

Study design

This study was a multicenter retrospective cohort. All consecutive patients diagnosed with a T1 CRC between 2014 and 2017 in one academic and 10 non-academic hospitals in the Netherlands were included in the cohort. Patients were identified through the Netherlands Cancer Registry and their electronic medical records (EMRs) were reviewed, including pathology, endoscopy, and radiology reports. Patients were included if the local pathology report confirmed the diagnosis of T1 CRC, defined as tumor growth through the muscularis mucosa and into, but not beyond, the submucosa.

Exclusion criteria included familial predisposition to CRC, non-adenocarcinoma, inflammatory bowel disease, missing endoscopy or pathology reports, neoadjuvant chemoradiotherapy, synchronous second primary CRC, and diagnosis of other $\geq T2$ stage CRC within the previous 5 years or at the time of detection of T1 CRC. Within this cohort, patients were identified meeting the following inclusion criteria: 1) endoscopic or local surgical excision of a T1 CRC; 2) a FRM ≥ 0.1 mm (in cases with mention of both lateral and deep resection margins, cases were only selected if both were free of carcinoma and grouped based on the deep resection margin) (cases with endoscopic piecemeal resection could be included if only one fragment contained malignancy and the resection margin could be evaluated); 3) absence of poor differentiation and LVI; and 4) at least 6 months of follow-up (► Fig. 1). Tumor budding and deep submucosal invasion were not used as exclusion criteria, as they were not part of the Dutch prediction model, and therefore, are poorly reported [6]. Patients were categorized in two subgroups: FRM between 0.1 and 1 mm and with a free resection margin > 1 mm.

This study was approved by the Medical Ethical Review Committee of the University Medical Center Utrecht (reference number 15–487/C) on August 18, 2015 and was carried out in accordance with the Helsinki Declaration. All patient data were coded. The study conformed to the STROBE guideline for co-



hort studies (Strengthening the Reporting of Observational Studies in Epidemiology) [19].

Data collection

Demographic and clinical data were collected at the participating hospitals. Patient characteristics were extracted from the EMRs and included age, gender, and physical status according to the American Society of Anesthesiologists (ASA) classification system [20]. Data on polyp morphology, location, size, and type of endoscopic treatment were extracted from the endoscopy report. Tumor location was defined as rectum if the polyp was located ≤ 15 cm from the anal verge according to the endoscopy report. In case of missing data on polyp morphology, an attempt was made to obtain this information by reexamining the original endoscopy images together with the local investigator. Histological features were extracted from the standardized histology reports and included LVI, differentiation grade, and resection margins [21]. In case of completion surgery, data on the number of dissected and positive lymph nodes and presence of residual malignant cells in the adjuvant resection specimen were extracted. Follow-up data including findings during colonoscopy, biopsies of the endoscopic excision scar, and vital status were obtained from the EMRs and endoscopy reports. Data on baseline and follow-up imaging of

liver and thorax were extracted from the radiology reports. In case of recurrent cancer, characteristics of the recurrence, such as stage and treatment, were collected.

Main outcomes

The main outcome was the risk of LIRC, which was a composite of intramural residual cancer in the resection specimen of completion surgery, intramural residual cancer in the full-thickness scar excision specimen (local full-thickness scar excision with either endoscopic full-thickness resection (eFTR) [22, 23], or transanal endoscopic microsurgery/transanal minimally invasive surgery [24]), or recurrence of cancer at the scar during endoscopic follow-up. Although not part of the primary research question, we recorded the number of patients with metastasis, defined as either histologically confirmed LNM or distant metastasis confirmed by imaging or histology and molecular profiling. New metachronous primary CRC during follow-up was not considered as recurrence. In patients with a free resection margin between 0.1 and 1 mm, we stratified for colon vs. rectum, sessile vs. pedunculated, and patients < 70 vs. ≥ 70 years of age to investigate groups with higher risks of LIRC or complications during surgery.

Additional assessment of tumor budding

Data provided in the local pathology report according to the Dutch guideline were used for this study [21]. Before dissection of endoscopically or local surgically resected T1 CRCs, the resection margins were identified and painted with ink. The specimens were transversely sectioned in 3-mm slices and totally embedded in sequentially labeled cassettes for histological evaluation. LVI was primarily evaluated using hematoxylin and eosin (H&E) staining, with additional immunohistochemical staining in cases with doubt (e.g. D2–40, CD-31, Victoria Blue or Elastica Van Gieson).

In addition, we asked the pathologists in the participating centers to assess tumor budding in cases with a FRM between 0.1 and 1 mm, as this was not mentioned in most original reports. Tumor budding was determined according to the International Tumor Budding Consensus guideline [25]. Bd2 and Bd3 were considered high-grade tumor budding.

Statistical analysis

Baseline characteristics were reported using standard descriptive statistics. Continuous data were expressed as medians with interquartile ranges (IQRs), while categorical data were expressed as frequencies and percentages. Binomial statistics were used to calculate 95% confidence intervals (CIs). Subgroup analyses were performed to stratify the risk of LIRC and metastasis for polyp morphology, polyp location, patient age and follow-up length. Differences in risks between subgroups and the overall cohort were calculated using the Fisher's exact test. Missing data were assessed according to the missing completely at random (MCAR) test by Little et al [26]. A two-sided $P < 0.05$ was considered significant. IBM SPSS Statistics version 25 (SPSS Inc., Chicago, Illinois, United States) was used for all analyses.

► **Table 1** Baseline characteristics.

	Free resection margin between 0.1 and 1 mm (N=171)	Free resection margin >1 mm (N=351)	(P value)
Age (years), median (IQR)	68 (63–73)	69 (63–74)	0.281
Male gender, n (%)	117 (68.4)	223 (63.5)	0.271
Colonoscopy indication, n (%)			0.859
▪ Screening program	113 (66.1)	230 (65.5)	
▪ Symptomatic	46 (26.9)	100 (28.5)	
▪ Other	12 (7.0)	21 (6.0)	
ASA score, n (%)			0.916
▪ ASA I-II	152 (89.4)	314 (89.7)	
▪ ASA III-IV	18 (10.6)	36 (10.3)	
▪ Missing	1	1	
Tumor location, n (%)			0.045
▪ Colon	117 (68.4)	269 (76.6)	
▪ Rectum	54 (31.6)	82 (23.4)	
Polyp morphology, n (%)			<0.001
▪ Pedunculated	48 (28.1)	220 (62.7)	
▪ Non-pedunculated	123 (71.9)	131 (37.3)	
▪ Polyp size (mm), median (IQR) ¹	15 (12–20)	16 (12–20)	0.027
Resection technique n (%)			<0.001
▪ En bloc EMR	131 (76.6)	263 (74.9)	
▪ Piecemeal EMR	16 (9.4)	18 (5.1)	
▪ ESD	16 (9.4)	9 (2.6)	
▪ TEM	5 (2.9)	38 (10.8)	
▪ eFTR	1 (0.6)	10 (2.8)	
▪ Missing	2 (1.1)	13 (3.7)	
Follow-up length (months), median (IQR)	33 (19–47)	20 (11–30)	<0.001

N, number; IQR, interquartile range; ASA, American Society of Anesthesiologists; mm, millimeter; EMR, endoscopic mucosal resection; ESD, endoscopic submucosal dissection; TEM, transanal endoscopic microsurgery; eFTR, endoscopic full-thickness resection.

¹ Polyp size was missing in seven patients with a free resection margin (FRM) between 0.1 and 1 mm and in 19 patients with a FRM > 1 mm.

Results

Characteristics of patients, tumors, and follow-up

Of the 2608 identified patients with T1 CRC in the participating hospitals, 1639 were enrolled in the database (► **Fig. 1**). In the final cohort, 171 patients (10%) with a FRM between 0.1 and 1 mm were included, with a median age of 68 years (IQR 63–73), 31.6% of whom were women, and the median follow-up was 33 months (IQR 19–47 months). There were 351 patients (21%) included with a FRM > 1 mm with a median age of 69 years (IQR 63–74), 36.5% were women, and the median follow-up was 20 months (IQR 11–30 months). An overview of patient characteristics at baseline is presented in ► **Table 1**. No imputation was performed for missing data as these were missing completely

at random, according to the MCAR test. Besides, the number of incomplete cases was <10%, with missing data merely for ASA classification, polyp size and resection technique, so the impact of imputation would be negligible. The secondary treatment strategy in cases with a FRM between 0.1 and 1 mm consisted of endoscopic follow-up (100 (59%) patients), local full-thickness resection of the scar (28 (16%) patients), or completion surgery with resection of the draining lymph nodes (43 (25%) patients). In cases with a FRM > 1 mm, all patients had endoscopic follow-up according to the guideline [6].

In patients with a FRM between 0.1 and 1 mm who did not receive completion surgery, at least three surveillance endoscopies of the scar were performed in 57.7% of patients. The first surveillance endoscopy was performed after a median

► **Table 2** LIRC and metastasis.

	Local intramural residual cancer, % (95% CI)	Metastasis, % (95% CI)
Overall		
Margin 0.1–1 mm (n = 171)	2.9 (1.0–6.7)	5.8 (2.8–10.8)
Margin > 1 mm (n = 351)	0.6 (0.1–2.1)	1.1 (0.3–2.9)
P value	0.028	0.002
Subgroup margin 0.1–1 mm		
Morphology		
Non-pedunculated (n = 123)	4.1 (1.3–9.2)	8.1 (3.9–15.0)
Pedunculated (n = 48)	0	0
P value	0.158	0.042
Location		
Rectum (n = 54)	3.7 (0.4–13.4)	5.6 (1.1–16.2)
Colon (n = 117)	2.6 (0.5–7.5)	6.0 (2.4–12.3)
P value	0.682	0.912
Age		
< 70 years (n = 104)	2.9 (0.6–8.4)	7.7 (3.3–15.2)
≥ 70 years (n = 67)	3.0 (0.4–10.8)	3.0 (0.6–10.8)
P value	0.970	0.202
Resection technique		
En bloc (n = 152)	5.9 (0.1–32.8)	5.9 (0.2–32.8)
Piecemeal (n = 17)	2.6 (0.7–6.7)	5.3 (2.2–10.4)
P value	0.742	0.967

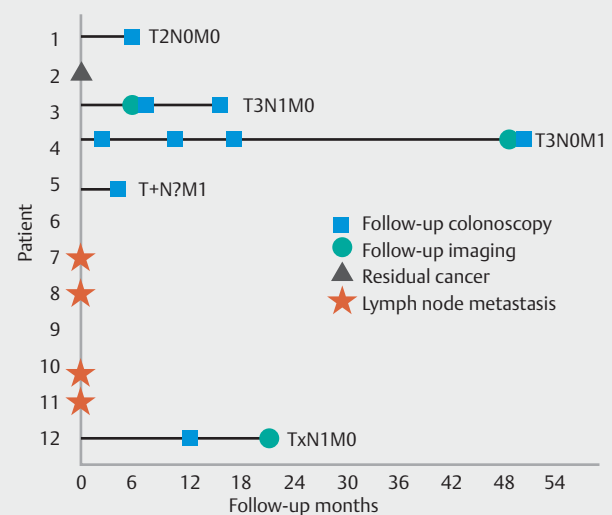
LIRC, local intramural residual cancer; N, number; CI, confidence interval.

duration of 3 months (IQR 3.0–5.0 months). Follow-up imaging of the abdomen and thorax was performed in 48.5% of patients with a follow-up strategy after local excision. Computed tomography scan and ultrasound were most frequently used for imaging of the abdomen and were performed in 27.8% and 25.4% of patients, respectively.

Oncological outcomes

Local residual intramural cancer

Of patients with a FRM between 0.1 and 1 mm, five with LIRC were identified, resulting in a risk of LIRC of 2.9% (95% CI 1.0–6.7%) (► **Table 2**). One patient who had full-thickness resection of the scar was found to have residual cancer in the resection specimen. Local recurrences were detected in four patients who had endoscopic follow-up. Recurrences were detected after a median duration of 10 months (IQR 3.25–41.5). Median duration between detection of recurrence and previous colonoscopy or end of treatment, in case follow-up colonoscopy had not been performed, was 4 months (IQR 2.5–7.5 months) (► **Fig. 2**). Subgroup analysis for non-pedunculated T1 CRCs



► **Fig. 2** Follow-up characteristics of patients with a free resection margin between 0.1 and 1 mm with LIRC or metastasis.

► **Table 3** Characteristics and histological review of patients with LIRC or metastasis.

Patient	Resection margin	Type of outcome	Time to recurrence (months)	Secondary treatment	Resection technique	Polyp size (mm)	Location primary CRC	Location distant recurrence	Tumor budding
1	0.1–1 mm	LR	4	ES	Pc-snare	15	Colon	–	Bd1
2	0.1–1 mm	LRC	–	SCR	B-ESD	30	Rectum	–	Bd2/3
3	0.1–1 mm	LRR	16	ES	B-snare	10	Rectum	–	Bd2/3
4	0.1–1 mm	LDR	50	ES	B-TEM	20	Rectum	Liver	Bd2/3
5	0.1–1 mm	LDR	3	ES	B-EMR	12	Colon	Subcutaneous tissue	Bd2/3
6	0.1–1 mm	LNM	–	SER	B-TEM	20	Rectum	–	Bd1
7	0.1–1 mm	LNM	–	SER	B-EMR	12	Colon	–	Bd1
8	0.1–1 mm	LNM	–	SER	B-EMR	15	Colon	–	Bd2/3
9	0.1–1 mm	LNM	–	SER	B-snare	15	Colon	–	Bd2/3
10	0.1–1 mm	LNM	–	SER	Pc-snare	40	Colon	–	Bd2/3
11	0.1–1 mm	LNM	–	SER	B-snare	20	Colon	–	Bd1
12	0.1–1 mm	LRR	21	SCR	B-snare	12	Rectum	–	Bd1
13	>1 mm	LR	38	ES	B-snare	25	Colon	–	–
14	>1 mm	LRR	3	ES	eFTR	15	Rectum	–	–
15	>1 mm	LDR	14	ES	TEM	5	Rectum	Liver and bone	–
16	>1 mm	DR	23	ES	TEM	120	Rectum	Bone	–
17	>1 mm	DR	25	ES	Pc-EMR	30	Colon	Liver and lung	–

LIRC, local intramural residual cancer; LRC, local residual cancer; LR, local recurrence; LRR, locoregional recurrence, recurrence in local tissue or lymph node; LDR, local and distant recurrence; DR, distant recurrence; LNM, lymph node metastasis at baseline; SCR, adjuvant scar resection; ES, endoscopic surveillance; SER, adjuvant segmental resection; B, en bloc resection; ESD, endoscopic submucosal dissection; Pc, piecemeal resection; TEM, transanal endoscopic microsurgery; EMR, endoscopic mucosal resection; CRC, colorectal cancer; NR, not revised; LVI, lymphovascular invasion; NA, not assessable.

showed LIRC in 4.1% (95% CI 1.3–9.2%) (► **Table 2**). Rectal lesions had LIRC (3.7%, 95% CI 0.4–13.4%) more often than colonic lesions (2.6%, 95% CI 0.5–7.5%), but this difference was not significant ($P=0.681$). No difference was found between patients <70 years and ≥ 70 years of age. Of patients with a FRM >1 mm, two with LIRC were identified (0.6%; 95% CI 0.1–2.1%) ($P=0.028$). Both were local recurrences during endoscopic follow-up after a negative follow-up endoscopy, 14 and 38 months after initial treatment.

Metastasis

Metastasis was observed in 10 patients with a FRM between 0.1 and 1 mm (5.8%, 95% CI 2.8–10.8%). Six of these patients with completion surgery had LNM at baseline. One patient who had endoscopic follow-up of the scar and developed a local recurrence had concomitant LNM. One patient who had full-thickness resection of the scar developed regional LNM after 21 months. In total, eight patients had LNM at the time of diagnosis or during follow-up (4.7%, 95% CI 2.0–9.2%). All patients were treated curatively. Distant metastasis occurred in two patients (1.2%, 95% CI 0.1–4.2%), both of whom had endoscopic follow-up and had concurrent LIRC at time of detection of metastasis. One patient with subcutaneous metastases could not

undergo curative resection. The other patient had a liver metastasis and was treated curatively. Subgroup analysis for non-pedunculated T1 CRCs showed a risk of metastasis of 9.1% (95% CI 3.9–15.0%). No difference in risk was seen between rectum and colon lesions. Patients <70 years of age developed metastasis more often (7.7%, 95% CI 3.3–15.2%) than patients ≥ 70 years of age (3.0% 95% CI 0.6–10.8%), but this difference was not significant ($P=0.200$). Of patients with a FRM >1 mm, metastasis was observed in four (1.1%; 95% CI 0.3–2.9%) ($P=0.002$). One patient had LNM during surveillance. Three patients had distant metastasis (liver, lung and bone) during surveillance, of which one had concomitant LIRC.

Characteristics of all patients who developed LIRC or metastasis are reported in ► **Table 3**. Patients with endoscopic follow-up of the scar after local resection of a T1 CRC with a FRM between 0.1 and 1 mm had a median follow-up of 33.0 months (IQR 20.8–46.3 months). Local recurrence was seen in four of 100 (4.0%, 95% CI 1.1–10.2%), of which two also developed distant metastasis (2.0%, 95% CI 0.2–7.2%). Of patients with endoscopic surveillance, 44 of 100 (44%) completed a minimum of 3 years follow-up. In this group, one patient developed a local recurrence with distant metastasis and risk of LIRC or metastasis was 2.3% (95% CI 0.1–12.0%). The risk did not differ

► **Table 4** Histological assessment of tumor budding in patients with a resection margin between 0.1 and 1 mm.

	LIRC (N=5)	Metastasis (N=10)	Control (N=148)
Bd1, n (%)	1 (20.0)	4 (40.0)	122 (82.4)
Bd2/3, n (%)	4 (80.0)	6 (60.0)	24 (16.2)
Unassessable, n (%)	–	–	2 (1.4)

LIRC, local intramural residual cancer; N, number.

significantly from the risks in all 100 patients with endoscopic follow-up of the scar.

Additional assessment of tumor budding

Results of the histological assessment of tumor budding in patients with a FRM between 0.1 and 1 mm are shown in ► **Table 4**. Specimens from 11 patients were not available for assessment due to missing H&E slides in the participating hospitals. In patients with LIRC, high-grade tumor budding was seen in 80.0% of cases versus 58.3% of patients with LIRC or metastasis. In patients without LIRC or metastasis high-grade tumor budding was seen in 16.2%. Accordingly, among the group with a FRM between 0.1 and 1 mm without tumor budding, LIRC was detected in one patient (0.8%; 95% CI 0.1–4.4%) and metastasis in four patients (3.1%; 95% CI 0.9–8.1%). These risks did not differ significantly from the risks in patients with a FRM > 1 mm ($P=0.790$ and $P=0.131$, respectively).

Discussion

To our knowledge, this is the largest study investigating the risk of LIRC and metastasis in 171 patients with local excision of T1 CRC and a FRM between 0.1 and 1 mm, in the absence of other histological risk factors (poor differentiation and LVI). We showed that the risk of LIRC was 2.9% (95% CI 1.0–6.7%) and the risk of metastasis was 5.8% (95% CI 2.8–10.8%). Additional histological assessment of tumor budding showed high-grade tumor budding in 80% of cases with LIRC. If tumor budding was graded low, the risk of LIRC decreased to 0.8% (95% CI 0.1–4.4%), which is comparable to that in patients with a FRM > 1 mm. Based on these findings, a FRM between 0.1 and 1 mm poses a low risk of LIRC, especially in the absence of high-grade tumor budding. Our results are in line with the low risk of LIRC in tumors with a FRM between 0.1 and 1 mm reported in previous smaller studies [10, 16–18].

In recent past decades, shared decision making has been implemented in oncology practice [27]. This is particularly applicable to T1 CRC, where rates of oncological adverse events (AEs) (LNM, LIRC) are close to the rates of surgical AEs (complications, mortality). To inform patients properly about the advantages and disadvantages of completion surgery, the risk of oncological AEs should be known. Definitions and percentages of “high-risk” and “low-risk” T1 CRC differ between guidelines and the “high-risk” status reflects an actual risk in a range from

0.7% to 30% [5, 6,28,29]. Preferably, actual percentages for specific situations should be taken into account and discussed with the patient. This study provides an important and well powered insight into the actual risk within this specific subgroup of patients.

Tumor budding has relatively recently drawn attention as a risk factor in T1 CRC and has not been incorporated into most guidelines yet [3, 5, 6, 25]. Although tumor budding has frequently been described as a risk factor for LNM in T1 CRC [3, 30], the association with LIRC in T1 CRCs has been studied less often [31–33]. In a meta-analysis by Rogers et al, high-grade (Bd2–3) tumor budding was associated with higher recurrences rates (OR 2.87, CI 1.12–7.35) in patients with T1/2 tumors [34]. It has been suggested that budding tumor cells have the capacity to invade and migrate through the surrounding stroma of the submucosa, possibly by a partial epithelial to mesenchymal transition [35]. Because tumor buds can be found at some distance from the invasive front, this could explain the strong association between LIRC and high-grade tumor budding (80%) in our study.

Therefore, it is not the FRM between 0.1 and 1 mm itself, but rather, the presence of high-grade tumor budding that seems to be related to LIRC. Our findings combined with previous studies suggest that if LVI, poor differentiation, and high-grade tumor budding are absent, the risk of LNM and LIRC is sufficiently low in T1 CRC with a FRM between 0.1 and 1 mm to justify an endoscopic follow-up strategy instead of performing completion surgery.

Some limitations of this study should be acknowledged. Although this was the largest study to date on this subject, the number of participants recruited (171 patients) was still limited. Inherent in the study’s retrospective design, confounding and unmeasured factors might have influenced the prevalence of the oncological outcomes. First, the relatively short duration and variation of follow-up may have resulted in under-detection of LIRC cases that are yet to develop. The median follow-up in our cohort was 33 months and the follow-up showed significant variation in follow-up strategies [36]. In a recent meta-analysis, 98% of all recurrent cases were identified within 6 years [29]. Subgroup analysis of patients with endoscopic surveillance of the scar who had completed at least 3 years of follow-up (44 cases [44%] median follow-up 48 months) demonstrates a similar risk of LIRC compared to all patients with endoscopic surveillance. Furthermore, surveillance colonoscopies and imaging were frequently performed in all except two patients that developed recurrent cancer. These patients did undergo a colonoscopy just a few months prior to the detection of recurrent cancer, which means the recurrences would not have been detected earlier if colonoscopies were performed more regularly. This is in line with previous reports showing that local recurrence can be preceded by negative colonoscopies [33]. This suggests that the impact of bias introduced due to the lack of a surveillance protocol might be small. Second, a resection margin between 0.1 and 1 mm might be related to deep submucosal invasion. It is clear that with increasing depth of invasion, the deep resection margin decreases. Therefore, it seems likely that a smaller deep resection margin may be a

proxy for Sm2 submucosal invasion. However, it has been observed that the actual risk of LNM with >1000 µm of submucosal invasion is only 1.5% to 2.5% [30, 37–42] in the absence of LVI, poor differentiation, and high-grade tumor budding. Although evidence within the current literature is limited, an association between deep submucosal invasion and LIRC has not been proven. Given the missing data on invasion depth, we were not able to study this relationship in our cohort. However, our study shows that although the cohort may include some cases with >1000 µm submucosal invasion, the risk will be low, and more important, rather related to tumor budding. Third, the histological evaluation of the local excision scar in the specimen from completion surgery might have been performed less thoroughly than evaluation of the scar in the specimen of a full-thickness scar resection, as histological findings have less consequences for treatment in completion surgery. Fourth, histological reassessment by an expert pathologist was not performed in this study. Because expert histopathologic reassessment of T1 CRCs is not routinely performed in daily clinical practice, we believe that reassessment would limit generalizability of our results. Last, tumor budding was not assessed in patients with a FRM >1 mm. However, the impact of performing this assessment in this group would be negligible because the number of patients with LIRC is very low.

Conclusions

In conclusion, we have shown that a FRM between 0.1 and 1 mm of a locally excised T1 CRC without LVI, poor differentiation, and high-grade tumor budding is associated with a low risk of LIRC and metastasis, and is comparable to a FRM >1 mm. Our findings suggest that it might be safe to perform endoscopic follow-up and refrain from completion surgery in these patients.

Acknowledgments

This work was supported by a grant from the Dutch Digestive Diseases Foundation (reference MG/2015–040) and the Boks Scholten Foundation.

Competing interests

Dr. Moons is consultant for Boston Scientific.

Funding

Boks Scholten Foundation
Maag Lever Darm Stichting MG/2015-040

References

- [1] Vermeer NCA, Backes Y, Snijders HS et al. National cohort study on postoperative risks after surgery for submucosal invasive colorectal cancer. *BJS Open* 2019; 3: 210–217
- [2] de Neree Tot Babberich MPM, Vermeer NCA, Wouters M et al. Post-operative Outcomes of Screen-Detected vs Non-Screen-Detected Colorectal Cancer in the Netherlands. *JAMA Surg* 2018; 153: e183567
- [3] Bosch SL, Teerenstra S, de Wilt JH et al. Predicting lymph node metastasis in pT1 colorectal cancer: a systematic review of risk factors providing rationale for therapy decisions. *Endoscopy* 2013; 45: 827–834
- [4] Di Gregorio C, Bonetti LR, de Gaetani C et al. Clinical outcome of low- and high-risk malignant colorectal polyps: results of a population-based study and meta-analysis of the available literature. *Intern Emerg Med* 2014; 9: 151–160
- [5] Ferlitsch M, Moss A, Hassan C et al. Colorectal polypectomy and endoscopic mucosal resection (EMR): European Society of Gastrointestinal Endoscopy (ESGE) Clinical Guideline. *Endoscopy* 2017; 49: 270–297
- [6] Dutch Working Group for Gastrointestinal Tumors. Dutch Colorectal Cancer Guideline 2014. <http://www.oncoline.nl/colorectaalcarcinoom>
- [7] Hashiguchi Y, Muro K, Saito Y et al. Japanese Society for Cancer of the Colon and Rectum (JSCCR) guidelines 2019 for the treatment of colorectal cancer. *Int J Clin Oncol* 2020; 25: 1–42
- [8] Shaikat A, Kaltenbach T, Dominitz JA et al. Endoscopic recognition and management strategies for malignant colorectal polyps: Recommendations of the US Multi-Society Task Force on Colorectal Cancer. *Am J Gastroenterol* 2020; 115: 1751–1767
- [9] Seitz U, Bohnacker S, Seewald S et al. Is endoscopic polypectomy an adequate therapy for malignant colorectal adenomas? Presentation of 114 patients and review of the literature *Dis Colon Rectum* 2004; 47: 1789–1796
- [10] Naqvi S, Burroughs S, Chave HS et al. Management of colorectal polyp cancers. *Ann R Coll Surg Engl* 2012; 94: 574–578
- [11] Williams JG, Pullan RD, Hill J et al. Management of the malignant colorectal polyp: ACPGBI position statement. *Colorectal Dis* 2013; 15: (Suppl. 02): 1–38
- [12] Butte JM, Tang P, Gonen M et al. Rate of residual disease after complete endoscopic resection of malignant colonic polyp. *Dis Colon Rectum* 2012; 55: 122–127
- [13] Cunningham KN, Mills LR, Schuman BM et al. Long-term prognosis of well-differentiated adenocarcinoma in endoscopically removed colorectal adenomas. *Dig Dis Sci* 1994; 39: 2034–2037
- [14] Benizri El, Bereder JM, Rahili A et al. Additional colectomy after colonoscopic polypectomy for T1 colon cancer: a fine balance between oncologic benefit and operative risk. *Int J Colorectal Dis* 2012; 27: 1473–1478
- [15] Junginger T, Goenner U, Hitzler M et al. Analysis of local recurrences after transanal endoscopic microsurgery for low risk rectal carcinoma. *Int J Colorectal Dis* 2017; 32: 265–271
- [16] Ueno H, Mochizuki H, Hashiguchi Y et al. Risk factors for an adverse outcome in early invasive colorectal carcinoma. *Gastroenterology* 2004; 127: 385–394
- [17] Berg KB, Telford JJ, Gentile L et al. Re-examining the 1-mm margin and submucosal depth of invasion: a review of 216 malignant colorectal polyps. *Virchows Arch* 2020; 476: 863–870
- [18] Gijsbers KM, Post Z, Schrauwen RWM et al. Low value of second-look endoscopy for detecting residual colorectal cancer after endoscopic removal. *Gastrointest Endosc* 2020; 92: 166–172
- [19] PLOS Medicine Editors. Observational studies: Getting clear about transparency. *PLoS Med* 2014; 11: e1001711
- [20] Reid BC, Alberg AJ, Klassen AC et al. The American Society of Anesthesiologists' class as a comorbidity index in a cohort of head and neck cancer surgical patients. *Head Neck* 2001; 23: 985–994
- [21] Stichting Pathologisch-Anatomisch Landelijk Geautomatiseerd Archief. Handleiding Protocol Colonrectum. 2019

- [22] Kuellmer A, Mueller J, Caca K et al. Endoscopic full-thickness resection for early colorectal cancer. *Gastrointest Endosc* 2019; 89: 1180–1189
- [23] Zwager LW, Bastiaansen BA, Bronzwaer MES et al. Endoscopic full-thickness resection (eFTR) of colorectal lesions: results from the Dutch colorectal eFTR registry. *Endoscopy* 2020; 52: 1014–1023
- [24] de Jong GM, Hugen N. Minimally invasive transanal surgery is safe after incomplete polypectomy of low risk T1 rectal cancer: a systematic review. *Colorectal Dis* 2019; 21: 1112–1119
- [25] Lugli A, Kirsch R, Ajioka Y et al. Recommendations for reporting tumor budding in colorectal cancer based on the International Tumor Budding Consensus Conference (ITBCC) 2016. *Mod Pathol* 2017; 30: 1299–1311
- [26] Rubin DB. Inference and missing data. *Biometrika* 1976; 63: 581–592
- [27] Covvey JR, Kamal KM, Gorse EE et al. Barriers and facilitators to shared decision-making in oncology: a systematic review of the literature. *Support Care Cancer* 2019; 27: 1613–1637
- [28] Fisher DA, Shergill AK. ASGE Standards and Practice Committee. et al. Role of endoscopy in the staging and management of colorectal cancer. *Gastrointest Endosc* 2013; 78: 8–12
- [29] Dang H, Dekkers N, le Cessie S et al. Risk and time pattern of recurrences after local endoscopic resection of T1 colorectal cancer: a meta-analysis. *Clin Gastroenterol Hepatol* 2022; 20: e298–e314 doi:10.1016/j.cgh.2020.11.032
- [30] Yasue C, Chino A, Takamatsu M et al. Pathological risk factors and predictive endoscopic factors for lymph node metastasis of T1 colorectal cancer: a single-center study of 846 lesions. *J Gastroenterol* 2019; 54: 708–717
- [31] Nam MJ, Han KS, Kim BC et al. Long-term outcomes of locally or radically resected T1 colorectal cancer. *Colorectal Dis* 2016; 18: 852–860
- [32] Tamaru Y, Oka S, Tanaka S et al. Long-term outcomes after treatment for T1 colorectal carcinoma: a multicenter retrospective cohort study of Hiroshima GI Endoscopy Research Group. *J Gastroenterol* 2017; 52: 1169–1179
- [33] Backes Y, de Vos Tot Nederveen Cappel WH, van Bergeijk J et al. Risk for incomplete resection after macroscopic radical endoscopic resection of T1 Colorectal Cancer: A multicenter cohort study. *Am J Gastroenterol* 2017; 112: 785–796
- [34] Rogers AC, Winter DC, Heeney A et al. Systematic review and meta-analysis of the impact of tumor budding in colorectal cancer. *Br J Cancer* 2016; 115: 831–840
- [35] Lugli A, Zlobec I, Berger MD et al. Tumor budding in solid cancers. *Nat Rev Clin Oncol* 2020; 18: 101–115
- [36] Gijsbers K, de Graaf W, Moons LMG et al. High practice variation in risk stratification, baseline oncological staging, and follow-up strategies for T1 colorectal cancers in the Netherlands. *Endosc Int Open* 2020; 8: E1117–E1122
- [37] Suh JH, Han KS, Kim BC et al. Predictors for lymph node metastasis in T1 colorectal cancer. *Endoscopy* 2012; 44: 590–595
- [38] Kim B, Kim EH, Park SJ et al. The risk of lymph node metastasis makes it unsafe to expand the conventional indications for endoscopic treatment of T1 colorectal cancer: A retrospective study of 428 patients. *Medicine* 2016; 95: e4373
- [39] Nakadoi K, Tanaka S, Kanao H et al. Management of T1 colorectal carcinoma with special reference to criteria for curative endoscopic resection. *J Gastroenterol Hepatol* 2012; 27: 1057–1062
- [40] Shin JW, Han KS, Hyun JH et al. Risk of recurrence after endoscopic resection of early colorectal cancer with positive margins. *Endoscopy* 2018; 50: 241–247
- [41] Ha RK, Han KS, Sohn DK et al. Histopathologic risk factors for lymph node metastasis in patients with T1 colorectal cancer. *Ann Surg Treat Res* 2017; 93: 266–271
- [42] Ronnow CF, Arthursson V, Toth E et al. Lymphovascular infiltration, not depth of invasion, is the critical risk factor of metastases in early colorectal cancer: retrospective population-based cohort study on prospectively collected data, including validation. *Ann Surg* 2020; doi:10.1097/SLA.0000000000003854