

Preclinical Feasibility and Patency Analyses of a New Distal Coronary Connector: The ELANA Heart Bypass

Innovations
2021, Vol. 16(2) 163–168
© The Author(s) 2021



Article reuse guidelines:
sagepub.com/journals-permissions
DOI: 10.1177/1556984521991519
journals.sagepub.com/home/inv



David Stecher^{1*}, MD, PhD, Marieke Hoogewerf^{2,3*}, MD, Glenn Bronkers³, BSc, Bart P. van Putte^{4,5}, MD, PhD, Pieter A. Doevendans^{2,6}, MD, PhD, Cornelis A.F. Tulleken^{3,7}, MD, PhD, Lex van Herwerden¹, MD, PhD, Gerard Pasterkamp⁸, MD, PhD, and Marc P. Buijsrogge¹, MD, PhD

Abstract

Objective: This preclinical study determines the feasibility and 6-month patency rates of a new distal coronary connector, the Excimer Laser Assisted Nonocclusive Anastomosis (ELANA) Heart Bypass. **Methods:** Twenty Dutch Landrace pigs received either a hand-sewn ($n = 8$) or an ELANA ($n = 12$) left internal thoracic artery to left anterior descending artery anastomosis, using off-pump coronary artery bypass grafting. Six-month patency rates were demonstrated by coronary angiography and histological evaluation. Throughout, procedural details and complication rates were collected. **Results:** The ELANA Heart Bypass demonstrated 0% mortality and complication rates during follow-up. It was demonstrated feasible, with comparable perioperative flow measurements (ELANA vs hand-sewn, median [min to max], 24 [14 to 28] vs 17 [12 to 31] mL/min; $P = 0.601$) and fast construction times (3 [3 to 7] vs 31 [26 to 37] min; $P < 0.001$). Yet, an extra hemostatic stitch was needed in 25% of the ELANA versus 12.5% of the hand-sewn anastomoses. The 6-month patency rate of the ELANA Heart Bypass was 83.3% versus 100% in hand-sewn anastomoses. The 2 occluded ELANA-anastomoses were defined model-based errors. **Conclusions:** The ELANA Heart Bypass facilitates a sutureless distal coronary anastomosis. A design change is suggested to improve hemostasis and will be evaluated in future translational studies. This new technique is a potential alternative to hand-sewn anastomoses in (minimally invasive) coronary surgery.

Central Message

The presented ELANA Heart Bypass is a novel sutureless anastomotic technique for CABG. With sutureless techniques easing and standardizing the distal anastomotic construction, we aim to facilitate routine minimally invasive CABG.

Keywords

coronary artery bypass grafting, sutureless anastomosis, coronary revascularization, coronary connector, OPCAB

Introduction

Coronary artery bypass grafting (CABG) is considered an invasive procedure. Currently the 30-day mortality is estimated at 1% to 2%, and the most disabling morbidity (among others: stroke, mediastinitis, and reoperation for bleeding) is reported in up to 7% of cases, all initiating at least prolonged hospital admission.^{1–3} In contrast, minimally invasive approaches are characterized by less tissue trauma and therefore tend to shorten hospital admission and improve quality of life. Mainly by reduced need for blood transfusion, less respiratory complications, and no mediastinitis in sternalsparing approaches.^{4,5} However, these approaches are technically demanding and therefore not routinely applied.

To facilitate routine minimally invasive CABG we developed a sutureless distal anastomotic technique, the Excimer Laser Assisted Nonocclusive Anastomosis (ELANA) Heart Bypass. Following successful testing on large caliber arteries (3.0 mm outer diameter [OD]), this new downsized connector enables a standardized distal anastomosis (1.6 to 1.9 mm OD) for off-pump CABG (OPCAB).^{6–8} Our previous studies demonstrated the feasibility of the ELANA

Corresponding Author:

Marieke Hoogewerf, Department of Cardiology, University Medical Center Utrecht & AMT Medical Research B.V. Yalelaan 52, 3584 CM Utrecht, The Netherlands.
Email: m.hoogewerf.mh@gmail.com

Heart Bypass in OPCAB and minimally invasive direct CABG models.^{9,10} However, follow-up data comparing the ELANA Heart Bypass to the hand-sewn, have not been provided yet. Therefore, we aim to compare 6-month outcomes of ELANA Heart Bypass and hand-sewn anastomoses in a porcine OPCAB model.

Methods

Study Design and Animals

In this translational follow-up trial, 20 left internal thoracic artery to left anterior descending artery (LITA-to-LAD) anastomoses were constructed during OPCAB surgery in 20 pigs (Dutch Landrace, female, 69 ± 6 KG). Pigs were assigned for a hand-sewn ($n = 8$) or an ELANA anastomosis ($n = 12$).

All pigs were followed for a period of 6 months. Perioperatively, transit time flow measurements (TTFM) were performed and perioperative parameters were collected; including procedure time, complications, and mortality. Hyperemic flow was determined following 30 seconds of LITA-graft occlusion. The peak hyperemic flow response (i.e., the anastomotic flow reserve) was calculated by dividing the mean peak graft flow by the mean baseline graft flow.¹⁰ At 6 months, patency was determined using coronary angiography (CAG), which was graded by 2 independent observers according to the FitzGibbon criteria.¹¹ We defined FitzGibbon class A (unimpaired runoff) as patent and FitzGibbon class B (>50% stenosis) and O (occlusion) as non-patent. Ultimately, histological evaluation was performed as described in the histology section below.

The pigs received humane care in compliance with the “Guide for the Care and Use of Laboratory Animals” (prepared by the Institute of Laboratory Animal Resources, National Research Council, revised 2011) and were fed only the minimally required nutrients to prevent extensive growth. The study was approved by the animal experimentation committee (2013.II.08.094).

ELANA Heart Bypass Technique

Figure 1 depicts the ELANA Heart Bypass technique and a Supplemental Video is available.¹⁰ All anastomoses were created with the Trinity-V2-Clip, a prototype of the current ELANA Heart Clip (AMT Medical B.V., Utrecht, The Netherlands).

After dissecting the LITA, the LITA-to-LAD anastomosis was constructed. First, the upper fork of the ELANA Heart Clip was inserted into the lumen of the LITA, at least 3 cm from the distal end. Secondly, with the LITA temporary occluded, the ELANA

Heart Catheter (AMT Medical B.V., Utrecht, The Netherlands) was introduced into the ELANA Heart Clip via the LITA's distal end, and laser-punched an opening into the LITA-wall. Thirdly, compression of the LITA to the LAD was effectuated by inserting the ELANA Heart Clip's lower fork into the lumen of the unopened and perfused LAD, where after the ELANA Heart Clip was closed. Finally, the anastomosis was finalized by laser-punching the LAD wall and subsequent ligation of the LITA's distal end.

Hand-Sewn Technique

The hand-sewn anastomoses were constructed using a 0-degree, end-to-side, running suture (8-0 Prolene, Ethicon Inc, Somerville, NJ), with use of an intracoronary shunt (Medtronic Inc., Minneapolis, MN).

Surgery

All procedures were performed by a single surgeon (DS). After a partial sternotomy, the LITA was harvested, and the target LAD (1.6 to 1.9 mm OD) was immobilized using the Octopus Evolution AS Tissue Stabilizer (Medtronic Inc, Minneapolis, MN). The LITA-to-LAD anastomosis was constructed using either the ELANA Heart Bypass or was hand-sewn, as described in the previous section. After anastomotic construction, competitive flow was prevented by complete ligation of the proximal LAD about 1 cm upstream, using hemoclips.

Medication

From 3 days prior to the OPCAB procedure until the end of follow-up, all pigs received Acetylsalicylic acid (320 mg) and Clopidogrel (75 mg) orally on a daily base. During the procedure, partial heparinization (>2.5 × baseline activated clotting time [ACT]) was induced. The same anesthetic protocol was used as in our previous publications.^{8,10}

At the end of follow-up, euthanasia was performed. After complete heparinization, Pentobarbital sodium (200 mg/kg) IV was administered, followed by exsanguination.

Coronary Angiography

CAG (Philips Allura Xper FD20, Eindhoven, The Netherlands) was performed before euthanasia via the femoral artery. The internal mammary catheter (6 Fr) was introduced in the proximal LITA. At least 2 directions were recorded.

¹Department of Cardiothoracic Surgery, University Medical Center Utrecht, The Netherlands

²Department of Cardiology, University Medical Center Utrecht, The Netherlands

³AMT Medical Research B.V., Utrecht, The Netherlands

⁴Department of Cardiothoracic Surgery, St. Antonius Hospital, Nieuwegein, The Netherlands

⁵Department of Cardiothoracic Surgery, Amsterdam University Medical Center, The Netherlands

⁶Netherlands Heart Institute, Utrecht, The Netherlands

⁷Department of Neurosurgery, University Medical Center Utrecht, The Netherlands

⁸Department of Experimental Cardiology, University Medical Center Utrecht, The Netherlands

*The authors David Stecher and Marieke Hoogewerf contributed equally to the work.

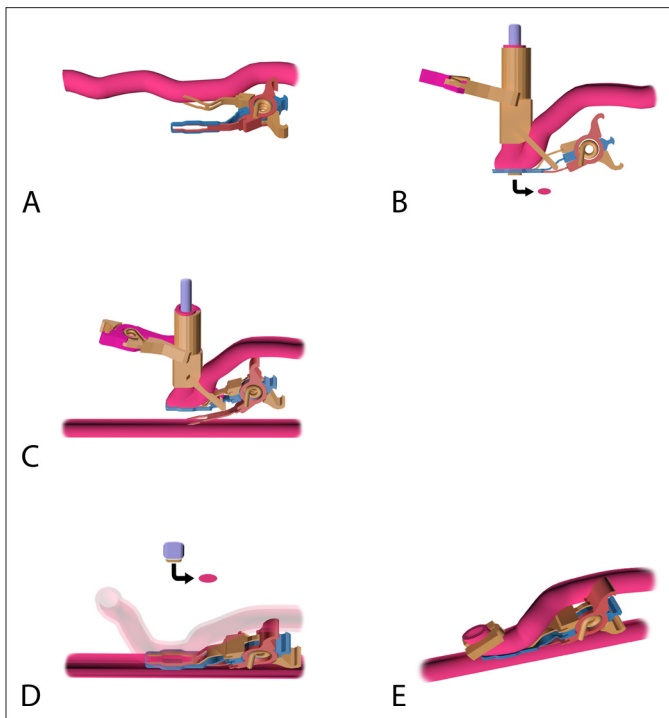


Fig. 1. The coronary anastomotic procedure with the ELANA Heart Bypass. (a) Mounting of the ELANA Heart Clip (Trinity-V2-Prototype): an applicator (not shown) is used to insert the upper fork of the ELANA Heart Clip into the lumen of the perfused graft, directed distally. By releasing the applicator, the ELANA Heart Clip closes and actively compresses the graft between the 2 forks and the extravascular band. (b) The mounted and laser-punched graft. The ELANA Heart Laser Catheter is introduced intraluminally, through the distal free end of the graft, into the ELANA Heart Clip, and is perpendicularly fixed by the external ELANA Fixation Device. The graft is laser-punched. Directly below the ELANA Heart Clip, the laser-punched fragment of the graft (i.e., “flap”) is projected (arrow). (c) Nonocclusive connection of the graft to the coronary: an applicator (not shown) is used to insert the lower fork. The fork punctures the coronary wall and is inserted into the lumen of the perfused coronary, directed distally. During the insertion, the upper fork maintains compression of the graft onto the extravascular band, ensuring proper fixation of the graft during this maneuver, while the ELANA Fixation Device ensures proper perpendicular positioning of the ELANA Heart Laser Catheter. (d) Laser-punched arteriotomy of the coronary artery. The ELANA Heart Clip is closed and compresses both vessel walls (i.e., graft and coronary artery) between the 2 intraluminal forks and the extravascular band. The coronary wall is laser-punched by the fixed ELANA Heart Laser Catheter, perpendicularly positioned onto the coronary artery wall. Subsequently, the ELANA Fixation Device is removed and the ELANA Heart Laser Catheter is retracted, including the retrieved flap (due to vacuum suction via the ELANA Heart Laser Catheter; arrow). (e) Final anastomosis: a ligating hemoclip is placed at the distal end of the graft. NB. The ELANA Heart Clip stays in situ and is not removed after anastomotic construction. Reprinted with permission from Stecher et al. *J Vis Exp* 2014; 93: e52127.¹⁰

Histological Evaluation

Directly after euthanasia, the heart was en-bloc excised and perfused with 4% Formalin at 80 mmHg for 120 min. After overnight

fixation, the hand-sewn anastomoses were embedded in Paraffin (sectioned at 3 to 10 μm transverse coupes) whilst the ELANA anastomoses were embedded in Methyl methacrylate (sectioned at 350 μm transverse coupes). All coupes were hematoxylin and eosin stained. The anastomotic dimensions and the amount of intimal hyperplasia were assessed using AnalySis (Soft-Imaging Software GmbH, Münster, Germany).

Statistical Analyses

Data were managed in Excel 2010 (Microsoft, Redmond, WA, USA) and analyzed in SPSS Statistics, Version 25.0 (IBM Corp., Armonk, NY, USA). Outcomes will be presented as median (minimum to maximum) or as stated. For all peri- and postoperative parameters, descriptive statistics were presented and compared between the 2 groups. This comparison was performed using Fisher’s exact tests for dichotomous, and Student’s *t*-tests or Mann-Whitney tests for respectively parametric and nonparametric continuous variables. The 6-month patency rates were compared between the 2 groups, using Fisher’s exact tests. Throughout, $P < 0.05$ was considered significant.

Results

Perioperative Results

Table 1 shows the porcine model characteristics. In both groups, no mortality occurred. One pig was excluded and replaced following a ruptured arteriotomy during intracoronary shunt-placement in the hand-sewn group.

It was demonstrated that the construction time of the ELANA Heart Bypass was faster than the hand-sewn anastomoses (3 [3 to 7] vs 31 [26 to 37] min; $P < 0.001$). An extra hemostatic stitch was required to achieve complete hemostasis in 3 of 12 ELANA versus 1 of 8 hand-sewn anastomoses ($P = 0.619$). Complementary, 3 connector-facilitated anastomoses needed a second attempt, due to a laser-punch failure. During the second attempt, with use of a new laser catheter and distal to the initial target, the flap of coronary wall tissue was successfully retrieved. The bleeding from the coronary puncture site (i.e., the introduction site of the lower fork) was self-limiting and the partially lasered arteriotomy was closed using Prolene 8-0 suture.

Intraoperative TTFM, presented comparable flow (ELANA vs hand-sewn, 24 [14 to 28] vs 17 [12 to 31] mL/min) and pulsatility index (2.1 [1.4 to 6.0] vs 2.5 [1.6 to 6.8]; Table 1).

Follow-Up

Six-month mortality rate was 0% and no complications occurred. During this follow-up period, a significant increase in porcine weight was observed (ELANA vs hand-sewn in mean \pm SD, 38 \pm 12 vs 48 \pm 18 kg; $P = 0.142$).

Table 1. Porcine Model and Perioperative Characteristics.

	Connector (n = 12)	Hand-sewn (n = 8)	P-value
Porcine model characteristics			
Bodyweight at procedure (kg)	69 (56-80)	71 (63-79)	0.985
Bodyweight at end of follow-up (kg)	107 (84-124)	120 (111-124)	0.072
LAD (OD, mm)	1.8 (1.6-2.0)	1.8 (1.6-2.0)	0.908
LITA (OD, mm)	2.7 (2.2-3.3)	3.0 (2.8-3.1)	0.089
Perioperative characteristics			
Construction time (min)	3 (3-7)	31 (26-37)	<0.001
Flap retrieval rate	9 (75)	—	—
Complete hemostasis	9 (75)	7 (88)	0.619
Graft flow, T = 10 min (mL/min)	24 (14-28)	17 (12-31)	0.601
Pulsatility index, T = 10 min	2.1 (1.4-6.0)	2.5 (1.6-6.8)	0.371
Graft flow, T = 60 min (mL/min)	20 (17-29)	20 (11-32)	0.894
Pulsatility index, T = 60 min	3.2 (1.4-4.7)	2.1 (1.9-6.9)	0.820
Peak hyperemic flow response (mL/min)	86 (66-136)	57 (46-75)	0.157
Hyperemic flow ratio	5 (3-5)	4 (3-6)	0.413

Abbreviations: LAD, left anterior descending artery; LITA, left internal thoracic artery; OD, outer diameter.

Flap retrieval rate excludes the redo-anastomoses; using a new laser catheter and fixation device, all 3 redo-anastomoses were successful. Hyperemic flow ratio = peak hyperemic flow/baseline graft flow. Values presented as n (%) or median (minimum-maximum).

Patency

All of the hand-sewn and the vast majority of the ELANA anastomoses were patent (FitzGibbon grade A) at 6-month follow-up (100% vs 83.3%; $P = 0.495$). Figure 2 and the Supplemental Video demonstrate the connector facilitated anastomosis per CAG. There were 2 non-patent anastomoses in the ELANA-group. The first showed competitive LAD-flow

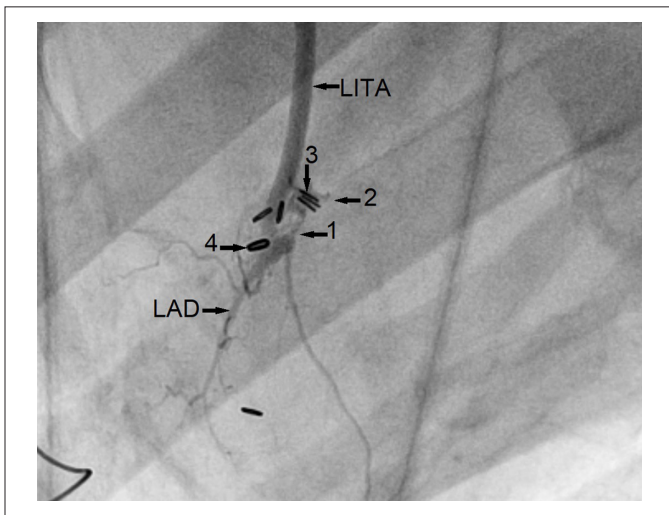


Fig. 2. Coronary angiogram of a connector-facilitated LITA-to-LAD anastomosis at 6-month follow-up. A side-view depicts the connector forks and anastomotic surface (1), the spring of the connector (2), the hemoclips placed for proximal LAD ligation (3), and the hemoclip placed at the distal end of the LITA (4). LAD, left anterior descending artery; LITA, left internal thoracic artery.

due to a non-occlusive LAD-ligation; the anastomosis was defined as FitzGibbon grade O. The second was defined as FitzGibbon grade B. Remarkable in this case is that the LITA was dissected over its complete length. In both cases initial intraoperative flow rates were adequate (25 mL/min, PI 1.8 and 24 mL/min, PI 2.5, respectively).

Histological Analyses

The histological evaluation showed all anastomoses to be remodeled and fully covered by neointima at the end of the 6-month follow-up. The maximum amount of intimal hyperplasia, measured mid-anastomosis (the anastomotic joining line), was significantly less in the ELANA than in the hand-sewn anastomoses (121 [67 to 245] vs 353 [192 to 685] μm ; $P = 0.001$). While this was the case, the mid-anastomotic width was significantly smaller in the ELANA than in the hand-sewn anastomoses (706 [506 to 839] vs 1,598 [949 to 2,120] μm ; $P < 0.001$). An example of these measurements is presented in Figure 3.

No (pseudo)aneurysm formation, no medial necrosis at the compression surface, and no excessive acute or long-term inflammation was demonstrated at 6 months, for both groups. The spring of the ELANA Heart Clip was completely encapsulated in connective tissue and incorporated in between the LITA and LAD. In addition, no erosion damage was seen.

Discussion

Our study presents feasibility of the ELANA Heart Bypass technique in its preclinical phase. This was demonstrated by sufficient

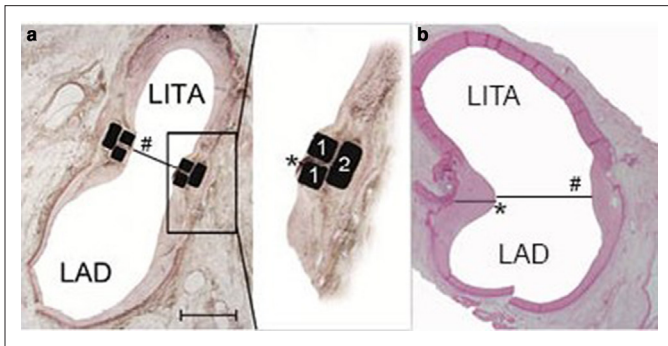


Fig. 3. Histological transverse sections of the connector-facilitated (a) and hand-sewn (b) LITA-to-LAD anastomosis at 6-month follow-up. Transverse sections, midanastomosis, H&E stained. Scale bar indicates 1 mm. (a) Presenting the upper and lower fork (1), extravascular band (2), mid-anastomotic width (#), and maximum amount of intima hyperplasia (*). (b) Presenting the mid-anastomotic width (#), and the maximum amount of intima hyperplasia (*). The Prolene is not in situ due to the sectioning of Paraffin embedded tissue. The interruption of the inferior coronary wall was caused by longitudinally opening of the coronary for inspection before embedment. H&E, hematoxylin and eosin stain; LAD, left anterior descending artery; LITA, left internal thoracic artery.

perioperative graft flow measurements and shorter construction times than the hand-sewn procedures. No mortality and complications were found during follow-up. Both CAG and histological examination indicate a 6-month patency rate of 83.3% for the ELANA-facilitated anastomoses. Two (16.7%) ELANA anastomoses were non-patent at the end of follow-up. Since one case showed competitive LAD flow and the other showed a LITA-dissection, the origin of the graft-failures seems model-based. We do emphasize that we did not find construction errors within the anastomotic area itself.

Notwithstanding the above presented feasibility, extra hemostatic stitches were required in 3 (25%) of the ELANA cases. All 3 were patent at 6-month follow-up. We hypothesize that the leakage resulted from an insufficient compression force of the prototype ELANA Heart Clip; both vessel walls need to be compressed between the extravascular band and intraluminal forks to enable complete hemostasis. Lack of this compression, due to the observed abundant tolerance in the spring of the ELANA Heart Clip (specifically the Trinity-V2-Prototype), could be solved by improving the spring, resulting in a standardized compression force and optimized hemostasis.

Equally important to discuss is the fact that 3 (25%) of the ELANA cases required a second attempt due to ineffective flap retrieval after laser-punching. We determined these specific cases to be a result of device malfunctioning and state these malfunctions to be related to the use and re-use of non-serial produced prototype devices for the current study. That aside, the ELANA Heart Bypass provides a bail out in case of ineffective flap retrieval. It is possible to retract the connector from the coronary artery and to re-insert it just distal to the original coronary target site. Since the connector and laser catheter remain fixed in the graft, it can immediately be

re-used. In all 3 cases, the second attempt was successful, using a new laser catheter, and all were patent at 6-month follow-up.

Histological analyses showed the mid-anastomotic width in the ELANA to be significantly smaller than the hand-sewn anastomosis. Whereas the hand-sewn anastomosis is able to remodel and resize to coronary growth in the porcine model, and in humans to LITA-growth, the ELANA connector is less flexible due to the fixed titanium parts. Yet, despite the anastomotic rigidity and moreover the physiologically growth of the coronaries of the pig, no lumen-narrowing intimal hyperplasia but streamlining neointimal coverage of the ELANA connector was demonstrated, in line with previous published data.⁸ Moreover, the 2 graft failures seen in this study seem related to model-based errors and not caused by the potential relative under sizing of the connector to the target coronary artery.

Evaluating Study Design

The use of prototype devices and the translational study design inevitably leads to limitations. Therefore, the results of this study should be interpreted carefully. It is briefly outlined that the devices used were prototypes and that the pigs gained significant weight during the 6-month follow-up. Since young animals grow, one could also expect coronary growth, eventually leading to a relative stenosis due to the fixed size of the connector. Additionally, it should be noted that the operating surgeon was an inexperienced cardiovascular surgery resident and that the statistical power of this study is limited due to financial and logistical reasons.

Implication of Connector-Facilitated Anastomoses

The traditional interpretation is that connector techniques could facilitate OPCAB, and eventually minimally invasive approaches, by simplification of the anastomotic technique and standardization of the quality of the anastomosis. This simplification results through their sutureless application. Promising clinical results were mainly presented with use of the C-port device.¹²⁻¹⁷

The major innovations of the ELANA Heart Bypass over the clinically applied techniques are the complete nonocclusive and sutureless application and the standardized arteriotomy. Nonocclusive application (i.e., with zero ischemia) results from vessel connection prior to coronary arteriotomy and renders eventual shunting or snaring superfluous. The arteriotomy itself is standardized due to use of the laser catheter, creating a standard oval opening in both the graft and coronary artery. Moreover, the connector is applicable to small sized coronary arteries (1.4 to 1.6 mm inner diameter).

Future Directions

Based on the results of this study, we aim to improve the anastomotic quality by standardization of device production and by increasing the compression force of the connector. We expect these changes to enable full hemostasis with a preserved patency. Based on these hypotheses the adjusted connector design will be

investigated in a new translational study by evaluation of hemostasis, tissue healing response, and patency.

Conclusions

This translational trial indicates feasibility of the ELANA Heart Bypass. Yet, the currently evaluated prototype should be improved to enable direct hemostasis and maintain full patency.

Author Note

Dr Marc P. Buijsrogge passed away unexpectedly in 2020. Approval from his estate was given for his authorship.

Acknowledgments

We acknowledge the constructive contributions of Martijn van Nieuwburg, Evelyn Velema, Grace Croft, Joyce Visser, Marlijn Jansen, Cees Verlaan, and colleagues from the Utrecht University Central Animal Facilities for their support and care for the animals and experiments; Noortje van den Dungen, Arjen Schoneveld, and Petra van der Kraak for their support for processing the samples for histology; and Niklank Noest, Rik Mansvelt Beck, Sander van Thoor, and other colleagues of Corvasco Medical and ELANA B.V., and the Brain Technology Institute, for their technical support.

Declaration of Conflicting Interests

The author(s) declared the following potential conflicts of interest with respect to the research, authorship, and/or publication of this article: This research was financially supported by the University Medical Center Utrecht and Corvasco Medical B.V. (the former company developing the ELANA Heart Bypass). David Stecher, Glenn Bronkers, and Cornelis A.F. Tulleken are registered as co-inventors of patents regarding the ELANA technique, without financial benefits. Cornelis A.F. Tulleken is founder of the ELANA technique. Marieke Hoogewerf and Glenn Bronkers are currently employed by AMT Medical Research B.V. All authors declare no competing financial interests and have nothing to disclose with regard to commercial support. The authors have performed a free and independent evaluation of this new technology and had full control of the design of the study, methods used, outcome parameters, analysis of data, and production of the written report.

Funding

The author(s) disclosed receipt of the following financial support for the research, authorship, and/or publication of this article: This work was supported by the EuroTransBio grant (ETB110014).

Supplemental Material

Supplemental material for this article is available online.

References

1. Head SJ, Börgermann J, Osnabrugge RLJ, et al. Coronary artery bypass grafting: part 2—optimizing outcomes and future prospects. *Eur Heart J* 2013; 34: 2873–2886.
2. Locker C, Schaff HV, Daly RC, et al. Multiarterial grafts improve the rate of early major adverse cardiac and cerebrovascular events in patients undergoing coronary revascularization: analysis of 12 615 patients with multivessel disease. *Eur J Cardiothorac Surg* 2017; 52: 746–752.
3. Shroyer AL, Grover FL, Hattler B, et al. On-pump versus off-pump coronary-artery bypass surgery. *N Engl J Med* 2009; 361: 1827–1837.
4. Ezelsoy M, Oral K, Caynak B, et al. Pain and the quality of life following robotic assisted minimally invasive surgery. *Heart Surg Forum* 2016; 19: E165–E168.
5. Reynolds AC and King N. Hybrid coronary revascularization versus conventional coronary artery bypass grafting: systematic review and meta-analysis. *Medicine* 2018; 97: e11941.
6. Stecher D, van Slochteren FJ, Hoefer IE, et al. The nonocclusive laser-assisted coronary anastomotic connector in an off-pump porcine bypass model. *J Thorac Cardiovasc Surg* 2014; 147: 1390–1397.
7. Stecher D, de Boer B, Tulleken CAF, et al. A new nonocclusive laser-assisted coronary anastomotic connector in a rabbit model. *J Thorac Cardiovasc Surg* 2013; 145: 1124–1129.
8. Stecher D, Agostoni P, Pasterkamp G, et al. Six-month healing of the nonocclusive coronary anastomotic connector in an off-pump porcine bypass model. *Innovations* 2014; 9: 130–136.
9. Stecher D, Bronkers G, Hoefer IE, et al. Total arterial minimally invasive direct coronary artery bypass surgery facilitated by the Trinity Clip connector. *Innovations* 2015; 10: 389–393.
10. Stecher D, Bronkers G, Noest JO, et al. Evaluation of a novel laser-assisted coronary anastomotic connector - the Trinity Clip - in a porcine off-pump bypass model. *J Vis Exp* 2014; 93: e52127.
11. Fitzgibbon GM, Kafka HP, Leach AJ, et al. Coronary bypass graft fate and patient outcome: angiographic follow-up of 5,065 grafts related to survival and reoperation in 1,388 patients during 25 years. *J Am Coll Cardiol* 1996; 28: 616–626.
12. Balkhy HH, Wann LS and Arnsdorf S. Early patency evaluation of new distal anastomotic device in internal mammary artery grafts using computed tomography angiography. *Innovations* 2010; 5: 109–113.
13. Balkhy HH, Patel NC, Ramshandani M, et al. Multicenter assessment of grafts in coronaries: midterm evaluation of the C-Port device (the MAGIC Study). *Innovations* 2018; 13: 273–281.
14. Cai TH, Acuff TE, Randolph Bolton JW, et al. Prospective evaluation of patency and early experience utilizing an automated distal anastomosis device (C-port). *Innovations* 2007; 2: 245–250.
15. Matschke KE, Gummert JF, Demertzis S, et al. The Cardica C-Port System: clinical and angiographic evaluation of a new device for automated, compliant distal anastomoses in coronary artery bypass grafting surgery—a multicenter prospective clinical trial. *J Thorac Cardiovasc Surg* 2005; 130: 1645–1652.
16. Verberkmoes NJ, Wolters SL, Post JC, et al. Distal anastomotic patency of the Cardica C-PORT(R) xA system versus the hand-sewn technique: a prospective randomized controlled study in patients undergoing coronary artery bypass grafting. *Eur J Cardiothorac Surg* 2013; 44: 512–519.
17. Soyulu E, Harling L, Ashrafian H, et al. A systematic review of the safety and efficacy of distal coronary artery anastomotic devices. *Eur J Cardiothorac Surg* 2016; 49: 732–745.