



# Acardiac twin pregnancies part VI: Why does acardiac twinning occur only in the first trimester?

Martin J. C. van Gemert<sup>1</sup>  | Michael G. Ross<sup>2</sup> |  
 Jeroen P. H. M. van den Wijngaard<sup>3</sup>  | Peter G. J. Nikkels<sup>4</sup>

<sup>1</sup>Department of Biomedical Engineering & Physics, Amsterdam University Medical Centers, Amsterdam, The Netherlands

<sup>2</sup>Department of Obstetrics and Gynecology, Harbor UCLA Medical Center, Torrance, California

<sup>3</sup>Department of Clinical Chemistry, Hematology and Immunology, Diaconessenhuis, Utrecht, The Netherlands

<sup>4</sup>Department of Pathology, Wilhelmina Children's Hospital, University Medical Center, Utrecht, The Netherlands

## Correspondence

Martin J. C. van Gemert, Department of Biomedical Engineering & Physics, Amsterdam University Medical Centers, Location AMC, Amsterdam, The Netherlands.

Email: m.j.vangemert@amsterdamumc.nl

## Abstract

**Background:** Clinical observation suggests that acardiac twinning occurs only in the first trimester. In part, this contradicts our previous analysis (part IV) of Benirschke's concept that unequal embryonic splitting causes unequal embryo/fetal blood volumes and pressures. Our aim is to explain why acardiac onset is restricted to the first trimester.

**Methods:** We applied the vascular resistance scheme of two fetuses connected by arterio-arterial (AA) and veno-venous (VV) anastomoses, the small VV resistance approximated as zero. The smaller twin has volume fraction  $\alpha < 1$  of the assumed normal larger twin, and has only access to fraction  $X < 1$  of its placenta; the larger twin's larger mean arterial pressure accesses the remaining fraction. Before 13 weeks, embryos have a much smaller vascular resistance than placentas. After 13 weeks, when maternal blood provides oxygen, smaller twins can increase their vascular volume by hypoxemia-mediated neovascularization. Estimated AA radii at 40 weeks,  $r_{AA}(40)$ , are 0.5–1.3 mm.

**Results:** Embryos with  $\alpha < 0.33$  unlikely survive 13 weeks and acardiac twinning occurs under appropriate conditions (AA-VV, small placenta). Acardiac body perfusion occurs because of a much smaller vascular resistance than the placenta. When  $\alpha > 0.33$  and  $r_{AA}(40)=1.3$  mm, modeled survival is  $>32$  weeks.

**Conclusion:** Before 13 weeks, embryos with  $\alpha < 0.33$  cannot survive and may result in the onset of acardia. Beyond 13 weeks, fetuses with  $\alpha \geq 0.33$  survive because  $r_{AA}(40)$  is too small for acardiac onset. Following fetal demise, exsanguination from the live twin increases its blood volume and, we assumed also, its vascular resistance. Perfusion then occurs through the lower resistance placenta.

## KEYWORDS

AA radius at 40 weeks, acardiac onset, arterio-arterial (AA) anastomoses, fetal survival, first and second trimesters, hypoxia, neovascularization, unequal monochorionic twins, unequal placental sharing

This is an open access article under the terms of the Creative Commons Attribution-NonCommercial-NoDerivs License, which permits use and distribution in any medium, provided the original work is properly cited, the use is non-commercial and no modifications or adaptations are made.

© 2021 The Authors. *Birth Defects Research* published by Wiley Periodicals LLC.

## 1 | INTRODUCTION

Acardiac twinning in monochorionic twin pregnancies requires a set of arterio-arterial (AA) and veno-venous (VV) placental anastomoses and cessation of cardiac function in the future acardiac twin. This complication occurs in about 1 of 8 monochorionic twin placentas that include a unique set of AA and VV anastomoses (van Gemert, van den Wijngaard, & Vandenbussche, 2015). The other twin, the pump twin, then perfuses the acardiac body with deoxygenated arterial blood in a reverse direction compared to normal, hence the name twin reversed arterial perfusion (TRAP) sequence (Van Allen, Smith, & Shepard, 1983). Perfusion of the acardiac body by deoxygenated arterial blood causes the acardiac to grow but often as a bizarre malformed fetus, the precise mechanisms responsible for causing such malformations are unknown (e.g., Das, 1902). Lewi, Valencia, Gonzalez, Deprest, and Nicolaidis (2010) diagnosed 24 first trimester acardiacs and found on average that the ratio of the acardiac twin upper-pole-rump-length to the pump twin crown-rump-length was 0.58, however, with considerable variation. The corresponding average weight ratio of smaller to larger twin, the  $\alpha$ -value, see Equation 1 below, then is approximately  $0.58^3 \approx 0.2$  (eq. 12 of van Gemert, van den Wijngaard, Paarlberg, Gardiner, & Nikkels, 2017). Without intervention, the reported pump twin mortality is about 50%, commonly a result of cardiac failure (Healey, 1994; Moore, Gale, & Benirschke, 1990; Van Allen et al., 1983).

The pathophysiology surrounding acardiac onset is based on two preconditions. First, both twins are connected by a set of AA and VV anastomoses and, second, the future pump twin has a mean arterial pressure that exceeds that of the future acardiac twin. For healthy twins, the second requirement implies a smaller future acardiac twin than future pump twin. It was hypothesized (Benirschke, 2009) that an uneven cell distribution following embryonic splitting must likely have occurred in discordant twins. There, the future acardiac twin has the smaller cell volume and becomes the smaller embryo, and the future pump twin has the larger cell volume and thus becomes the larger embryo. When these effects are “of major proportion,” acardiac twinning will occur, where the pump twin perfuses the acardiac body by a circulation along the AA-VV anastomoses. Another possibility of unequal sized twins is an abnormal future acardiac embryo, for example, due to a chromosomal defect (Sogaard, Skibsted, & Brocks, 1999; Van Allen et al., 1983). Sufficient unequal arterial pressures imply that the larger twin now also perfuses part of the smaller twin's placenta. Thus, the smaller twin must share its placental perfusion with the larger twin and its access to

a smaller placental volume hampers its growth and, hence, also its placental perfusion. This deteriorating process, when “of major proportion,” continues until cardiac arrest occurs. Then, the blood flow from pump to acardiac twin goes via the AA anastomosis through its umbilical cord in reversed direction, and the return flow via the acardiac's umbilical vein and the VV back to the pump twin (van Gemert et al., 2017).

Yet, the pathophysiology of acardiac twinning is still debated, particularly, the mandatory presence of a VV is not well understood, for example, Van Allen et al. (1983) only mentioned that a VV was seen in all placentas, and Otieno, Kosgei, and Keitany (2020) that a VV *occasionally*, rather than always, accompanies an AA.

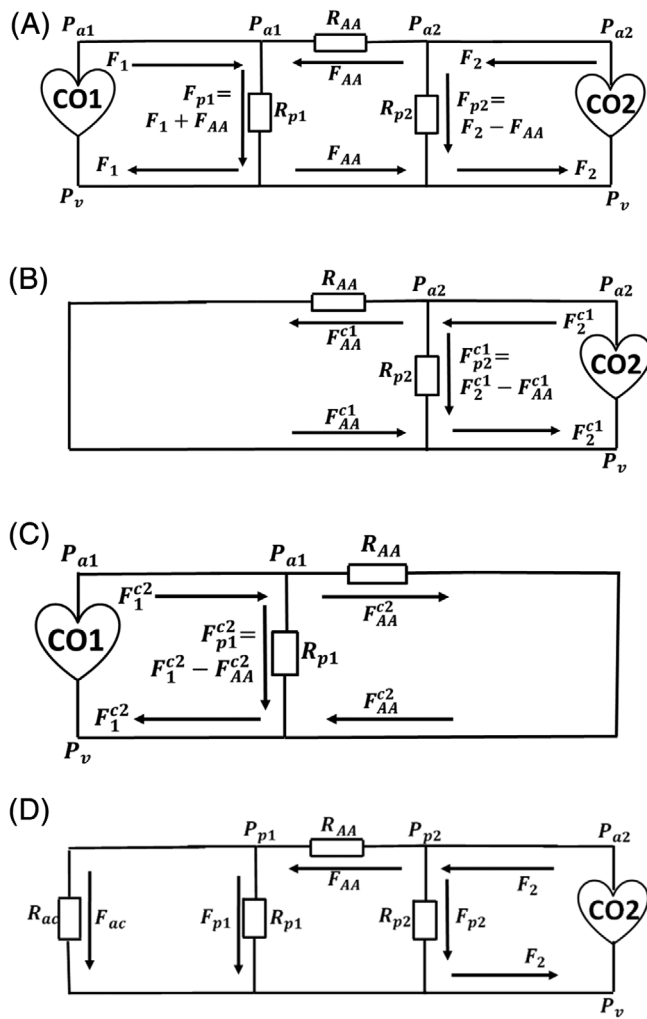
Interestingly, our prior analysis suggested that acardiac onset can occur at earlier as well as later gestations, however, acardiac formation beyond 13 weeks has never been observed. The aim of this paper is to propose possible mechanisms that can explain why acardiac onset is restricted to the first trimester.

## 2 | MATERIALS AND METHODS

The vascular resistance scheme used in this paper to represent a monochorionic twin pregnancy, Figure 1A, is slightly simplified compared to the scheme we used previously (van Gemert et al., 2017). Here, we neglected umbilical arteries and all venous resistances, the latter because they are much smaller (much larger diameter) than their arterial counterparts. The venous pressures of both twins are thus equal now. The pressure gradient that perfuses the larger twin's placenta is the mean arterial minus venous pressure, which we abbreviate as “*mean arterio-venous pressure*”. Similarly for the smaller twin. The two twins, the one with the smaller cardiac output is denoted nr 1 and the one with the larger cardiac output nr 2, are connected by the AA and VV anastomotic resistances,  $R_{AA}$  and  $R_{VV} \approx 0$ , within their monochorionic placenta, with placental resistances  $R_{p1}$  of the smaller twin and  $R_{p2}$  of the larger one.

### 2.1 | Blood volumes, pressures, flows, resistances

At onset of blood pressures, at about five gestational weeks, the blood volume of the smaller twin,  $V_1(t)$ , is a factor of  $\alpha < 1$  smaller than the blood volume of the larger twin,  $V_2(t) = V_N(t)$ , assumed to be of normal dimensions, thus (van Gemert & Sterenborg, 1998)



**FIGURE 1** (A) Resistance scheme of the monozygotic twin pregnancy. CO1, CO2 are the cardiac outputs of twins 1 and 2;  $P_{a1}$ ,  $P_{a2}$  are the mean arterial pressures of twins 1 and 2, and  $P_v$  the common venous pressure of both twins, because all venous resistances (umbilical and VV) have been approximated as zero;  $F_1$ ,  $F_2$ ,  $F_{p1}$ ,  $F_{p2}$  are the blood flows of twins 1, 2 and their placentas;  $F_{AA}$  is the AA blood flow. (B) Resistance scheme with short-circuited CO1, indicated with superscript “c1”. (C) Resistance scheme with short-circuited CO2, indicated with superscript “c2”. (D) Resistance scheme of the resulting acardiac twin pregnancy, with parallel resistances  $R_{ac}$  and  $R_{p1}$ , and  $F_{AA} = F_{ac} + F_{p1}$

$$V_1(t) = \alpha \cdot V_N(t) = \alpha \cdot 149 \cdot \left(\frac{t}{31}\right)^3 = 149 \cdot \left(\frac{\sqrt[3]{\alpha} \cdot t}{31}\right)^3 \quad (1)$$

The mean arterio-venous blood pressure of the smaller twin is (van Gemert et al., 2017, Equation 6)

$$P_{a1} = 52.5 \cdot \frac{(\sqrt[3]{\alpha} \cdot t - 5)}{35} \cdot (0.3 \cdot X + 0.7) \quad (2)$$

where  $X$  is the fraction of the smaller twin’s placenta that still perfuses the smaller twin’s body. The other part is

perfused by the larger twin due to its larger mean arterial pressure and the AA–VV anastomoses. The larger twin’s mean arterio-venous pressure is

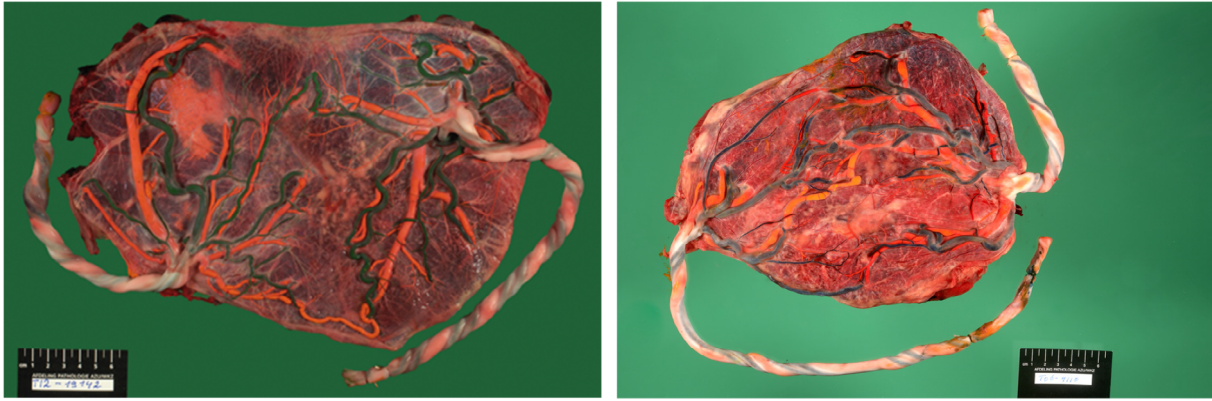
$$P_{a2} = 52.5 \cdot \frac{(t-5)}{35} \quad (3)$$

The diameter of the AA anastomosis at 40 weeks,  $r_{AA}(40)$  (m), is a crucial parameter in this analysis because its resistance is defined as (van Gemert & Sterenberg, 1998, Table 4)

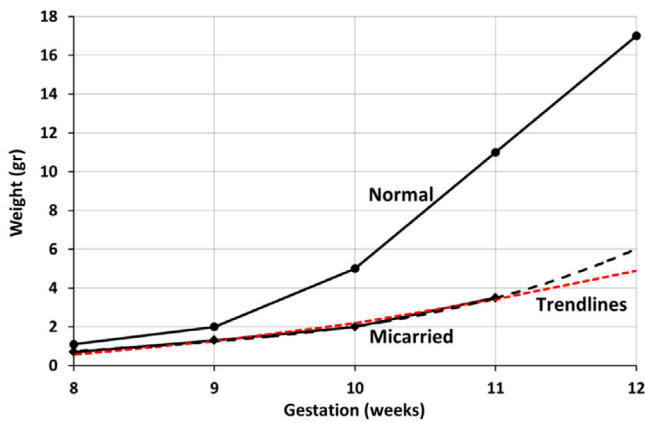
$$R_{AA}(t) = \frac{8 \cdot 0.005}{\pi} \cdot \frac{0.15 \cdot (t-4)/(27 \cdot 1.193)}{[r_{AA}(40) \cdot (t-4)/(27 \cdot 1.193)]^4} \cdot \left(\frac{1}{1.3333 \cdot 10^8 \cdot 60 \cdot 60 \cdot 24 \cdot 7}\right) \quad (4)$$

The blood viscosity used as before is  $0.005 \text{ N}/(\text{m} \cdot \text{s}^2)$  and the AA length at 40 weeks  $0.15 \text{ m}$ . The last term between brackets converts the SI value for resistance [ $(\text{N}/\text{m}^2)/(\text{m}^3/\text{s})$ ] to [ $\text{mmHg}/(\text{ml}/\text{week})$ ]. Factor  $(t - 4)$  indicates that vessel growth is linear with gestation and begins at 4 weeks. An estimate of typical large  $r_{AA}(40)$  values follows from our series of non-acardiac monozygotic twin placentas with a set of large AA–VV anastomoses and about equal sharing (Figure 2), where the extrapolated outer AA diameters at 40 weeks were approximately between  $1.7$  and  $4.5 \text{ mm}$ , hence, using factor  $0.58$  for the inner/outer diameter ratio (Gansburgskiy & Yaltsev, 2018) gives large  $r_{AA}(40)$ -values between about  $0.5$  and  $1.3 \text{ mm}$ , in accordance with values shown in Figure 3 of previous work (van den Wijngaard, Umur, Ross, & van Gemert, 2008). Alternatively (Barbieri, Cecatti, Surita, Marussi, & Costa, 2012; Weissman, Jakobi, Bronshtein, & Goldstein, 1994), the average inner diameters of the umbilical arteries measured in the second and third trimesters gave an average radius of about  $2.1$ – $2.3 \text{ mm}$  at 40 weeks. From the non-acardiac placentas with AA and VV anastomoses, Figure 2, we observed about 2 to 4 branching levels into two-daughter arteries before reaching the AA. Application of branching theory (e.g., Appendix of Umur, van Gemert, Nikkels, & Ross, 2002), the diameter ratio of a pulsating branch is  $1/\sqrt{2}$ , thus  $r_{AA}(40)$ -values of about  $0.5$ – $0.6$  to  $1.1$ – $1.2 \text{ mm}$ , not that different from the values of  $0.5$ – $1.3 \text{ mm}$  above. Thus, in our analysis below, we will use  $r_{AA}(40)$  values of at most  $1.3 \text{ mm}$ .

Calculation of the pressures at the placental insertions and the flows along the resistances requires application of Thévenin’s theorem (e.g., van Gemert et al., 2017), which implies short circuiting the cardiac output of twin 1 (indicated by superscript “c1” in Figure 1B) and calculating pressures and flows, and subsequently short



**FIGURE 2** (Left) Monochorionic twin pregnancy with about equal placental sharing and large AA-VV and arterio-venous and veno-arterial anastomoses at 35 weeks. Dark-colored vessels: arteries; red-orange colored vessels: veins. (Right) Similarly at 36 weeks



**FIGURE 3** Normal weights of Table 28.1, page 1020, of Benirschke, Kaufmann, and Baergen (2006). Miscarried weights from Table 5, median weights, of Nogueira et al. (2020). Trendlines: black and red dashed lines (third and second degree polynomial fit, respectively). Ratio of miscarried/normal weights is 0.32 at 11 weeks and 0.288 and 0.357, thus averaged also 0.32, at 12 weeks. These results suggest that embryos with a weight ratio smaller than 33% unlikely survive beyond 11 weeks, thus supporting our assumption that embryos with  $\alpha < 0.33$  unlikely survive beyond 13 weeks

circuiting twin 2 (“c2” in Figure 1C), calculating all pressures and flows again, and adding the corresponding outcomes. The results are straightforward

$$F_{AA} = \frac{(P_{\alpha 2} - P_{\alpha 1})}{R_{AA}} \quad (5)$$

$$F_1 = P_{\alpha 1} \cdot \frac{(R_{AA} + R_{p1})}{R_{AA} \cdot R_{p1}} \quad (6)$$

$$F_{p1} = P_{\alpha 1} \cdot \frac{(R_{AA} + R_{p1})}{R_{AA} \cdot R_{p1}} + \frac{(P_{\alpha 2} - P_{\alpha 1})}{R_{AA}} \quad (7)$$

$$F_2 = P_{\alpha 2} \cdot \frac{(R_{AA} + R_{p2})}{R_{AA} \cdot R_{p2}} \quad (8)$$

$$F_{p2} = P_{\alpha 2} \cdot \frac{(R_{AA} + R_{p2})}{R_{AA} \cdot R_{p2}} - \frac{(P_{\alpha 2} - P_{\alpha 1})}{R_{AA}} \quad (9)$$

It is also straightforward to check the validity of the equations because at points “ $P_{\alpha 1}$ ” and “ $P_{\alpha 2}$ ”, Figure 1A, the sum of the blood flows entering each location has to be zero, or, point “ $P_{\alpha 1}$ ”, ( $F_1 + F_{AA} - F_{p1} = 0$ ), and, point “ $P_{\alpha 2}$ ”, ( $F_2 - F_{AA} - F_{p2} = 0$ ).

From previous work (Appendix A of van Gemert et al., 2017), the resistance relations for the placenta of the smaller twin 1 and for the normal assumed placenta of twin 2 are

$$R_{p1}(t'') = \frac{0.41}{(t'' + 5) \cdot (t''^2 + 25)} \quad (10)$$

$$t'' = \sqrt[3]{\alpha} \cdot (t - 5) + 5 \quad (11)$$

$$R_{p2}(t) = \frac{0.41}{(t + 5) \cdot (t^2 + 25)} \quad (12)$$

Gestational age  $t'' < t$  is defined as follows: at  $t''$ , the normal twin's blood pressures equal the smaller twin's values at  $t$ , see Figure 2B of previous work (van Gemert et al., 2017).

## 2.2 | Hypoxemia and neovascularization

An important part of our analysis is premise that fetal hypoxemia causes neovascularization, hence increasing

fetal blood volume (de Groot, van den Wijngaard, Beek, Nikkels, & van Gemert, 2007; van Gemert, Ross, Nikkels, & van den Wijngaard, 2016). Using that only fraction  $X < 1$  of the smaller placenta produces venous blood flow with oxygen saturation of 0.8, filling up the whole body gives an oxygen saturation of the smaller twin of  $X$  times 0.8. Then, from eq. 7 of van Gemert et al. (2016), the smaller twin's blood volume with arterial oxygen saturation of  $0.8X$  compared to normal ( $X = 1$ ) is

$$\frac{V_1(0.8 \cdot X)}{V_1(0.8)} = 0.933 + \frac{0.036}{(0.8 \cdot X - 0.0667)^2 + 0.01335} \quad (13)$$

The new  $\alpha$ -value,  $\alpha(\text{new})$ , then becomes

$$\alpha(\text{new}) = \alpha \cdot \left( 0.933 + \frac{0.036}{(0.8 \cdot X - 0.0667)^2 + 0.01335} \right) \quad (14)$$

We will implement Equation 14 from 13 weeks on, when the maternal blood has started the oxygenation of the placenta (e.g., Jaffe, Jauniaux, & Hustin, 1997).

### 3 | RESULTS

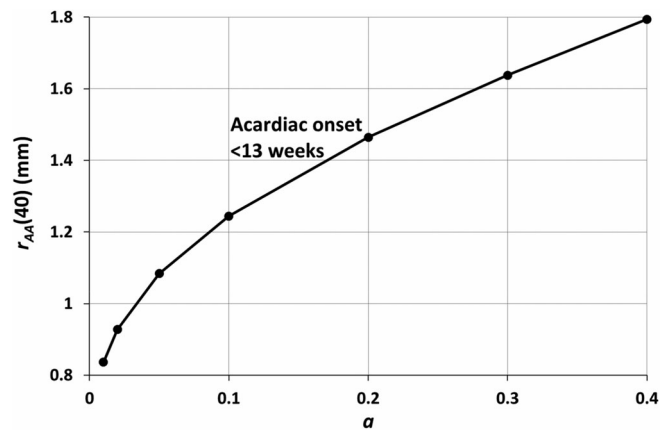
Figure 3 suggests that fetuses whose weight are smaller than about 33% of normal, so  $\alpha < 0.33$ , are unlikely to survive beyond 13 weeks, based on spontaneous loss fetal weights (Table 5, median weights, of Nogueira et al., 2020) versus normal weights (Table 28.1, page 1020, of Benirschke et al., 2006). Thus,

$$\alpha > 0.33 \quad (15)$$

will be used.

Figure 4 shows the outcomes of our prior analysis of acardiac formation occurring before 13 weeks, as related to  $r_{AA}(40)$  and  $\alpha$ . It is clear that fetuses with  $\alpha \approx 0.33$  and  $r_{AA}(40) \approx 1.3$  mm survive beyond 13 weeks. It also suggests that survival beyond 13 weeks already occurs at smaller  $\alpha$ -values, in our model from about 0.15 onward.

Figure 5 shows how the  $\alpha(\text{new})$ , Equation 14, at  $r_{AA}(40) = 1.3$  mm, changes with gestation. For example, for  $\alpha = 0.33$ , the  $\alpha(\text{new})$  value increases from  $\alpha = 0.33$  before 13 weeks to 0.4 at 30 weeks, and the perfused placental fraction  $X$  decreases from 0.85 to 0.51. Previously (van Gemert et al., 2017), we considered that fetal demise would happen when  $X$  became 0.5 or less, which occurs here at about 32 weeks.



**FIGURE 4** Modeled onset of an acardiac twin at 13 weeks, criterion is that the small twin's available placental fraction  $X$  reached 0.5, as a function of  $\alpha$  and  $r_{AA}(40)$

### 3.1 | Limitations

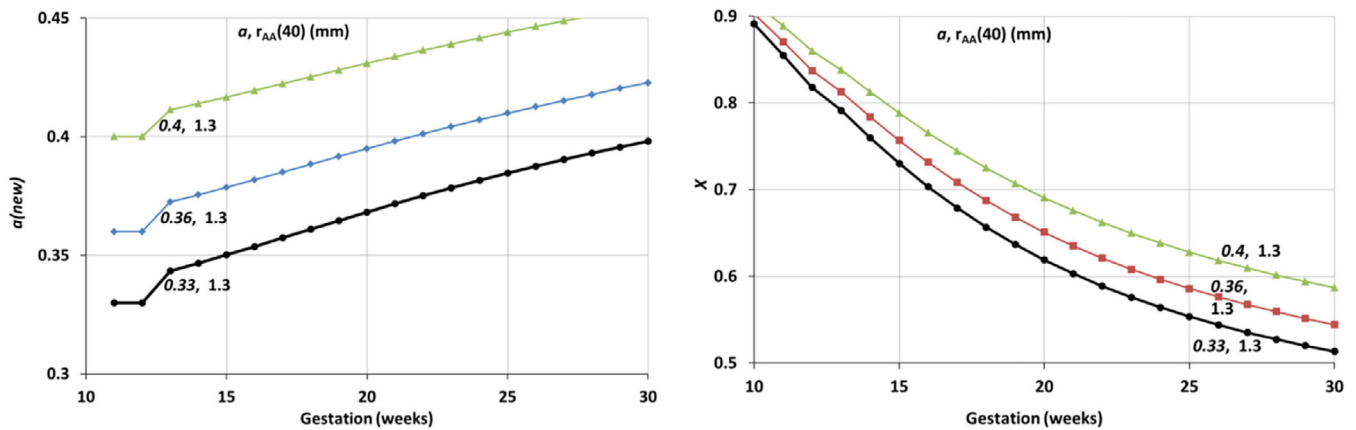
At 32 weeks, when  $X$  becomes about 0.5, a number of protective fetal mechanisms other than hypoxia-mediated-neovascularization will then develop, summarized for a singleton fetus by Baschat (2004). These mechanisms have not been taken into account. Neither have we accounted for protective mechanisms specific for monochorionic twins, not mentioned by Baschat, for example, an increased placental growth and affecting the  $\alpha(\text{new})$ -value due to the smaller twin's increased mean arterial pressure. This increased  $P_{\alpha 1}$ -arterial pressure also reduces the AA flow, which will reduce its  $r_{AA}(40)$  value due to the reduced shear stress; an increased AA-resistance then follows, which mitigates possible deleterious effects on the smaller twin.

### 4 | DISCUSSION

Our results suggest some simple mechanisms that can explain why acardiac onset remains confined to the first trimester. We actually identified two publications where acardiac onset was indeed observed in the first trimester. The first identified two beating hearts at 6 weeks and only one at 7 weeks, and diagnosed the TRAP sequence at 11 weeks (Coulam, 1996). The second identified two beating hearts at 6 + 5 weeks and diagnosed TRAP at 8 + 5 weeks (Wesley et al., 2011).

Before summarizing our findings in the Conclusion, we briefly review some general characteristics associated with acardiac twinning, also incorporating our findings.

The vascular anatomy in acardiac twins that is formed from normal but small embryos, thus before possible anatomical deterioration by deoxygenated blood

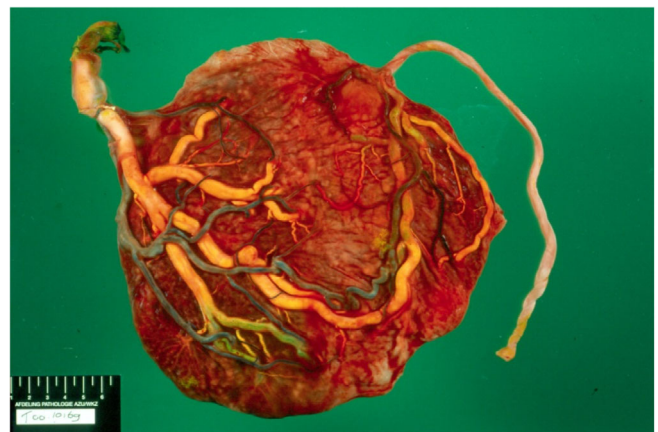

**FIGURE 5** (Left) Model outcomes of  $\alpha(\text{new})$  versus gestation (Equation 14) for various values of  $\alpha$  and  $r_{AA}(40)$ . (Right) Similarly, model outcomes of the small twin's placental fraction  $X$

perfusion occurs, is to our knowledge not presented in literature. Key in this model is the finding that arterial blood from the donor twin flowing retrograde through the acardiac aorta still perfuses all aorta-connected organs in a normal direction, including the lungs of the retrograde-perfused pulmonary artery via the arterial ductus (ductus Botalli). In the acardiac heart, the aorta and pulmonary valves prevent the retrograde flow of blood from entering the left and right ventricles, respectively. However, the blood can go normally to brain, arms and legs. Thus, we expect normal perfusion of the venous circulation, acknowledging that venous valves in legs and arms develop at the end of the first trimester (Kampmeier & Birch, 1927). Except for the heart, the vascular anatomy thus remains normal. The blood flow through the arteries, excluding the aorta and pulmonary artery, is also in normal direction.

Some of the key factors surrounding acardiac twinning are as follows. It requires primarily a monochorionic twin placenta (but see the next two paragraphs), a set of AA and VV anastomoses for the circulation between pump and acardiac, and cessation of cardiac function in the future acardiac twin. This twin usually has a small placenta and a low weight compared to normal; specifically, this weight is to be smaller than 33% of normal, Equation 15. The small twin can be the result of unequal embryonic splitting as postulated by Benirschke (2009), but also due to genetic abnormalities, by Sogaard et al. (1999) called “primary defect in embryogenesis.” We acknowledge that one or more arterio-venous (AV) anastomoses from larger to smaller twin provide additional blood flow to the smaller twin and may prevent acardiac onset. Among monochorionic twins, an AA anastomosis occurs in about 82%, and a VV in about 26% (van Gemert et al., 2015), so assuming unrelated incidences, about 21% of these placentas can produce an

acardiac twin. From our series of 507 dye-injected monochorionic placentas (PGJN), 17, 3.35%, had a set of AA-VV anastomoses, but no deep anastomoses (i.e., AV or VA). Second, within these placentas (Figures 2 and 6), typical AA radii are smaller than 1.3 mm at 40 weeks, and our model predicts that these AA anastomoses keep the smaller twin's placenta large enough to continue the pregnancy beyond 32 weeks. Subsequently, we assumed that fetoplacental protective measures (e.g., brain sparing, peripheral arterial constriction, Baschat, 2004) keep the fetus alive and ongoing. Third, a set of AA-VV anastomoses without (bidirectional) AVs could affect the size of the smaller twin, increasing its mean arterial pressure and, hence, placental perfusion, and may thus affect the level of placental sharing. In twin-twin transfusion syndrome cases, an AA is known to have a protective role



**FIGURE 6** Monochorionic twin placenta at 36.3 weeks with a live girl of 2,490 g and IUFD of the other child at 27 weeks. The deceased twin, its (former) placenta, and umbilical cord were not perfused, indicated by the macerated cord. Dark-colored vessels: arteries, yellow vessels: veins

for the donor twin (e.g., Umur et al., 2002). On the other hand (Denbow, Cox, Taylor, Hammal, & Fisk, 2000; Nikkels, Hack, & van Gemert, 2008), a VV anastomosis can sometimes complicate the pregnancy, an observation that is not well understood.

Interestingly, an acardiac twin pregnancy has also been described in a dichorionic fused placenta (French, Bieber, David, Bing, & Genest, 1998). To our best knowledge, this is the only such case published in literature. At 13.7 weeks, ultrasonography identified a twin pregnancy with one of the twins demised. At 42 weeks, a 3,554 g healthy male and a 230 g amorphous ovoid acardiac mass with a fluid filled cyst were delivered. The placenta weighted 450 g, the pump's part about 4 times larger than the acardiac's part (derived from the given dimensions). The dividing membrane showed two chorions and two amnions. A large VV anastomosis was identified following barium injection into the pump's umbilical vein. No mentioning was made of an AA anastomosis, however, the two placentas were reported to be histologically mature, implying that an AA anastomosis must have been present.

Further, in a personal communication to Schinzel, Smith, and Miller (1979), Professor Jan E. Jirásek, Embryology Laboratory, Prague, reported a "conjoined" twin placenta with dizygotic chromosomally XX and XY twins of which one was an acardiac. In addition, Bieber et al. (1981) described a two polar body twin pregnancy with a monochorionic-diamniotic placenta and a chromosomally XY pump twin and triploid XXX acardiac mass.

The rare incidence of dichorionic fused placental acardiac twinning can be approximately estimated as follows. From 1977 to 1980, Robertson and Neer (1983) collected 278 twin pairs of which 66 were monochorionic, 96 dichorionic fused, and 97 dichorionic separate. Assuming a 0.4% incidence of monochorionic twinning, the incidence of dichorionic fused placentas is about  $(96/66) \times 0.4\% = 0.58\%$ . Thus, one in  $(1/0.0058) = 172$  pregnancies. In one of 68 dichorionic placentas, an anastomosis (an AV) was observed. Thus, one in  $68 \times 172 = 11,700$  pregnancies. Assuming that the probability of anastomotic formation in dichorionic fused placentas is identical as in monochorionic placentas, the probability of an acardiac twin where the pump survived the first trimester is one in 35,000 (the old probability without early miscarried pumps). Thus, the probability of a dichorionic acardiac twin is about one in  $11,700 \times 35,000 = 409.5$  million pregnancies! With 213 million pregnancies worldwide in 2012 (Sedgh, Singh, & Hussain, 2014), this implies worldwide one dichorionic acardiac in  $409.5/213 = 1.9$  years. If the mentioned 20% or so miscarriages are included, the prediction becomes one dichorionic acardiac worldwide in

2.4 years. Despite the unavoidable uncertainties in this analysis, the extreme rarity of this phenomenon is clear.

Essential for acardiac growth is that the retrograde arterial perfusion from the pump twin is through the acardiac body rather than through its placenta. Because these two organs function as parallel resistances (Figure 1D), this requires a lower acardiac- than placental vascular resistance. From pathology experience (PGJN), the vascular density of a first trimester embryo is indeed much larger than a first trimester placenta, thus fulfilling this resistance requirement. Experimental support comes from the very small number of placental capillaries per villous profile, which increases from 1 at 6 weeks to 4 at 17 weeks (Figures 4d and 1c of Jauniaux, Jurkovic, and Campbell (1991), Jauniaux, Jurkovic, Campbell, & Hustin, 1992), respectively). In contrast, the organs of embryos have a significantly larger vascular density.

An interesting question is why an acardiac twin will not develop when, for whatever reason, cardiac function ceases in the smaller twin in the second trimester or later. From similar arguments as discussed above for the first trimester, here, the resistance relation between placenta and fetus must be reversed, thus the placenta must have a much lower resistance than the fetus to prevent fetal body perfusion and hence acardiac growth. From Table 28.1 of Benirschke et al. (2006), normal placental weight becomes lower than normal fetal body weight beyond 14 weeks, and because weight is proportional to blood volume, the placental resistance becomes larger under normal conditions than the body resistance. However, essential is here that cardiac arrest of the smaller fetus causes its arterial pressure to drop to about its venous pressure, hence exsanguination of the larger twin into the small twin occurs, particularly into the veins, until the arterial pressures at the two cord insertions have become equal. In the second trimester, the compliance of the veins allows a significant volume of extra blood to enter the deceased fetus, which we tacitly assumed increases its body vascular resistance also significantly. Thus, opposite to embryos, here we have an assumed (much) larger body- than placental resistance, which prevents that backflow toward the larger twin goes through the high-resistance body but, instead, it goes via the lower resistance placenta. A first example is shown in Figure 6. At 27 weeks, IUFD was observed and delivery was at 36 weeks (girl of 2,490 g and deceased body of 590 g). There was an AA, a very large VV and a few AVs. No placental parenchyma could be observed belonging to the deceased twin and the umbilical cord had a macerated aspect compatible with cessation of perfusion. A second example is the acardiac dichorionic fused placenta

case, where the former acardiac placenta is about 20% of the total placenta. Apparently here, not only the acardiac was perfused and grew, but also the placenta. We attribute the difference between the previous (Figure 6) and this case to the exsanguination and hence increased body resistance of the case of Figure 6, which did not happen in the dichorionic placenta.

In conclusion, our analysis suggests that acardiac twinning is restricted to the first trimester because (a) small fetuses ( $\leq 33\%$  of normal weight) do not survive 13 weeks and, because the placental resistance strongly exceeds the embryo resistance, an acardiac pregnancy from embryo-perfusion will form under the right circumstances (AA-VV resistances, no significant AV's from larger to smaller twin, and small placenta), (b) beyond the first trimester, the smaller twin has  $>33\%$  weight compared to normal, hypoxemia mediated neovascularization increases the blood volume of the smaller twin, and the AA anastomoses then have a too small diameter, hence too large resistance, to be able to cease cardiac activity in the second trimester, and (c) even if cardiac function ceases in the smaller twin in the second trimester, retrograde perfusion through the deceased twin, or acardiac onset, does not occur, due to its assumed large vascular resistance from the relatively large exsanguinated blood volume, making the return flow to go through the much lower resistance placenta (Figure 6).

These findings may have clinical significance. Should mid to late first trimester ultrasound demonstrate a marked discordancy in fetal weight, the prognosis for acardiac development is extremely high.

## CONFLICT OF INTEREST


The authors declare no conflict of interest.

## DATA AVAILABILITY STATEMENT

I have a data availability statement.

## ORCID

Martin J. C. van Gemert  <https://orcid.org/0000-0002-3747-6219>

Jeroen P. H. M. van den Wijngaard  <https://orcid.org/0000-0001-6648-8967>

## REFERENCES

- Barbieri, C., Cecatti, J. G., Surita, F. G., Marussi, E. F., & Costa, J. V. (2012). Sonographic measurement of the umbilical cord area and the diameters of its vessels during pregnancy. *Journal of Obstetrics and Gynecology*, *32*, 230–236.
- Baschat, A. A. (2004). Fetal responses to placental insufficiency: An update. *British Journal of Obstetrics and Gynaecology*, *111*, 1031–1041.
- Benirschke, K. (2009). The monozygotic twinning process, the twin-twin transfusion syndrome and acardiac twins. *Placenta*, *30*, 923–928.
- Benirschke, K., Kaufmann, P., & Baergen, R. (2006). *Pathology of the human placenta* (5th ed.). New York, NY: Springer.
- Bieber, F. R., Nance, W. E., Morton, C. C., Brown, J. A., Redwine, F. O., Jordan, R. L., & Mohanakumar, T. (1981). Genetic studies of an acardiac monster: Evidence of polar body twinning in man. *Science*, *213*(4509), 775–777.
- Coulam, C. B. (1996). First trimester diagnosis of acardiac twins. *American Journal of Obstetrics and Gynecology*, *88*(4), 729.
- Das, K. (1902). Acardiacus anceps. *The Journal of Obstetrics and Gynaecology of the British Empire*, *2*, 341–355.
- de Groot, R., van den Wijngaard, J. P. H. M., Beek, J. F., Nikkels, P. G. J., & van Gemert, M. J. C. (2007). Modeling acardiac twin pregnancies. *Ann N York Acad Sci*, *1101*, 235–249.
- Denbow, M. L., Cox, P., Taylor, M., Hammal, D. M., & Fisk, N. M. (2000). Placental angioarchitecture in monochorionic twin pregnancies: relationship to fetal growth, fetofetal transfusion syndrome, and pregnancy outcome. *American Journal of Obstetrics and Gynecology*, *182*(2), 417–426.
- French, C. A., Bieber, F. R., David, H., Bing, D. H., & Genest, D. R. (1998). Twins, placentas, and genetics: Acardiac twinning in a dichorionic, diamniotic, monozygotic twin gestation. *Human Pathology*, *29*, 1028–1031.
- Gansburgskiy, A. N., & Yaltsev, A. V. (2018). Arteries of the chorion of pregnant women with arterial hypertension. *Nurs Palliat Care*, *3*(1), 1–4.
- Healey, M. G. (1994). Acardia: Predictive risk factors for the co-twin's survival. *Teratology*, *50*, 205–213.
- Jaffe, R., Jauniaux, E., & Hustin, J. (1997). Maternal circulation in the first-trimester human placenta—Myth or reality? *American Journal of Obstetrics and Gynecology*, *176*(3), 695–705.
- Jauniaux, E., Jurkovic, D., & Campbell, S. (1991). In vivo investigations of the anatomy and the physiology of early human placental circulations. *Ultrasound in Obstetrics and Gynecology*, *1*, 435–445.
- Jauniaux, E., Jurkovic, D., Campbell, S., & Hustin, J. (1992). Doppler ultrasonographic features of the developing placental circulation: Correlation with anatomical findings. *American Journal of Obstetrics and Gynecology*, *166*, 585–587.
- Kampmeier, O. F., & Birch, C. L. F. (1927). The origin and development of the venous valves, with particular reference to the saphenous district. *The American Journal of Anatomy*, *38*, 451–499.
- Lewi, L., Valencia, C., Gonzalez, E., Deprest, J., & Nicolaides, K. H. (2010). Arterial perfusion sequence diagnosed in the first trimester. *American Journal of Obstetrics and Gynecology*, *203*, e1–e4.
- Moore, T. R., Gale, S., & Benirschke, K. (1990). Perinatal outcome of forty-nine pregnancies complicated by acardiac twinning. *American Journal of Obstetrics and Gynecology*, *163*, 907–912.
- Nikkels, P. G. J., Hack, K. E. A., & van Gemert, M. J. C. (2008). Pathology of twin placentas with special attention to monochorionic twin placentas. *Journal of Clinical Pathology*, *61*, 1247–1253.
- Nogueira, R., Sousa, S., Braga, A. C., Azevedo, A., Pereira, N., Carmo, O., ... Correia Pinto, J. (2020). Measurements in first-



- trimester abortion products: A pathologic study. *Archives of Pathology & Laboratory Medicine*, 144, 207–214.
- Otieno, P. O., Kosgei, W., & Keitany, K. K. (2020). Acardiac twin: The overlooked diagnosis. A recent case report and review of literature. *Gynecology and Obstetrics Case Reports*, 6(2), 89 (1–5).
- Robertson, E. G., & Neer, K. J. (1983). Placental injection studies in twin gestation. *American Journal of Obstetrics and Gynecology*, 147, 170–174.
- Schinzel, A. A. G. L., Smith, D. W., & Miller, J. R. (1979). Monozygotic twinning and structural defects. *The Journal of Pediatrics*, 95(6), 921–930.
- Sedgh, G., Singh, S., & Hussain, R. (2014). Intended and unintended pregnancies worldwide in 2012 and recent trends. *Studies in Family Planning*, 45(3), 301–314.
- Søgaard, K., Skibsted, L., & Brocks, V. (1999). Acardiac twins: Pathophysiology, diagnosis, outcome and treatment. *Fetal Diagnosis and Therapy*, 14, 53–59.
- Umur, A., van Gemert, M. J. C., Nikkels, P. G. J., & Ross, M. G. (2002). Monochorionic twins and twin-twin transfusion syndrome: The protective role of arterio-arterial anastomoses. *Placenta*, 23, 201–209.
- Van Allen, M. I., Smith, D. W., & Shepard, T. H. (1983). Twin reversed arterial perfusion (TRAP) sequence: A study of 14 twin pregnancies with acardiacus. *Seminars in Perinatology*, 7, 285–293.
- van den Wijngaard, J. P. H. M., Umur, A., Ross, M. L., & van Gemert, M. J. C. (2008). Twin-twin transfusion syndrome: Mathematical modelling. *Prenatal Diagnosis*, 28, 280–291.
- van Gemert, M. J. C., Ross, M. G., Nikkels, P. G. J., & van den Wijngaard, J. P. H. M. (2016). Acardiac twin pregnancies part III: Model simulations. *Birth Defects Research Part A: Clinical and Molecular Teratology*, 106, 1008–1015.
- van Gemert, M. J. C., & Sterenborg, H. J. C. M. (1998). Hemodynamic model of twin-twin transfusion syndrome in mono-chorionic twin pregnancies. *Placenta*, 19, 195–208.
- van Gemert, M. J. C., van den Wijngaard, J. P. H. M., Paarlberg, K. M., Gardiner, H. M., & Nikkels, P. G. J. (2017). Acardiac twin pregnancies part IV: Acardiac onset from unequal embryonic splitting simulated by a fetoplacental resistance model. *Birth Defects Research*, 109, 211–223.
- van Gemert, M. J. C., van den Wijngaard, J. P. H. M., & Vandenbussche, F. P. H. A. (2015). Twin reversed arterial perfusion sequence is more common than generally accepted. *Birth Defects Research Part A: Clinical and Molecular Teratology*, 103, 641–643.
- Weissman, A., Jakobi, P., Bronshtein, M., & Goldstein, I. (1994). Sonographic measurements of the umbilical cord and vessels during normal pregnancies. *Journal of Ultrasound in Medicine*, 13, 11–14.
- Wesley, A. J., Thomas, J. T., Peterson, S., Cincotta, R., Lourie, R., & Gardiner, G. (2011). An acardiac twin with a documented heart beat at 6+5 weeks and TRAP diagnosed at 8+5 weeks—Insights into possible pathophysiology. *Prenatal Diagnosis*, 31, 413–414.

**How to cite this article:** van Gemert MJC, Ross MG, van den Wijngaard JPHM, Nikkels PGJ. Acardiac twin pregnancies part VI: Why does acardiac twinning occur only in the first trimester? *Birth Defects Research*. 2021;113:687–695. <https://doi.org/10.1002/bdr2.1882>