

Title	Effects of Cerclage Cabling on Preventing Periprosthetic Femoral Fractures When Using Cementless Stems for Unstable Femoral Neck Fractures
Author(s)	Iwasa, Makoto; Ando, Wataru; Takashima, Kazuma et al.
Citation	Journal of Arthroplasty. 2024
Version Type	VoR
URL	https://hdl.handle.net/11094/97168
rights	This article is licensed under a Creative Commons Attribution-NonCommercial 4.0 International License.
Note	

Osaka University Knowledge Archive : OUKA

<https://ir.library.osaka-u.ac.jp/>

Osaka University



ELSEVIER

Contents lists available at ScienceDirect

The Journal of Arthroplasty

journal homepage: www.arthroplastyjournal.org

Effects of Cerclage Cabling on Preventing Periprosthetic Femoral Fractures When Using Cementless Stems for Unstable Femoral Neck Fractures

Makoto Iwasa, MD, PhD ^a, Wataru Ando, MD, PhD ^{a, b}, Kazuma Takashima, MD, PhD ^c,
Keisuke Uemura, MD, PhD ^c, Hidetoshi Hamada, MD, PhD ^a,
Nobuhiko Sugano, MD, PhD ^{a, *}

^a Department of Orthopaedic Medical Engineering, Osaka University Graduate School of Medicine, Suita City, Osaka, Japan

^b Department of Orthopaedic Surgery, Kansai Rosai Hospital, Amagasaki City, Hyogo, Japan

^c Department of Orthopaedic Surgery, Osaka University Graduate School of Medicine, Suita City, Osaka, Japan

ARTICLE INFO

Article history:

Received 23 November 2023

Received in revised form

30 April 2024

Accepted 30 April 2024

Available online xxx

Keywords:

cerclage cabling

postoperative periprosthetic fracture

intraoperative periprosthetic fracture

femoral neck fracture

cementless stem

ABSTRACT

Background: Periprosthetic femoral fractures (PFFs) are serious complications in hip arthroplasty for femoral neck fractures. The rates of intraoperative (iPFFs) and postoperative PFFs (pPFFs) are higher in cementless stem cases than in cemented cases. This study aimed to investigate the effects of cerclage cabling on PFF prevention in cementless arthroplasty for femoral neck fractures.

Methods: This retrospective study included 329 consecutive patients who underwent hip arthroplasty using a cementless stem for femoral neck fractures. A total of 159 and 170 patients were in the non-cabling and cabling groups, respectively. Patient characteristics were comparable in both groups. The PFF occurrence (iPFF and pPFF) rates, reoperation rates, operative time, and blood loss volume were compared between the groups.

Results: The iPFF rate was significantly higher in the noncabling group (6.3%) than in the cabling group (0%, $P < .001$). The rate of pPFF was significantly higher in the non-cabling group (5.1%) than in the cabling group (0.6%; $P = .016$). All patients in the non-cabling group required reoperation (5.1%), whereas the patient in the cabling group was an ambulatory case and required no reoperation (0%, $P = .003$). No significant difference in either operative time or blood loss volume was observed between the non-cabling (50 minutes, 133 mL) and cabling (52 minutes, $P = .244$; 149 mL, $P = .212$, respectively) groups.

Conclusions: When a cementless stem is used to treat unstable femoral neck fractures, cerclage cabling effectively prevents iPFF and pPFF without increasing surgical time or blood loss volume.

© 2024 The Author(s). Published by Elsevier Inc. This is an open access article under the CC BY-NC license (<http://creativecommons.org/licenses/by-nc/4.0/>).

Unstable femoral neck fractures in elderly patients constitute a severe traumatic event associated with a decline in the quality

of life and an increased risk of mortality [1–3], and are increasingly common [4,5]. Approximately 4.5 million people worldwide, including 2 million people in Asia, will suffer from femoral neck fractures by 2050 [4]. In general, arthroplasty is indicated for unstable femoral neck fractures for early restoration of ambulation [6], and 2 principal approaches for femoral stem fixation are considered: cemented and cementless methods.

Cemented stem fixation has some limitations. The bone cement implantation syndrome [7,8] is a serious and fatal complication associated with cemented stem fixation. It is characterized by a high mortality rate within 24 hours postoperatively and an increased postoperative infection risk, which is exacerbated by a

Funding: This study was supported by a research grant from JSPS KAKENHI Grant Number (20K09503).

One or more of the authors of this paper have disclosed potential or pertinent conflicts of interest, which may include receipt of payment, either direct or indirect, institutional support, or association with an entity in the biomedical field which may be perceived to have potential conflict of interest with this work. For full disclosure statements refer to <https://doi.org/10.1016/j.arth.2024.04.085>.

* Address correspondence to: Nobuhiko Sugano, MD, PhD, Department of Orthopaedic Medical Engineering, Osaka University Graduate School of Medicine, 2-2 Yamadaoka, Suita City, Osaka 565-0871, Japan.

<https://doi.org/10.1016/j.arth.2024.04.085>

0883-5403/© 2024 The Author(s). Published by Elsevier Inc. This is an open access article under the CC BY-NC license (<http://creativecommons.org/licenses/by-nc/4.0/>).

prolonged operative time, compared to those associated with the cementless method [9].

However, intraoperative periprosthetic femoral fractures (iPFFs) and postoperative periprosthetic femoral fractures (pPFFs) are major complications of hip arthroplasty, particularly in the context of cementless fixation, because of bone fragility in elderly patients [1]. Moreover, hip arthroplasty performed by surgeons who have limited experience, known as low-volume surgeons, is associated with a high risk of periprosthetic femoral fractures (PFFs) [10]. Several risk factors for PFF have been identified, including age, sex, body mass index (BMI), and femur bone quality [9,11–13]. Reoperation for PFF in elderly patients is associated with a high risk of intraoperative bleeding, long operative time, and high dislocation risk and revision rates. The treatment is technically demanding, and the risk of postoperative mortality remains high [11,14–16]. To reduce the risk of PFF, some studies have recommended the use of cemented stem fixation for arthroplasty in the treatment of hip fractures in older patients [14,15]. Cementless hip arthroplasty is the predominant treatment choice in many areas worldwide [17,18], and some authors have reported on the use of cementless stems even for unstable femoral neck fractures [16,19,20]. Moreover, the proportions of patients who have unstable femoral neck fractures who underwent cementless stem fixation have been estimated at 74% [16] and 70% [19] in previous studies. This evidence suggests the need to minimize the risk of PFF during cementless stem fixation.

Consequently, we introduced prophylactic cerclage cabling of the proximal femur with cementless stem fixation to treat unstable femoral neck fractures. This study aimed to evaluate the efficacy of femoral cabling in cementless bipolar hip arthroplasty for unstable femoral neck fractures in reducing the PFF rate.

Methods

Patients

This was a retrospective study, and all procedures involving human participants were performed in accordance with the ethical standards of our institutional research committee (reference number: 16,409) and the 1964 Helsinki Declaration and its later amendments or comparable ethical standards.

Patients who had undergone bipolar hip arthroplasty for unstable femoral neck fractures at a single institution were included. We diagnosed an unstable femoral neck fracture, stages III and IV of the Garden classification, based on the findings from anterior and lateral hip radiographs [21]. All the patients underwent bipolar hip arthroplasty with cementless stems to help reduce operative time and bone cement implantation syndrome risk [7–9,22]. Patients who had stable neck fractures were excluded from this study because osteosynthesis was the treatment of choice. A total of 160 consecutive patients who did not undergo femoral cerclage cabling (February 2016 to June 2020) were evaluated. Between February 2016 and June 2020, we observed cases of iPFF and pPFF. A total of 177 patients underwent femoral cerclage cabling as a preventive strategy between July 2020 and January 2023. The patients were then categorized into cabling groups. In the non-cabling group, 1 patient who underwent revision surgery owing to an infection 1 month postoperatively was excluded. In the cabling group, 7 patients who had different stem designs were excluded. This study included 159 and 170 patients in the non-cabling and cabling groups, respectively (Figure 1). A *post hoc* power analysis was

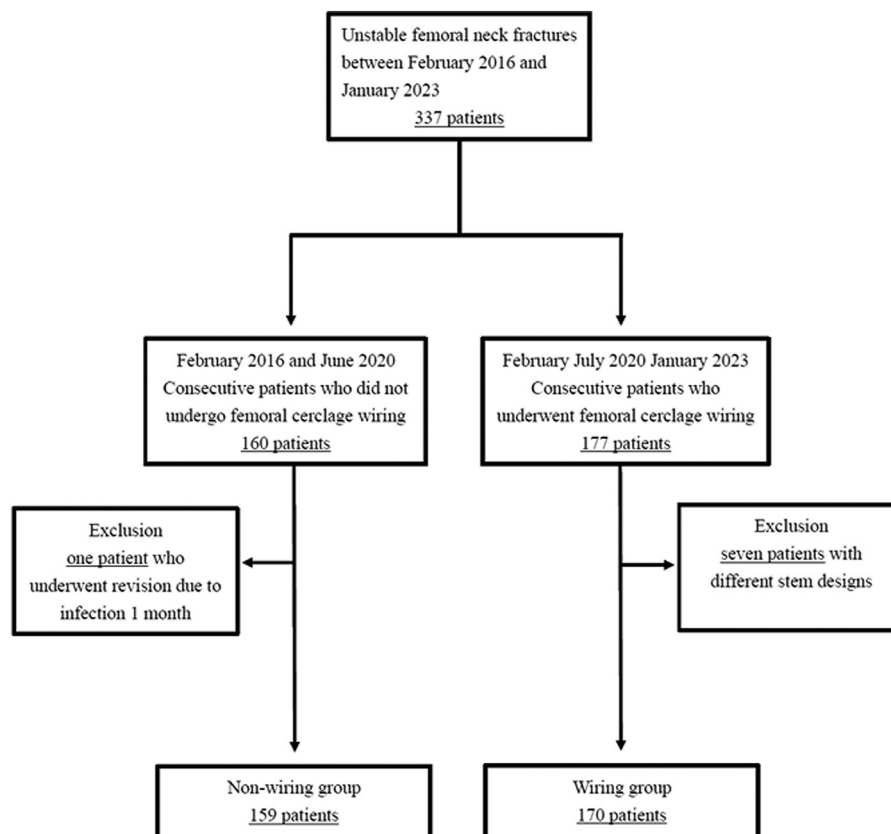


Fig. 1. Flowchart of the study.

Table 1
Comparison of Patient Characteristics Between the 2 Groups.

Group	Noncabling (n = 159)	Cabling (n = 170)	P Value
Sex (men and women)	119 and 40	129 and 41	.898
Age (y)	83 ± 7.6	83 ± 7.1	.772
Body mass index (kg/m ²)	20.3 ± 3.8	20.8 ± 3.6	.484
Dorr classification (n [%])			.231
Type A	2 (1.3)	3 (1.8)	
Type B	123 (77.3)	142 (83.5)	
Type C	34 (21.4)	25 (14.7)	

performed, which revealed that with an alpha error of 0.05 and an effect size of 0.3, the study had a power of 0.99 using G*Power version 3.1.9.6 (Heinrich-Heine-Universität Düsseldorf, Düsseldorf, Germany) [23]. Patient characteristics related to PFF, including sex, age, BMI, and femoral bone quality [9,11–13], were investigated. Femoral bone quality was evaluated according to the Dorr classification (types A, B, and C) [13], using immediate postoperative radiographic images. The patient characteristics were comparable between the groups (Table 1).

All surgeons were orthopaedic general surgeons who had 5 to 9 years of postresidency experience. They performed procedures utilizing a single-design femoral implant (Trabecular Metal stem; ZimmerBiomet, Warsaw, IN) through the modified Watson–Jones approach. A cerclage cable (Cable-Ready; ZimmerBiomet, Warsaw, IN) was placed in a standard manner superior to the lesser trochanter before rasping (Figure 2). This technique was standardized among surgeons. Perioperative rehabilitation followed the standard protocol, and all patients were allowed full weight-bearing on the first postoperative day. Patients who had intraoperative fractures were given 4 weeks to recover before weight-bearing.

Assessment Items

We evaluated the radiographs of patients at 1, 3, and 6 months; 1 year postoperatively; and annually thereafter. The mean observation period was 12 months (range, 1 to 66) in the noncabling group and 6 months (range, 1 to 24) in the cabling group. The first half of the continuous period was the non-cabling group and the second half was the cabling group, and there was a difference in the observation period. The occurrence of iPPF, pPPF, reoperation, superficial infection, operative time, blood loss volume, dislocation, and postoperative subsidence rates were compared between the 2 groups. The iPPF were identified as follows: after the removal of soft tissue obstructions that impeded visibility and the broaching process, the femoral cortical bone was meticulously examined before and after stem insertion. If iPPF was identified, the femoral cerclage cable was used. The proportion of pPPF was calculated using patients excluded who had an iPPF as the denominator. The cumulative survival rate was assessed using the reoperation of the most important outcome as the endpoint. Subsidence was investigated as a surgical factor related to pPPF [24] and was defined as a postoperative change of ≥ 2 mm on radiographs at the last follow-up [11].

Data Analyses

The normality of the variable distribution was confirmed using the Shapiro–Wilk test. Age, BMI, operative time, blood loss, iPPF occurrence rate, pPPF occurrence rate, reoperation rate, infection rate, dislocation rate, and postoperative subsidence rate were

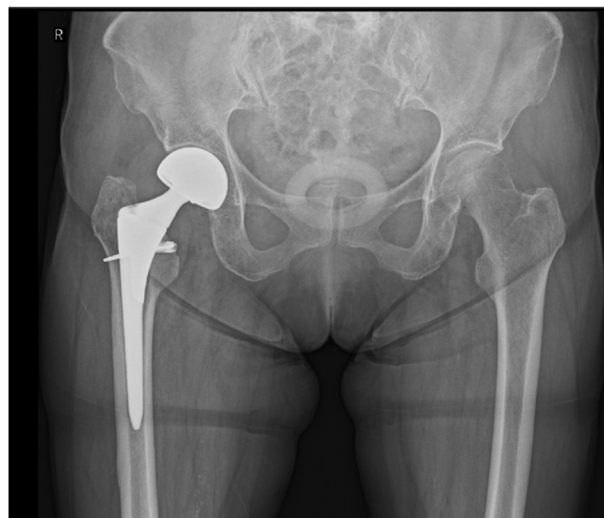


Fig. 2. Cerclage cabling was performed on the femoral neck with a cable passer at the end of the rasping.

compared using paired Student's *t*-tests and *Chi*-square tests. We compared the Dorr classifications using $m \times n$ contingency table tests. The cumulative survival rates for the 2 groups were measured using the Kaplan–Meier method. Statistical analyses were performed using the JMP software version 15.0 (SAS Institute, Cary, NC), with significance set at $P < .05$.

Results

An iPPF was observed in 11 (6.9%) and zero (0%) patients in the noncabling and cabling groups, respectively ($P < .001$; Table 2). All iPPFs were observed during stem insertion. A pPPF occurred in 8 (5.4%) patients in the noncabling group and in only 1 case (0.6%) in the cabling group. The incidence of pPPF was significantly lower in the cabling group than in the noncabling group ($P = .016$; Table 2). All cases of pPPF occurred within 1 month postoperatively. Reoperations for pPPF were performed in 8 (5.0%) patients in the noncabling group. In contrast, reoperation was not required in the cabling group. Among the patients in the noncabling group who underwent reoperation, osteosynthesis was performed in 5 patients, a combination of osteosynthesis and stem revision in 2 patients, and stem revision in only 1 patient. The incidence of reoperation was significantly lower in the cabling group than in the noncabling group ($P = .003$; Table 2). The cumulative survival rates with reoperation as the endpoint differed significantly between the 2 groups ($P = .003$; Figure 3).

Table 2
Comparison of Surgical Outcomes Between the 2 Groups.

Group	Noncabling (n = 159)	Cabling (n = 170)	P Value
Intraoperative fracture (%)	6.9	0	<.001
Postoperative fracture (%)	5.4	0.6	.016
Reoperation rate (%)	5.0	0	.003
Operative time (min)	50.0 ± 12.6	52.5 ± 17.4	.244
Bleeding volume (mL)	133.1 ± 63.4	149.9 ± 93.2	.212
Postoperative superficial infection rate (%)	0	0	Not applicable
Postoperative dislocation rate (%)	0	0	1.000
Subsidence ≥ 2 mm (%)	8.2	4.1	.166

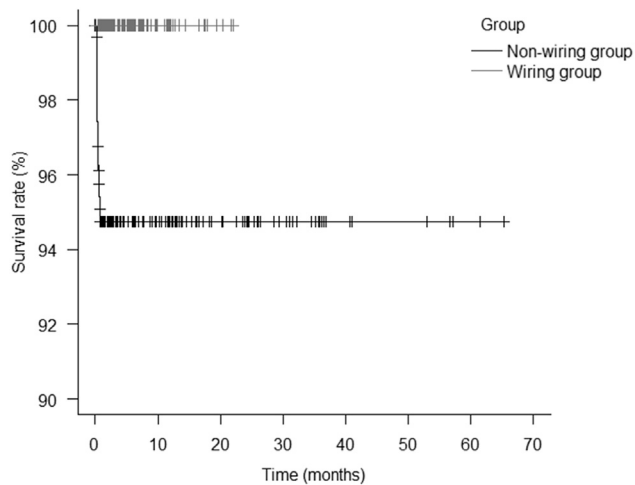


Fig. 3. Graph demonstrates patients who underwent reoperation as an endpoint in the 2 groups. The reoperation rate was 5.1% in the noncabling group and 0% in the cabling group ($P = .003$).

In the non-cabling and cabling groups, the mean operative times were 52.5 ± 17.4 and 50.0 ± 12.6 minutes, and mean blood loss volumes were 149.9 ± 93.2 and 133.1 ± 63.4 mL, respectively; these values were similar in both groups (Table 2). Post-operative superficial infection and dislocation rates were 0% in both groups (Table 2). The percentage of patients who had subsidence was not significantly different between the 2 groups (Table 2).

Discussion

In this study, cerclage cabling reduced the occurrence of PFF in patients undergoing cementless bipolar hip arthroplasty for unstable fractures of the femoral neck. To the best of our knowledge, this is the first study to investigate the efficacy of cerclage cabling in preventing PFF in this context. Previously, the incidence of PFF with cemented stems was reported to be 0.4 to 3.4% [25–28]; cabling may improve technique safety.

Previous studies have reported that cerclage cabling effectively prevents 2 types of fractures: iPPF and pPPF [29–31], and most iPPFs occur during stem insertion [12]. In the noncabling group in the present study, iPPF occurred during the stem insertion procedure in all patients. In contrast, iPPF was not observed in the cable group. The implementation of cerclage cabling for stem insertion may help reduce the incidence of iPPFs.

Undetectable iPPF may progress to pPPF after minor trauma. Although pPPF is caused by a combination of stem axial stress and rotational torque from falls [32,33], adding cerclage cabling to the femur improves resistance to hoop stress from stem subsidence and rotational torque [34,35]. Cerclage cabling may provide mechanical stability and reduce the rate of pPPF formation. A patient in the cabling group who had a pPPF could walk without reoperation, suggesting that cerclage cabling may minimize fracture line elongation owing to a PFF.

In this study, the cabling group exhibited a slight increase in the mean operative time (2 minutes) and mean blood loss volume (16 mL); however, these values were comparable to those of the noncabling group, suggesting that cabling may not affect the extent of procedure invasiveness. Moreover, no significant differences in superficial infection rates were observed between the 2 groups. Preoperative cable preparation helped minimize the risk of operative delays, suggesting that the overall use of cerclage cabling in

cementless bipolar hip arthroplasty for femoral neck fractures has minimum effects on surgical intervention. In fact, the procedure is simple and minimally invasive. Although the cost of this technique may increase in the short term, given the cost of the cables, it may be reduced in the long term when accounting for the costs of treating complications or performing reoperations. Our future studies aim to provide comparative estimates of these costs.

No significant differences in patient or surgical factors related to PFF [9,11,12] were observed between the 2 groups. The incidence of PFF in patients who did not have cerclage cabling was higher than that reported previously [36]. This discrepancy may be attributable to the involvement of early-career surgeons. Conversely, our findings strongly suggest that cerclage cabling is an effective method for preventing PFF and reoperation owing to PFF, even when performed by surgeons during the early stages of their careers.

This study had several potential limitations. The surgeries were performed by early-career surgeons. Therefore, the results may differ if expert surgeons perform the surgeries, and the effectiveness of cerclage cabling may be limited to expert surgeons who are skilled in performing these procedures. In addition, historical control data were analyzed. However, we believe that this should not affect the conclusions, as the 2 groups did not demonstrate differences in characteristics. Also, our investigation focused on a single stem type. Although circular cabling may be effective in preventing PFF with fit and fill stems, the effects of using other types of stems require further investigation. Furthermore, the observation period was relatively short. Nevertheless, most pPPFs occur within 1 month postoperatively [32], which is consistent with the duration of our study. Most fractures occurring within the first postoperative month may be associated with intraoperative occult fractures or stem subsidence; therefore, this study makes a major contribution to the literature. These limitations notwithstanding, this study suggests that cerclage cabling reduces the risk of pPPF and PFF or the consequent need for additional surgical intervention.

Conclusions

When a cementless stem is used to treat unstable femoral neck fractures, cerclage cabling effectively prevents iPPF and pPPF without increasing surgical time or blood loss volume. This method may help prevent PFF, which is a serious complication.

CRediT authorship contribution statement

Makoto Iwasa: Writing – review & editing, Writing – original draft, Investigation, Formal analysis, Data curation. **Wataru Ando:** Writing – review & editing, Supervision. **Kazuma Takashima:** Supervision, Data curation. **Keisuke Uemura:** Supervision, Data curation. **Hidetoshi Hamada:** Supervision, Data curation. **Nobuhiko Sugano:** Writing – review & editing, Supervision, Methodology, Conceptualization.

References

- [1] Lamb JN, Baetz J, Messer-Hannemann P, Adekanmbi I, van Duren BH, Redmond A, et al. A calcar collar is protective against early periprosthetic femoral fracture around cementless femoral components in primary total hip arthroplasty: a registry study with biomechanical validation. *Bone Joint J* 2019;101-B:779–86. <https://doi.org/10.1302/0301-620X.101B7-BJJ-2018-1422.R1>.
- [2] Gjertsen J-E, Baste V, Fevang JM, Furnes O, Engesaeter LB. Quality of life following hip fractures: results from the norwegian hip fracture register. *BMC Musculoskelet Disord* 2016;17:265. <https://doi.org/10.1186/s12891-016-1111-y>.
- [3] Raut S, Parker MJ. Medium to long term follow up of a consecutive series of 604 Exeter Trauma Stem Hemiarthroplasties (ETS) for the treatment of

- displaced intracapsular femoral neck fractures. *Injury* 2016;47:721–4. <https://doi.org/10.1016/j.injury.2015.10.077>.
- [4] Gullberg B, Johnell O, Kanis JA. World-wide projections for hip fracture. *Osteoporos Int* 1997;7:407–13. <https://doi.org/10.1007/pl000004148>.
 - [5] Kurtz S, Ong K, Lau E, Mowat F, Halpern M. Projections of primary and revision hip and knee arthroplasty in the United States from 2005 to 2030. *J Bone Joint Surg Am* 2007;89:780–5. <https://doi.org/10.2106/JBJS.F.00222>.
 - [6] Bhandari M, Devereaux PJ, Tornetta P, Swiontkowski MF, Berry DJ, Haidukewych G, et al. Operative management of displaced femoral neck fractures in elderly patients. An international survey. *J Bone Joint Surg Am* 2005;87:2122–30. <https://doi.org/10.2106/JBJS.E.00535>.
 - [7] Donaldson AJ, Thomson HE, Harper NJ, Kenny NW. Bone cement implantation syndrome. *Br J Anaesth* 2009;102:12–22. <https://doi.org/10.1093/bja/aen328>.
 - [8] Olsen F, Kotyra M, Houltz E, Ricksten S-E. Bone cement implantation syndrome in cemented hemiarthroplasty for femoral neck fracture: incidence, risk factors, and effect on outcome. *Br J Anaesth* 2014;113:800–6. <https://doi.org/10.1093/bja/aeu226>.
 - [9] Cooper HJ, Rodriguez JA. Early post-operative periprosthetic femur fracture in the presence of a non-cemented tapered wedge femoral stem. *HSS J* 2010;6:150–4. <https://doi.org/10.1007/s11420-010-9161-4>.
 - [10] Ravi B, Jenkinson R, Austin PC, Croxford R, Wasserstein D, Escott B, et al. Relation between surgeon volume and risk of complications after total hip arthroplasty: propensity score matched cohort study. *BMJ* 2014;348:g3284. <https://doi.org/10.1136/bmj.g3284>.
 - [11] Song J-H, Jo W-L, Lee K-H, Cho Y-J, Park J, Oh S. Subsidence and perioperative periprosthetic fractures using collarless hydroxyapatite-coated stem for displaced femoral neck fractures according to Dorr type. *J Orthop Surg (Hong Kong)* 2019;27:2309499019877530. <https://doi.org/10.1177/2309499019877530>.
 - [12] Abdel MP, Cross MB, Yassen AT, Haddad FS. The functional and financial impact of isolated and recurrent dislocation after total hip arthroplasty. *Bone Joint J* 2015;97-B:1046–9. <https://doi.org/10.1302/0301-620X.97B8.34952>.
 - [13] Dorr LD, Faugere MC, Mackel AM, Gruen TA, Bognar B, Malluche HH. Structural and cellular assessment of bone quality of proximal femur. *Bone* 1993;14:231–42. [https://doi.org/10.1016/8756-3282\(93\)90146-2](https://doi.org/10.1016/8756-3282(93)90146-2).
 - [14] Parker MJ, Cawley S. Cemented or uncemented hemiarthroplasty for displaced intracapsular fractures of the hip: a randomized trial of 400 patients. *Bone Joint J* 2020;102-B:11–6. <https://doi.org/10.1302/0301-620X.102B1.Bjj-2019-1041.R1>.
 - [15] Kristensen TB, Dybvik E, Kristoffersen M, Dale H, Engesæter LB, Furnes O, et al. Cemented or uncemented hemiarthroplasty for femoral neck fracture? Data from the Norwegian Hip Fracture Register. *Clin Orthop Relat Res* 2020;478:90–100. <https://doi.org/10.1097/CORR.0000000000000826>.
 - [16] Heckmann ND, Chen XT, Ballatori AM, Ton A, Shahrestani S, Chung BC, et al. Cemented vs cementless femoral fixation for total hip arthroplasty after displaced femoral neck fracture: a nationwide analysis of short-term complications and readmission rates. *J Arthroplasty* 2021;36:3667–3675.e4. <https://doi.org/10.1016/j.arth.2021.06.029>.
 - [17] Capello WN, D'Antonio JA, Jaffe WL, Geesink RG, Manley MT, Feinberg JR. Hydroxyapatite-coated femoral components: 15-year minimum followup. *Clin Orthop Relat Res* 2006;453:75–80. <https://doi.org/10.1097/01.blo.0000246534.44629.b2>.
 - [18] Khanuja HS, Vakili JJ, Goddard MS, Mont MA. Cementless femoral fixation in total hip arthroplasty. *J Bone Joint Surg Am* 2011;93:500–9. <https://doi.org/10.2106/JBJS.J.00774>.
 - [19] Pangaud C, Pauly V, Jacquet C, Orleans V, Boyer L, Khakha R, et al. Reduced mortality associated to cementless total hip arthroplasty in femoral neck fracture. *Sci Rep* 2023;13:16849. <https://doi.org/10.1038/s41598-023-43790-8>.
 - [20] Lo I-N, Tzeng Y-H, Wang C-S, Yang T-C, Lin C-C, Chiang C-C. Initial femoral stem position in cementless bipolar hemiarthroplasty for femoral neck fracture in elderly patients is associated with early implant subsidence: a radiographic analysis. *Injury* 2021;52:1801–6. <https://doi.org/10.1016/j.injury.2021.05.006>.
 - [21] Garden RS. Low-angle fixation in fractures of the femoral neck. *J Bone Joint Surg Br* 1961;43-B:647–63. <https://doi.org/10.1302/0301-620X.43B4.647>.
 - [22] Kelly M, Chen AF, Ryan SP, Working ZM, Porter KR, De A, et al. Cemented femoral fixation in total hip arthroplasty reduces the risk of periprosthetic femur fracture in patients 65 years and older: an analysis from the American Joint Replacement Registry. *J Arthroplasty* 2023;38:S351–4. <https://doi.org/10.1016/j.arth.2023.04.039>.
 - [23] Faul F, Erdfelder E, Lang A-G, Buchner A. C*Power 3: a flexible statistical power analysis program for the social, behavioral, and biomedical sciences. *Behav Res Methods* 2007;39:175–91. <https://doi.org/10.3758/bf03193146>.
 - [24] Loudon JR, Older MW. Subsidence of the femoral component related to long-term outcome of hip replacement. *J Bone Joint Surg Br* 1989;71:624–8. <https://doi.org/10.1302/0301-620X.71B4.2768310>.
 - [25] Joanroy R, Stork-Hansen J, Rotwitt L, Viberg B. Cemented hemiarthroplasty for femoral neck fracture patients: collarless, polished tapered stem (CPT) versus anatomic matte stem (Lubinus SP2). *Eur J Orthop Surg Traumatol* 2021;31:855–60. <https://doi.org/10.1007/s00590-021-02948-8>.
 - [26] Song JSA, Dillman D, Wilson D, Dunbar M, Richardson G. Higher periprosthetic fracture rate associated with use of modern uncemented stems compared to cemented stems in femoral neck fractures. *Hip Int* 2019;29:177–83. <https://doi.org/10.1177/1120700018772291>.
 - [27] Barenius B, Inngul C, Alagic Z, Enocson A. A randomized controlled trial of cemented versus cementless arthroplasty in patients with a displaced femoral neck fracture: a four-year follow-up. *Bone Joint J* 2018;100-B:1087–93. <https://doi.org/10.1302/0301-620X.100B8.Bjj-2017-1593.R1>.
 - [28] Gausden EB, Cross WW, Mabry TM, Pagnano MW, Berry DJ, Abdel MP. Total hip arthroplasty for femoral neck fracture: what are the contemporary reasons for failure? *J Arthroplasty* 2021;36:S272–6. <https://doi.org/10.1016/j.arth.2021.02.008>.
 - [29] Herzworm PJ, Walsh J, Pettine KA, Ebert FR. Prophylactic cerclage: a method of preventing femur fracture in uncemented total hip arthroplasty. *Orthopedics* 1992;15:143–6. <https://doi.org/10.3928/0147-7447-19920201-06>.
 - [30] Waligora AC, Owen JR, Wayne JS, Hess SR, Golladay GJ, Jiranek WA. The effect of prophylactic cerclage wires in primary total hip arthroplasty: a biomechanical study. *J Arthroplasty* 2017;32:2023–7. <https://doi.org/10.1016/j.arth.2017.01.019>.
 - [31] Wongsak S, Sa-Ngasoongsong P, Pinitkwamdee S, Thongchuea N, Prasai AB, Warinsiriruk E, et al. Effectiveness of prophylactic double-looped wiring in cementless Hip arthroplasty: a biomechanical study in osteoporotic bone model using impaction simulation system. *Injury* 2022;53:2454–61. <https://doi.org/10.1016/j.injury.2022.05.034>.
 - [32] Gromov K, Bersang A, Nielsen CS, Kallemose T, Husted H, Troelsen A. Risk factors for post-operative periprosthetic fractures following primary total hip arthroplasty with a proximally coated double-tapered cementless femoral component. *Bone Joint J* 2017;99-B:451–7. <https://doi.org/10.1302/0301-620X.99B4.Bjj-2016-0266.R2>.
 - [33] Jørgensen CC, Kehlet H, Lundbeck Foundation Centre for Fast-track Hip and Knee Replacement Collaborative Group. Fall-related admissions after fast-track total hip and knee arthroplasty - cause of concern or consequence of success? *Clin Interv Aging* 2013;8:1569–77. <https://doi.org/10.2147/CIA.S52528>.
 - [34] Lenz M, Perren SM, Richards RG, Mückley T, Hofmann GO, Gueorguiev B, et al. Biomechanical performance of different cable and wire cerclage configurations. *Int Orthop* 2013;37:125–30. <https://doi.org/10.1007/s00264-012-1702-7>.
 - [35] Augat P, Bliven E, Hackl S. Biomechanics of femoral neck fractures and implications for fixation. *J Orthop Trauma* 2019;33:S27–32. <https://doi.org/10.1097/BOT.0000000000001365>.
 - [36] Yoon B-H, Lee Y-K, Jo W-L, Ha Y-C, Choi D-H, Koo K-H. Incidence and risk period of periprosthetic femoral fracture after cementless bipolar hemiarthroplasty in elderly patients. *J Arthroplasty* 2016;31:1326–30. <https://doi.org/10.1016/j.arth.2015.12.030>.