



Impact of osteoporosis and osteoporosis medications on fracture healing: a narrative review

M. Chandran¹ · K. E. Akesson² · M. K. Javaid³ · N. Harvey⁴ · R. D. Blank^{5,6} · M. L. Brandi⁷ · T. Chevalley⁸ · P. Cinelli⁹ · C. Cooper^{10,11} · W. Lems¹² · G. P. Lyritis¹³ · P. Makras¹⁴ · J. Paccou¹⁵ · D. D. Pierroz¹⁶ · M. Sosa¹⁷ · T. Thomas¹⁸ · S. Silverman¹⁹ · Fracture Working Group of the Committee of Scientific Advisors of the International Osteoporosis Foundation, on behalf of the International Osteoporosis Foundation, Société Internationale de Chirurgie Orthopédique et de Traumatologie

Received: 10 October 2023 / Accepted: 6 March 2024 / Published online: 8 April 2024
© The Author(s) 2024

Abstract

Summary Antiresorptive medications do not negatively affect fracture healing in humans. Teriparatide may decrease time to fracture healing. Romosozumab has not shown a beneficial effect on human fracture healing.

Background Fracture healing is a complex process. Uncertainty exists over the influence of osteoporosis and the medications used to treat it on fracture healing.

Methods Narrative review authored by the members of the Fracture Working Group of the Committee of Scientific Advisors of the International Osteoporosis Foundation (IOF), on behalf of the IOF and the Société Internationale de Chirurgie Orthopédique et de Traumatologie (SICOT).

Results Fracture healing is a multistep process. Most fractures heal through a combination of intramembranous and endochondral ossification. Radiographic imaging is important for evaluating fracture healing and for detecting delayed or non-union. The presence of callus formation, bridging trabeculae, and a decrease in the size of the fracture line over time are indicative of healing. Imaging must be combined with clinical parameters and patient-reported outcomes. Animal data support a negative effect of osteoporosis on fracture healing; however, clinical data do not appear to corroborate with this. Evidence does not support a delay in the initiation of antiresorptive therapy following acute fragility fractures. There is no reason for suspension of osteoporosis medication at the time of fracture if the person is already on treatment. Teriparatide treatment may shorten fracture healing time at certain sites such as distal radius; however, it does not prevent non-union or influence union rate. The positive effect on fracture healing that romosozumab has demonstrated in animals has not been observed in humans.

Conclusion Overall, there appears to be no deleterious effect of osteoporosis medications on fracture healing. The benefit of treating osteoporosis and the urgent necessity to mitigate imminent refracture risk after a fracture should be given prime consideration. It is imperative that new radiological and biological markers of fracture healing be identified. It is also important to synthesize clinical and basic science methodologies to assess fracture healing, so that a convergence of the two frameworks can be achieved.

Keywords Fracture healing · Osteoporosis · Osteoporosis medication · Union

Introduction

A recent fracture is a powerful risk factor for a subsequent fracture [1]. Therefore, it is imperative that osteoporosis treatment be initiated very soon after an incident fracture to decrease imminent fracture risk. However, a theoretical concern about potential deleterious effects of osteoporosis medications on fracture healing exists amongst the medical

K. E. Akesson and M. K. Javaid are joint second authors.

This manuscript has been endorsed by the Committee of Scientific Advisors of the International Osteoporosis Foundation (IOF).

Extended author information available on the last page of the article

and surgical community. In addition, patients being treated for osteoporosis still experience fractures. Whether to continue or discontinue osteoporosis therapy at that juncture is also an oft-asked clinical question.

Though the majority of fractures heal uneventfully, delayed- or non-healing (union) of fractures is estimated to occur in about 5–15% of cases, with numbers varying depending on anatomical location and other factors such as age [2]. The financial burden associated with non-union of fractures is huge [3, 4]. Potential complications that can arise from a poorly healed fracture include malunion, non-union, chronic pain, joint stiffness, and secondary osteoarthritis [5]. Other significant consequences from non-union of fractures which have been reported in high-risk groups such as veterans with spinal cord injury include risks of pressure sores, osteomyelitis, and subsequent amputation [6]. Understanding fracture healing and the consequences of delayed or non-healing of fractures as well as the cost savings that can potentially be obtained with appropriate treatment is thus critical for healthcare providers since they can thus better assess and manage fractures in their patients. Understanding fracture healing also allows healthcare providers to educate their patients about the complications that can arise from non-union/delayed union and the importance of compliance with treatment, such as immobilization or physical therapy.

This narrative review authored by members of the Fracture Working Group of the International Osteoporosis Foundation's (IOF) Committee of Scientific Advisors, on behalf of the IOF and the Société Internationale de Chirurgie Orthopédique et de Traumatologie (SICOT), aims to shed comprehensive light on the basic biological processes involved in fracture healing and the evidence linking fracture healing with osteoporosis and the medications currently available to treat it. Since this review focuses on the effect of currently available osteoporosis medications on osteoporotic fracture healing, we will not be discussing atypical fracture healing, the role of agents such as bone morphogenetic protein and local osteo enhancement procedures (LOEP) on fracture healing, or the principles of fracture fixation. This review also assumes that any given fracture can readily be designated as “osteoporotic” or “non-osteoporotic” appropriately. Differentiating between the two is both challenging and important; however, it is beyond the scope of the article.

Biology of fracture healing

The mechanistic and cellular processes underlying the healing of a fracture are complex. It is a continuous biological phenomenon that occurs through an exquisitely orchestrated series of events that follow in general, a temporal and spatial sequence with stages that are important to note, overlap substantially. These stages include inflammation, repair, and

remodelling, and the entire process requires the coordinated efforts of multiple cell types and biochemical signals.

Fracture healing may either be *indirect* or *direct*, or a *combination of the two*. *Indirect (secondary)* fracture healing occurs in situations where fracture fragments can potentially move as occurs after external fixation or intramedullary nailing, or when there is a significant gap between the fracture fragments as when the fracture is left untreated. In this process, there is abundant callus formation, and the bone fragments are bridged initially by new bone that is formed via *endochondral ossification that mimics de novo formation of embryonic bone*. This process of indirect fracture healing is complex and involves multiple steps [7, 8]. It begins with the *reaction phase*, where immediately after trauma, the hematoma that forms attracts inflammatory cells such as neutrophils to the site of injury. Platelets, erythrocytes, granulocytes, and lymphocytes form a clot that serves as a provisional fibrin matrix. Neutrophils are replaced by monocytes which then differentiate into macrophages. This reaction phase lasts for a few days. The hematoma is critically important to healing, with experimental removal of the hematoma shown to result in delay or non-union in animal models [9]. The subsequent *repair phase*, which can last several months progresses through several steps beginning with macrophages phagocytosing dead cells and debris, and secreting signalling molecules such as tumor necrosis factor-alpha (TNF- α), interleukin-1 (IL-1), interleukin-6 (IL-6), transforming growth factor β (TGF β), and angiogenic factors. These growth factors recruit mesenchymal stem cells (MSCs) which differentiate into pre-hypertrophic chondrocytes, endothelial cells, and osteoblasts. In response to interfragmentary strain, pre-hypertrophic chondrocytes produce a type II collagen-rich matrix [10, 11]. Once strain is reduced to a sufficient degree, the pre-hypertrophic chondrocytes enlarge to form hypertrophic chondrocytes that promote vascular ingress by producing cytokines and growth factors and create a supportive scaffolding for osteoblastic influx. The hypertrophic chondrocytes release microvesicles coated with alkaline phosphatase that hydrolyses pyrophosphate—the principal inhibitor of hydroxyapatite formation [12]. The microvesicles also contain vascular endothelial growth factor (VEGF) which promotes angiogenesis, bone morphogenetic protein-2 (BMP-2) [13] as well as nanohydroxyapatite, a seed crystal for microhydroxyapatite [14]. VEGF draws vascular endothelial cells into the collagen-rich cartilaginous matrix [15, 16]. Osteoblasts accumulate along with the endothelial cells. Once within the unique bone-forming micro-ecosystem, osteoblasts produce type I collagen, hydroxyapatite, BMP-2, and additional VEGF [17, 18]. Platelet-derived factors such as platelet-derived growth factor (PDGF), VEGF, TGF β , and insulin-like growth factor 1 (IGF1) promote both MSC differentiation as well as early osteoblastic and chondrocyte cell production. Osteoblasts differentiate and promote the deposition of microhydroxyapatite

on the cartilaginous matrix forming a *chondroid soft callus* that bridges the fracture. There presumably is a maximum tolerable instability and a required minimal degree of strain for induction of callus formation [19]. In contrast, if the strain is too high, chondrocyte stabilization, hypertrophy, and bony union may be prevented leading to pseudoarthrosis [8].

In parallel with the chondroid soft callus formation by the osteoblasts, osteoclast recruitment and infiltration commence, the osteoclasts resorb the soft callus, and the osteoblasts gradually through deposition of new bone replace the *soft callus with hard bone*. Subsequently, mineralization of type 1 collagen and bone substitution results in the formation of *woven bone* which is further remodelled to mature and structurally efficient *lamellar bone* with a reduction in hard callus volume. Osteoclasts play a vital role in bone callus remodelling [20]. Osteoclast-deficient mice and mice treated with osteoprotegerin (an inhibitor of osteoclastogenesis) or bisphosphonates (inhibitors of osteoclast function) do not demonstrate any delay in fracture union but show significant inhibition of hard callus remodelling. Woven bone in the hard callus is structurally less efficient compared to remodelled lamellar bone, but it has a larger cross-sectional area and thus similar mechanical properties [21–23]. Coupled cycles of osteoblast and osteoclast activity then happen, with resultant remodelling of the callus tissues to the bone's original cortical structure and the marrow space is also re-established.

A pictorial representation of the process of indirect healing is presented in Fig. 1. *Of note, this is a simplified portrayal since it is impossible to stringently delineate the transition from one stage to another.*

Direct (primary) healing occurs in situations where the fractured segments of the bone are in absolute proximity to each other by virtue of being exactly anatomically reduced—operatively or non-operatively and fixed rigidly. In this process, a cartilaginous scaffold is not necessary, and the bony fragments are directly bridged by new bone formed by *intramembranous ossification*. The fracture site is remodelled by the cortex directly attempting to reestablish new Haversian systems and involves the harnessing of osteoclasts to form discrete remodelling units known as cutting cones. These osteoclastic cutting cones cross the fracture line bringing vascular endothelial cells (which differentiate into blood vessels) and perivascular mesenchymal cells (which are osteoprogenitors and differentiate into osteoblasts) in their wake that fill the canals with bone thus securing mechanical continuity [24, 25]. The source of the vascular endothelial cells and perivascular mesenchymal cells appears to be the cortical bone underlying the fracture site, the periosteum adjacent to the fracture, and the bone marrow within the fracture site [24]. A pictorial representation of the process of direct fracture healing is provided in Fig. 2.

Theoretically, fractures that are rigidly fixed, heal through primary union and formation of new bone by intramembranous ossification, and at the other end, fractures with large defects and disproportionate interfragmentary strain will require a cartilage intermediate and will heal almost entirely through endochondral ossification. *However, in reality, the majority of fractures employ a combination of intramembranous and endochondral ossification* [8]. Even in the most closely approximated fracture, there may be areas of avascular necrosis and strain that cause chondrocyte stimulation which result in some endochondral ossification. Similarly, even in maximally displaced fractures, if a degree of periosteal blood supply has remained intact, areas of intramembranous ossification may occur. The complete temporal and spatial patterns of revascularization in displaced versus stabilized fractures have been elegantly demonstrated through a reproducible murine femur fracture model by Yuasa et al. [26].

Clinical and radiological evaluation of fracture healing

Determining whether a fracture has healed affects patient management decisions, including when to recommend weight bearing, the type of activity allowed, as well as whether further hardware placement and/or revisions are needed. However, a lack of consensus exists as to what the exact imaging and clinical criteria to conclusively demonstrate fracture healing are, as well as in how to define delayed and non-union. A combination of clinical and radiological measures was found to define healing in 62% of published studies, while radiological criteria alone were used to define it in the remaining publications in a systematic review and meta-analyses of the orthopedic literature [27]. Twelve clinical and 11 different radiographic criteria were identified in this systematic review. The assessment of fracture healing thus typically should involve a combination of clinical examination, patient-reported outcomes, radiographic imaging, and, in some cases, more advanced imaging techniques such as computed tomography (CT).

Fracture healing time differs depending on the fracture site and type, the anatomical location and complexity, as well as the biomechanical demands of the affected fracture site. Most metaphyseal long bone fractures heal in 6–8 weeks and vertebral fractures in 8–10 weeks, whereas diaphyseal fracture of long bones may take up to 3–4 months.

Indications of fracture healing on physical examination include the absence of pain or tenderness at the fracture site on palpation and the ability to weight bear without pain. However, these are subjective measures as individual and cultural differences in pain perception and tolerance exist.

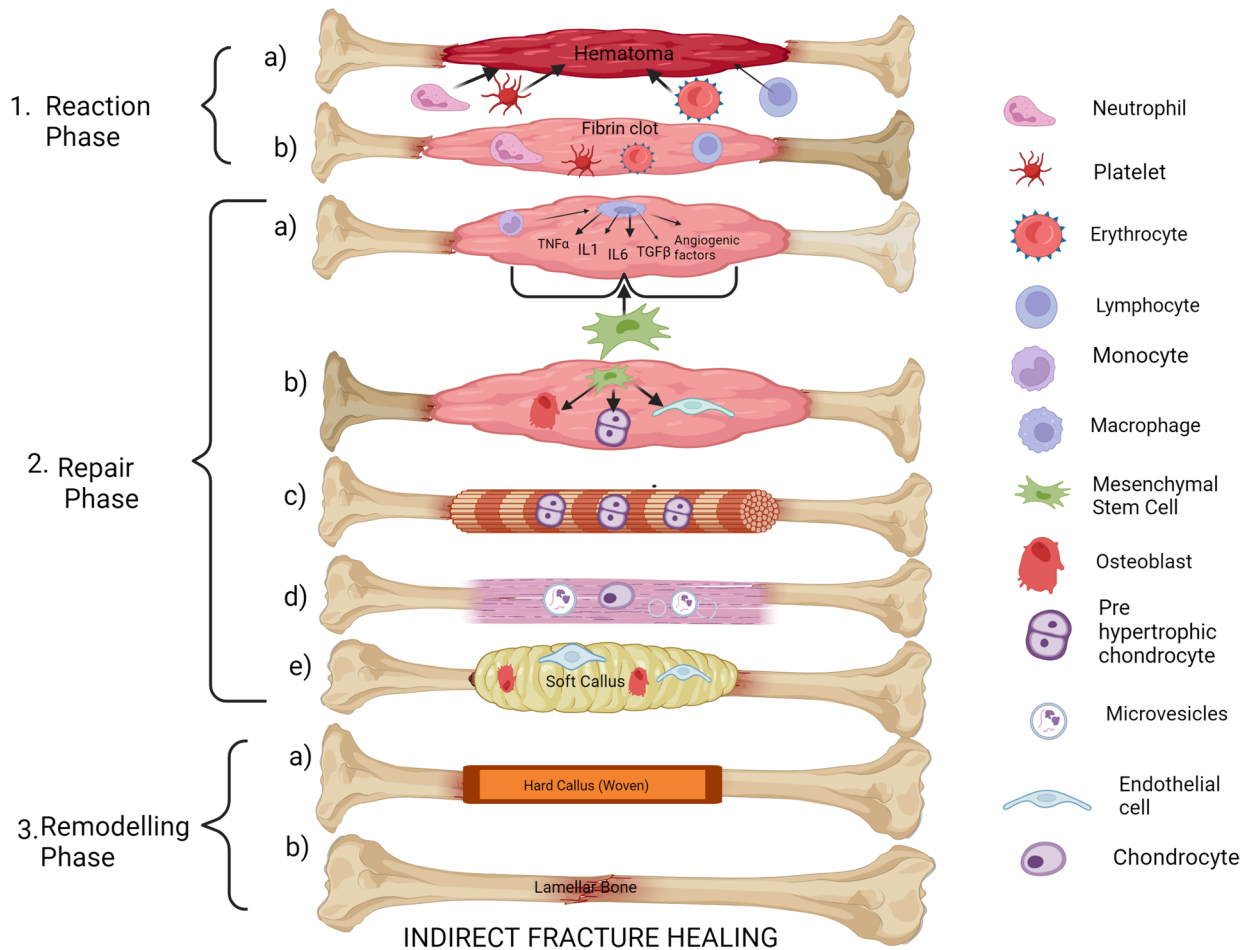


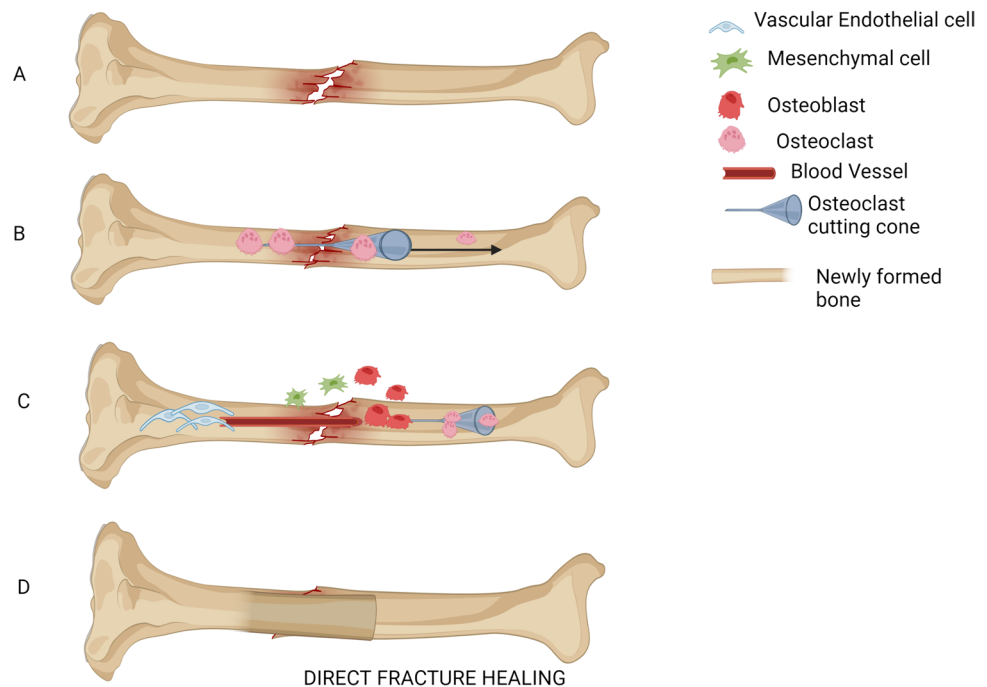
Fig. 1 Indirect fracture healing. (1) Reaction phase: (a) Hematoma attracts inflammatory cells. (b) Neutrophils, platelets, erythrocytes, and lymphocytes form fibrin clot. (2) Repair phase: (a) Neutrophils are replaced by monocytes that transform to macrophages. Macrophages secrete tumor necrosis factor α (TNF- α), interleukin-1 (IL-1), interleukin-6 (IL-6), transforming growth factor β (TGF- β), and angiogenic factors. These recruit mesenchymal stem cells (MSC). (b) MSC differentiate to osteoblasts, prehypertrophic chondrocytes, and endothelial cells. (c) Prehypertrophic chondrocytes form collagen rich matrix. (d) Prehypertrophic chondrocytes enlarge to hypertrophic

chondrocytes which release microvesicles coated with alkaline phosphatase and which has vascular endothelial growth factor (VEGF), bone morphogenic protein 2 (BMP2), and nanohydroxyapatite. (e) VEGF draws endothelial cells derived from MSC. Osteoblasts also accumulate. Osteoblasts promote deposition of microhydroxyapatite on cartilaginous matrix to form soft callus. (3) Remodelling phase: (a) Osteoclasts resorb soft callus. Osteoblasts deposit new bone and mineralization occurs to form Hard Woven Callus. (b) Further osteoclastic remodelling occurs to form lamellar bone

A basic knowledge of the radiologic signs of fracture healing is necessary to understand the studies exploring the effect of osteoporosis medications on fracture healing that will be subsequently alluded to in this article. In general, radiographic signs of fracture healing include the presence of callus formation, the presence of bridging trabeculae across the fracture site, and a decrease in the size of the fracture line over time. Animal osteotomy experiments have been used to validate these radiological findings against the biomechanics of fracture healing such as dynamic torsion performance and cortex to callus ratio with stiffness [28, 29]. Several scoring systems have been developed to assess fracture healing including modifications of the Radiographic Union Score in Tibial fractures (RUST) score which has a

number for each of four bridged cortices based on the presence or absence of callus and fracture line visibility [30]. The score is based on the degree of callus formation, bridging callus, and remodelling observed on radiographs. The RUST score ranges from 0 to 12, with higher scores indicating better healing. A score of 10 or higher is typically considered to indicate radiographic union. The RUSH (Radiographic Union Score for Hip) score is a similar scoring system used to assess fracture healing in femoral neck and intertrochanteric fractures [31]. In addition to the standard scoring algorithm of the RUST score, the RUSH score also adds evaluation of trabecular consolidation and trabecular fracture line disappearance—these signs of fracture healing being especially important for proximal femur stability.

Fig. 2 Direct fracture healing occurs when the fracture fragments are in proximity to each other. Bone fragments are directly bridged by new bone formed by intramembranous ossification for which initially, osteoclasts are harnessed to form cutting cones. These cutting cones cross the fracture line, bringing in their wake, vascular endothelial cells that differentiate into blood vessels and perivascular mesenchymal cells that differentiate into osteoblasts which then fill the canals with bone



The RUSS (Radius Union Scoring System) score is used to assess fracture healing in distal radius fractures [32]. An exhaustive review of the radiographic signs and advantages and disadvantages of each scoring system is beyond the scope of this article, and the reader is referred to an excellent overview of the subject [33].

Delayed union is typically defined as a lack of radiographic evidence of healing at 3–6 months after injury, while non-union is defined as a lack of healing at 9 months or more [34, 35]. However, the exact definition of delayed union and non-union can vary depending on the location and type of fracture. Radiographic signs of delayed union or non-union include persistent fracture lines, lack of callus formation, or evidence of resorption of previously formed callus. In cases of non-union, there may also be evidence of bone resorption or fragmentation at the site of the fracture. CT scanning may be useful in cases where X-ray imaging is inconclusive or when more detailed information is needed about the location and extent of the non-union [36].

As important as assessment of fracture union is the evaluation of the early healing process to predict ultimate union or non-union. Indices that combine patient characteristics, functional assessments, patient-reported outcome scores, and radiographic parameters such as the QuickDash score for clavicle fracture [37], Radiographic Union Score for Humeral fractures (RUSHU) in combination with degree of mobility of the fracture site [38, 39], the Tibial Fracture Healing Score (TFHS) [40], and the Nonunion Risk Determination (NURD) score [41] have been developed. Such scores, when used appropriately, can provide an early time point for counselling patients on the likelihood of union of

their fracture. For example, a QuickDash score greater than or equal to 40, fracture movement on clinical exam, and lack of callus on X-ray examination at 6 weeks were identified as risk factors for subsequent non-union of clavicle fractures by Nicholson et al. [37].

In addition to indices utilizing clinical and radiographic parameters, biochemical markers may be used to predict non-union. Examples of such patient-specific biomarkers include subsets of terminally differentiated CD8+ effector memory T cells in peripheral blood that have been used to predict delayed fracture healing in proximal tibia fractures [42]. Changes in the serum proteome have been observed during fracture healing in a murine model [43], and several biomarkers including that associated with inflammation have been found in proteomics studies to be up or down-regulated in patients with non-union as compared to controls [44], thus shedding some light on new markers that could represent a deleterious effect on bone healing through the enhancement of a persistent and non-resolving inflammatory process.

In summary, radiographic imaging is an important tool for evaluating fracture healing and for detecting delayed union or non-union. The presence of callus formation, bridging trabeculae, and a decrease in the size of the fracture line over time are typically indicative of healing, while persistent fracture lines or lack of callus formation denote delayed union or non-union. However, imaging must be combined with clinical parameters as well as patient-reported outcomes for optimal assessment of fracture healing. Likewise, non-union prediction models must be multifactorial to offer the best prognostic value.

The impact of osteoporosis on fracture healing

Risk factors for non-union can be either patient-dependent factors such as age, tobacco and alcohol abuse, non-steroidal anti-inflammatory drug use, malnutrition, diabetes, vascular disease, previous radiation therapy, hypothyroidism, and vitamin D deficiency *or* fracture- or injury-related factors such as comminution, poor cortical apposition, interposed soft tissue, soft tissue damage, bone loss, quality of surgical treatment, and infection [45].

Whether osteoporosis contributes to fracture non-union or delayed union is controversial. Impaired fracture healing in the presence of osteoporosis may be due to altered biomechanical properties of the osteoporotic bone with such bones having not only reduced bone mass but decreased cortical thickness and increased cortical porosity, trabecular disorientation with regard to the direction of loading, and alterations in bone matrix composition [46–49]. Bone cells in osteoporosis may have impaired response vis-à-vis cell proliferation and release of TGF- β and nitric oxide to mechanical stress. This was shown in a study in which bone cells from donors with osteoporosis were found to differ in their response to cyclic strain [50].

Though it appears intuitive that osteoporosis is likely to have a significant impact on fracture healing, obtaining definitive evidence to substantiate this assumption has been difficult for many reasons. (1) Osteoporosis is an age-related disorder and since aging is also associated with impaired fracture healing through multiple other molecular, cellular, and systemic factors [51], it is difficult to separate the influence of aging from that of osteoporosis on fracture healing. (2) Osteoporosis is also associated with several other comorbidities including diabetes and other endocrine conditions which may all directly or indirectly affect the fracture healing process. Additionally, which animal model of osteoporosis should be employed in pre-clinical studies of osteoporosis and fracture healing and whether any of those models are applicable to humans is still unclear. Therefore, many assumptions must be made without the benefit of hard evidence. *Osteoporotic fractures in humans are typically located in metaphyseal regions of bones while the preponderance of animal data has been obtained from diaphyseal models of induced fracture.* There is evidence to show that differences in bone healing exist between the metaphyseal and diaphyseal regions of long bones with less periosteal callus formation in the metaphysis than in the diaphysis [52]. Also, most studies have considered the formation of bony callus with bridging as the end point of fracture healing, whereas evaluation of the subsequent remodelling phase has rarely been performed. It is thus important to understand these limitations before interpreting the studies exploring the impact of osteoporosis on fracture healing.

Animal studies

Animal models that incorporate ovariectomy in combination with a low-calcium diet are most likely to be representative of post-menopausal osteoporotic bone. Those models in which complete bone discontinuity has been achieved via complete osteotomies better mimic clinical fractures in humans rather than models in which drill hole defects or partial osteotomies have been done since the two heal differently [53, 54].

A systematic review and meta-analysis conducted in 2016 that explored 26 ovariectomized rat model studies specifically examining biomechanical recovery in osteoporosis showed disruption in either the anabolic or catabolic phases of healing with prolonged healing time and lower maximum load, i.e., a decrease in the biomechanical properties [55]. In another systematic review and meta-analysis that investigated 18 prospective studies with ovariectomized rodent and sheep models, less of callus and new bone formation, less of bone mineralization, decreased biomechanical strength, and delay in the cellular differentiation process of chondrocytes were found in the osteoporotic animals. However, no evidence of radiological delay in femoral fracture healing was observed [55].

Very few studies have explored the middle and late phases of fracture healing in osteoporotic models. In one such model, in the ovariectomized rat (i.e., osteoporotic) group, endochondral bone formation was delayed, more osteoclast cells were seen around the trabecula, and the new bone trabecula was found to be arranged loosely and irregularly [56]. More recent animal studies that simulate the characteristic metaphyseal fractures that are seen in human osteoporosis also suggest that fracture healing of osteoporotic bone produces bone of lower mechanical strength [57] with one study showing poorly mineralized callus formation in the osteoporotic animals compared to controls [58].

Overall, the animal studies appear to support the view that osteoporosis negatively influences fracture healing. However, as mentioned earlier, the findings must be interpreted with caution given the wide variation in the experimental parameters, the osteoporosis model used, fracture type and animal used, and the definition of osteoporosis that was employed.

Clinical studies

Clinical studies of fracture healing in osteoporosis have yielded conflicting results. Osteoporosis has been identified as a risk factor for non-union in two large database prospective studies, one—an analysis of a national insurance database that included 56,492 fractures [59] and the other an analysis of patient-level health claims with 309,330 fractures

[60]. This latter study included the use of anti-osteoporosis medications as a variable in their analysis. It must be noted that there were several confounding factors in these two ‘big data’ studies including the fact that they relied on claims by patients, coding was imprecise, prospective follow-up was not for a specific outcome, and there were missing data. In contrast to these large database studies in which likely the power of big data-analysis was evident, in a small, matched case–control prospective study of 40 patients with fracture non-union and 80 controls without fracture non-union, no correlation between osteoporosis and non-union was found [61]. In another retrospective small study on patients with femoral shaft fracture, 29 patients with radiological evidence of osteoporosis detected using the Singh Index (a simple, semiquantitative evaluation tool for diagnosing osteoporosis with plain radiographs of the proximal femur [62]) and 37 subjects without osteoporosis, found a statistically significant prolonged union time of 19.38 ± 5.9 weeks as opposed to 16.9 ± 5.7 weeks and more delayed unions (10/29 vs 4/37) in the patients with osteoporosis. However, it was noted that fractures healed within 32 weeks in both the osteoporotic and non-osteoporotic groups [61]. No evidence that osteoporosis was associated with delayed or non-union was found in another small retrospective study on subcapital humerus and distal radius fractures though a trend towards a negative association was seen [63].

In summary, clinical studies investigating the potential association between osteoporosis and delayed fracture healing or non-union are overall insufficient in providing clear evidence. This reflects a gap in knowledge but also the difficulties in designing and performing such studies.

Effect of osteoporosis medications on fracture healing

Bisphosphonates

Bisphosphonates are preferentially incorporated into sites of active bone remodelling [64]. When bone containing a bisphosphonate is resorbed, the bisphosphonate is released in the acidic lacuna created by the osteoclast and attaches to hydroxyapatite binding sites on the osteoclast cell surface. The non-nitrogen-containing bisphosphonates induce apoptosis in the osteoclast by incorporating into ATP and thereby causing a decrease in their number. Nitrogen-containing bisphosphonates inhibit farnesyl pyrophosphate synthase (FPPS) a key enzyme in the mevalonate pathway. This causes cytoskeletal changes in the osteoclast resulting in inhibition of its activity or induction of its apoptosis [65]. Given that osteoclastic bone resorption is an important step in fracture repair, and because the calculated half-life of elimination of bisphosphonates is up to 10 years, justified questions have

risen about their effect on fracture healing both where there has been previous use of these agents as well as if they are initiated immediately after a fracture [66, 67]. Histological and microCT analysis of a rat fracture model have shown that zoledronic acid-treated calluses had a distinctive internal structure consisting of an intricate network of retained trabecular bone, with the timing of the dose of zoledronic acid playing an important role in the modulation of callus properties. Delaying the dose of zoledronic acid produced a larger and stronger callus in this study [66]. Theoretical concerns also exist over whether the possible preferential deposition of oral and intravenous bisphosphonates at the site of an acute fracture can have a clinically significant impact on fracture healing and whether this would make them less available for the rest of the osteoporotic skeleton.

Animal studies

Several animal models have been used to examine the effects of bisphosphonates on fracture healing in both osteoporotic and non-osteoporotic models, though it must be pointed out that most of them have been on the impact of bisphosphonates on *indirect fracture healing*, i.e., healing with callus formation. Overall, the studies suggest that bisphosphonate administration does not interfere with the formation of the callus itself but decreases the remodelling of the callus with resultant retention of the cancellous bone structure, leading to greater callus volume. A delay in the conversion of the woven bone at the fracture site to mature lamellar bone occurs. The callus has increased biomechanical strength also. This may be due to the retention of trabecular elements in the callus and/or increased fracture bridging. Some of the pertinent studies that show the effect of bisphosphonates on indirect fracture healing in animal models are shown in Table 1.

Direct fracture healing

Bisphosphonates seem to have a different effect on fractures that undergo rigid internal fixation and thus direct healing. In a rat model, where an osteotomy was rigidly fixed, Savaridas et al. showed that ibandronate given 3 weeks prior to the fracture resulted in impairment in progression to fracture union, a reduction in mean stress at failure and a decrease in BMD at the osteotomy site as well the persistence of cartilage-like tissue and undifferentiated mesenchymal tissue at the osteotomy site [78].

In summary, the concerns that administration of a long-acting bisphosphonate shortly after a fracture will, because of it binding preferentially to the remodelling surfaces of the skeleton, make it unavailable for the rest of the skeleton, and cause delay in callus evolution, changes in its morphology and make it more fragile have largely been assuaged by

Table 1 Studies of bisphosphonates on animal models of indirect fracture healing

Study	Animal model	Bisphosphonate	Findings
Fu et al. [68]	Ovariectomized rats with femur fractures	Alendronate	Larger fracture callus Delayed conversion of woven bone to lamellar bone Mechanical properties of callus similar to control animals
Manabe et al. [69]	Ovariectomized rats with femur fractures	Ibandronate	Extending dosing interval can mitigate the delay of conversion of woven bone to lamellar bone
Kidd et al. [70]	Rats with ulnar fractures	High and low dose Risedronate	Delay in healing with high dose but not with low dose No interference in callus formation with either high or low dose
Yu et al. [71]	Mice with mandibular and tibial fractures	Zoledronic acid	Delay in cartilage hypertrophy and in angiogenesis during early fracture repair. Delay in remodelling of callus in late fracture repair- more pronounced in mandible than in tibia
Tatli et al. [72]	Rabbits with mandibular fractures	Zoledronic acid	Acceleration of fracture healing
Bosemark et al. [73]	Rat femur autologous graft	Zoledronic acid + bone morphogenetic protein 7 (BMP7)	Increase in callus volume and fourfold increase in mechanical strength (force at failure) at healed fracture site compared to controls. Callus volume and force at failure were double in the combination group compared to BMP alone
Doi et al. [74]	Rat femur fracture model	Zoledronic acid + BMP 2	Zoledronic acid alone or combination resulted in greater ultimate load at failure and greater stiffness than controls or BMP2 alone
Gerstenfeld et al. [75]	Male non osteoporotic mice with tibial fractures	Alendronate vs denosumab	Alendronate delayed fracture healing, while denosumab did not
Mashiba et al. [76]	Dogs with rib fractures	Alendronate	Reduced biomechanical properties and increased microdamage accumulation
Amanat et al. [66]	Female rats with tibial fractures	Zoledronic acid	No delay in fracture healing with bolus or weekly dosing, but weekly dosing delayed hard callus remodelling. Delaying dose to 1 or 2 weeks post-fracture improved mechanical strength and produced larger and stronger callus
Li et al. [77]	Growing rats with femoral shaft fracture	Incadronate	No effect on radiographic, morphometric, or mechanical parameters post-fracture when administered prior to fracture and stopped. Increased callus formation and delayed healing but paradoxical higher mechanical strength when administration continued post-fracture

findings in most animal studies. In fact, paradoxically, there appears to be an improvement in mechanical properties of the callus. Inhibiting bone resorption with bisphosphonates at the time of fracture does not appear to be harmful to callus strength.

Clinical studies

The concern whether bisphosphonates could, through bone turnover suppression, delay fracture healing was first raised

by Odvina et al. [79]. In their case series of nine patients with osteoporosis or osteopenia on chronic alendronate treatment, all patients developed incident non-traumatic fractures involving skeletal areas that are rich in cortical bone, with fractures occurring at atypical sites such as femoral shafts, pubic bone, and ischium. Bone biopsy data in these patients showed severe suppression of bone turnover, with reduced or absent osteoblastic surface. Matrix synthesis was markedly diminished, with absence of double tetracycline label and absent or reduced single-tetracycline label. The same trend

was seen in the intracortical and endocortical surfaces. Six out of the nine patients displayed either delayed or absent fracture healing during therapy. However, it must be noted that this study was limited by the lack of a control group, and therefore, a causal relationship cannot be inferred between bisphosphonate use and the fractures, or the delay in healing.

Only a few studies have explored the effect of bisphosphonates on fracture healing when administered at or around the time of fracture incidence. No significant delay in upper or lower extremity fracture healing has been noted in any of the studies. A meta-analysis that assessed 8 RCTs and included patients with fractures of the distal forearm, hip, and tibia as well as those with lumbar posterior body fusion did not show any delay in indirect bone healing via external callus formation with the use of bisphosphonates [80]. Time of starting treatment ranged from immediately after fracture to 90 days afterwards. There were no differences in indirect bone healing between early and delayed bisphosphonate administration groups. It must be noted that there was some heterogeneity amongst the studies included in the meta-analysis and, the small number of studies included in the analysis, different doses of bisphosphonates used, variations in the duration of use, differences in the fracture sites looked at, etc. were limitations. Delayed union was defined as one or more clinical symptoms (pain, inability to ambulate, and gait disorder) at least 6 weeks after surgical repair along with radiographic findings in this meta-analysis, and non-union was defined as incomplete bony bridging through cages in the lumbar spine in 12 months post-operation, or no cortices bridging at the fracture site at more than 8 months post-operation.

In contrast, in a nested case–control study of 19,731 elderly patients with humerus fractures, 81 (0.4%) of patients experienced a non-union. Amongst these patients, 16% were exposed to bisphosphonates. Bisphosphonate use in the post-fracture period was associated with an approximate doubling of the risk of non-union (OR, 2.37; 95% CI, 1.13–4.96). Outcome of non-union was defined based on the presence of a surgical procedure for non-union 91–365 days after the initial humerus fracture. The increased risk was observed in the very small number of patients who did not have a history of prior osteoporosis at the time of fracture [81]. The main limitation of this study was the extremely small sample size of patients with non-union. The number needed to harm was approximately 125. Therefore, the findings are of unclear clinical significance. It is also likely that patients who are prescribed bisphosphonates differ in important ways from those who are not, and therefore, the observed risk increase may have been simply related to these unmeasured confounders, such as the baseline bone mineral density or corticosteroid use rather than to the bisphosphonate itself.

In another retrospective study in 196 patients with distal radius fractures that explored pre-fracture bisphosphonate

use and how that impacted on rates of fracture union, a 6-day greater mean time to radiographic union in the bisphosphonate group vs control [82] was found. This delay persisted after adjustment for age, gender, fracture complexity, or comorbidity. However, the authors themselves acknowledged that the small difference in healing time (< 1 week) was not clinically significant and suggested that bisphosphonate therapy can be continued after distal radius fractures without notable deleterious effects.

A Korean study randomized 50 women (> 50 years of age) who had undergone volar locking plate fixation of a distal radius fracture and had been diagnosed with osteoporosis, to early initiation of bisphosphonate treatment at 2 weeks postoperatively, or late initiation at 3 months postoperatively [83]. No significant differences with respect to radiographic union, other radiographic parameters, or clinical outcomes such as Disabilities of the Arm, Shoulder, and Hand (DASH) scores, wrist motion, or grip strength were found.

There are limited data on the effect of bisphosphonates on vertebral fracture healing. A prospective study that aimed to investigate whether bisphosphonates affected fracture healing and clinical outcomes of conservatively managed osteoporotic spinal fractures, enrolled 105 consecutive patients with acute osteoporotic spinal fractures who were separated into groups depending on whether they did or did not have a history of bisphosphonate use [84]. Clinical outcomes were assessed using a visual analog scale and the Oswestry disability index. Radiographic parameters including changes in height loss and kyphotic angle at the index vertebra, as well as radiographic findings indicative of impaired vertebral fracture healing such as the intervertebral cleft sign and fracture instability, were evaluated. No differences in clinical outcomes or radiographic parameters were observed. Patients on bisphosphonates developed intervertebral clefts and the authors in fact suggested that suspension of bisphosphonates should be considered during the fracture healing period for acute osteoporotic spinal fractures.

In a *pre-planned* secondary analysis of the HORIZON Recurrent Fracture Trial (RFT), 2127 participants randomized within 90 days of surgical repair of hip fracture to intravenous zoledronic acid vs placebo were examined to see whether the timing of zoledronic acid affected the risk of delayed hip fracture healing. No significant difference in incidence of delayed union of the qualifying hip fracture (3.2% for zoledronic acid vs 2.7% for placebo, OR 1.17, $p=0.61$) was noted. No interaction by timing of infusion was observed, with non-union rates similar even when zoledronic acid was given within 2 weeks of fracture repair. In the HORIZON RFT, a relative reduction of 28% in the risk of death was observed in the zoledronic acid group, and therefore, a post hoc analysis was performed to look at the hazard ratios for key outcomes by timing of administration of zoledronic acid. When time points > 2 weeks after fracture repair were used for statistical testing, all time

to fracture endpoints, as well as time to all-cause mortality, showed significant and generally larger relative risk reductions. For time to all-cause mortality, the ≤ 2 -week group showed no reduction in the hazard of death, whereas other infusion time periods did, although the 95% confidence intervals crossed 1 for all but one time point [85]. Whether this was a statistical artifact induced by the post hoc analysis can be debated. In clinical practice, for practical purposes, zoledronic acid often is administered within 2 weeks of a surgically operated hip fracture with no negative deleterious effect on fracture healing or systemic osteoporosis management having been reported in the post-marketing literature.

Further reassurance that bisphosphonates do not appear to interfere with fracture healing when given around the time of fracture was provided through a meta-analysis of 10 RCTs that included 2888 subjects [86]. Four of the trials included in the meta-analysis used alendronate, three zoledronic acid, two risedronate, and one etidronate. There were three control groups—receiving placebo in parallel, delayed bisphosphonate treatment, or no therapy. The aim of the meta-analysis was to evaluate benefits and adverse effects of early administration of bisphosphonates to provide recommendations on when these agents could be given after a fracture. Patients who were treated with early bisphosphonate therapy had no statistically significant difference in radiological fracture healing times compared with patients in the control group, neither did they have a higher risk of delay or non-union of fracture healing. The limitations of this meta-analysis included the small size of the study population and the three types of control groups that were utilized. The pooling of distal radius, hip, spine, and other kinds of fractures together is also somewhat controversial although there is no definitive evidence that bisphosphonates have different effects at different skeletal sites.

The clinical studies described above are listed in Table 2.

In summary, though the extrapolation to humans of pre-clinical data obtained from animals is not entirely fail-safe, both the animal data from published literature as well as the current evidence from clinical studies in humans do not support a reason for delay in the initiation of bisphosphonate therapy following an acute typical metaphyseal fragility fracture nor do they form a reason for suspension of treatment if the person is already on the agent for treatment of osteoporosis. The efficacy of bisphosphonates in preventing secondary fractures outweighs the miniscule potential risk of delayed or non-union of fractures associated with their use. On the other hand, in diaphyseal fractures that require rigid internal fixation, given that osteoclastic involvement is harnessed early, and which may be inhibited by bisphosphonates, delaying initiation and/or suspending treatment till after healing is well established may be considered.

Other antiresorptive agents

Denosumab

Denosumab is a monoclonal antibody, the mechanism of action of which is anchored around its binding to the receptor activator of nuclear factor- κ B ligand (RANKL), leading to the decrease of differentiation and function of osteoclasts with consequent inhibition of bone resorption [87].

Animal studies

Data on the effect of RANKL inhibitors on osteoporotic animal models is lacking. However limited data in non-osteoporotic animal models show that though treatment with osteoprotegerin (OPG)—a natural RANKL inhibitor, did not influence callus formation or mechanical strength in female rats, it impaired normal remodelling [22]. Other studies also showed similar findings, with treatment with a RANKL-inhibitor not being detrimental to fracture healing in a mouse model [88] and delayed callus remodelling, but increased mechanical strength with increased torsional rigidity in male mice treated with denosumab [75].

Clinical studies

In the FREEDOM trial, postmenopausal women > 60 years with osteoporosis were randomized to receive denosumab every 6 months or a placebo. A pre-planned sub-analysis of the FREEDOM trial evaluated the effect of denosumab administration on fracture healing amongst 851 patients with non-vertebral fractures (386 in the denosumab group and 465 in the placebo group) to address theoretical concerns related to initiating or continuing denosumab therapy in patients presenting with a non-vertebral fracture [89]. Delayed union was reported in a total of 7 subjects (two in the denosumab group (0.5%) and five in the placebo group (1.1%)). Neither delayed healing nor non-union was observed in any subject who had received denosumab within 6 weeks preceding or following the fracture. Complications associated with the fracture or intervention occurred in five subjects (2%) and twenty subjects (5%) in the denosumab and placebo groups, respectively ($p = 0.009$). Fracture healing seemed to be unaffected even when denosumab was administered within a day of the fracture. Thus, denosumab does not appear to delay fracture healing even when it is administered at or near the time of the fracture, and considering that abrupt treatment discontinuation may incite new vertebral fractures, it seems prudent to recommend continuing denosumab treatment when a fracture has occurred.

Table 2 Clinical studies of bisphosphonates and fracture healing

Study	Type of study	Type of bisphosphonate	Site of fracture	Timing of initiation of bisphosphonate	Effect on fracture healing	Definition of delayed/non-union	Problems with study/ caveats if any
Xue D et al. [80]	Meta-analysis of randomized controlled trials	Alendronate	Distal forearm, hip, tibia, lumbar posterior body fusion	Immediately after fracture to 90 days afterwards	No delay in fracture healing. No difference noted in fracture healing between early and delayed bisphosphonate administration groups	Delayed union: one of more clinical symptoms at least 6 weeks after surgical repair + radiographic findings. Non-union: incomplete bone bridging through lumbar spine cages at 12 months post-operation, or no cortices bridging at fracture site more than 8 months post-operation	Heterogeneity amongst studies. Small number of studies included in analysis. Different doses and duration of bisphosphonates. Different fracture sites assessed
Solomon H et al. [81]	Nested case-control study	Any bisphosphonate	Humerus fractures	Exposure to bisphosphonate in the 365 days prior to fracture	Doubling of risk of non-union	Presence of surgical procedure for non-union 91–365 days after fracture	Small number of patients with non-union. Findings of unclear clinical significance. Presence of unmeasured confounders
Rozenal TD et al. [82]	Retrospective study	Any bisphosphonate	Distal radius fracture	Currently on bisphosphonate therapy at time of fracture	6-day greater mean time to radiographic union	Radiographic union	Small (< 1-week difference in healing time not clinically significant
Gong HS et al. [83]	Randomized controlled trial	Any bisphosphonate	Volar locking plate fixation of distal radius fracture	Bisphosphonate initiated at 2 weeks or 3 months postoperative	No significant difference between early and late initiation	Radiographic union, clinical outcomes such as DASH scores, wrist motion or grip strength	
Ha KY et al. [84]	Prospective study	Any bisphosphonate use	Conservatively managed spine fractures	History of bisphosphonate use	No difference in clinical outcomes or radiographic parameters. However, patients with history of bisphosphonate use developed intervertebral clefts	Clinical outcomes such as visual analog scale, Oswestry disability index. Radiographic parameters including changes in height and kyphotic angle at the index vertebra, intervertebral cleft sign, and fracture instability	

Table 2 (continued)

Study	Type of study	Type of bisphosphonate	Site of fracture	Timing of initiation of bisphosphonate	Effect on fracture healing	Definition of delayed / non-union	Problems with study/ caveats if any
Colon-Emeric C et al. [85]	Pre-planned secondary analysis of HORIZON Recurrent Fracture Trial	Intravenous zoledronic acid vs placebo	Hip fracture	Within 90 days of surgical repair of hip fracture	No significant difference in incidence of delayed union between zoledronic acid and placebo. No interaction by timing of infusion with non-union rates similar even when administered within 2 weeks after fracture	Clinical parameters such as pain, inability to ambulate and radiological parameters such as persistence of fracture line, appearance of new fracture line, displacement of fracture	
Li Y-T et al. [86]	Meta-analysis of randomized controlled trials	Alendronic acid, zoledronic acid, risedronate, etidronate	Distal radius, hip, spine, other kinds of fractures	Early bisphosphonate therapy compared to 3 control groups: placebo/delayed bisphosphonate therapy/no therapy	No statistically significant difference in radiologic fracture healing times between early administration of bisphosphonates vs controls	Radiological evidence of fracture healing	Small population. Pooling of distal radius, hip, spine, and other fractures

Estrogen and selective estrogen receptor modulators (SERMs)

Animal studies

Raloxifene is a SERM with mild antiresorptive properties. Both estrogen and raloxifene suppressed callus remodelling in an ovariectomized rat femoral osteotomy model but did not impair fracture healing [90]. In a rabbit long bone fracture model, animals treated with local administration of estrogen at the fracture gap had significantly higher gross stability, radiographic union, and gap reduction compared to those administered sham normal saline [91]. Both estrogen and raloxifene also have been shown to improve the fracture biomechanical properties in another plate fixation tibial fracture rat model. In this latter study, raloxifene mainly induced total callus formation, while estrogen predominantly increased new endosteal bone formation [58].

Clinical studies

No studies evaluating the influence of raloxifene or estrogen on fracture healing in humans exist.

Calcitonin

Calcitonin is a weak antiresorptive agent that decreases the number and activity of osteoclasts. In the armamentarium of osteoporosis pharmacotherapy, calcitonin has been superseded by other more potent medications.

Animal studies

A multitude of earlier preclinical animal studies have examined the effect of calcitonin on fracture healing. Most of these studies have shown that calcitonin treatment increases callus formation and some have shown that it improves biomechanical properties of the healed bone with a rat tibial model showing more mature early callus with calcitonin treatment having improved mechanical strength [92].

Clinical studies

Statistically significant differences in radiographic fracture healing with calcitonin treatment compared to placebo were seen in a randomized, double-blind, placebo-controlled study of elderly hip fracture patients. However, there was no difference noted in functional recovery between groups [93]. In another randomized, double-blind, placebo-controlled trial in patients with osteoporotic vertebral crush fracture, calcitonin treatment led to decreased pain, earlier mobilization, and faster restoration of locomotor function [94].

Anabolic agents

Teriparatide

Teriparatide is the 1–34 N-terminal amino acid sequence analog of the endogenous human parathyroid hormone. Existing data suggest that teriparatide accelerates chondrocyte recruitment and differentiation [95] both of which are essential processes in early endochondral ossification. It also stimulates osteoblast and fibroblast growth factor-2 upregulation [96]. Case series and reports have described the “off-label” use of teriparatide to accelerate fracture healing and to treat non-union [97]. We examine the evidence that is currently available regarding teriparatide and fracture healing.

Animal studies Multiple studies have shown accelerated fracture healing (both histological and radiological), increased bone mineral content and callus formation, and newly formed bone as well as improvements in biomechanical strength with teriparatide in both male and female and in non-osteoporotic as well as osteoporotic animal models. In animal models of fracture healing and implant fixation, the effect of teriparatide appeared to be stronger on newly forming bone than on preexisting bone.

In a non-osteoporotic cynomolgus monkey model that had femur osteotomy and surgical plate fixation, PTH 1–34 administration post-fracture accelerated the natural fracture healing process by shrinking callus size and increasing the degree of mineralization of the fracture callus and restored intrinsic material properties of the osteotomized femur shaft [98]. Cynomolgus monkeys have an intracortical Haversian remodelling system like that of humans that allows the observation of cortical bone metabolism [99].

A few of the pertinent studies of teriparatide in osteoporotic animal models are highlighted in Table 3.

Clinical studies The animal studies showing accelerated fracture healing with teriparatide have stimulated research into the potential for it to enhance or fasten fracture healing in humans.

A systematic review and meta-analysis by Eastman et al. looked at 11 RCTs to evaluate the evidence of PTH analogs on fracture healing [105]. There were three comparators: placebo or positive comparator or standard care, and though it caused increased heterogeneity in the results, all fracture types were included to maximize the inclusion of all RCTs that explored the use of PTH analogs in fracture healing. Fracture sites in the 11 articles were vertebrae ($n=789$, 3 trials), femur (atypical) ($n=13$, 1 trial), hip ($n=343$, 4 trials), tibia ($n=13$, 1 trial), humerus ($n=40$, 1 trial), and radius ($n=102$, 1 trial). There was no difference in fracture healing rate at the first reported time point in teriparatide-treated patients. There were however significant reductions in pain

Table 3 Studies of teriparatide on animal models of fracture healing

Study	Animal model	Findings
Ellegard et al. [100]	Ovariectomized rat with tibia osteotomy	Non-significantly increased amount of callus after 4–6 weeks and no difference after 8 weeks. Increased bone mineral content. Callus bone mineral density and bone mineral content even in conditions of unloading
Kim et al. [101]	Ovariectomized rat with tibia osteotomy stabilized by intramedullary nailing	Enhanced biomechanical strength of callus
Lin et al. [102]	Ovariectomized rat with femur shaft osteotomy	Enhanced new bone formation, enhanced maximum femoral loading, and increased levels of procollagen type I N-terminal propeptide (PINP) and osteocalcin. Enhanced osteotomy healing
Liu et al. [95]	Ovariectomized rats with femur shaft osteotomy	Combination of insulin and PTH improved differentiation and proliferation of hypertrophic chondrocytes. Increased newly formed trabecular/cancellous bone with increased mineralized bone volume fraction (BV/TV) and connectivity density
Kitaguchi et al. [103]	Ovariectomized mice with femur metaphyses osteotomy (cancellous bone healing model)	Combination treatment with RANK ligand antibody and PTH Accelerated regeneration of cancellous bone volume. No effect on cortical bone regeneration
Nozaka et al. [104]	Normal and ovariectomized rats with cancellous bone (proximal tibial) osteotomy	Increased cancellous bone volume by stimulating bone formation in both normal and ovariectomized rats and decreased adipogenesis. Increased cancellous bone union

and improved functional outcomes. The authors concluded that PTH analogs improved functional outcomes across a range of fracture types with no additional incidence of adverse events compared with bisphosphonates and standard care. It must be noted that there were several limitations to the study including the varied comparators, varying trial designs, lack of a common fracture healing analysis time point, and differences in criteria to denote fracture healing amongst the trials.

Another meta-analysis by Kim et al. of 11 trials (6 RCTs, 4 well-controlled retrospective studies, and 1 retrospective post hoc subgroup analysis) showed varying effect of teriparatide on fracture healing based on the site of fracture [106]. Teriparatide showed positive effects on radiographic bone healing in 6 studies and was associated with a decrease in pain or shorter mobilization in 6 studies. The conclusion was that teriparatide appears to provide *selective* advantages to fracture healing, i.e., at certain sites such as the pelvis and distal radius, and functional recovery of osteoporotic fractures.

One of the more pertinent randomized controlled trials in the Kim et al. meta-analysis was a trial by Aspenberg et al. a 53-week RCT that enrolled 102 postmenopausal women with a *distal radius* fracture who required closed reduction but did not require surgery. Women were randomized to 8 weeks of teriparatide 20 µg, 40 µg, or placebo within 10 days of fracture [107]. The investigators hypothesized that the higher teriparatide dose would shorten the time to cortical bridging. They found that the median time from fracture to first radiographic evidence of complete cortical

bridging in three of four cortices was significantly reduced in the teriparatide 20 µg group vs placebo. However, no significant difference between the 40 µg versus placebo group was seen. No differences for functional outcomes or adverse effects were found between the three groups. The lack of effect of teriparatide 40 µg to accelerate healing compared with placebo was an unexpected finding. It was postulated that the higher dose resulted in a decreased mineral density in the cortex of the radial shaft, likely related to increased remodelling. The increased porosity in the callus may have made the callus larger and mechanically functional though it might have been less visible on X-rays. In a subsequent post hoc subgroup analysis that was not part of the original protocol, two of the authors of the original study examined the qualitative appearance of the callus 5 weeks after fracture (i.e., early callus) in 27 of the subjects [108]. They found that early callus quality was improved with both the high and low dose of teriparatide as compared to with placebo. The authors suggest that though their findings had to be interpreted with caution (given the nature of the analysis), in combination with the results of the larger trial, radiographic callus quality at an early time point might be a better and more sensitive variable of fracture healing, than time to cortical continuity.

Another trial randomized 171 patients to either teriparatide (20 µg/day) or risedronate (35 mg/week) initiated within 2 weeks after fixation of a low-trauma pertrochanteric hip fracture [109]. Contrary to the findings seen in the distal radius, this study showed improved functional outcomes such as short Timed Up and Go test and improvement in

pain in the teriparatide arm. However, there were *no* significant differences in radiographic healing, implant mechanical failure, or loss of fracture reduction between the groups.

Two meta-analyses that have been performed to assess the effectiveness of teriparatide on fracture healing times have provided conflicting results. The first meta-analysis by Lou et al. of patients with osteoporosis found a significantly shortened healing time in the teriparatide-treated group, though stratified analysis showed that the lower limb group had shorter healing time but the upper limb group did not [110]. The reason for this discrepancy is not clear. The second meta-analysis by Shi et al. included non-osteoporotic fractures and did not demonstrate effectiveness of teriparatide in hastening fracture union [111].

In summary, the accumulated evidence from both pre-clinical and clinical data suggests that though teriparatide treatment can enhance fracture healing, there does not seem to be evidence that it prevents non-union or influences union rates. If used to enhance fracture healing, the optimal timing, treatment duration, dose, dosing interval, and therefore the clinical meaningfulness remain uncertain.

Abaloparatide

Abaloparatide is a novel synthetic peptide analog of PTHrP given at four times the teriparatide dose in a human osteoporosis trial. Abaloparatide increased bone density more than teriparatide, and both reduced fracture risk [112].

There is no evidence to suggest that abaloparatide has a deleterious effect on fracture healing in either animals or humans. Evidence of *improved* outcomes on fracture healing with abaloparatide however comes only from mouse models. In a study that was a head-to-head comparison between the potential fracture healing effects of abaloparatide and teriparatide, both metaphyseal and diaphyseal fracture healing were assessed [113]. In the metaphyseal model, a dose-dependent increase in screw pull-out force was seen with both abaloparatide and teriparatide (the screw pull-out force is reflective of cancellous bone healing, is a surrogate for the strength of the bone that has regenerated and grasped the screw threads during the 10 days after screw insertion, and is a measure of local cancellous bone formation in response to trauma). Both medications also significantly increased callus density in the diaphyseal model.

Romosozumab

Romosozumab is a monoclonal antibody directed against sclerostin, which is a glycoprotein secreted by osteocytes and is the product of the SOST gene [114]. Sclerostin functions as an endogenous antagonist and inhibits the binding of Wnt ligand to low-density lipoprotein

receptor-related protein (LRP5/6) [115]. Activation of Wnt signalling stimulates β -catenin (a molecule downstream in the Wnt pathway) to activate osteoblastic gene transcription. Activation of Wnt signalling also diverts the differentiation of pluripotent mesenchymal cells towards the osteoblastic lineage and suppresses chondrogenesis. On the other hand, the increased level of β -catenin results in an increased expression of OPG, which binds to RANKL as a decoy receptor, preventing the binding of RANKL and RANK. Osteoclast activation and differentiation, which lead to bone resorption, occur in the presence of RANKL-to-RANK binding [115, 116].

The canonical Wnt (cWnt) β -catenin pathway is one of the most critical signalling pathways involved in bone healing [117, 118]. The peak upregulation of the pathway is seen within 7 to 14 days after fracture in rat models. Bone healing can potentially be accelerated by upregulating and/or controlling the cWnt pathway along with levels of β -catenin. It has been reported that Wnt-responsive cells are not observed near the marrow cavity but seen over the periosteal callus, presuming that the cWnt- β -catenin pathway associates with endochondral rather than intramembranous bone formation. Montjovent et al. have shown that non-rigid fixation of femoral defects is associated with increased levels of inhibitors of Wnt proteins [119], and as detailed earlier, the main healing process in non-rigid fixation is through endochondral bone formation. Therefore, theoretically at least, inhibiting Wnt protein inhibitors and activating the cWnt- β -catenin pathway may help healing of such fractures.

Animal studies Most animal fracture model studies employing sclerostin-neutralizing antibodies have shown a positive effect. This was especially so in diabetic and osteoporotic models [120–122]. Treatment with anti-sclerostin antibody of rats with femoral defects resulted in faster healing times and increased BMD at fracture sites when compared to control sites at both early (3 weeks) and late (8 weeks) time points post-fracture induction [123, 124]. Rats who had open osteotomy and subsequently given anti-sclerostin antibody at 3 and 6 weeks post-fracture or at 3, 6, and 9 weeks post-fracture showed more highly mineralized calluses and higher BMD at the fracture sites [125, 126]. Moreover, there was increased callus angiogenesis noted. An increase in callus bone volume accompanied by increased bone strength has been also observed in sclerostin gene knockout mice models with fractures that were externally fixed and healed through endochondral ossification [127, 128]. On the other hand, Kruck et al. reported negative effects of sclerostin antibody (Scl-Ab) on bone healing [129]. In the rigid and semirigid fixation rat models for femoral osteotomy that were created for this study, no difference in late healing between the Scl-Ab and control groups that underwent semirigid fixation was

Table 4 Animal models of fracture healing with romosozumab/SOST antibody

Study	Animal model	Findings
Ominsky et al. [128]	Rat with femur fracture	Increased bone mass and bone strength at the site of fracture. Less callus cartilage and smaller fracture gaps containing more bone and less fibrovascular tissue
Ominsky et al. [128]	Cynomolgus monkey with fibula osteotomy	Increased bone mass and bone strength at the site of fracture in treated animals. Less callus cartilage and smaller fracture gaps containing more bone and less fibrovascular tissue
Virdi AS [130]	Rat with femur ablation and implant placement	Fixation strength increased in treated rats compared to controls
Yee et al. [122]	Streptozocin-induced T1 DM mouse with femur fracture	Sclerostin antibody rescued the impaired osteogenesis seen in T1DM fracture model by facilitating osteoblast differentiation and mineralization of bone
Agholme et al. [131]	Rat with tibia metaphyseal screw	Pull-out strength increased, bone volume surrounding screw increased with treatment
McDonald et al. [132]	Rat with femur distraction osteogenesis	Increased bone volume and increased strength of united bone with treatment
Virk et al. [124]	Rat with femur critical defect	Complete healing of critical defect in subset of rats treated with sclerostin antibody compared to no healing in controls
Kruck et al. [129]	Mouse with femur osteotomy rigidly or semirigidly fixed	Increased bone volume in sclerostin antibody-treated mice. However, higher degree of endosteal bridging indicating delayed fracture callus remodelling

noted. However, with rigid fixation, the Scl-Ab group had more bridging of the endosteum, which adversely affected late healing, suggesting delayed callus remodelling and marrow reconstitution.

Some of the pertinent studies of romosozumab in animal models are highlighted in Table 4.

Clinical studies Though the preclinical studies with sclerostin antibody overall showed promising results on fracture healing, and though no adverse effects on it have been observed so far with romosozumab, human studies with this agent exploring its efficacy in fracture healing have been disappointing. In a phase 2 randomized double-blind trial that evaluated the effect of romosozumab on outcomes in patients who had open reduction and internal fixation of intertrochanteric or femoral neck hip fractures, no evidence of improvements in fracture healing-related clinical and radiographic outcomes was seen [133]. In this study, 243 subjects were randomized to receive romosozumab at doses of 70 mg ($n=60$), 140 mg ($n=93$), and 210 mg ($n=90$) and 89 to receive a placebo. Subjects received three subcutaneous injections of romosozumab or a placebo postoperatively on day 1 and at weeks 2, 6, and 12. The primary end point was the timed “Up & Go” (TUG) score over weeks 6 to 20. Additional end points included the time to radiographic evidence of healing (defined as effacement of the fracture lines by newly formed bone along the cortices and within the trabecular bone on anteroposterior and lateral [or oblique] radiographs) and the Radiographic Union Scale for Hip (RUSH) score. There was no difference in the TUG

score, or in the median time to radiographic evidence of healing between romosozumab and placebo. Neither was there a difference between the two in the RUSH score. The reason for the absence of accelerated healing, despite the stimulation of bone formation that romosozumab induces, was unclear. Another randomized double-blind phase 2 trial evaluated the effect of romosozumab in patients after surgical fixation of tibial diaphyseal fracture. In this study, 299 subjects were randomized to the romosozumab group and 103 to the placebo group. Patients received subcutaneous injections of romosozumab or the placebo postoperatively on day 1 and subsequently in weeks 2, 6, and 12. The primary outcome was the time to radiographic evidence of healing (“radiographic healing”) analyzed after the week-24 assessments had been completed for all patients. No significant difference in time to radiographic or clinical healing nor a benefit in physical function was seen between the two groups [134].

The reasons for the lack of acceleration of fracture healing in the romosozumab groups compared with the placebo group in the studies described above are unclear though it is hypothesized that perhaps the studies were too short or underpowered to detect changes in subgroups of patients who might benefit from treatment. Other postulates that have been raised to explain the discrepancies noted between the animal and human studies include differences in the timing of administration of the sclerostin antibody. In both human studies, romosozumab was administered starting on post-operative day 1 whereas in the animal studies, it was given much later after the fracture.

Romozosumab promotes the differentiation of osteoblasts from osteoprogenitors with little increase in immature osteoprogenitor cells whereas teriparatide increases levels of immature osteoprogenitor cells also [135]. *SOST* gene expression has been noted to be more abundant in the hard callus in the later stages of bone repair than in the soft callus in the early stages in a mouse tibia fracture model [136]. In this study, administration of teriparatide upregulated *SOST* expression as the hard callus increased. These findings suggest that changing the time of initiation of romozosumab to later in the fracture healing process and perhaps a sequential use of teriparatide followed by romozosumab may benefit fracture healing although this has not been studied clinically. In both the human clinical studies described earlier, the patients received rigid fixation and romozosumab may have had a deleterious effect on the healing process in this situation. It may also be possible that fracture healing requires remodelling while romozosumab exerts its stimulatory bone formation effect primarily through modelling-based mechanisms [135]. All these postulates remain speculative at best and call for further research.

In summary, strong evidence for fracture healing with anabolic agents is lacking. Teriparatide is associated with shorter fracture healing time at sites such as the distal radius. There is conflicting evidence in its use for hip fracture healing though there does appear to be better pain and functional outcomes with its use. There is limited data regarding its use in vertebral fracture healing; however, it is associated with pain improvement in this setting. There is scant data for fracture healing outcomes with abaloparatide, and studies on fracture healing with romozosumab have yielded disappointing results in humans.

Conclusion and areas of potential research

Fracture healing is a complex process that involves multiple biological and mechanical factors. Fracture repair involves different stages that resemble embryological skeletal development. The timing of healing and delayed healing after fracture varies across skeletal sites. The assessment of fracture healing typically involves a combination of clinical examination and radiographic imaging. Animal studies appear to support the view that osteoporosis negatively influences fracture healing. However, clinical studies in humans have yielded conflicting results.

The effect of osteoporosis medications on fracture healing has been extensively studied, though most of the investigations have been in animal models and therefore may not fully translate to humans. Other factors such as aging, smoking, poor nutrition, and comorbidities such as diabetes and vitamin D deficiency may confound and contribute

to delayed healing of osteoporotic fragility fractures. Overall, there does not appear to be a deleterious effect of osteoporosis medications on fracture healing. Bisphosphonates can be safely started early after metaphyseal osteoporotic fractures without adversely affecting clinical outcome. The benefit of treating osteoporosis and the urgent necessity to mitigate imminent fracture risk should take precedence over any theoretical risks of non-union or delayed union. There is a suggestion of benefit for teriparatide in time to fracture healing. Data on the impact of new antiosteoporosis agents such as romozosumab on fracture healing is scant and deserves further attention.

Several areas would benefit from additional research. The identification of new radiological and biological markers of fracture healing and the development of simple, reliable clinical measures for malunion and non-union is one such. Currently, microCT is the most accurate method to assess non-union in rat fracture models [137]. MicroCT generates density-related parameters [138], torsional rigidity [139], etc. may potentially be used to describe outcomes in human clinical studies also, though cost and concerns about radiation exposure may limit its practical use in human patients.

In the realm of assessment of fracture healing and prediction of union vs non-union, an attempt to synthesize clinical and basic science methodologies must be made so that a convergence of the two frameworks can be achieved. An example is the quantification of pain, weight-bearing, and analysis of gait and function. Assessment of pain and functional recovery in animal models include the amount of weight bearing (with animals flinching or withdrawing the affected part in the presence of pain) and locomotor activity and gait analysis. In humans, such assessments include rating pain on a Likert scale, or reporting of pain on palpation of the fracture site is standard clinical praxis. However, for translation of animal studies, it is essential that parameters that are conserved across species be identified to better unite clinical and pre-clinical assessment techniques.

It is also imperative that systemic and local agents that mechanistically target steps in the molecular pathway of fracture healing and can be used as therapeutic agents to aid union be developed, and more refined fracture fixation techniques based on a deeper understanding of the strain and vascularity patterns at the fracture site be undertaken.

Acknowledgements We are grateful to the Committee of Scientific Advisors of the International Osteoporosis Foundation (IOF) for their review and endorsement of this publication. Fracture Working Group of the Committee of Scientific Advisors of the IOF: Kristina E Åkeson, Robert D Blank, Maria Louisa Brandi, Derrick Chan, Manju Chandran, Thierry Chevalley, Cyrus Cooper, Patrice Fardellone, Julio C Fernandes, Stefan Goemaere, Nicholas Harvey, G Holzer, Kassim Javaid, Willem F Lems, Michael E Lewiecki, George P Lyritis, Polyzois Makras, Nicola Napoli, Julien Paccou, Stuart Silverman, Manuel Sosa Henriquez, Thierry Thomas

Declarations

Conflict of interest MC has received honoraria and travel grants from AMGEN and DKSH for speaking engagements outside the submitted work.

KEA has received speaker fees from Amgen, Astellas Pharma, Chugai, and UCB outside the submitted work.

MKJ has received honoraria, unrestricted research grants, and travel and/or subsistence expenses from Amgen, Lilly UK, Internis, Consilient Health, Zebra Medical Vision, Kyowa Kirin Hakin, and UCB outside the submitted work.

NCH reports personal fees, consultancy, lecture fees, and honoraria from Alliance for Better Bone Health, AMGEN, MSD, Eli Lilly, Servier, Shire, UCB, Kyowa Kirin, Consilient Healthcare, Theramex, and Internis Pharma, outside the submitted work.

RDB serves on an advisory board for Amgen, has received royalties from Wolters-Kluwer, and has ownership/stock interests in Abbott Labs, Abbvie, Amgen, Doctorpedia, Glaxo, JangoBio, Johnson & Johnson, Procter & Gamble, and ROMTech outside the submitted work.

MLB has served as a consultant for Aboca, Alexion, Amolyt, Bruno Farmaceutici, Calcilytix, Echolight, Kyowa Kirin, Personal Genomics, and Smoke-Free World Foundation; has received honoraria from Amgen, Bruno Farmaceutici, Calcilytix, Kyowa Kirin, and UCB; and received grants from Abiogen, Alexion, Amgen, Amorphical, Bruno Farmaceutici, CGeDi, Echolight, Eli Lilly, Enterabio, Gedeon Richter, Italfarmaco, Kyowa Kirin, Menarini, Monter Rosa Therapeutics, SPA, Takeda, Thermax, and UCB outside the submitted work.

TC has no conflict of interest to disclose.

GPL has no conflict of interest to disclose.

PM reports fees for lectures/advisory boards and research grants from Amgen and Galenica and fees for lectures/advisory boards and conference travel from UCB, Elpen, Bianex, and Eli-Lilly outside the submitted work.

JP has no conflict of interest to disclose.

PC has no conflict of interest to disclose.

DP has no conflict of interest to disclose.

MS has no conflict of interest to disclose.

TT has received consultancy/speaker's fees from AMGEN, Arrow, Biogen, Chugai, Expanscience, Grunenthal, Jansen, LCA, Lilly, MSD, Nordic, Novartis, Pfizer, Sanofi, Thuasne, Theramex, TEVA, and UCB and financial support or fees for research activities from Bone Therapeutics, Chugai, and UCB outside the submitted work.

SS reports consultancy fees from Radius, Amgen, Lilly, and Pfizer and grants from Amgen outside the submitted work.

Open Access This article is licensed under a Creative Commons Attribution-NonCommercial 4.0 International License, which permits any non-commercial use, sharing, adaptation, distribution and reproduction in any medium or format, as long as you give appropriate credit to the original author(s) and the source, provide a link to the Creative Commons licence, and indicate if changes were made. The images or other third party material in this article are included in the article's Creative Commons licence, unless indicated otherwise in a credit line to the material. If material is not included in the article's Creative Commons licence and your intended use is not permitted by statutory regulation or exceeds the permitted use, you will need to obtain permission directly from the copyright holder. To view a copy of this licence, visit <http://creativecommons.org/licenses/by-nc/4.0/>.

References

- Johansson H, Siggeirsdóttir K, Harvey NC, Odén A, Gudnason V, McCloskey E et al (2017) Imminent risk of fracture after fracture. *Osteoporos Int* 28(3):775–780
- Mills LA, Aitken SA, Simpson AHRW (2017) The risk of non-union per fracture: current myths and revised figures from a population of over 4 million adults. *Acta Orthop* 88(4):434–439
- Kanakaris NK, Giannoudis PV (2007) The health economics of the treatment of long-bone non-unions. *Injury* 38(Suppl 2):S77–84
- Antonova E, Le TK, Burge R, Mershon J (2013) Tibia shaft fractures: costly burden of nonunions. *BMC Musculoskelet Disord* 14:42
- Yeo JH, Kim JY (2018) Surgical strategy for scaphoid nonunion treatment. *J Hand Surg Asian-Pac Vol* 23(4):450–462
- Sinnott B, Ray C, Weaver F, Gonzalez B, Chu E, Premji S et al (2022) Risk factors and consequences of lower extremity fracture nonunions in veterans with spinal cord injury. *JBM Plus* 6(3):e10595
- Kostenuik P, Mirza FM (2017) Fracture healing physiology and the quest for therapies for delayed healing and nonunion. *J Orthop Res* 35(2):213–223
- Baker CE, Moore-Lotridge SN, Hysong AA, Posey SL, Robinette JP, Blum DM et al (2018) Bone fracture acute phase response—a unifying theory of fracture repair: clinical and scientific implications. *Clin Rev Bone Min Metab* 16(4):142–158
- Park SH, Silva M, Bahk WJ, McKellop H, Lieberman JR (2002) Effect of repeated irrigation and debridement on fracture healing in an animal model. *J Orthop Res* 20(6):1197–1204
- Hirao M, Tamai N, Tsumaki N, Yoshikawa H, Myoui A (2006) Oxygen tension regulates chondrocyte differentiation and function during endochondral ossification. *J Biol Chem* 281(41):31079–31092
- Trueta J, Amato VP (1960) The vascular contribution to osteogenesis. III. Changes in the growth cartilage caused by experimentally induced ischaemia. *J Bone Joint Surg Br* 42-B:571–87
- Cui L, Houston DA, Farquharson C, MacRae VE (2016) Characterisation of matrix vesicles in skeletal and soft tissue mineralisation. *Bone* 87:147–158
- Yu YY, Lieu S, Lu C, Mclau T, Marcucio RS, Colnot C (2010) Immunolocalization of BMPs, BMP antagonists, receptors, and effectors during fracture repair. *Bone* 46(3):841–851
- Zhou X, von der Mark K, Henry S, Norton W, Adams H, de Crombrughe B (2014) Chondrocytes transdifferentiate into osteoblasts in endochondral bone during development, postnatal growth and fracture healing in mice. *PLoS Genet* 10(12):e1004820
- Gerber HP, Vu TH, Ryan AM, Kowalski J, Werb Z, Ferrara N (1999) VEGF couples hypertrophic cartilage remodeling, ossification and angiogenesis during endochondral bone formation. *Nat Med* 5(6):623–628
- Gerstenfeld LC, Cruceta J, Shea CM, Sampath K, Barnes GL, Einhorn TA (2002) Chondrocytes provide morphogenic signals that selectively induce osteogenic differentiation of mesenchymal stem cells. *J Bone Miner Res* 17(2):221–230
- Deckers MML, van Bezooijen RL, van der Horst G, Hoogendam J, van Der Bent C, Papapoulos SE et al (2002) Bone morphogenetic proteins stimulate angiogenesis through osteoblast-derived vascular endothelial growth factor A. *Endocrinology* 143(4):1545–1553
- Maes C, Kobayashi T, Selig MK, Torrekens S, Roth SI, Mackem S et al (2010) Osteoblast precursors, but not mature osteoblasts, move into developing and fractured bones along with invading blood vessels. *Dev Cell* 19(2):329–344

19. Perren SM (2002) Evolution of the internal fixation of long bone fractures. The scientific basis of biological internal fixation: choosing a new balance between stability and biology. *J Bone Joint Surg Br* 84(8):1093–110
20. Fazzalari NL (2011) Bone fracture and bone fracture repair. *Osteoporos Int* 22(6):2003–2006
21. McDonald MM, Dulai S, Godfrey C, Amanat N, Szynda T, Little DG (2008) Bolus or weekly zoledronic acid administration does not delay endochondral fracture repair but weekly dosing enhances delays in hard callus remodeling. *Bone* 43(4):653–662
22. Ulrich-Vinther M, Andreassen TT (2005) Osteoprotegerin treatment impairs remodeling and apparent material properties of callus tissue without influencing structural fracture strength. *Calcif Tissue Int* 76(4):280–286
23. Ulrich-Vinther M, Schwarz EM, Pedersen FS, Søballe K, Andreassen TT (2005) Gene therapy with human osteoprotegerin decreases callus remodeling with limited effects on biomechanical properties. *Bone* 37(6):751–758
24. Tsidiris E, Upadhyay N, Giannoudis P (2007) Molecular aspects of fracture healing: which are the important molecules? *Injury* 38(Suppl 1):S11–25
25. Fleisch H (2001) Can bisphosphonates be given to patients with fractures? *J Bone Miner Res* 16(3):437–440
26. Yuasa M, Mignemi NA, Barnett JV, Cates JMM, Nyman JS, Okawa A et al (2014) The temporal and spatial development of vascularity in a healing displaced fracture. *Bone* 67:208–221
27. Corrales LA, Morshed S, Bhandari M, Miclau T (2008) Variability in the assessment of fracture-healing in orthopaedic trauma studies. *J Bone Joint Surg Am* 90(9):1862–1868
28. Panjabi MM, Walter SD, Karuda M, White AA, Lawson JP (1985) Correlations of radiographic analysis of healing fractures with strength: a statistical analysis of experimental osteotomies. *J Orthop Res* 3(2):212–218
29. Sano H, Uthoff HK, Backman DS, Yeaton A (1999) Correlation of radiographic measurements with biomechanical test results. *Clin Orthop Relat Res* 368:271–278
30. Whelan DB, Bhandari M, Stephen D, Kreder H, McKee MD, Zdero R et al (2010) Development of the radiographic union score for tibial fractures for the assessment of tibial fracture healing after intramedullary fixation. *J Trauma* 68(3):629–632
31. Chiavaras MM, Bains S, Choudur H, Parasu N, Jacobson J, Ayeni O et al (2013) The Radiographic Union Score for Hip (RUSH): the use of a checklist to evaluate hip fracture healing improves agreement between radiologists and orthopedic surgeons. *Skeletal Radiol* 42(8):1079–1088
32. Patel SP, Anthony SG, Zurakowski D, Didolkar MM, Kim PS, Wu JS et al (2014) Radiographic scoring system to evaluate union of distal radius fractures. *J Hand Surg [Am]* 39(8):1471–1479
33. Fisher JS, Kazam JJ, Fufa D, Bartolotta RJ (2019) Radiologic evaluation of fracture healing. *Skeletal Radiol* 48(3):349–361
34. Hak DJ, Fitzpatrick D, Bishop JA, Marsh JL, Tilp S, Schnettler R et al (2014) Delayed union and nonunions: epidemiology, clinical issues, and financial aspects. *Injury* 45(Suppl 2):S3–7
35. Frölke JPM, Patka P (2007) Definition and classification of fracture non-unions. *Injury* 38(Suppl 2):S19–22
36. Grigoryan M, Lynch JA, Fierlinger AL, Guermazi A, Fan B, MacLean DB et al (2003) Quantitative and qualitative assessment of closed fracture healing using computed tomography and conventional radiography. *Acad Radiol* 10(11):1267–1273
37. Nicholson JA, Clement ND, Clelland AD, MacDonald D, Simpson AHRW, Robinson CM (2020) Displaced midshaft clavicle fracture union can be accurately predicted with a delayed assessment at 6 weeks following injury: a prospective cohort study. *J Bone Joint Surg Am* 102(7):557–566
38. Oliver WM, Smith TJ, Nicholson JA, Molyneux SG, White TO, Clement ND et al (2019) The Radiographic Union Score for HUMeral fractures (RUSHU) predicts humeral shaft nonunion. *Bone Joint J* 101-B(10):1300–6
39. Dekker AP, Chuttha S, Tambe AA, Clark DI (2021) Predicting the behavior of humeral shaft fractures: an independent validation study of the Radiographic Union Score for HUMeral Fractures and value of assessing fracture mobility. *J Orthop Trauma* 35(10):555–559
40. Jang Y, Gaski G, Natoli R, Virkus W, Mckinley T (2020) Tibial fracture healing score: a novel tool to predict tibial nonunion. *Orthopedics* 43(4):e323–e328
41. O'Halloran K, Coale M, Costales T, Zerhusen T, Castillo RC, Nascone JW et al (2016) Will my tibial fracture heal? Predicting nonunion at the time of definitive fixation based on commonly available variables. *Clin Orthop Relat Res* 474(6):1385–1395
42. Reinke S, Geissler S, Taylor WR, Schmidt-Bleek K, Juelke K, Schwachmeyer V et al (2013) Terminally differentiated CD8⁺ T cells negatively affect bone regeneration in humans. *Sci Transl Med* 5(177):177ra36
43. Hussein AI, Mancini C, Lybrand KE, Cooke ME, Matheny HE, Hogue BL et al (2018) Serum proteomic assessment of the progression of fracture healing. *J Orthop Res* 36(4):1153–1163
44. de Seny D, Cobraiville G, Leprince P, Fillet M, Collin C, Mathieu M et al (2016) Biomarkers of inflammation and innate immunity in atrophic nonunion fracture. *J Transl Med* 14(1):258
45. Niikura T, Lee SY, Sakai Y, Nishida K, Kuroda R, Kurosaka M (2014) Causative factors of fracture nonunion: the proportions of mechanical, biological, patient-dependent, and patient-independent factors. *J Orthop Sci* 19(1):120–124
46. Seebeck J, Goldhahn J, Morlock MM, Schneider E (2005) Mechanical behavior of screws in normal and osteoporotic bone. *Osteoporos Int* 16(Suppl 2):S107–S111
47. Carden A, Morris MD (2000) Application of vibrational spectroscopy to the study of mineralized tissues (review). *J Biomed Opt* 5(3):259–268
48. Tsubota KI, Adachi T, Tomita Y (2003) Effects of a fixation screw on trabecular structural changes in a vertebral body predicted by remodeling simulation. *Ann Biomed Eng* 31(6):733–740
49. Currey JD, Brear K, Zioupos P (1996) The effects of ageing and changes in mineral content in degrading the toughness of human femora. *J Biomech* 29(2):257–260
50. Neidlinger-Wilke C, Stalla I, Claes L, Brand R, Hoellen I, Rübenaeker S et al (1995) Human osteoblasts from younger normal and osteoporotic donors show differences in proliferation and TGF beta-release in response to cyclic strain. *J Biomech* 28(12):1411–1418
51. Gruber R, Koch H, Doll BA, Tegtmeier F, Einhorn TA, Hollinger JO (2006) Fracture healing in the elderly patient. *Exp Gerontol* 41(11):1080–1093
52. Steen H, Fjeld TO (1989) Lengthening osteotomy in the metaphysis and diaphysis. An experimental study in the ovine tibia. *Clin Orthop Relat Res* 247:297–305
53. Wong RMY, Choy MHV, Li MCM, Leung KS, Chow SK-H, Cheung WH et al (2018) A systematic review of current osteoporotic metaphyseal fracture animal models. *Bone Joint Res* 7(1):6–11
54. Thompson DD, Simmons HA, Pirie CM, Ke HZ (1995) FDA Guidelines and animal models for osteoporosis. *Bone* 17(4 Suppl):125S–S133
55. Chen L, Yang L, Yao M, Cui XJ, Xue CC, Wang YJ et al (2016) Biomechanical characteristics of osteoporotic fracture


- healing in ovariectomized rats: a systematic review. *PLoS One* 11(4):e0153120
56. Wang JW, Li W, Xu SW, Yang DS, Wang Y, Lin M et al (2005) Osteoporosis influences the middle and late periods of fracture healing in a rat osteoporotic model. *Chin J Traumatol = Zhonghua Chuang Shang Za Zhi* 8(2):111–6
 57. Alt V, Thormann U, Ray S, Zahner D, Dürselen L, Lips K et al (2013) A new metaphyseal bone defect model in osteoporotic rats to study biomaterials for the enhancement of bone healing in osteoporotic fractures. *Acta Biomater* 9(6):7035–7042
 58. Stuermer EK, Sehmisch S, Rack T, Wenda E, Seidlova-Wuttke D, Tezval M et al (2010) Estrogen and raloxifene improve metaphyseal fracture healing in the early phase of osteoporosis. A new fracture-healing model at the tibia in rat. *Langenbeck's Arch Surg* 395(2):163–72
 59. Zura R, Braid-Forbes MJ, Jeray K, Mehta S, Einhorn TA, Watson JT et al (2017) Bone fracture nonunion rate decreases with increasing age: a prospective inception cohort study. *Bone* 95:26–32
 60. Zura R, Xiong Z, Einhorn T, Watson JT, Ostrum RF, Prayson MJ et al (2016) Epidemiology of fracture nonunion in 18 human bones. *JAMA Surg* 151(11):e162775
 61. van Wunnik BPW, Weijers PHE, van Helden SH, Brink PRG, Poeze M (2011) Osteoporosis is not a risk factor for the development of nonunion: a cohort nested case-control study. *Injury* 42(12):1491–1494
 62. Singh M, Nagrath AR, Maini PS (1970) Changes in trabecular pattern of the upper end of the femur as an index of osteoporosis. *J Bone Joint Surg Am* 52(3):457–467
 63. Gorter EA, Gerretsen BM, Krijnen P, Appelman-Dijkstra NM, Schipper IB (2020) Does osteoporosis affect the healing of subcapital humerus and distal radius fractures? *J Orthop* 22:237–241
 64. Drake MT, Clarke BL, Khosla S (2008) Bisphosphonates: mechanism of action and role in clinical practice. *Mayo Clin Proc* 83(9):1032–1045
 65. Favus MJ (2010) Bisphosphonates for osteoporosis. *N Engl J Med* 363(21):2027–2035
 66. Amanat N, McDonald M, Godfrey C, Bilston L, Little D (2007) Optimal timing of a single dose of zoledronic acid to increase strength in rat fracture repair. *J Bone Miner Res* 22(6):867–876
 67. Li J, Mori S, Kaji Y, Kawanishi J, Akiyama T, Norimatsu H (2000) Concentration of bisphosphonate (incadronate) in callus area and its effects on fracture healing in rats. *J Bone Miner Res* 15(10):2042–2051
 68. Fu LJ, Tang TT, Hao YQ, Dai KR (2013) Long-term effects of alendronate on fracture healing and bone remodeling of femoral shaft in ovariectomized rats. *Acta Pharmacol Sin* 34(3):387–392
 69. Manabe T, Mori S, Mashiba T, Kaji Y, Iwata K, Komatsubara S et al (2012) Effect of dosing interval duration of intermittent ibandronate treatment on the healing process of femoral osteotomy in a rat fracture model. *Calcif Tissue Int* 90(3):193–201
 70. Kidd LJ, Cowling NR, Wu ACK, Kelly WL, Forwood MR (2011) Bisphosphonate treatment delays stress fracture remodeling in the rat ulna. *J Orthop Res* 29(12):1827–1833
 71. Yu YY, Lieu S, Hu D, Miclau T, Colnot C (2012) Site specific effects of zoledronic acid during tibial and mandibular fracture repair. *PLoS One* 7(2):e31771
 72. Tatli U, Ustün Y, Kürçü M, Erdoğan O, Gürbüz CC, Özgür H et al (2011) Effects of zoledronic acid on healing of mandibular fractures: an experimental study in rabbits. *J Oral Maxillofac Surg* 69(6):1726–1735
 73. Bosemark P, Isaksson H, McDonald MM, Little DG, Tägil M (2013) Augmentation of autologous bone graft by a combination of bone morphogenic protein and bisphosphonate increased both callus volume and strength. *Acta Orthop* 84(1):106–111
 74. Doi Y, Miasashi M, Yoshiiwa T, Hara K, Kataoka M, Tsumara H (2011) Manipulation of the anabolic and catabolic responses with BMP-2 and zoledronic acid in a rat femoral fracture model. *Bone* 49(4):777–82
 75. Gerstenfeld LC, Sacks DJ, Pelis M, Mason ZD, Graves DT, Barrero M et al (2009) Comparison of effects of the bisphosphonate alendronate versus the RANKL inhibitor denosumab on murine fracture healing. *J Bone Miner Res* 24(2):196–208
 76. Mashiba T, Hirano T, Turner CH, Forwood MR, Johnston CC, Burr DB (2000) Suppressed bone turnover by bisphosphonates increases microdamage accumulation and reduces some biomechanical properties in dog rib. *J Bone Miner Res* 15(4):613–620
 77. Li C, Mori S, Li J, Kaji Y, Akiyama T, Kawanishi J et al (2001) Long-term effect of incadronate disodium (YM-175) on fracture healing of femoral shaft in growing rats. *J Bone Miner Res* 16(3):429–436
 78. Savaridas T, Wallace RJ, Salter DM, Simpson AHRW (2013) Do bisphosphonates inhibit direct fracture healing?: A laboratory investigation using an animal model. *Bone Joint J* 95-B(9):1263–8
 79. Odvina CV, Zerwekh JE, Rao DS, Maalouf N, Gottschalk FA, Pak CYC (2005) Severely suppressed bone turnover: a potential complication of alendronate therapy. *J Clin Endocrinol Metab* 90(3):1294–1301
 80. Xue D, Li F, Chen G, Yan S, Pan Z (2014) Do bisphosphonates affect bone healing? A meta-analysis of randomized controlled trials. *J Orthop Surg Res* 9:45
 81. Solomon DH, Hochberg MC, Mogun H, Schneeweiss S (2009) The relation between bisphosphonate use and non-union of fractures of the humerus in older adults. *Osteoporos Int* 20(6):895–901
 82. Rozental TD, Vazquez MA, Chacko AT, Ayogu N, Bouxsein ML (2009) Comparison of radiographic fracture healing in the distal radius for patients on and off bisphosphonate therapy. *J Hand Surg [Am]* 34(4):595–602
 83. Gong HS, Song CH, Lee YH, Rhee SH, Lee HJ, Baek GH (2012) Early initiation of bisphosphonate does not affect healing and outcomes of volar plate fixation of osteoporotic distal radial fractures. *J Bone Joint Surg Am* 94(19):1729–1736
 84. Ha KY, Park KS, Kim SI, Kim YH (2016) Does bisphosphonate-based anti-osteoporosis medication affect osteoporotic spinal fracture healing? *Osteoporos Int* 27(2):483–488
 85. Colón-Emeric C, Nordsletten L, Olson S, Major N, Boonen S, Haentjens P et al (2011) Association between timing of zoledronic acid infusion and hip fracture healing. *Osteoporos Int* 22(8):2329–2336
 86. Li YT, Cai HF, Zhang ZL (2015) Timing of the initiation of bisphosphonates after surgery for fracture healing: a systematic review and meta-analysis of randomized controlled trials. *Osteoporos Int* 26(2):431–441
 87. Lacey DL, Boyle WJ, Simonet WS, Kostenuik PJ, Dougall WC, Sullivan JK et al (2012) Bench to bedside: elucidation of the OPG-RANK-RANKL pathway and the development of denosumab. *Nat Rev Drug Discov* 11(5):401–419
 88. Flick LM, Weaver JM, Ulrich-Vinther M, Abuzzahab F, Zhang X, Dougall WC et al (2003) Effects of receptor activator of NF- κ B (RANK) signaling blockade on fracture healing. *J Orthop Res* 21(4):676–684
 89. Adami S, Libanati C, Boonen S, Cummings SR, Ho PR, Wang A et al (2012) Denosumab treatment in postmenopausal women with osteoporosis does not interfere with fracture-healing: results from the FREEDOM trial. *J Bone Joint Surg Am* 94(23):2113–2119
 90. Cao Y, Mori S, Mashiba T, Westmore MS, Ma L, Sato M et al (2002) Raloxifene, estrogen, and alendronate affect the processes of fracture repair differently in ovariectomized rats. *J Bone Miner Res* 17(12):2237–2246
 91. Tahami M, Haddad B, Abtahian A, Hashemi A, Aminian A, Konan S (2016) Potential role of local estrogen in enhancement of fracture healing: preclinical study in rabbits. *Arch Bone Joint Surg* 4(4):323–329

92. Bulbul M, Esenyel CZ, Esenyel M, Ayanoglu S, Bilgic B, Gulmez T (2008) Effects of calcitonin on the biomechanics, histopathology, and radiography of callus formation in rats. *J Orthop Sci* 13(2):136–144
93. Huusko TM, Karppi P, Kautiainen H, Suominen H, Avikainen V, Sulkava R (2002) Randomized, double-blind, clinically controlled trial of intranasal calcitonin treatment in patients with hip fracture. *Calcif Tissue Int* 71(6):478–484
94. Lyritis GP, Paspati I, Karachalios T, Ioakimidis D, Skarantavos G, Lyritis PG (1997) Pain relief from nasal salmon calcitonin in osteoporotic vertebral crush fractures. A double blind, placebo-controlled clinical study. *Acta Orthop Scand Suppl* 275:112–4
95. Liu GY, Cao GL, Tian FM, Song HP, Yuan LL, Geng LD et al (2017) Parathyroid hormone (1–34) promotes fracture healing in ovariectomized rats with type 2 diabetes mellitus. *Osteoporos Int* 28(10):3043–3053
96. Hurley M, Yao W, Lane NE (2005) Changes in serum fibroblast growth factor 2 in patients with glucocorticoid-induced osteoporosis treated with human parathyroid hormone (1–34). *Osteoporos Int* 16(12):2080–2084
97. Rao SK, Rao AP (2014) A literature review and case series of accelerating fracture healing in postmenopausal osteoporotic working women. *J Orthop* 11(3):150–152
98. Manabe T, Mori S, Mashiba T, Kaji Y, Iwata K, Komatsubara S et al (2007) Human parathyroid hormone (1–34) accelerates natural fracture healing process in the femoral osteotomy model of cynomolgus monkeys. *Bone* 40(6):1475–1482
99. Jerome CP, Peterson PE (2001) Nonhuman primate models in skeletal research. *Bone* 29(1):1–6
100. Ellegaard M, Kringelbach T, Syberg S, Petersen S, Beck Jensen JE, Brül A et al (2013) The effect of PTH(1–34) on fracture healing during different loading conditions. *J Bone Miner Res* 28(10):2145–2155
101. Kim HW, Jahng JS (1999) Effect of intermittent administration of parathyroid hormone on fracture healing in ovariectomized rats. *Iowa Orthop J* 19:71–77
102. Lin J, Wu J, Sun S, Chen K, Wu H, Lin R et al (2020) Combined antisclerostin antibody and parathyroid hormone (1–34) synergistically enhance the healing of bone defects in ovariectomized rats. *Z Gerontol Geriatr* 53(2):163–170
103. Kitaguchi K, Kashii M, Ebina K, Kaito T, Okada R, Makino T et al (2020) The combined effects of teriparatide and anti-RANKL monoclonal antibody on bone defect regeneration in ovariectomized mice. *Bone* 130:115077
104. Nozaka K, Miyakoshi N, Kasukawa Y, Maekawa S, Noguchi H, Shimada Y (2008) Intermittent administration of human parathyroid hormone enhances bone formation and union at the site of cancellous bone osteotomy in normal and ovariectomized rats. *Bone* 42(1):90–97
105. Eastman K, Gerlach M, Piec I, Greeves J, Fraser W (2021) Effectiveness of parathyroid hormone (PTH) analogues on fracture healing: a meta-analysis. *Osteoporos Int* 32(8):1531–1546
106. Kim SM, Kang KC, Kim JW, Lim SJ, Hahn MH (2017) Current role and application of teriparatide in fracture healing of osteoporotic patients: a systematic review. *J Bone Metab* 24(1):65–73
107. Aspenberg P, Genant HK, Johansson T, Nino AJ, See K, Krohn K et al (2010) Teriparatide for acceleration of fracture repair in humans: a prospective, randomized, double-blind study of 102 postmenopausal women with distal radial fractures. *J Bone Miner Res* 25(2):404–414
108. Aspenberg P, Johansson T (2010) Teriparatide improves early callus formation in distal radial fractures. *Acta Orthop* 81(2):234–236
109. Aspenberg P, Malouf J, Tarantino U, García-Hernández PA, Corradini C, Overgaard S et al (2016) Effects of teriparatide compared with risedronate on recovery after pertrochanteric hip fracture: results of a randomized, active-controlled, double-blind clinical trial at 26 weeks. *J Bone Joint Surg Am* 98(22):1868–1878
110. Lou S, Lv H, Wang G, Zhang L, Li M, Li Z et al (2016) The effect of teriparatide on fracture healing of osteoporotic patients: a meta-analysis of randomized controlled trials. *Biomed Res Int* 2016:6040379
111. Shi Z, Zhou H, Pan B, Lu L, Liu J, Kang Y et al (2016) Effectiveness of teriparatide on fracture healing: a systematic review and meta-analysis. *PLoS One* 11(12):e0168691
112. Miller PD, Hattersley G, Riis BJ, Williams GC, Lau E, Russo LA et al (2016) Effect of abaloparatide vs placebo on new vertebral fractures in postmenopausal women with osteoporosis: a randomized clinical trial. *JAMA* 316(7):722–733
113. Bernhardtsson M, Aspenberg P (2018) Abaloparatide versus teriparatide: a head to head comparison of effects on fracture healing in mouse models. *Acta Orthop* 89(6):674–677
114. Lim SY, Bolster MB (2017) Profile of romosozumab and its potential in the management of osteoporosis. *Drug Des Dev Ther* 11:1221–1231
115. Delgado-Calle J, Sato AY, Bellido T (2017) Role and mechanism of action of sclerostin in bone. *Bone* 96:29–37
116. Baron R, Kneissel M (2013) WNT signaling in bone homeostasis and disease: from human mutations to treatments. *Nat Med* 19(2):179–192
117. Schupbach D, Comeau-Gauthier M, Harvey E, Merle G (2020) Wnt modulation in bone healing. *Bone* 138:115491
118. Zhong N, Gersch RP, Hadjiargyrou M (2006) Wnt signaling activation during bone regeneration and the role of dishevelled in chondrocyte proliferation and differentiation. *Bone* 39(1):5–16
119. Montjovent MO, Siegrist M, Klenke F, Wetterwald A, Dolder S, Hofstetter W (2013) Expression of antagonists of WNT and BMP signaling after non-rigid fixation of osteotomies. *Bone* 53(1):79–86
120. McDonald MM, Morse A, Mikulec K, Peacock L, Yu N, Baldock PA et al (2012) Inhibition of sclerostin by systemic treatment with sclerostin antibody enhances healing of proximal tibial defects in ovariectomized rats. *J Orthop Res* 30(10):1541–1548
121. Liu Y, Rui Y, Cheng TY, Huang S, Xu L, Meng F et al (2016) Effects of sclerostin antibody on the healing of femoral fractures in ovariectomized rats. *Calcif Tissue Int* 98(3):263–274
122. Yee CS, Xie L, Hatsell S, Hum N, Murugesu D, Economides AN et al (2016) Sclerostin antibody treatment improves fracture outcomes in a type I diabetic mouse model. *Bone* 82:122–134
123. Alaei F, Virk MS, Tang H, Sugiyama O, Adams DJ, Stolina M et al (2014) Evaluation of the effects of systemic treatment with a sclerostin neutralizing antibody on bone repair in a rat femoral defect model. *J Orthop Res* 32(2):197–203
124. Virk MS, Alaei F, Tang H, Ominsky MS, Ke HZ, Lieberman JR (2013) Systemic administration of sclerostin antibody enhances bone repair in a critical-sized femoral defect in a rat model. *J Bone Joint Surg Am* 95(8):694–701
125. Suen PK, He YX, Chow DHK, Huang L, Li C, Ke HZ et al (2014) Sclerostin monoclonal antibody enhanced bone fracture healing in an open osteotomy model in rats. *J Orthop Res* 32(8):997–1005
126. Suen PK, Zhu TY, Chow DHK, Huang L, Zheng LZ, Qin L (2015) Sclerostin antibody treatment increases bone formation, bone mass, and bone strength of intact bones in adult male rats. *Sci Rep* 5:15632
127. Morse A, Yu NYC, Peacock L, Mikulec K, Kramer I, Kneissel M et al (2015) Endochondral fracture healing with external fixation in the Sost knockout mouse results in earlier fibrocartilage callus removal and increased bone volume fraction and strength. *Bone* 71:155–163
128. Ominsky MS, Li C, Li X, Tan HL, Lee E, Barrero M et al (2011) Inhibition of sclerostin by monoclonal antibody enhances bone healing and improves bone density and strength of nonfractured bones. *J Bone Miner Res* 26(5):1012–1021
129. Kruck B, Zimmermann EA, Damerow S, Figge C, Julien C, Wulsten D et al (2018) Sclerostin neutralizing antibody

- treatment enhances bone formation but does not rescue mechanically induced delayed healing. *J Bone Miner Res* 33(9):1686–1697
130. Viridi AS, Liu M, Sena K, Maletich J, McNulty M, Ke HZ et al (2012) Sclerostin antibody increases bone volume and enhances implant fixation in a rat model. *J Bone Joint Surg Am* 94(18):1670–1680
131. Agholme F, Li X, Isaksson H, Ke HZ, Aspenberg P (2010) Sclerostin antibody treatment enhances metaphyseal bone healing in rats. *J Bone Miner Res* 25(11):2412–2418
132. McDonald MM, Morse A, Birke O, Yu NYC, Mikulec K, Peacock L et al (2018) Sclerostin antibody enhances bone formation in a rat model of distraction osteogenesis. *J Orthop Res* 36(4):1106–1113
133. Schemitsch EH, Miclau T, Karachalios T, Nowak LL, Sancheti P, Poolman RW et al (2020) A randomized, placebo-controlled study of romosozumab for the treatment of hip fractures. *J Bone Joint Surg Am* 102(8):693–702
134. Bhandari M, Schemitsch EH, Karachalios T, Sancheti P, Poolman RW, Caminis J et al (2020) Romosozumab in skeletally mature adults with a fresh unilateral tibial diaphyseal fracture: a randomized phase-2 study. *J Bone Joint Surg Am* 102(16):1416–1426
135. Ominsky MS, Brown DL, Van G, Cordover D, Pacheco E, Frazier E et al (2015) Differential temporal effects of sclerostin antibody and parathyroid hormone on cancellous and cortical bone and quantitative differences in effects on the osteoblast lineage in young intact rats. *Bone* 81:380–391
136. Yukata K, Xie C, Li TF, Takahata M, Hoak D, Kondabolu S et al (2014) Aging periosteal progenitor cells have reduced regenerative responsiveness to bone injury and to the anabolic actions of PTH 1–34 treatment. *Bone* 62:79–89
137. Schmidhammer R, Zandieh S, Mittermayr R, Pelinka LE, Leixnering M, Hopf R et al (2006) Assessment of bone union/nonunion in an experimental model using microcomputed technology. *J Trauma* 61(1):199–205
138. Böhm AM, Jungkunz B (1999) Bending stiffness of healing fractures can be calculated from quantitative computed tomography. *Eur J Radiol* 30(1):28–32
139. Wright DA, Nam D, Whyne CM (2012) A comparison of stereology, structural rigidity and a novel 3D failure surface analysis method in the assessment of torsional strength and stiffness in a mouse tibia fracture model. *J Biomech* 45(13):2236–2240

Publisher's Note Springer Nature remains neutral with regard to jurisdictional claims in published maps and institutional affiliations.

Authors and Affiliations

M. Chandran¹  · K. E. Akesson² · M. K. Javaid³ · N. Harvey⁴ · R. D. Blank^{5,6} · M. L. Brandi⁷ · T. Chevalley⁸ · P. Cinelli⁹ · C. Cooper^{10,11} · W. Lems¹² · G. P. Lyritis¹³ · P. Makras¹⁴ · J. Paccou¹⁵ · D. D. Pierroz¹⁶ · M. Sosa¹⁷ · T. Thomas¹⁸ · S. Silverman¹⁹ · Fracture Working Group of the Committee of Scientific Advisors of the International Osteoporosis Foundation, on behalf of the International Osteoporosis Foundation, Société Internationale de Chirurgie Orthopédique et de Traumatologie

✉ M. Chandran
mchandran7@gmail.com

¹ Osteoporosis and Bone Metabolism Unit, Department of Endocrinology, Singapore General Hospital, DUKE NUS Medical School, Singapore, Singapore

² Clinical and Molecular Osteoporosis Research Unit, Department of Clinical Sciences, Lund University, Department of Orthopedics, Skåne University Hospital, Malmö, Sweden

³ NIHR Musculoskeletal Biomedical Research Unit, University of Oxford, Oxford, UK

⁴ MRC Lifecourse Epidemiology Centre, University of Southampton, NIHR Southampton Biomedical Research Centre, University of Southampton, University Hospital Southampton NHS Foundation Trust, Southampton, UK

⁵ Garvan Institute of Medical Research, Medical College of Wisconsin, Darlinghurst, NSW, Australia

⁶ Medical College of Wisconsin, Milwaukee, WI, USA

⁷ Department of Biomedical, Experimental and Clinical Sciences, University of Florence, Largo Palagi 1, Florence, Italy

⁸ Division of Bone Diseases, Geneva University Hospitals and Faculty of Medicine, Geneva, Switzerland

⁹ Department of Trauma Surgery, University Hospital Zurich and University of Zurich, Zurich, Switzerland

¹⁰ MRC Lifecourse Epidemiology Centre, University of Southampton, NIHR Southampton Biomedical Research Centre, University of Southampton, University Hospitals Southampton NHS Foundation Trust, Southampton, UK

¹¹ NIHR Oxford Biomedical Research Unit, University of Oxford, Oxford, UK

¹² Department of Rheumatology, Amsterdam UMC, Location VUmc, Amsterdam, The Netherlands

¹³ Hellenic Osteoporosis Foundation, Athens, Greece

¹⁴ Department of Medical Research, 251 Hellenic Air Force & VA General Hospital, Athens, Greece

¹⁵ Department of Rheumatology, MABlab ULR 4490, CHU Lille, Univ. Lille, 59000 Lille, France

¹⁶ International Osteoporosis Foundation, Nyon, Switzerland

¹⁷ University of Las Palmas de Gran Canaria, Investigation Group on Osteoporosis and Mineral Metabolism, Canary Islands, Spain

¹⁸ Department of Rheumatology, North Hospital, CHU Saint-Etienne and INSERM U1059, University of Lyon-University Jean Monnet, Saint-Etienne, France

¹⁹ Cedars-Sinai Medical Center and Geffen School of Medicine UCLA, Los Angeles, CA, USA