





Hereditary epidermolytic palmoplantar keratosis due to a novel desmoglein-1 mutation: A case report

Kevin Koschitzki¹  | Bernadett Kurz¹ | Julia Schreml² | Judith Fischer³ | Alrun Hotz³ | Christoph M. Hammers¹  | Mark Berneburg¹ | Dennis Niebel¹  | Stephan Schreml¹ 

¹Department of Dermatology, University Hospital Regensburg, Regensburg, Germany

²Institute of Human Genetics, University of Cologne, Cologne, Germany

³Institute of Human Genetics, University of Freiburg, Freiburg, Germany

Correspondence

Stephan Schreml, Department of Dermatology, University Hospital Regensburg, Franz-Josef-Strauß-Allee 11, 93053 Regensburg, Germany. Email: stephan.schreml@ukr.de

Key Clinical Message

Keratosis palmoplantaris striata type I (SPPK-I) is a rare autosomal-dominant type of hereditary epidermolytic palmoplantar keratoderma, which can be caused by mutations in desmoglein-1 (DSG-1). Patients suffer from hyperkeratotic plaques and painful palmoplantar fissures. Unfortunately, treatment options including salicylic vaseline, topical corticosteroids, phototherapy, and retinoids are inefficient.

Abstract

Hereditary palmoplantar keratodermas (PPKs) represent a heterogeneous group of rare skin disorders with epidermal palmoplantar hyperkeratosis. Mutations in the *desmoglein 1 gene (DSG1)*, a transmembrane glycoprotein, have been reported primarily in striate PPKs. We report a patient with keratosis palmoplantaris striata type I (SPPK-I) with a specific pathogenic variant [c.349C>T, p.(Arg117*)] in *DSG1*. Despite increased understanding, effective treatment options for PPK, including SPPK-I, remain limited.

KEYWORDS

disorders of cornification, desmoglein-1, keratoderma, palmoplantar

1 | INTRODUCTION

Hereditary palmoplantar keratodermas (PPKs) are classified either by their genetic mutation or by their clinical picture. The importance of identifying isolated forms from syndromic entities has major clinical and therapeutic relevance.¹ More than 69 different forms of PPK are known and can involve mutations in keratin (*KRT*), which are generally the most common subtypes and cause more diffuse forms often linked to epidermolytic ichthyosis.² PPK can also be

divided into four different types according to the clinical appearance of the hyperkeratosis: striate, punctate, focal, and diffuse PPK. Diffuse PPKs are the most common and striate PPK appears to be rare, and are commonly associated with syndromes, such as woolly hair syndrome.³ Mutations in *DSG1* cause striate SPPK-1; striate SPPK-2 is caused by desmoplakin (DSP) mutations and SPPK-3 results from heterozygous mutations in *KRT1*.⁴

We report a case of keratosis palmoplantaris striata type I (SPPK-I) with a novel specific pathogenic variant

Kevin Koschitzki and Bernadett Kurz contributed equally to this study.

This is an open access article under the terms of the [Creative Commons Attribution-NonCommercial-NoDerivs](https://creativecommons.org/licenses/by-nc-nd/4.0/) License, which permits use and distribution in any medium, provided the original work is properly cited, the use is non-commercial and no modifications or adaptations are made.

© 2024 The Authors. *Clinical Case Reports* published by John Wiley & Sons Ltd.

[c.349C>T, p.(Arg117*)] in *DSG1*, highlighting the genetic basis of SPPK-I and its association with altered desmoglein function.

2 | CASE HISTORY

2.1 | Patient information

A 31-year-old woman presented with painful palmoplantar hyperkeratotic plaques and rhagades (Figure 1A,B) that first appeared during puberty. She did not suffer from skin fragility, blistering, hair or nail involvement. There was no history of cardiac or any other internal diseases. Two of her six siblings as well as her father had the same skin condition. History of consanguinity in parents may point toward the presence of recessive variants. In our case, the parents were not consanguine. None of the family members had additional symptoms (e.g., deafness, cardiological involvement, and mental retardation).

2.2 | Clinical findings

Upon physical examination, striated yellowish to brownish, spongy hyperkeratoses were seen on the palmoplantar

side in pressure-exposed areas. In the plantar region, deep rhagades up to 2 cm long were also seen in the area of the hyperkeratoses.

3 | METHODS

3.1 | Diagnostic assessment

The patient underwent a lesion biopsy and histopathology of the ridged skin of the palm revealed orthohyperkeratosis and irregular acanthosis with a prominent stratum granulosum as well as akantolysis (Figure 2A,B). Transmission electron microscopy showed markedly elongated basal keratinocytes as well as numerous tonofilaments (Figure 2C). Next generation sequencing (NGS; Illumina MiSeq, 2×150bp, paired end) revealed a novel heterozygous pathogenic variant in exon 4 of desmoglein-1 (*DSG1*) [c.349C>T, p.(Arg117*)] (Figure 3) concluding the diagnosis of SPPK-I. This variant causes a premature stop and is assumed to result in loss of function (haploinsufficiency) and was classified as 5 (pathogenic) according to the American College of Medical Genetics and Genomics classification. No pathogenic mutations in *AQP5*, *CARD14*, *CAST*, *CTSC*, *GJB2*, *JUP*, *KRT1*, *KRT9*, *MBTPS2*, *NLRP1*, *POMP*, *SERPINB7*, *SERPINB8*, *SLURP1* or *TRPV3* were observed.

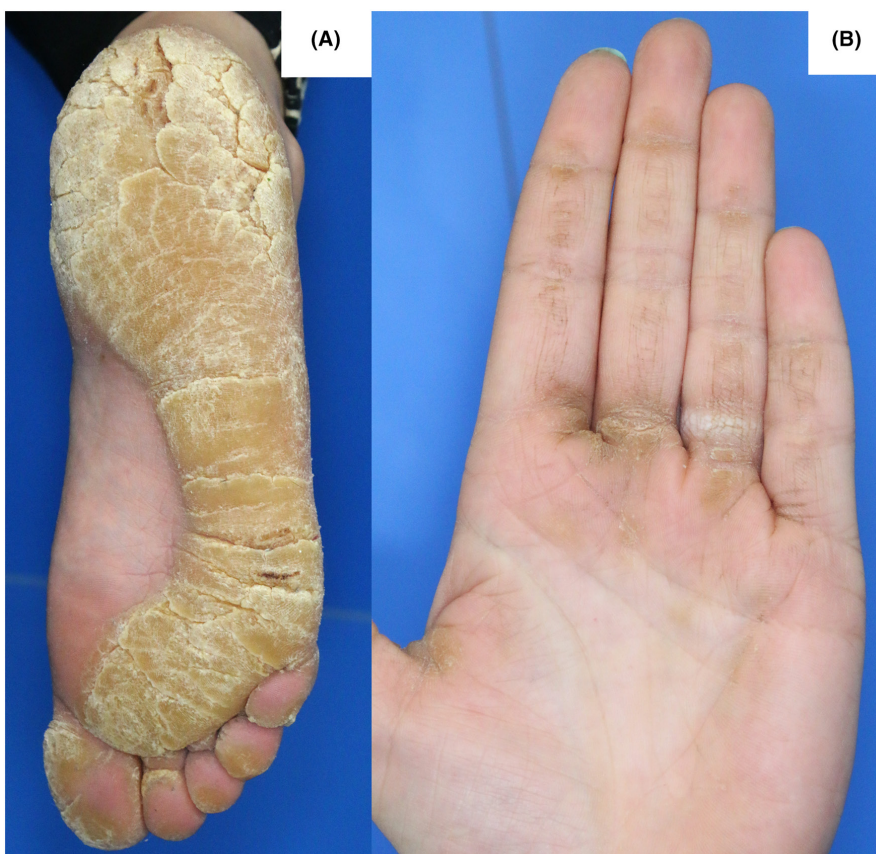

FIGURE 1 Clinical finding. (A, B) Palmoplantar hyperkeratosis and rhagades.

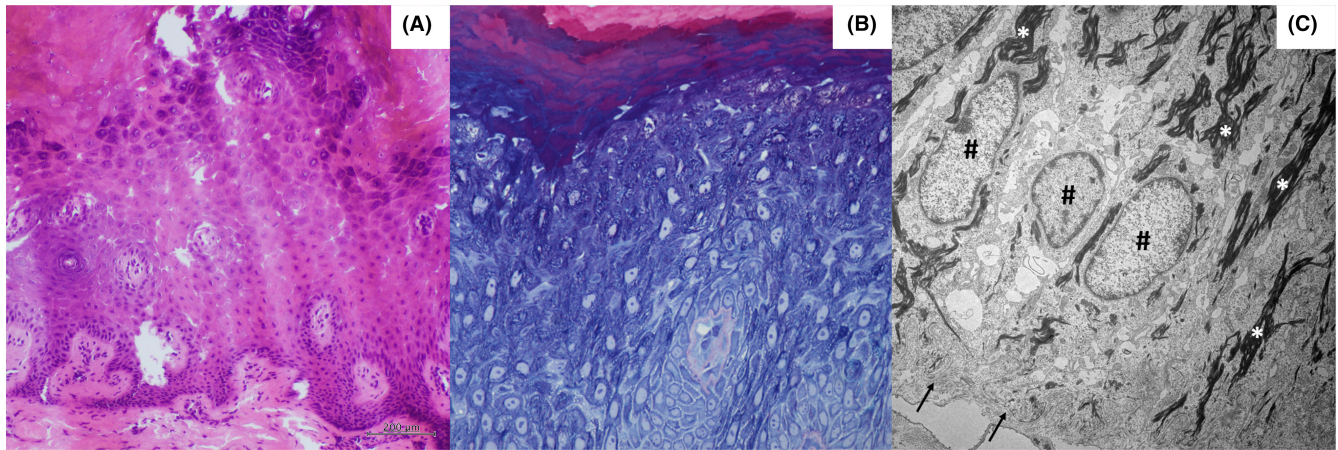
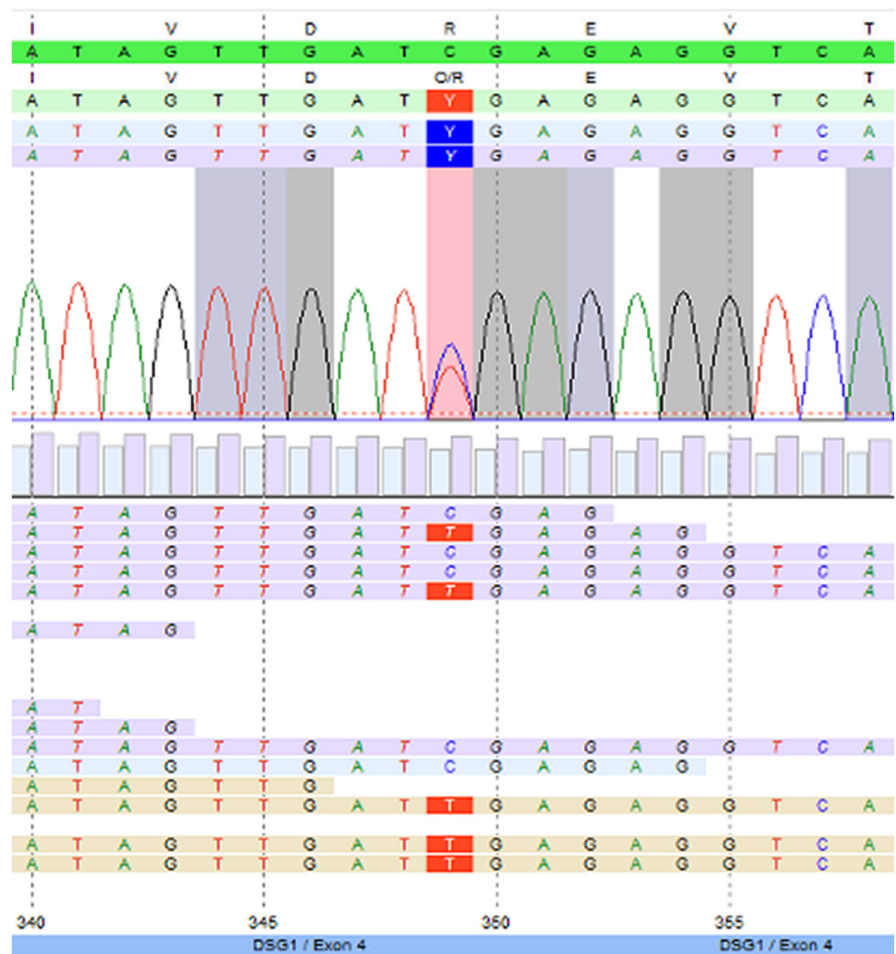


FIGURE 2 Histological and ultrastructural findings. (A) H&E staining: orthohyperkeratosis, hypergranulosis, and acantholysis. (B) Semi-thin section with toluidine blue and alkaline fuchsin: orthohyperkeratosis, hypergranulosis, and acantholysis. (C) Electron microscopy demonstrates markedly elongated basal keratinocytes. These cells (arrows) show elongated nuclei (#). Furthermore, numerous tonofilaments are visible (*).

FIGURE 3 Electropherogram of a novel heterozygous pathogenic variant in exon 4 of desmoglein-1 (*DSG1*) [c.349C>T, p.(Arg117*)].



3.2 | Therapeutic interventions and outcome

Treatment initially consisted of topical 20% salicylic-vaseline ointments and 1 mg/g mometasone furoate

applied on a once-daily basis. After 6 weeks, there was no improvement. Psoralen plus ultraviolet A therapy consisting of 45 sessions in a time span of 4 months resulted in a moderate but overall insufficient amelioration. Due to persisting hyperkeratosis with only slight

improvement in inflammation, topical corticosteroid therapy was discontinued in favor of systemic acitretin 20 mg once daily. However, the skin condition did not improve.

4 | DISCUSSION

In summary, our female patient presented with painful palmoplantar fissures and hyperkeratotic plaques. Histopathology revealed orthohyperkeratosis as well as an irregular acanthosis with a prominent stratum granulosum as well as acantholysis. NGS showed a heterozygous pathogenic variant in exon 4 of *DSG1* [c.349C>T, p.(Arg117*)]. These findings could indicate a type of palmoplantar keratosis. Hereditary PPKs can be classified either by their genetic mutation or by their clinical picture.² The importance of identifying isolated forms from syndromic entities has major clinical and therapeutic relevance.

The clinical history is crucial to differentiate between acquired and congenital causes of palmoplantar hyperkeratosis. Acquired causes would include atopic dermatitis, psoriasis, HIV infection, or exposure to chemicals such as arsenic and many more.⁵ None of these were present in our patient, so we considered whether there might be a genetic cause, which leads to NGS. More than 69 different forms of PPK are known and can involve mutations in *KRT*, which are generally the most common subtypes and cause more diffuse forms often linked to epidermolytic ichthyosis.^{2,6} Other forms are due to variants in lorincrin (which causes mutilating PPK), connexins (often related to syndromal PPKs), as well as variants in cathepsin, aquaporin, and chloride channels.^{4,5} In our case, we found a novel heterozygous pathogenic variant in exon 4 of *DSG1* [c.349C>T, p.(Arg117*)], which fits the clinical diagnosis of keratosis palmoplantaris striata type I (SPPK-I).

While the name keratosis palmoplantaris striata and areata type I already indicates the clinical subgroup of the rare “striate” forms which are separated from diffuse, focal, and punctuate types, the disease is caused by a mutation of *DSG1* and therefore belongs to the genetic subgroup of desmosomopathies.

Mutations in *DSG1* cause striate SPPK-1 (characterized by localized lesions in the majority of cases), Striate SPPK-2 is caused by *DSP* mutations (characterized by more focal lesions with fissures), and SPPK-3 results from heterozygous mutations in *KRT1* (diffuse plantar changes).⁴

DSG-1 is mainly expressed in the suprabasal layers of the epidermis and mucosa, and codes for the protein desmoglein. It consists of the Greek words “desmos” and “glein” which stand for “tie” and “glue like,” respectively. Desmoglein creates calcium-dependent heterophilic

bindings with desmocollins of adjacent cells in its extracellular domain, while the intracytoplasmic domain binds plakoglobin and links keratin cytoskeletons.⁷ *DSG-1* is therefore essential for the intercellular adhesive function of desmosomes which are in general abundant in cells prone to higher amounts of mechanical stress.⁷⁻⁹ In SPPK-1, the mutation of *DSG1* causes an alteration in the extracellular domain of desmoglein,⁷ which leads to haploinsufficiency via nonsense-mediated mRNA decay. In severe skin dermatitis, multiple allergies and the metabolic wasting (SAM) syndrome, there is a significant reduction or absence of *DSG1* from the cell membrane. This deficiency may arise from various factors such as failure in *DSG1* localization, decreased *DSG1* expression, or nonsense-mediated mRNA decay.¹⁰ *DSG1* also interacts with Erbin, thereby inhibiting the Ras/MAPK pathway, which leads to elevated Ras activity, resulting from inadequate or absent *DSG1*.¹¹

Diagnosis is based on the clinical findings, histology and positive family history given the autosomal dominant inheritance. Despite the clinical, histological, and electron microscopic features of the disease, genetic testing is required for exact diagnosis.³

Furthermore, syndromic PPK must be ruled out. Potential symptoms pointing toward syndromic PPK include deafness, cardiologic involvement, or mental retardation.²

Treatment options consist of keratolysis and mechanical relief by wearing customized shoes to reduce pressure.⁴ Systemic retinoids have to be used carefully in epidermolytic PPKs, which can exacerbate upon medication with acitretin or alitretinoin.

Unfortunately, treatment options of PPKs are still not promising despite the wide knowledge of the individual forms and their pathophysiology.

This case presents SPPK-I, a rare hereditary skin disorder, resulting from mutations in the *DSG-1* gene, causing painful palmoplantar fissures and hyperkeratotic plaques. A specific novel pathogenic variant [c.349C>T, p.(Arg117*)] in *DSG1* was identified, highlighting the genetic basis of SPPK-I and its association with altered desmoglein function. The mutation leads to characteristic longitudinal hyperkeratosis on palms and soles. SPPK-I is part of a diverse group of over 69 palmoplantar keratosis (PPK) forms, diagnosed based on clinical findings and family history. Despite increased understanding, effective treatment options for PPK, including SPPK-I, remain limited.

AUTHOR CONTRIBUTIONS

Kevin Koschitzki: Investigation; writing – original draft. **Bernadett Kurz:** Writing – review and editing. **Julia Schreml:** Formal analysis. **Judith Fischer:** Conceptualization; writing – review and editing. **Alrun**

Hotz: Formal analysis. **Christoph M. Hammers:** Writing – review and editing. **Mark Berneburg:** Writing – review and editing. **Dennis Niebel:** Formal analysis; writing – review and editing. **Stephan Schreml:** Conceptualization; formal analysis; resources; writing – original draft; writing – review and editing.

ACKNOWLEDGMENTS

The authors have nothing to report. Open Access funding enabled and organized by Projekt DEAL.

FUNDING INFORMATION

None.

CONFLICT OF INTEREST STATEMENT

All Authors have no conflict of interest to declare.

DATA AVAILABILITY STATEMENT

The data that support the findings of this study are available upon reasonable request.

ETHICS STATEMENT

Ethical approval is not required for this study in accordance with local or national guidelines.

CONSENT

Written informed consent was obtained from the patient for publication of the details of their medical case and any accompanying images.

ORCID

Kevin Koschitzki  <https://orcid.org/0000-0001-5659-124X>

Christoph M. Hammers  <https://orcid.org/0000-0001-5631-2415>

Dennis Niebel  <https://orcid.org/0000-0003-2069-0486>

Stephan Schreml  <https://orcid.org/0000-0002-2820-1942>

REFERENCES

- Dev T, Mahajan VK, Sethuraman G. Hereditary palmoplantar keratoderma: a practical approach to the diagnosis. *Indian Dermatol Online J*. 2019;10(4):365-379. doi:10.4103/idoj.IDOJ_367_18
- Harjama L, Karvonen V, Kettunen K, et al. Hereditary palmoplantar keratoderma–phenotypes and mutations in 64 patients. *J Eur Acad Dermatol Venereol*. 2021;35(9):1874-1880. doi:10.1111/jdv.17314
- Sakiyama T, Kubo A. Hereditary palmoplantar keratoderma "clinical and genetic differential diagnosis". *J Dermatol*. 2016;43(3):264-274. doi:10.1111/1346-8138.13219
- Has C, Technau-Hafsi K. Palmoplantar keratodermas: clinical and genetic aspects. *J Dtsch Dermatol Ges*. 2016;14(2):123-139; quiz 140. doi:10.1111/ddg.12930
- Schiller S, Seebode C, Hennies HC, Giehl K, Emmert S. Palmoplantare Keratosen (PPK): erworbene und genetische Ursachen eines gar nicht so seltenen Krankheitsbildes. *JDDG: J Dtsch Dermatol Ges*. 2014;12(9):781-788. doi:10.1111/ddg.12418_suppl
- Arin MJ, Oji V, Emmert S, et al. Expanding the keratin mutation database: novel and recurrent mutations and genotype-phenotype correlations in 28 patients with epidermolytic ichthyosis. *Br J Dermatol*. 2011;164(2):442-447. doi:10.1111/j.1365-2133.2010.10096.x
- Whitlock NV, Bower C. Targetting of desmoglein 1 in inherited and acquired skin diseases. *Clin Exp Dermatol*. 2003;28(4):410-415. doi:10.1046/j.1365-2230.2003.01311.x
- Samuelov L, Sarig O, Harmon RM, et al. Desmoglein 1 deficiency results in severe dermatitis, multiple allergies and metabolic wasting. *Nat Genet*. 2013;45(10):1244-1248. doi:10.1038/ng.2739
- Hammers CM, Stanley JR. Desmoglein-1, differentiation, and disease. *J Clin Invest*. 2013;123(4):1419-1422. doi:10.1172/jci69071
- Lovgren ML, McAleer M, Irvine A, et al. Mutations in desmoglein 1 cause diverse inherited palmoplantar keratoderma phenotypes: implications for genetic screening. *Br J Dermatol*. 2017;176(5):1345-1350. doi:10.1111/bjd.14973
- Harmon RM, Simpson CL, Johnson JL, et al. Desmoglein-1/Erbin interaction suppresses ERK activation to support epidermal differentiation. *J Clin Invest*. 2013;123(4):1556-1570. doi:10.1172/jci65220

How to cite this article: Koschitzki K, Kurz B, Schreml J, et al. Hereditary epidermolytic palmoplantar keratosis due to a novel desmoglein-1 mutation: A case report. *Clin Case Rep*. 2024;12:e8881. doi:10.1002/ccr3.8881