



**University of
Zurich**^{UZH}

**Zurich Open Repository and
Archive**

University of Zurich
University Library
Strickhofstrasse 39
CH-8057 Zurich
www.zora.uzh.ch

Year: 2024

Bilateral phrenic nerve block to reduce hazardous respiratory drive in a mechanically ventilated patient with COVID-19—A case report

Levis, Anja ; Gardill, Michael ; Bachmann, Kaspar F ; Berger, David ; Schandl, Christian ; Piquilloud, Lise ;
Haenggi, Matthias

DOI: <https://doi.org/10.1002/ccr3.8850>

Posted at the Zurich Open Repository and Archive, University of Zurich

ZORA URL: <https://doi.org/10.5167/uzh-260580>

Journal Article

Published Version



The following work is licensed under a Creative Commons: Attribution-NonCommercial-NoDerivatives 4.0 International (CC BY-NC-ND 4.0) License.


Originally published at:

Levis, Anja; Gardill, Michael; Bachmann, Kaspar F; Berger, David; Schandl, Christian; Piquilloud, Lise; Haenggi, Matthias (2024). Bilateral phrenic nerve block to reduce hazardous respiratory drive in a mechanically ventilated patient with COVID-19—A case report. *Clinical Case Reports*, 12(5):e8850.

DOI: <https://doi.org/10.1002/ccr3.8850>

CASE REPORT

Bilateral phrenic nerve block to reduce hazardous respiratory drive in a mechanically ventilated patient with COVID-19—A case report

Anja Levis^{1,2} | Michael Gardill¹ | Kaspar F. Bachmann¹ | David Berger¹ |
Christian Schandl³ | Lise Piquilloud⁴ | Matthias Haenggi¹ 

¹Department of Intensive Care Medicine, Inselspital, Bern University Hospital, University of Bern, Bern, Switzerland

²Department of Anesthesiology and Pain Medicine, Inselspital, Bern University Hospital, University of Bern, Bern, Switzerland

³Department of Intensive Care Medicine, Cantonal Hospital Winterthur, Winterthur, Switzerland

⁴Adult Intensive Care Unit, Lausanne University Hospital (CHUV), University of Lausanne, Lausanne, Switzerland

Correspondence

Matthias Haenggi, Department of Intensive Care Medicine, Inselspital, Bern University Hospital, University of Bern, Bern, Switzerland.

Email: matthias.haenggi@usz.ch

Key Clinical Message

Forced inspiration during mechanical ventilation risks self-inflicted lung injury. However, controlling it with sedation or paralysis may cause polyneuropathy and myopathy. We tested bilateral phrenic nerve paralysis with local anesthetic in a patient, showing reduced inspiratory force. This offers an alternative to drug-induced muscle paralysis.

Abstract

Mechanical ventilation, although a life-saving measure, can also pose a risk of causing lung injury known as “ventilator-induced lung injury” or VILI. Patients undergoing mechanical ventilation sometimes exhibit heightened inspiratory efforts, wherein the negative pressure generated by the respiratory muscles adds to the positive pressure generated by the ventilator. This combination of high pressures can lead to a syndrome similar to VILI, referred to as “patient self-inflicted lung injury” or P-SILI. Prevention of P-SILI requires the administration of deep sedation and muscle paralysis to the patients, but both these measures can have undesired effects on their health. In this case report, we demonstrate the effect of a bilateral phrenic nerve block aiming to reduce excessive inspiratory respiratory efforts in a patient suffering from COVID-19 pneumonitis.

KEYWORDS

acute respiratory distress syndrome, ARDS prevention and control, ARDS therapy, SARS-CoV-2 infection

1 | INTRODUCTION

Acute respiratory distress syndrome (ARDS) is a severe form of respiratory failure. A variety of underlying conditions may result in its occurrence, such as pneumonia, sepsis, trauma, or aspiration. ARDS is characterized by

the rapid onset of severe hypoxemia, bilateral pulmonary infiltrates, and respiratory distress, and it is associated with high morbidity and mortality rates.^{1,2}

Clinical management of ARDS involves the use of mechanical ventilation. While mechanical ventilation can be a life-saving intervention, it is not without potential

This is an open access article under the terms of the [Creative Commons Attribution-NonCommercial-NoDerivs](https://creativecommons.org/licenses/by-nc-nd/4.0/) License, which permits use and distribution in any medium, provided the original work is properly cited, the use is non-commercial and no modifications or adaptations are made.

© 2024 The Authors. *Clinical Case Reports* published by John Wiley & Sons Ltd.

risks and complications. One of the main hazards associated with mechanical ventilation is high driving pressure, which can cause lung injury by itself and worsen the severity of ARDS.³ Patients themselves can generate excessive driving pressures during mechanical ventilation, which may lead to a type of lung injury known as patient self-inflicted lung injury (P-SILI).^{4–6}

Strategies aimed at reducing the risk of P-SILI during mechanical ventilation include the use of deep sedation and muscle paralysis.⁷ However, it is important to note that these interventions may also lead to their own set of complications and side effects as ICU-acquired weakness of delirium.⁸

Unilateral phrenic nerve block with diaphragm palsy occurred as a side effect of local anesthesia for jugular vein catheterization using the landmark technique⁹ and may also be observed during scalene or cervical nerve block.¹⁰ While most patients tolerate this condition, it may cause respiratory insufficiency in patients who are already at the margin of their respiratory reserve.

The COVID-19 pandemic has resulted in a significant influx of critically ill patients with severe ARDS who required mechanical ventilation in the intensive care unit (ICU). A substantial proportion of these patients exhibited an unusually high respiratory drive and required extended periods of deep sedation and muscle paralysis to prevent the development of P-SILI.¹¹

In this case report, we present the effects of a bilateral phrenic nerve block in an attempt to reduce respiratory drive and avoid the side effects of deep sedation and muscle relaxation. For case presentation, we followed CARE reporting guidelines,¹² and the patient provided written informed consent for publication.

2 | CASE PRESENTATION

In December 2020, a 40-year-old female patient with a medical history of lupus erythematosus and a renal transplant presented with typical symptoms of COVID-19. A PCR test 2 days prior to admission confirmed the diagnosis. The patient's respiratory insufficiency continued to worsen, leading to hospital admission and subsequent transfer to the ICU of the Inselspital Bern. She required intubation and mechanical ventilation. A CT scan revealed extensive infiltrates typical of COVID-19 infection. Oxygenation could only be maintained with prone positioning, deep sedation, and muscle paralysis. When muscle paralysis and sedation were reduced, high driving pressures that could potentially lead to P-SILI became a clinical concern.

In an attempt to aid in the process of weaning the patient from continuous muscle paralysis, an ultrasound-guided bilateral phrenic nerve block was performed.

3 | METHODS

The patient was ventilated with a Hamilton C-6 mechanical ventilator (Hamilton Medical, Bonaduz, Switzerland) that included an esophageal balloon catheter (NutriVent, SIDAM S.R.L., Mirandola (MO) Italy) for measuring intrathoracic (i.e., pleural) pressure to help guide mechanical ventilation. A data logger (Memory Box, Hamilton Medical, Bonaduz, Switzerland) retrieved the ventilator curves.

The phrenic nerve was located by high-resolution ultrasound (SonoSite X-Porte Ultrasound System, HFL50xp (15–6 MHz) transducer) as a hypoechoic structure running superficially to the anterior scalene muscle (ASM) from its lateral to the medial border. Mepivacaine 1% (Mepivacain, Institut für Spitalpharmazie, Bern) was administered at the origin of this structure from the brachial plexus at the level of the interscalene groove and along its course over the ASM, under direct visualization of the local anesthetic's spread around the nerve and the medial border of the ASM. A total of 13 mL was administered on the left side and 9 mL on the right side. The procedure required approximately 20 min per side to complete.

4 | RESULTS

The impact on ventilatory drive was observable within 5 min after completion, with almost complete attenuation of inspiratory effort (see [Figure 1A](#), for details B and C).

5 | DISCUSSION

Following the procedure, an instantaneous effect on intrathoracic pressure oscillations was evident in our patient. Before the block, transpulmonary pressure (pressure difference between the alveolar space and the pleural space) could only be estimated, as the high respiratory drive with flow starvation made the plateau pressure unmeasurable. With the ventilator settings given, we assume a transpulmonary pressure of 36 cmH₂O (estimated plateau pressure of 28 cmH₂O – maximal negative intrathoracic/plateau pressure of –8 cmH₂O) before intervention, which fell to 18 cmH₂O after the intervention.

The use of mechanical ventilation has saved thousands of patients with ARDS. However, it was realized early after the initial description of the syndrome¹³ that mechanical ventilation can cause lung injury on its own, known as ventilator-induced lung injury (VILI).¹⁴ Uneven distribution of mechanical stress and strain on the alveoli causes cyclic closure and reopening, collapse, and overdistension.¹⁵ As a result of this energy transfer,

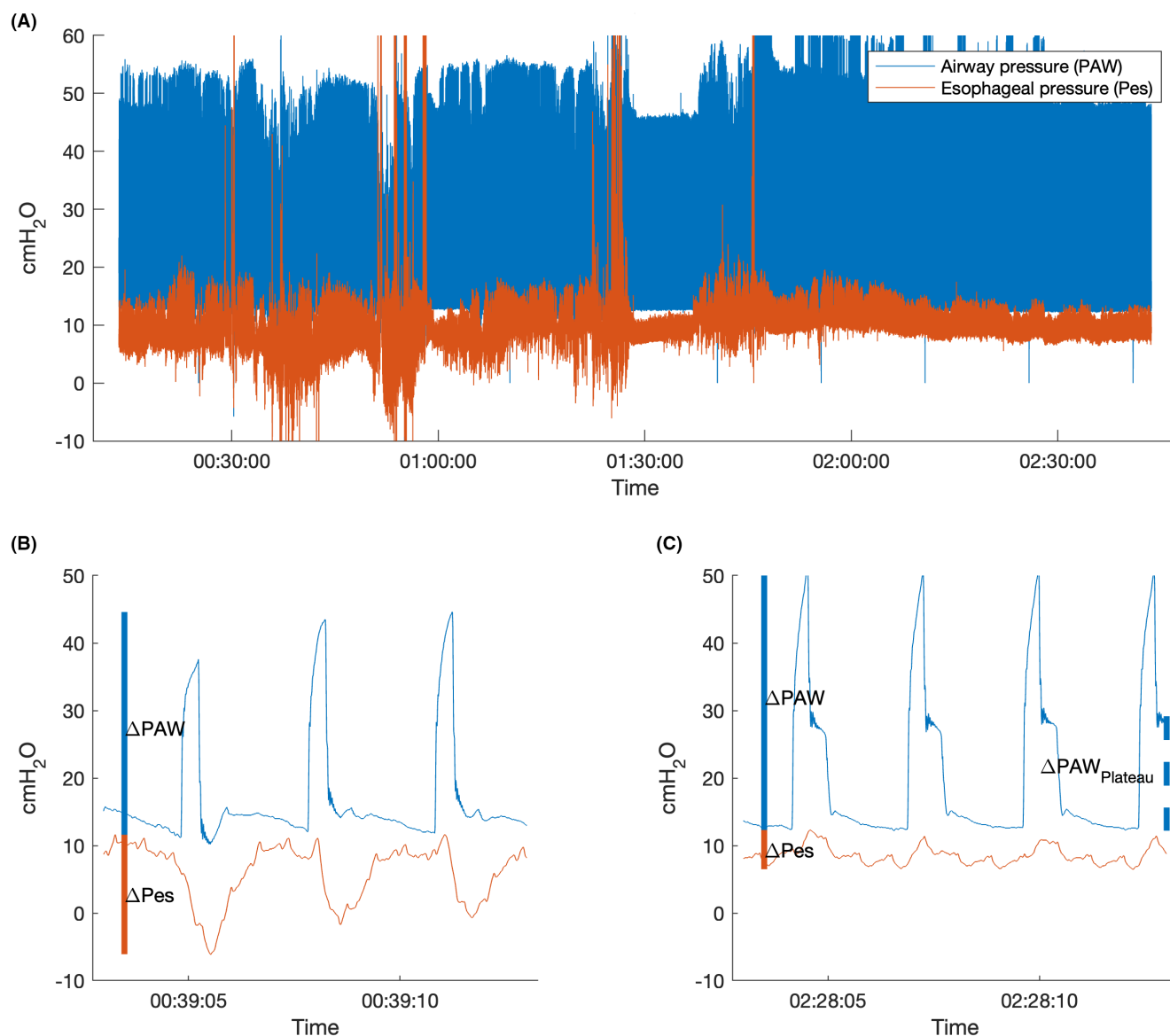


FIGURE 1 (A) Airway pressure tracing from the mechanical ventilator P_{AW} (blue) and intrathoracic pressure tracing from the esophageal balloon catheter P_{es} (orange) over time. The procedure started at 0:45 hours after start recording and finished at 1:30 hours. The patient was ventilated in an assisted volume-controlled, time-cycled mode with 12 cmH₂O PEEP. In the first hour of recording large variations in airway pressures can be seen, and variable, even negative intrathoracic (and therefore pleural) pressures can be identified, indicating enhanced respiratory efforts. (B) High-resolution image of (A), exemplary at 39 min after recording started. Esophageal pressure swings from +10 to -8 cmH₂O can be identified (ΔP_{es}), the ventilator's "plateau pressure" (static pressure measured in the respiratory system after inspiration, when all valves are closed and flow equals "0," reflecting intraalveolar pressure) is artificially abolished by the high inspiratory effort. (C) High-resolution image of (A), exemplary after bilateral phrenic nerve block. Esophageal pressure swings (ΔP_{es}) are now positive with very low amplitude, indicating passive ventilation. The airway plateau pressure can now be identified at 28 cmH₂O.

tight junctions are disrupted, leading to the leakage of plasma fluids into the interstitium and causing inflammation.¹⁶ To mitigate the side effects of mechanical ventilation, various strategies have been developed, such as the implementation of positive end-expiratory pressure (PEEP) to counteract the cyclic closure and reopening of the alveoli,¹³ reducing tidal volumes to limit plateau airway pressure,¹⁷ and restricting driving

pressure (plateau airway pressure – PEEP).³ While the airway pressure measurements are easily obtained from the ventilator, since they are measured in the ventilator's circuit, they may not accurately reflect the pressure differences across the alveolar membrane. In certain patients, such as those who are obese or have high intraabdominal pressure, the pressure in the pleural space can be elevated, which makes airway and plateau pressures

unreliable for the estimation of transpulmonary pressure in ARDS.¹⁸ The pressure in the pleural space is required to assess transpulmonary pressure, that is, the pressure across the alveolar walls. Pleural pressure can be estimated by measuring esophageal pressure with a balloon (such as one mounted on a feeding tube).^{19,20}

Routine measurements of esophageal pressure have drawn attention to a previously unnoticed phenomenon. During forced inspiration, excessive negative pleural pressures can generate dangerously high transpulmonary pressures if extensive positive pressures are added by the ventilator. This patient self-inflicted lung injury (P-SILI), equivalent to ventilator-induced lung injury (VILI), can cause harm to the lungs.⁴

Our patient experienced forced inspiratory negative pressure, which exceeded the limits of safe mechanical ventilation. This phenomenon is often observed in patients with COVID-19, but it is not exclusive to this disease and is frequently recognized in patients with widespread diffuse pulmonary inflammation.²¹ Although the precise mechanism is not fully understood, we believe that pulmonary mechanical stretch receptors may be affected and the feedback loop to relevant control centers in the brain stem is disturbed. This theory may provide an explanation for the “happy hypoxia” phenomenon commonly observed in the early stages of COVID-19 disease in which patients experience severe hypoxia after a period of extensive respiratory effort breathing but do not appear to experience any respiratory distress.²²

Our patient in the case vignette returned to the pathologically high ventilator drive pattern after the mepivacain weaned off, and the phrenic nerve block was not repeated with a longer-acting anesthetic due to missing expertise. She was treated with deep sedation and further muscle paralysis, and after a prolonged period of mechanical ventilation with tracheostomy and several failed weaning attempts, she recovered well to her baseline condition after a long rehabilitation.

Meanwhile, a case report from Japan detailed the successful implementation of catheter-based bilateral phrenic nerve block on two patients with COVID-19.²³ The report demonstrated the impact on ventilatory drive through esophageal pressure and diaphragm electromyography.²³ In 2022, Amato and colleagues from Brazil reported on the results of blocking the phrenic nerves bilaterally in nine COVID-19 patients, following an animal experiment conducted on pigs.²⁴ Using 15 mL lidocaine 2%, the group reported an effect similar to that of our patient, which lasted for 12 h. Our patient was administered 22 mL of 1% mepivacaine (equivalent to 220 mg), whereas Brazilian patients were given 300 mg of lidocaine. Both doses were below the recommended

maximum doses (lidocaine <4.5 mg/kg body weight, mepivacaine <5 mg/kg). Both drugs share similar onset and duration characteristics, but mepivacaine has a slightly better safety profile.

Upon close inspection of the pressure tracings, it can be observed that the diaphragm respiratory muscle seems to contract after the ventilator initiates the breath. Patients sometimes experience a phenomenon called “reverse triggering,” where each external mechanical breath triggers a spontaneous breath by the patient.²⁵ While reverse triggering cannot be entirely dismissed as a possibility for this patient, we do not think this is the case here since it is an infrequent occurrence. Additionally, the presence of excessive inspiratory efforts is not observed during reverse triggering.

We will assess the effect of the here-described intervention and its influence on respiratory drive including reverse triggering in an ongoing prospective, non-randomized, open-label pilot study including 10 patients suffering from severe ARDS, focusing on feasibility and efficacy of suppressing forced inspiratory efforts. We aim to administer a secure alternative therapy to individuals who exhibit excessive inspiratory efforts, in order to avoid the potential hazards of prolonged high-dose sedation and muscle paralysis.

Integrating phrenic nerve block into the ARDS patient treatment plan may face various obstacles. Firstly, there must be a sufficient number of skilled personnel proficient in conducting the block, especially in challenging scenarios such as when there's a risk of bleeding. Furthermore, ensuring consistent application via a catheter placed accurately is vital to prevent the potential hazards linked with incorrect local anesthetic administration. Additionally, prolonged use of local anesthetic may lead to toxicity and enduring complications, underscoring the need for thoughtful consideration.

In conclusion, bilateral phrenic blockade can be used to diminish the effects of exaggerated ventilator drive. It has the potential to reduce the risk of self-inflicted lung injury, without the need for pharmacological muscle paralysis and deep sedation. This might mitigate the well-known risks of sedation/paralysis but needs to be confirmed in a larger trial.

AUTHOR CONTRIBUTIONS

Anja Levis: Conceptualization; investigation; methodology; supervision; writing – original draft. **Michael Gardill:** Conceptualization; data curation; formal analysis; validation; writing – review and editing. **Kaspar F. Bachmann:** Data curation; methodology; validation; visualization; writing – review and editing. **David Berger:** Formal analysis; methodology; validation; writing – review and editing. **Christian Schandl:** Formal analysis;

validation; writing – review and editing. **Lise Piquilloud:** Conceptualization; formal analysis; methodology; validation; writing – review and editing. **Matthias Haenggi:** Conceptualization; formal analysis; investigation; methodology; project administration; supervision; validation; writing – review and editing.

FUNDING INFORMATION

This research did not receive specific funding but was performed as part of the employment of the authors (Inselspital Bern, Kantonsspital Winterthur; Centre Hospitalier Universitaire Vaudois in Lausanne).

CONFLICT OF INTEREST STATEMENT

The authors declare that they do not have any conflict of interest regarding this case report.

DATA AVAILABILITY STATEMENT

The data that support the findings of this study are available from the corresponding author upon reasonable request.

CONSENT

The patient provided written consent to publish her data.

ORCID

Matthias Haenggi  <https://orcid.org/0000-0001-5845-031X>

REFERENCES

- Ranieri VM, Rubenfeld GD, Thompson BT, et al. Acute respiratory distress syndrome: the Berlin definition. *JAMA*. 2012;307(23):2526-2533. doi:10.1001/jama.2012.5669
- Bellani G, Laffey JG, Pham T, et al. Epidemiology, patterns of care, and mortality for patients with acute respiratory distress syndrome in intensive care units in 50 countries. *JAMA*. 2016;315(8):788-800. doi:10.1001/jama.2016.0291
- Amato MB, Meade MO, Slutsky AS, et al. Driving pressure and survival in the acute respiratory distress syndrome. *N Engl J Med*. 2015;372(8):747-755. doi:10.1056/NEJMs1410639
- Brochard L, Slutsky A, Pesenti A. Mechanical ventilation to minimize progression of lung injury in acute respiratory failure. *Am J Respir Crit Care Med*. 2017;195(4):438-442. doi:10.1164/rccm.201605-1081CP
- Yoshida T, Grieco DL, Brochard L, Fujino Y. Patient self-inflicted lung injury and positive end-expiratory pressure for safe spontaneous breathing. *Curr Opin Crit Care*. 2020;26(1):59-65. doi:10.1097/mcc.0000000000000691
- Yoshida T, Torsani V, Gomes S, et al. Spontaneous effort causes occult pendelluft during mechanical ventilation. *Am J Respir Crit Care Med*. 2013;188(12):1420-1427. doi:10.1164/rccm.201303-0539OC
- Papazian L, Forel JM, Gacouin A, et al. Neuromuscular blockers in early acute respiratory distress syndrome. *N Engl J Med*. 2010;363(12):1107-1116. doi:10.1056/NEJMoa1005372
- Devlin JW, Skrobik Y, Gelinas C, et al. Clinical practice guidelines for the prevention and Management of Pain, agitation/sedation, delirium, immobility, and sleep disruption in adult patients in the ICU. *Crit Care Med*. 2018;46(9):e825-e873. doi:10.1097/CCM.0000000000003299
- Haro M, Izquierdo M, Vizcaya M, Catalan B, Manso F, Martinez-Moratalla J. Paralisis Diafragmatica Como Complicacion de Una Puncion de la Vena Yugular Interna [Diaphragm paralysis as a complication of internal jugular vein puncture]. *Arch Bronconeumol*. 1996;32(2):105-107. doi:10.1016/s0300-2896(15)30819-x
- Opperer M, Kaufmann R, Meissnitzer M, et al. Depth of cervical plexus block and phrenic nerve blockade: a randomized trial. *Reg Anesth Pain Med*. 2022;47(4):205-211. doi:10.1136/rapm-2021-102851
- Marini JJ, Gattinoni L. Management of COVID-19 respiratory distress. *JAMA*. 2020;323(22):2329-2330. doi:10.1001/jama.2020.6825
- Gagnier JJ, Kienle G, Altman DG, et al. The CARE guidelines: consensus-based clinical case report guideline development. *J Clin Epidemiol*. 2014;67(1):46-51. doi:10.1016/j.jclinepi.2013.08.003
- Ashbaugh DG, Bigelow DB, Petty TL, Levine BE. Acute respiratory distress in adults. *Lancet*. 1967;2(7511):319-323. doi:10.1016/s0140-6736(67)90168-7
- Dreyfuss D, Saumon G. Ventilator-induced lung injury: lessons from experimental studies. *Am J Respir Crit Care Med*. 1998;157(1):294-323. doi:10.1164/ajrccm.157.1.9604014
- Gattinoni L, Tonetti T, Quintel M. Regional physiology of ARDS. *Crit Care*. 2017;21(Suppl 3):312. doi:10.1186/s13054-017-1905-9
- Dreyfuss D, Soler P, Basset G, Saumon G. High inflation pressure pulmonary edema. Respective effects of high airway pressure, high tidal volume, and positive end-expiratory pressure. *Am Rev Respir Dis*. 1988;137(5):1159-1164. doi:10.1164/ajrccm/137.5.1159
- Acute Respiratory Distress Syndrome Network, Brower RG, Matthay MA, et al. Ventilation with lower tidal volumes as compared with traditional tidal volumes for acute lung injury and the acute respiratory distress syndrome. *N Engl J Med*. 2000;342(18):1301-1308. doi:10.1056/NEJM200005043421801
- Chiumello D, Carlesso E, Cadringer P, et al. Lung stress and strain during mechanical ventilation for acute respiratory distress syndrome. *Am J Respir Crit Care Med*. 2008;178(4):346-355. doi:10.1164/rccm.200710-1589OC
- Berger D, Bloechlinger S, Takala J, Sinderby C, Brander L. Heart-lung interactions during neurally adjusted ventilatory assist. *Crit Care*. 2014;18(5):499. doi:10.1186/s13054-014-0499-8
- Mauri T, Yoshida T, Bellani G, et al. Esophageal and transpulmonary pressure in the clinical setting: meaning, usefulness and perspectives. *Intensive Care Med*. 2016;42(9):1360-1373. doi:10.1007/s00134-016-4400-x
- Zhou Y, Holets SR, Li M, et al. Etiology, incidence, and outcomes of patient-ventilator asynchrony in critically-ill patients undergoing invasive mechanical ventilation. *Sci Rep*. 2021;11(1):12390. doi:10.1038/s41598-021-90013-z
- Kallet RH, Branson RD, Lipnick MS. Respiratory drive, dyspnea, and silent hypoxemia: a physiological review in the context of COVID-19. *Respir Care*. 2022;67(10):1343-1360. doi:10.4187/respcare.10075

23. Nakayama R, Iwamoto Y, Bunya N, et al. Bilateral phrenic nerve block as an effective means of controlling inspiratory efforts in a COVID-19 patient. *Respir Med Case Rep*. 2021;33:101455. doi:[10.1016/j.rmcr.2021.101455](https://doi.org/10.1016/j.rmcr.2021.101455)
24. Pereira SM, Sinedino BE, Costa ELV, et al. Phrenic nerve block and respiratory effort in pigs and critically ill patients with acute lung injury. *Anesthesiology*. 2022;136(5):763-778. doi:[10.1097/ALN.0000000000004161](https://doi.org/10.1097/ALN.0000000000004161)
25. Akoumianaki E, Lyazidi A, Rey N, et al. Mechanical ventilation-induced reverse-triggered breaths: a frequently unrecognized form of neuromechanical coupling. *Chest*. 2013;143(4):927-938. doi:[10.1378/chest.12-1817](https://doi.org/10.1378/chest.12-1817)

How to cite this article: Levis A, Gardill M, Bachmann KF, et al. Bilateral phrenic nerve block to reduce hazardous respiratory drive in a mechanically ventilated patient with COVID-19—A case report. *Clin Case Rep*. 2024;12:e8850. doi:[10.1002/ccr3.8850](https://doi.org/10.1002/ccr3.8850)