

# Reticulated livedoid skin patterns after soft-tissue filler–related vascular adverse events

Leonie W. Schelke, MD, PhD,<sup>a</sup> Peter J. Velthuis, MD, PhD,<sup>a</sup> Ali Mojallal, MD, PhD,<sup>b</sup> Guillaume Henry, MD,<sup>b</sup> Stefan O. P. Hofer, MD, PhD,<sup>c</sup> and Sebastian C. Cotofana, MD, PhD<sup>a,d,e</sup>

**Background:** For the treatment of vascular adverse events caused by filler injections, duplex ultrasound imaging may be used. The findings of duplex ultrasound examination and the clinical features of reticulated livedoid skin patterns were compared with the hemifaces anatomy.

**Objective:** The objective of this study was to link the reticulated livedoid skin patterns to the corresponding duplex ultrasound findings and the facial perforasomes.

**Methods:** Duplex ultrasound imaging was used for the diagnosis and treatment of vascular adverse events. The clinical features and duplex ultrasound findings of 125 patients were investigated. Six cadaver hemifaces were examined to compare the typical livedo skin patterns with the vasculature of the face.

**Results:** Clinically, the affected skin showed a similar reticulated pattern in each facial area corresponding with arterial anatomy and their perforators in the cadaver hemifaces. With duplex ultrasound, a disturbed microvascularization in the superficial fatty layer was visualized. After hyaluronidase injection, clinical improvement of the skin pattern was seen. Normalization of blood flow was noted accompanied by restoration of flow in the corresponding perforator artery. The skin patterns could be linked to the perforators of the superficial fat compartments.

**Conclusion:** The livedo skin patterns seen in vascular adverse events may reflect the involvement of the perforators. (J Am Acad Dermatol <https://doi.org/10.1016/j.jaad.2024.02.008>.)

**Key words:** facial anatomy; filler; injections; reticulated livedoid; vascular adverse events.

## INTRODUCTION

Recently, we described the results of a new treatment protocol for vascular adverse events after soft-tissue filler injections.<sup>1,2</sup> By using duplex ultrasound imaging to assess the primary cause and for subsequent injection of hyaluronidase, a good

clinical outcome could be achieved. In this group of patients, we became aware of distinct clinical patterns. In the current study, we therefore reviewed the original series and expanded this with newly referred cases to a total of 125. We focused on facial skin areas affected in relation to the arteries involved.

From the Department of Dermatology, Erasmus Medical Center, Rotterdam, the Netherlands<sup>a</sup>; Department of Plastic, Reconstructive, and Aesthetic Surgery, Croix-Rousse Hospital, Hospices Civils de Lyon, Claude Bernard University Lyon 1, Lyon, France<sup>b</sup>; Division of Plastic Surgery, University Health Network, University of Toronto, Toronto, Ontario, Canada<sup>c</sup>; Centre for Cutaneous Research, Blizard Institute, Queen Mary University of London, London, UK<sup>d</sup>; and Department of Plastic and Reconstructive Surgery, Guangdong Second Provincial General Hospital, Guangzhou, Guangdong Province, China.<sup>e</sup>

Funding sources: None.

IRB approval status: This study did not require ethics committee approval as ultrasound imaging is considered standard of care before and during vascular adverse events by the respective

approval board according to The Medical Research Involving Human Subjects Act 10.

Accepted for publication February 3, 2024.

Correspondence to: Leonie Schelke, MD, PhD, Department of Dermatology, Erasmus Medical Centre, Dr. Molewaterplein 40, 3015 GD Rotterdam, the Netherlands. E-mail: [lschelke@outlook.com](mailto:lschelke@outlook.com).

Published online March 6, 2024.

0190-9622

© 2024 by the American Academy of Dermatology, Inc. Published by Elsevier Inc. This is an open access article under the CC BY license (<http://creativecommons.org/licenses/by/4.0/>).

<https://doi.org/10.1016/j.jaad.2024.02.008>

## MATERIAL AND METHODS

### Study setup

This study consists of 2 groups both referred for vascular adverse events after filler injection. Patients in both groups received the same treatment. The first group (group 1) consisted of 81 patients who were assessed retrospectively using clinical imaging and treatment data. The second group (group 2) consisted of 44 patients that were studied in the same manner, but with a protocolized use of duplex ultrasound imaging. The area with the absence of microvascularization in the superficial subcutis was identified first. Next, these areas were carefully assessed for their spatial relation with perforating arteries and the main facial arteries in that area.

This vascular territory that is formed by a perforator and microvascularization is also called a perforasome or angiosome.<sup>3-5</sup> The probe position was marked on the skin and photographed to standardize follow-up examinations. After blood flow had been restored, the vascular anatomy in the respective area was reassessed. One or several days later, a final assessment was made using the identical probe position.

This study was performed in adherence with the Declaration of Helsinki (1996) and in accordance with regional laws and Good Clinical Practice for studies in human subjects.<sup>5</sup>

The study did not require ethics committee approval as ultrasound imaging is considered standard of care before and during vascular adverse events by the respective approval board according to The Medical Research Involving Human Subjects Act 10.<sup>6,7</sup> Before the inclusion into the study, all patients gave written informed consent. For the publication of photographs, additional patient consents were obtained.

### Ultrasound imaging

Ultrasound imaging was performed with the patients in an upright (90°) seated position. An 18-MHz linear transducer using duplex mode has been deployed for all examinations (Philips Affinity 70). All measurements were performed avoiding pressure to the skin as the transducer was placed in visualization gel without direct skin contact (Aquasonic, Parker Laboratories Inc).

### Injection procedure and assessment

Once disturbed flow was located, the hypoechoic areas were identified, and ultrasound-guided hyaluronidase injections (30-150 units Hyason) were performed. The injected area was then reassessed with duplex ultrasound. This process was repeated once more if no improvement in blood flow could be detected. Patients referred after a delay (3 or more days) were assessed again the day after. Also, patients with unsatisfactory clinical improvement were seen the next day. If necessary, a second session of hyaluronidase was performed. A third treatment was only necessary in 1 patient because no clinical improvement could be seen.

### CAPSULE SUMMARY

- Filler induced vascular adverse events or occlusions lead to a clinical marbling skin pattern.
- These reticulated skin patterns are similar per skin area, may reflect the perforators of the artery involved and may help to diagnose the adverse event in an early stage.

### Specimen examination of facial arteries and their superficial perforators

Six cadaver hemifaces, freshly frozen and injected with colored latex through the carotid arteries (both sides of 2 heads from the Department of Anatomy, Rockefeller Medical School, Lyon, France, and 1 from the Department of Anatomy, Erasmus MC Rotterdam, the Netherlands) were used for examination of the superficial fat compartments and facial source arteries. The perforators coursing upward were identified and compared with the skin patterns after a vascular adverse event.

### Statistical analysis

All statistical calculations were run using SPSS Statistics 25. Differences were considered significant at a probability level of  $\leq 0.05$ .

## RESULTS

### Patient demographic data

One-hundred twenty five patients were treated. The mean age of these patients was 44.0 years (SD 12.7). Ten (8.0%) were men, and 115 (92.0%) were women. A total of 92.0% (n = 115) of all patients (n = 123) were treated with hyaluronic acid-based soft-tissue fillers, whereas 7.2% (n = 9) were treated with calcium hydroxyapatite, and the remaining 0.8% (n = 1) was treated with both hyaluronic acid-based soft-tissue fillers and calcium hydroxyapatite (Table 1).

### Clinical findings

Besides the reticulated skin pattern, all patients showed hematoma or ecchymosis. This was

**Table I.** Numbers per skin location

Location	Numbers
Forehead	11
Temples	6
Lateral corner of the eye	2
Infraorbital foramen	11
Nose	18
Nasolabial fold	19
Upper lip	22
Lower lip	11
Chin	17
Tongue	1
Lateral cheek	5
Submental area	2
Total	125

frequently accompanied by tenderness, pain, and a feeling of pressure in the affected area. Some patients exhibited scabs, pustules, or other signs of skin necrosis. One case was complicated by a herpes simplex infection.

In all patients, a strikingly similar reticulated pattern was observed for each facial area (Fig 1). The reticulated livedoid skin pattern in the nasolabial area showed involvement of perioral, nasolabial, nasal, and medial periorbital regions sometimes with additional involvement of the forehead. In the mental region, clinically, an oval shape with a broad basis ending in a point reaching cranially toward the lower lip was seen with the tongue and neck being affected in some as well (Figs 2 and 3). The reticulated pattern in the lower lip presented as a triangular-shaped marbling.

The upper lip region displayed extensions over the midline cranially toward the columella that reached the nose tip in some cases. The lateral malar region representing the perforasomes of the transverse facial artery showed an oval-shaped-marbling pattern. The skin pattern of the perforasome of the dorsal nasal artery involved mainly one side of the nose stretching from the tip to the radix. In the temple, the skin pattern of the angiosome territory of the frontal branch of the superficial temporal artery presented as an oval-shaped patch mainly latero-caudal and to a smaller extent medio-cranial to the temporal crest. In the frontal region of the forehead, the territory of the supratrochlear artery showed a vertical-linear area in the midline affected starting at the upper orbital margin, extending into the hairline. More lateral, in the angiosome of the supraorbital artery, a squared area starting halfway to the forehead at the lateral side, extending into the hairline was seen. The infraorbital region, as a perforasome

of the infraorbital artery shows a skin pattern mainly in the midface with mid-lateral part of the nose. In the zygomatic region, in the perforasome of the zygomatico-orbital artery, the clinically affected area showed a rounded patch in the upper lateral malar region stretching up to the lateral lower orbital rim. In most areas, skin lesions were unilateral with minor transitions to the opposite side. However, when affected, on the forehead, the middle part was affected in all patients.

### Duplex ultrasound findings


Invariably, a hypervascular artery was located deep in the subcutis with the overlying superficial area displaying vessels with absent or diminished blood flow. The diminished flow is one or several small vessels with “weaker pulsations,” displaying more gradual and slower flow compared with the hypervascular microvascularization in close vicinity. When blood flow returned after the intervention, a perforator artery could be found branching from the source artery (being one of the main facial arteries) and piercing through the fascia into the subcutaneous layer. Also, the vessels with absent or diminished flow in the superficial fatty layer restored its blood flow and the surrounding hypervascularity in the microvascularization normalized. In the final visit, stabilized blood flow of the perforator and its subcutaneous branches was observed.

### Cadaver examination of facial arteries and their superficial perforators

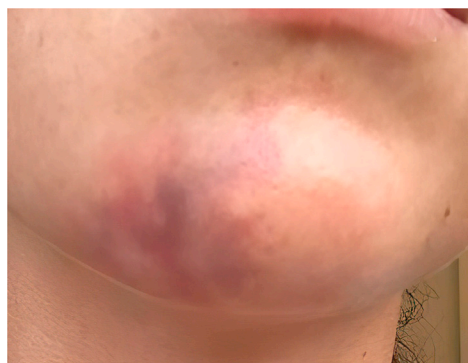The first dissection layer was deep into the subcutaneous plane to expose the main facial source artery. All major facial arteries were exposed and identified: facial, submental, angular, inferior, and superior labial; lateral nasal; dorsal nasal; transverse facial; zygomatico-orbital; superficial temporal; and supratrochlear and supraorbicular artery. Then, the dissection continued upward into the superficial fatty layer to locate the perforators piercing into this layer. The different perforators coursing from these arteries into the superficial fatty layers were compared with the livedo skin patterns given in Figs 2 and 3. Groups of perforators branching off the main arteries were found to match each specific skin area with the reticulated pattern. Fig 4 demonstrates an example of this on the chin.

### DISCUSSION

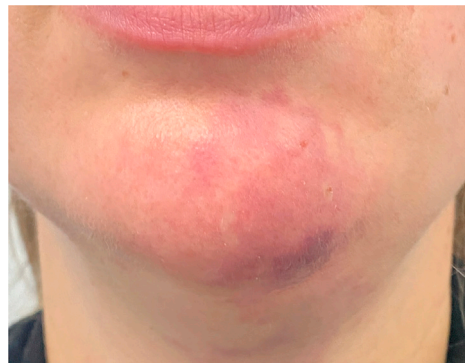Each facial area has its own arterial blood supply stemming from perforators that branch from the main facial arteries. Such an area is commonly named a perforasome, angiosome, or territory of a perforator.<sup>3-5,8,9</sup> Perforasomes are three-dimensional



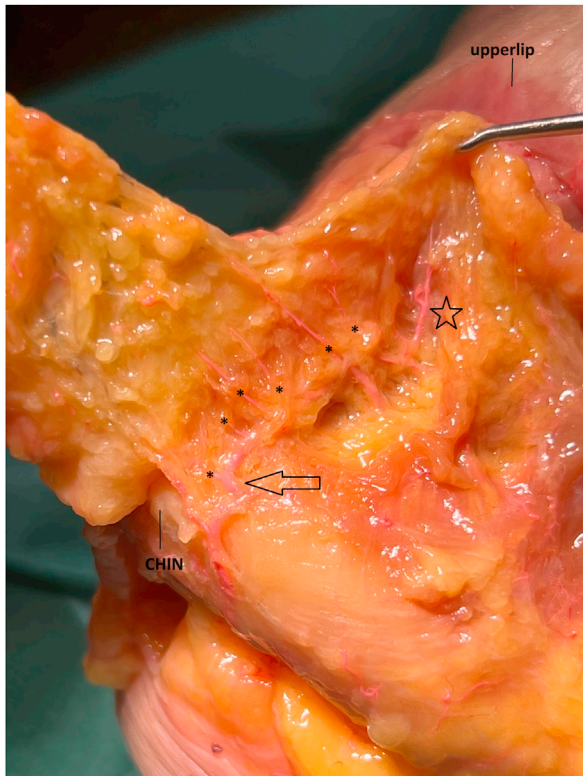
**Fig 1.** Illustration showing the skin patterns per facial region.



**Fig 2.** Patients in Fig 2 and Fig 3 have similar reticulated patterns of the chin; oval-shaped with a broad basis ending in a point reaching cranially toward the lower lip.



**Fig 3.** Patients in Fig 2 and Fig 3 have similar reticulated patterns of the chin; oval-shaped with a broad basis ending in a point reaching cranially toward the lower lip.



**Fig 4.** Perforators\* branching off the source artery (←) and terminating at a point that extends cranially toward the lower lip.

anatomical units, involving not only skin but also fat, bone, and muscle. The perforasomes of main facial arteries have been well-researched as they play an integral role in the conception of various skin flaps for reconstructive surgery.<sup>10-17</sup>

In each facial area, the clinical pictures of a vascular adverse event after filler injection display a striking similarity in pattern and extension. The affected areas bear a close resemblance to the perforasomes. There are however some deviations. Although chin (submental artery) and lower lip (inferior labial artery) only show small skin areas to be affected, matters are different with the facial artery. Vascular adverse events stemming from this artery may be located in the nasolabial fold, midface, upper lip, nose, in some cases with extension to the mid-forehead. These different extensions may reflect the anatomical variations of the angular artery described earlier.<sup>13-15</sup> The number, distribution, and course of skin perforators branching from most main facial arteries are well described in the field of flap reconstruction.<sup>8-12,15,16,18,19</sup> It is demonstrated that despite large variations in the course of arteries, reliable clusters of perforators are always present.<sup>10,11,17,18</sup> We hypothesize that the livedoid skin patterns of the patients presented in this study reflect

the hypervascularity of the capillary bed of the involved underlying perforator(s) along the course of the main arteries. This typical skin pattern may be used in the clinical diagnosis of a vascular adverse event.

## CONCLUSION

The livedo skin patterns seen in vascular adverse events reflect the involvement of the perforators.

## Conflict of interest

Drs Schelke and Velthuis are shareholders in Cutaneous BV, a company that provides educational courses and materials in the realm of facial ultrasound imaging. Drs Mojallal, Henry, Hofer, and Cotofana have no conflicts of interest to declare.

## REFERENCES

- Schelke LW, Velthuis P, Kadouch J, Swift A. Early ultrasound for diagnosis and treatment of vascular adverse events with hyaluronic acid fillers. *J Am Acad Dermatol*. 2023;88(1):79-85. <https://doi.org/10.1016/j.jaad.2019.07.032>
- Schelke LW, Velthuis PJ, Decates T, Kadouch J, Alftershofer M, Frank K, Cotofana S. Ultrasound-guided targeted vs regional flooding: a comparative study for improving the clinical outcome in soft tissue filler vascular adverse event management. *Aesthet Surg J*. 2023;43(1):86-96. <https://doi.org/10.1093/asj/sjac227>
- Saint-Cyr M, Wong C, Schaverien M, Mojallal A, Rohrich RJ. The perforasome theory: vascular anatomy and clinical implications. *Plast Reconstr Surg*. 2009;124(5):1529-1544. <https://doi.org/10.1097/PRS.0b013e3181b98a6c>
- Houseman ND, Taylor GI, Pan WR. The angiosomes of the head and neck: anatomic study and clinical applications. *Plast Reconstr Surg*. 2000;105(7):2287-2313. <https://doi.org/10.1097/00006534-200006000-00001>
- Kwon JG, Brown E, Suh HP, Pak CJ, Hong JP. Planes for perforator/skin flap elevation-definition, classification, and techniques. *J Reconstr Microsurg*. 2023;39(3):179-186. <https://doi.org/10.1055/s-0042-1750127>
- WMA Declaration of Helsinki—Ethical Principles for Medical Research Involving Human Subjects—WMA—The World Medical Association. Accessed August 5, 2018. <https://www.wma.net/polic-ies-post/wma-declaration-of-helsinki-ethical-principles-for-medical-research-involving-human-subjects/>
- Netherlands. Medical research involving human subjects act. *Bull Med Ethics*. 99;152:13-18. Accessed June 22, 2020. % <https://pubmed.ncbi.nlm.nih.gov/11658081/>
- Braverman IM. The cutaneous microcirculation. *J Invest Dermatol Symp Proc*. 2000;5(1):3-9. <https://doi.org/10.1046/j.1087-0024.2000.00010.x>
- Ashton MW, Taylor GI, Corlett RJ. The role of anastomotic vessels in controlling tissue viability and defining tissue necrosis with special reference to complications following injection of hyaluronic acid fillers. *Plast Reconstr Surg*. 2018;141(6):818e-830e. <https://doi.org/10.1097/PRS.0000000000004287>
- Hofer SOP, Posch NA, Smit X. The facial artery perforator flap for reconstruction of perioral defects. *Plast Reconstr Surg*. 2005;115(4):995-1003. <https://doi.org/10.1097/01.prs.0000154208.67390.5c>
- Qassemayr Q, Havet E, Sinna R. Vascular basis of the facial artery perforator flap: analysis of 101 perforator territories.

- Plast Reconstr Surg.* 2012;129(2):421-429. <https://doi.org/10.1097/PRS.0b013e31822b6771>
12. Ng ZY, Fogg QA, Shoaib T. Where to find facial artery perforators: a reference point. *J Plast Reconstr Aesthet Surg.* 2010;63(12):2046-2051. <https://doi.org/10.1016/j.bjps.2010.01.002>
  13. Wang R, Cen Y. Vascular basis of the facial artery perforator flap: analysis of 101 perforator territories. *Plast Reconstr Surg.* 2012;130(5):743e. <https://doi.org/10.1097/PRS.0b013e318267d6ee>
  14. Pils U, Anderhuber F, Neugebauer S. The facial artery-the main blood vessel for the anterior face? *Dermatol Surg.* 2016;42:203-208.
  15. Lohn JW, Penn JW, Norton J, Butler PEM. The course and variation of the facial artery and vein: implications for facial transplantation and facial surgery. *Ann Plast Surg.* 2011;67(2):184-188. <https://doi.org/10.1097/SAP.0b013e31822484ae>
  16. Furukawa M, Mathes DW, Anzai Y. Evaluation of the facial artery on computed tomographic angiography using 64-slice multi-detector computed tomography: implications for facial reconstruction in plastic surgery. *Plast Reconstr Surg.* 2013;131(3):526-535. <https://doi.org/10.1097/PRS.0b013e31827c6f18>
  17. Ercan A, Ercan LD, Demiroz A. Nasolabial perforator flap: a multi-tool for reconstruction of facial units. *J Craniofac Surg.* 2020;31(4):1042-1045. <https://doi.org/10.1097/SCS.00000000000006285>
  18. Pierrefeu A, Brosset S, Lahon M, et al. Transverse facial artery perforators: anatomical, two- and three-dimensional radiographic study. *Plast Reconstr Surg.* 2019;143(4):820e-828e. <https://doi.org/10.1097/PRS.00000000000005421>
  19. Lewis K, Islam S, Phillips S, Carney MJ 3rd, Clune J. The facial artery perforator flap. *J Craniofac Surg.* 2023;34(5):e434-e437. <https://doi.org/10.1097/SCS.00000000000009249>