



Top Stories: Pediatric Electrophysiology

Top stories on catheter ablation of atrial fibrillation in patients with congenital heart defects

Natasja M.S. de Groot, MD, PhD,^{1,2} Can Zhang, MD¹

(Heart Rhythm 2024;21:971–972) © 2024 Heart Rhythm Society. This is an open access article under the CC BY license (<http://creativecommons.org/licenses/by/4.0/>).

Atrial fibrillation (AF) is the next major challenge in management of patients with congenital heart disease (CHD). This tachyarrhythmia arises at a relatively young age and rapidly progresses from paroxysmal to long-standing persistent AF in <5 years, which justifies aggressive therapy.

Pulmonary vein isolation: emerging treatment of AF in CHD patients

There has been an increase in reports of pulmonary vein isolation (PVI) performed in CHD patients with AF. Successful outcomes of this therapy suggest pulmonary vein ectopy as the underlying mechanism. Frequent atrial ectopy in this group of patients is related to aging, female sex, univentricular hearts, lower body mass index, valvular dysfunction, and left atrial dilation. Ectopy in CHD patients arises from both right and left atrial sites, but targeting non-pulmonary vein trigger sites was not related to freedom of AF.¹

PVI has mainly been performed in patients with atrial septal defects or bicuspid aortic valves. In patients with complex CHD, there are fewer data on favorable outcomes of PVI. Interestingly, AF originating from circumscriptive areas in the right atrium has been described in patients with Fontan circulation and transposition of the great arteries, and isolation of these areas resulted in termination of AF.

AF recurrences

Recurrence rates after PVI are variable and are related to patient, procedural, and follow-up variables, including, for example, complexity of CHD, number of surgical procedures, ablation techniques, and frequency and type of postprocedural rhythm monitoring. Multiple procedures are often required to obtain freedom from AF.^{1–4} High recurrence rates in CHD patients can be the result of incomplete

ablation of lesions due to complex anatomies. AF may also be a more substrate mediated arrhythmia in these patients as 32% to 53% of the study populations had persistent AF.^{1–3} However, the type of AF, paroxysmal or persistent, was not associated with AF recurrences after PVI.

Coexistence of different types of atrial tachyarrhythmias

After corrective or palliative cardiac surgery (cavotricuspid isthmus dependent), macroreentrant tachycardia (MRT) is frequently observed.^{1–4} Importantly, MRT in CHD patients often coexists with AF, and either AF or MRT is the initial presenting arrhythmia. Noninducibility of MRT after PVI is associated with AF-free survival.^{1–3} The relationship between MRT and AF in CHD patients is only partly understood. Comparable to patients without CHD, AF may develop after ablation of cavotricuspid isthmus-dependent atrial flutter. In contrast, frequent episodes of MRT may aggravate preexisting remodeling by pressure or volume overload, which in turn facilitates development of AF.⁵ Also, MRT may arise after PVI.

Additional ablation approaches

Although additional ablation approaches, such as targeting complex fractionated electrograms or rotational activity, have been performed in CHD patients, they had no positive impact on AF ablation outcome with the exception of creation of a lateral mitral annular line.²

If AF is a substrate-mediated arrhythmia in CHD patients, at present there are no conclusive data on whether the substrate is located at the right or left atrium. Intraoperative mapping studies in patients with atrial septal defects demonstrated extensive areas of conduction disorders in the right atrium and Bachmann bundle and to a lesser degree in the left atrium (Figure 1).

From the ¹Department of Cardiology, Erasmus University Medical Center, Rotterdam, The Netherlands, and ²Department of Microelectronics, Signal Processing Systems, Faculty of Electrical Engineering, Mathematics and Computer Sciences, Delft University of Technology, Delft, The Netherlands.

spatial distribution of conduction disorders

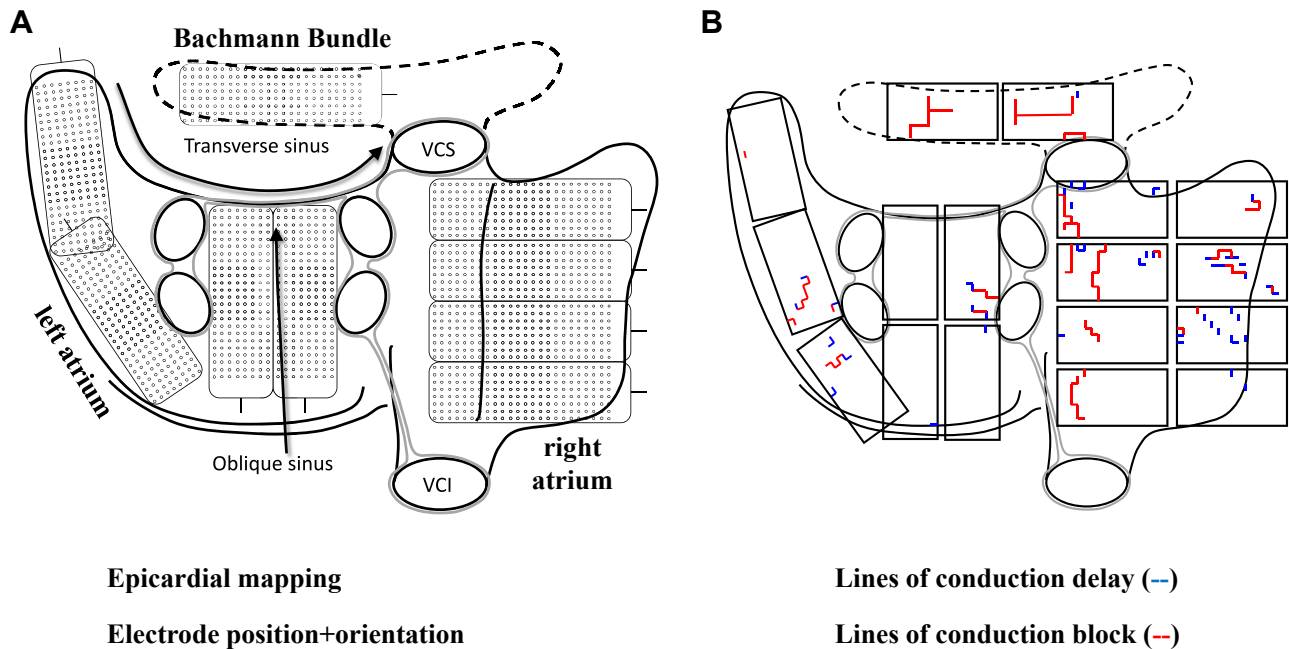


Figure 1

A: Schematic presentation of the positions and orientations of a 192-electrode array on the atria for intraoperative mapping. VCI = vena cava inferior; VCS = vena cava superior. B: Spatial distribution of conduction disorders during sinus rhythm in a patient with an atrial septal defect. Conduction disorders are scattered throughout the atria but mainly present on the right atrium and Bachmann bundle.

AF ablation in CHD patients: What's next?

Variations in underlying CHD, associated surgeries, and residual lesions and consequently differences in AF pathophysiologic processes call for more insights into AF mechanisms and patient-tailored ablation approaches. Reported ablation outcomes may overestimate ablation success in more complex CHD as only small numbers of complex CHD patients were included. Continuous rhythm monitoring before and after PVI will provide further insights into relationships between AF and MRT that can be used to refine AF ablation strategies with additional targeting of MRT to improve arrhythmia-free survival.

Funding Sources: The authors have no funding sources to disclose.

Disclosures: The authors have no conflicts of interest to disclose.

Address reprint requests and correspondence: Prof dr N.M.S de Groot, Unit Translational Electrophysiology, Department of Cardiology, Erasmus Medical Center, Dr Molewaterplein 40, 3015 GD Rotterdam, The Netherlands. E-mail address: n.m.s.degroot@erasmusmc.nl

References

1. Griffiths JR, Nussinovitch U, Liang JJ, et al. Catheter ablation for atrial fibrillation in adult congenital heart disease: an international multicenter registry study. *Circ Arrhythm Electrophysiol* 2022;15:e010954.
2. Hu TY, Janga C, Amin M, et al. Catheter ablation of atrial fibrillation in adult congenital heart disease: procedural characteristics and outcomes. *Circ Arrhythm Electrophysiol* 2023;16:437–446.
3. Krause U, Muller MJ, Schneider HE, Paul T. Catheter ablation of atrial fibrillation using 2nd-generation cryoballoon in congenital heart disease patients—significance of RF ablation of additional atrial macro-reentrant tachycardia. *J Interv Card Electrophysiol* 2022;65:411–417.
4. Waldmann V, Bessiere F, Gardey K, et al. Catheter ablation of atrial tachyarrhythmias in patients with atrioventricular septal defect. *Europace* 2023;25:eua275.
5. Martin de Miguel I, Madhavan M, Miranda WR, Connolly HM, Egbe AC. Prognostic implications of atrial fibrillation in adults with Ebstein anomaly. *Heart* 2023; 109:442–448.