

ZAIATS, Liubomyr, PASICHNYK, Olga and ZUKOW, Walery. Submicroscopic changes of type II alveolocyttes in the late development of experimental acute pancreatitis. *Journal of Education, Health and Sport*. 2024;64:84-93. eISSN 2391-8306. <https://dx.doi.org/10.12775/JEHS.2024.64.005>  
<https://apcz.umk.pl/JEHS/article/view/49559>  
<https://zenodo.org/records/10847208>

The journal has had 40 points in Minister of Science and Higher Education of Poland parametric evaluation. Annex to the announcement of the Minister of Education and Science of 05.01.2024 No. 32318. Has a Journal's Unique Identifier: 201159. Scientific disciplines assigned: Physical culture sciences (Field of medical and health sciences); Health Sciences (Field of medical and health sciences).  
Punkty Ministerialne 40 punktów. Załącznik do komunikatu Ministra Nauki i Szkolnictwa Wyższego z dnia 05.01.2024 Lp. 32318. Posiada Unikatowy Identyfikator Czasopisma: 201159. Przypisane dyscypliny naukowe: Nauki o kulturze fizycznej (Dziedzina nauk medycznych i nauk o zdrowiu); Nauki o zdrowiu (Dziedzina nauk medycznych i nauk o zdrowiu). © The Authors 2024;  
This article is published with open access at Licensee Open Journal Systems of Nicolaus Copernicus University in Torun, Poland  
Open Access. This article is distributed under the terms of the Creative Commons Attribution Noncommercial License which permits any noncommercial use, distribution, and reproduction in any medium, provided the original author (s) and source are credited. This is an open access article licensed under the terms of the Creative Commons Attribution Non commercial license Share alike.  
(<http://creativecommons.org/licenses/by-nc-sa/4.0/>) which permits unrestricted, non commercial use, distribution and reproduction in any medium, provided the work is properly cited.  
The authors declare that there is no conflict of interests regarding the publication of this paper.  
Received: 10.01.2024. Revised: 10.02.2024. Accepted: 15.03.2024. Published: 21.03.2024.

**UDC 616-092+616.24+616-018.2+616.37-002+616-08+616-092.9**

## **SUBMICROSCOPIC CHANGES OF TYPE II ALVEOLOCYTES IN THE LATE DEVELOPMENT OF EXPERIMENTAL ACUTE PANCREATITIS**

**Liubomyr Zaiats<sup>1</sup>, Olga Pasichnyk<sup>1</sup>, Walery Zukow<sup>2</sup>**

**<https://orcid.org/0000-0003-3265-1273>**

**<https://orcid.org/0009-0005-0272-2378>**

**<https://orcid.org/0000-0002-7675-6117>**

**<sup>1</sup> Ivano-Frankivsk National Medical University, Ivano-Frankivsk,  
Ukraine [patfisiology@ifnmu.edu.ua](mailto:patfisiology@ifnmu.edu.ua)**

**<sup>2</sup> Nicolaus Copernicus University, Torun, Poland [w.zukow@wp.pl](mailto:w.zukow@wp.pl)**

## **Abstract**

**Background.** Today, acute pancreatitis is one of the most common and severe visceral disorders in patients worldwide. **The aim of the work** was to study the dynamics of ultrastructural changes of type II alveolocytes in the long-term periods of development of experimental acute pancreatitis. **Material and methods.** The experiments were carried out on 54 white Wistar male rats weighing 180–220 g. The animals were divided into three groups: first — intact, second — control, third — experimental with a model of acute pancreatitis, which was reproduced by intraperitoneal administration of a 20% solution of L-arginine at a total dose of 5 g/kg at one-hour interval. The control group of animals was intraperitoneally injected with an equivalent dose of isotonic sodium chloride solution. All research were performed under sodium thiopental anesthesia at the rate of 60 mg/kg body weight. Lung tissue for electron microscopic examination was collected from the lower lobe of the left lung at 3–5 and 7 days. Pieces of lung tissue measuring 1×1×1 mm were fixed in a 2.5% glutaraldehyde solution, followed by additional fixation in a 1% osmium tetroxide solution. After dehydration, the material was poured

into Epon-Araldite. Sections with a thickness of 20–50 nm obtained on “Tesla BS-490” ultramicrotome were studied in a PEM-125K electron microscope. **Results.** It was found that three days after the start of the study, along with dystrophic-destructive changes, type II alveolocytes in a state of increased functional activity were observed. Continuation of the experiment (5 days) leads to the progression of ultrastructural changes in type II alveolocytes are determined, which are most pronounced on the 7 day of the study. **Conclusion.** Acute experimental pancreatitis is accompanied by marked changes in the ultrastructural structure of type II alveolocytes. The nature and severity of structural changes of type II alveolocytes depends on the duration of the course of arginine-induced acute pancreatitis.

**Key words:** arginine-induced acute pancreatitis, lungs, type II alveolocytes.

## **INTRODUCTION**

Nowadays, acute pancreatitis (AP) is one of the most common and severe visceral disorders in patients worldwide [2, 4, 5, 10]. The incidence of AP continues to increase, causing single or multiple organ failure [7, 8, 9]. Pulmonary complications occupy a special place

among the consequences of AP [1, 6, 13, 14]. It has been established that in the pathogenesis of lung pathology, the morphofunctional state of type II alveolocytes plays an important role.

**The aim of the work** was to study the dynamics of ultrastructural changes of type II alveolocytes in the long-term periods of development of experimental acute pancreatitis.

## **MATERIAL AND METHODS**

The experiments were carried out on 54 white Wistar male rats weighing 180–220 g. The animals were divided into three groups: first — intact, second — control, third — experimental with a model of acute pancreatitis, which was reproduced by intraperitoneal administration of a 20% solution of L-arginine at a total dose of 5 g/kg at one-hour interval. The control group of animals was intraperitoneally injected with an equivalent dose of isotonic sodium chloride solution. All research were performed under sodium thiopental anesthesia at the rate of 60 mg/kg body weight. Lung tissue for electron microscopic examination was collected from the lower lobe of the left lung at 3–5 and 7 days. Pieces of lung tissue measuring 1×1×1 mm were fixed in a 2.5% glutaraldehyde solution, followed by additional fixation in a 1% osmium tetroxide solution. After dehydration, the material was poured into Epon-Araldite. Sections with a thickness of 20–50 nm obtained on “Tesla BS-490” ultramicrotome were studied in a PEM-125K electron microscope.

## RESULTS AND DISCUSSION

The conducted ultrastructural analysis shows that in three days after the start of the study, nuclei of many A-II are enlarged in volume with nucleoplasm of low electron-optical density (Fig. 1).

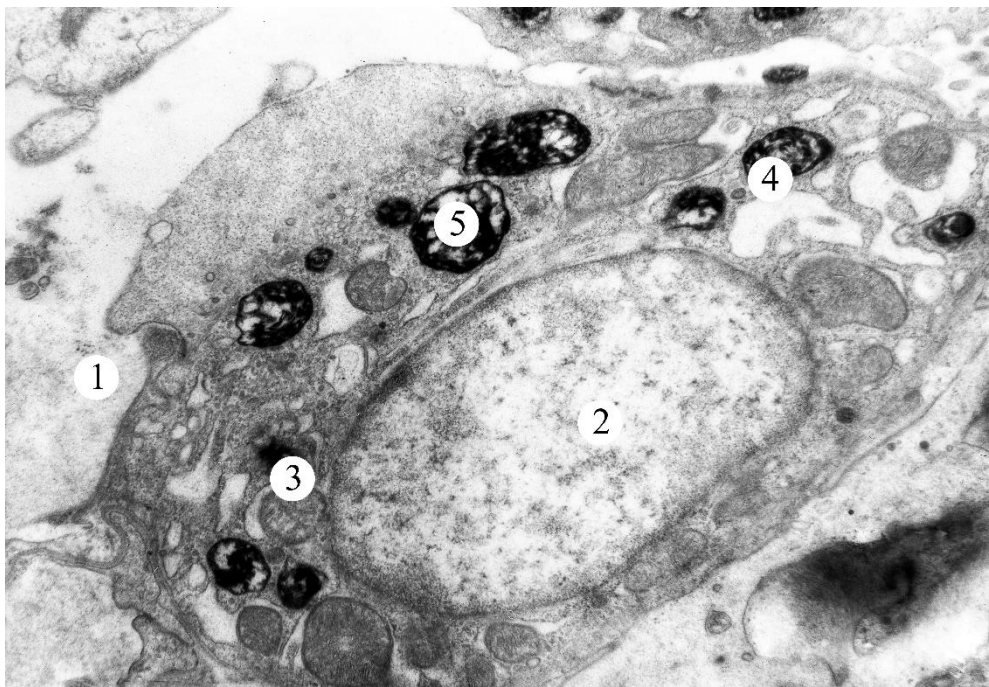


Figure. 1. Ultrastructural changes of the type II alveolocyte three days after the start of the experiment. Electron microphotograph x6400.

Key: 1 — alveolar lumen; 2 — nucleus; 3 — mitochondrion; 4 — granular endoplasmic reticulum; 5 — lamellar body.

The perinuclear space is expanded. Mitochondria are enlarged in volume with a lightened matrix and disoriented cristas. The components of the Golgi complex (GC) consist of dilated cisterns and small bubbles. The rough endoplasmic reticulum (GER) channels have been significantly expanded. The number of ribosomes on the outer surface of membranes is reduced. Separate lamellar bodies (LB) are observed in the cytoplasm of A-II, which are characterized by the presence of uneven light spaces between bimembrane osmiophilic plates. A significantly reduced number of microvilli is determined on the apical surface of A-II. Along with this, part A-II is determined in the lungs in a state of increased functional activity.

In 5 days after the start of the experiment, nuclei of A-II with an illuminated matrix. The perinuclear space is expanded. Mitochondria with a matrix of low electron-optical density and shortened crista. Mitochondria with complete lysis of crista are also found. The constituent components of GC and GER are expanded and deformed. The fragmentation of GER membranes is also determined. A large part of LB is partially filled with phospholipid material with disoriented and fragmented membranes. Vacuoles with remnants of membranes are sometimes observed at the site of LB. The apical surface of A-II is smoothed. BM is swollen throughout. With an increase in the duration of the study (7 days), the nuclei of many A-II are enlarged in volume with a matrix of low electron-optical density. Chromatin granules are localized along the inner surface of the nuclear membrane or grouped into individual granules. Mitochondria with a lightened matrix and

shortened crista. The cisterns and tubules of the GC and GER are vacuolated and fragmented. Most LBs are at various stages of vacuolization. BMs are thickened, deformed. In many places, the destruction of plasmalemma A-II is observed, which leads to the release of intracellular structures into the lumen of the alveoli.

The conducted studies showed that acute arginine-induced pancreatitis is accompanied by pronounced disorders of ultrastructural organization of A-II. Our data are consistent with the results of research by other scientists who studied the submicroscopic structure of the components of the respiratory part of the lungs in other pathological conditions [3, 11, 12].

## **CONCLUSION**

Acute experimental pancreatitis is accompanied by marked changes in the ultrastructural structure of type II alveolocytes. The nature and severity of structural changes of type II alveolocytes depends on the duration of the course of arginine-induced acute pancreatitis.

## **REFERENCES**

1. Adam F, Bor C, Uyar M, Demirag K, Cankayali I. Severe acute pancreatitis admitted to intensive care unit: SOFA is superior to Ranson's criteria and APACHE II in determining prognosis. Turk J Gastroenterol. 2013;24:430-5.

2. Han X, Wang Y, Chen H, Zhang J, Xu C, Li J, et al. Enhancement of ICAM-1 via the JAK2/STAT3 signaling pathway in a rat model of severe acute pancreatitis-associated lung injury. *Experimental and therapeutic medicine*. 2016; 11: 788-796. doi: 10.3892/etm.2016.2988.
3. Klishch IP, Zaiats LM. Electron microscopic changes of type II pneumocyte in the experimental acute renal failure [in Ukrainian]. *Reports of morphology*. 2017;1(23):37-39.
4. Lankisch PG, Apte M, Banks PA. Acute pancreatitis. *Lancet*. 2015;386:85-96. doi:10.1016/S0140-6736(14)6U649-8.
5. Leppaniemi A, Tolonen M, Tarasconi A, Segovia-Lohse H, Gamberini E, Kirkpatrick AW, et al. 2019 WSES guidelines for the management of severe acute pancreatitis. *World Journal of Emergency Surgery*. 2019; 14:27 <https://doi.org/10.1186/s13017-019-0247-0>.
6. Qiu Z, Xu F, Wang Z, Yang P, Bu Z, Cheng F, et al. Blockade of JAK2 signaling produces immunomodulatory effect to preserve pancreatic homeostasis in severe acute pancreatitis. *Biochemistry and Biophysics Reports*. 2021; 28: 101133. <https://doi.org/10.1016/j.bbrep.2021.101133>.
7. Tan J-H, Cao R-C, Zhou L, Zhou Z-T, Chen H-J, Xu J, et al. ATF6 aggravates acinar cell apoptosis and injury by regulating p53/AIFM2 transcription in Severe Acute Pancreatitis. *Theranostics* 2020. 10(18):8298-8314.
8. Trikudanathan G, Wolbrink DRJ, van Santvoort H, Mallery S, Freeman M, Besselink MG. Current Concepts in Severe Acute and



Necrotizing Pancreatitis; An Evidence-Based Approach. *Gastroenterology*. 2019;156(7): 1994-2007. <https://doi.org/10.1053/j.gastro.2019.01.269>.

9. Wolbrink DRJ, Kolwijck E, Oever JT, Horvath KD, Bouwense SAW, Schouten JA. Management of infected pancreatic necrosis in the intensive care unit: a narrative review. *Clinical Microbiology and Infection*. 2020; 26:18-25. <https://doi.org/10.1016/j.cmi.2019.06.017>.

10. Yin T, Peeters R, Liu Y, Feng Y, Zhang X, Jiang Y, et al. Visualization, Quantification and Characterization of Caerulein-Induced Acute Pancreatitis in Rats by 3.0T Clinical MRI, Biochemistry and Histomorphology. *Theranostics*. 2017; 7(2):285-294.

11. Zaiats LM, Fedorchenko YuV. Features of lipoperoxidation and morphological changes of the lungs in experimental diabetes mellitus [in Ukrainian]. *World of Medicine and Biology*. 2022;3(81):214-18. DOI: 10.26724/2079-8334-2022-3-81-214-218.

12. Zaiats LM, Kuz UV. Electron microscopic changes in alveolar lung epithelium in multiple skeletal trauma [in Ukrainian]. *Reports of morphology*. 2017;2(23):195-198.

13. Zarem E. Treatment of severe acute pancreatitis and its complications. *World J. Gastroenterol*. 2014;20(38):13879-13892. <https://doi.org/10.3748/wjg.v20>.

14. Zhang Y, Yan L, Han W. Elevated Level of miR-551b-5p is Associated With Inflammation and Disease Progression in Patients

With Severe Acute Pancreatitis. Therapeutic Apheresis and Dialysis.  
2018; 22(6):649-655. doi: 10.1111/1744-9987.12720.