

ResearchOnline@ND

University of Notre Dame Australia  
ResearchOnline@ND

Medical Papers and Journal Articles

School of Medicine

2015

## The thalamus as a putative biomarker in neurodegenerative disorders

Brian D. Power

University of Notre Dame Australia, [Brian.Power@nd.edu.au](mailto:Brian.Power@nd.edu.au)

Jeffrey C.L Looi

Follow this and additional works at: [http://researchonline.nd.edu.au/med\\_article](http://researchonline.nd.edu.au/med_article)



Part of the [Medicine and Health Sciences Commons](#)

This article was originally published as:

Power, B. D., & Looi, J. C. (2015). The thalamus as a putative biomarker in neurodegenerative disorders. *Australian and New Zealand Journal of Psychiatry*, 49 (6), 502-518.

Original article available here:

<http://anp.sagepub.com/content/49/6/502>

This article is posted on ResearchOnline@ND at  
[http://researchonline.nd.edu.au/med\\_article/712](http://researchonline.nd.edu.au/med_article/712). For more information,  
please contact [researchonline@nd.edu.au](mailto:researchonline@nd.edu.au).



This is the authors' post-print copy of the article published as:-

Power, Brian D., and Looi, Jeffrey C.L. (2015) The thalamus as a putative biomarker in neurodegenerative disorders. *Australian & New Zealand Journal of Psychiatry*, 49(6): 502-518. doi: 10.1177/0004867415585857.

## **TITLE PAGE**

**TITLE: The thalamus as a putative biomarker in neurodegenerative disorders.**

**Running title:** Neuroimaging the thalamus in neurodegenerative disorders.

## **AUTHORS:**

B.D. Power<sup>\*a,b</sup>, and J.C.L. Looi<sup>c</sup>

- a. School of Medicine Fremantle, The University of Notre Dame Australia, Fremantle, Australia
- b. Clinical Research Centre, North Metropolitan Health Service - Mental Health, Perth, Australia
- c. Research Centre for the Neurosciences of Ageing, Academic Unit of Psychiatry and Addiction Medicine, Australian National University Medical School, Canberra Hospital, Canberra, Australia

## **\*CORRESPONDING AUTHOR:**

Professor Brian D Power.

School of Medicine Fremantle, The University of Notre Dame Australia, PO Box 1225, Fremantle, WA 6959, Australia.

Email: [briandiarmidpower@gmail.com](mailto:briandiarmidpower@gmail.com).

Telephone: (+61) 08 94330228.

Fax: (+61) 08 94330250.

## **ABSTRACT**

**Objective:** This review provides a brief account of the clinically relevant functional neuroanatomy of the thalamus, before considering the utility of various modalities utilised to image the thalamus and technical challenges therein, and going on to provide an overview of studies utilising structural imaging techniques to map thalamic morphology in the spectrum of neurodegenerative disorders.

**Methods:** A systematic search was conducted for peer-reviewed studies involving structural neuroimaging modalities investigating the morphology (shape and/ or size) of the thalamus in the spectrum of neurodegenerative disorders.

**Results:** Whilst the precise role of the thalamus in the healthy brain remains unclear, there is a large body of knowledge accumulating which defines more precisely its functional connectivity within the connectome, and a burgeoning literature implicating its involvement in neurodegenerative disorders. It is proposed that correlation of clinical features with thalamic morphology (as a component of a quantifiable subcortical connectome) will provide a better understanding of neuropsychiatric dysfunction in various neurodegenerative disorders, potentially yielding clinically useful endophenotypes and disease biomarkers.

**Conclusions:** Thalamic biomarkers in the neurodegenerative disorders have great potential to provide clinically meaningful knowledge regarding not only disease onset and progression,

but may yield targets of and perhaps a way of gauging response to future disease-modifying modalities.

**Key words**

Biomarker; dementia; neurodegenerative disorder; neuroimaging; thalamus.

***“Essentially, the cortex must view the world through the thalamus: that is the only view the cortex has.” Sherman and Guillery, 2006.***

## **INTRODUCTION**

### **Framing the thalamus in the context of endophenotypes.**

There has been a marked shift in the approach to characterizing and understanding neuropsychiatric disease with a focus upon endophenotypes that has driven change in research paradigms (Gottesman and Gould, 2003). The concept of intermediate phenotypes (or endophenotypes) has been described as, “measurable components unseen by the unaided eye along the pathway between disease and distal phenotype” (Gottesman and Gould, 2003). Accordingly, correlation between genetic factors and measurements of the neural circuit substrates of cognition, emotion, motor function and behavior may constitute steps towards establishing a genotype to morphotype relationship. The morphotype thus derived may then determine the phenotype (see Looi and Walterfang, 2012).

In this paper, we apply the framework of the endophenotypes and its antecedents in the endomorphotypes (morphology) and ultimately (though not currently) the endogenotype to understand the involvement of a crucial network hub in the human brain, the thalamus, in neurodegenerative disease. We argue that: the thalamus serves as a crucial hub in the extensive topographically distinct neuronal networks relevant to human brain disease and its manifestations; the morphology (shape and volume) of the thalamus can be quantified in vivo; quantified morphology (morphometry) may be correlated to endophenotypic features of the disease such as impairments in cognition, emotion, motor function and behavior; and

therefore, morphometry of the thalamus may be used to measure disease progression as a potential biomarker.

## **BASIC AND CLINICAL NEUROANATOMY OF THE THALAMUS**

### **Historical aspects**

The term thalamus is from the Greek word *thalamos* (θάλαμος), referring to an inner-most room but also used to describe storeroom and a sleeping or bridal chamber; the word was used commonly in ancient Greek texts, such as Homer's *Odyssey*. The first documented neuroanatomical usage of the word was by Galen in the second century AD when using as an analogy the floor plan of a Greek house, but it is quite likely he was referring to a part of the ventricular system (possibly as a 'storeroom' of *pneuma*), rather than what is referred to as the thalamus today; Thomas Willis, in the mid to late 1600s, was the first to refer to the large mass of grey matter in the dorsal part of the diencephalon as *the thalamus* (see Jones, 2007).

### **Embryology and gross anatomy of the thalamus**

During development the primitive forebrain gives rise to the *telencephalon* (or end-brain), which has as its derivatives the cerebral cortex, striatum, amygdala, and associated structures, and the *diencephalon* (or between-brain), which gives rise primarily to the thalamus and hypothalamus. It is likely that connections between the thalamus and cortex occur after subcortical afferents have innervated the thalamus, with corticothalamic connections preceding thalamocortical connections. Hence, maturation of the thalamus and cortex are related intimately, such that an abnormality in the early neurodevelopmental period of thalamic organization could impair normal cortical development, and vice versa;

consistent with a neurodevelopmental model, it has been proposed that pathology of the thalamus may play an important role in the neurobiology of schizophrenia (see Byne et al., 2009).

Whilst the diencephalon can be generally divided into the thalamus and hypothalamus, it includes a number of other structures (such as the habenular nuclei of the epithalamus). The thalamus itself can be divided into the dorsal and ventral divisions, based on their relative position in the lateral diencephalic wall during development, and also on the basis of their connectivity (Jones, 2007). The dorsal thalamus is composed of nuclei having reciprocal connections with the cerebral cortex and striatum, whilst the ventral thalamus (despite having direct input from the cortex and, in part from the basal ganglia) does not project to the cortex. The ventral thalamic nuclei include the reticular thalamic nucleus (RTN), zona incerta (ZI) and ventral lateral geniculate nucleus, and a shared feature of these nuclei appears to be projections to and a close anatomical and functional relationship with the dorsal thalamus (Mitrofanis and Guillery, 1993; Power et al., 1999; Kolmac et al., 2000; Mitrofanis, 2005). From a neuroanatomical and neuroimaging perspective, the RTN and ZI assist with the lateral and inferior boundary definition, respectively, throughout much of the rostral-caudal extent of the dorsal thalamus (Power et al., 2015). This review will focus primarily on the dorsal thalamus unless otherwise stated.

Occupying approximately the volume of a Brazil nut (*Bertholletia excelsa*) in the human, the two dorsal thalami are located strategically at the very 'inner-most' region of the brain, between other subcortical structures and cortex (see Figure 1). Gross anatomical landmarks



defining the boundaries of the thalamus are as follows: the third ventricle serves as the medial boundary, and the internal capsule separates the thalamus from the basal ganglia laterally; superiorly the thalamus is bound by the lateral ventricle, and inferiorly a number of distinctive structures abut the thalamus (including the ZI, substantia nigra, subthalamic nucleus, red nucleus). The dorsal thalamus has anterior, medial and lateral subdivisions, defined by a curved sheet of myelinated fibres called the internal medullary lamina (Figure 2). These subdivisions are composed of distinct thalamic nuclei, defined on the basis of their cytoarchitecture, patterns of connectivity and functionality (see Table 1, Figures 1, 2), however these nuclei share many features in common as outlined below. The anterior subdivision is defined by the anterior nucleus (AN) and the medial subdivision by mediodorsal nucleus (MD). The lateral subdivision has a dorsal and ventral tier of nuclei: the dorsal tier contains the lateral dorsal nucleus (LD) and the pulvinar; the ventral tier contains the ventral anterior (VA), ventral lateral (VL) and ventral posterior (VP) nuclei. Sometimes considered as a caudal extension of the ventral tier are the lateral geniculate (LGN) and medial geniculate (MGN) nuclei (which are found inferior to the pulvinar). The internal medullary lamina itself also encloses the intralaminar nuclei (IL); the midline nuclei (ML) cover portions of the medial surface of the dorsal thalamus.

### **Genetic factors involved in neurodevelopment**

The neurodevelopment of the thalamus has been summarized extensively (see Jones, 2007; and Blackshaw et al., 2010), and the following is a brief synopsis to establish that there are significant genetic factors involved in development. A relatively small number of gene sets are thought to be expressed in the developing diencephalon, with 3 major compartments

identified (p1, p2, and p3) (Puelles and Rubenstein, 2003), and a mid-diencephalic organiser (Scholpp et al., 2009) releasing several signalling factors crucial to thalamic organisation, including Sonic hedgehog (SHH) and fibroblast growth factor (FGF) (Bulfone et al., 1993).

A recent study reported that genetic variation within the Human Leukocyte Antigen locus (previously associated with schizophrenia) influences the volume of the left thalamus (Brucato et al., 2015). Further studies will need to ascertain the genetic factors associated with thalamic volume. A correlation between genetic factors and thalamic volume may constitute a step towards establishing a genotype to morphotype relationship. The morphotype thus derived may then determine the phenotype (see Looi and Walterfang, 2012).

### **Physiology**

There are two types of neurons in dorsal thalamic nuclei which can be distinguished by their unique morphology and chemoarchitecture: locally acting interneurons immunoreactive for  $\gamma$ -aminobutyric acid (GABA), and glutamatergic relay cells projecting outside of the thalamus (which have a variety of voltage dependent membrane properties). The physiological properties of thalamic relay cells suggests that they have two main types of response modes - either tonic or burst - which will determine the nature of the message relayed to the cortex, and these response modes are thought to underpin changes in behavioral states. A burst response mode is utilized for signal detection, or salience (for instance, in response to novel stimuli or sudden changes in the environment), whereas a tonic response mode is believed to be utilized by the thalamic relay cells for more accurate signal analysis (Crick, 1984; Sherman and Guillery, 2006). The response mode of thalamic relay cells (i.e., shifting from signal

analysis to signal detection, and vice versa) is thought to be modulated by brainstem and cortical inputs to the thalamus; it has been suggested that disturbance of this process may underpin the aberrant salience seen in neuropsychiatric disease (for instance see Byne et al., 2009).

### **Drivers and modulators**

The nuclei of the dorsal thalamus are innervated by two types of afferent fibres, classified as either drivers or modulators; this classification is regardless of whether the fibres originate from cortical or subcortical structures (see Figure 3). Afferent fibres can be defined on the basis of their synaptic morphology (e.g., drivers have large terminals on proximal dendrites forming multiple contacts, whereas modulators have small terminals on distal dendrites forming single contact) and post synaptic actions (e.g., drivers activate ionotropic receptors and cause large excitatory postsynaptic potentials (EPSP), whereas modulators also activate metabotropic receptors, and cause small EPSP). The key feature of the modulator axon is that its terminals are less well-grouped than those of the driving axon terminals; further, modulator afferents send a branch to innervate the RTN, whereas driver afferents do not (Bourassa *et al.*, 1995; Darien-Smith *et al.*, 1999). A key feature of driver afferents is that they determine the thalamic relay cell receptive field, whereas modulators do not. Drivers can therefore be conceptualized as those afferents to the thalamus that carry the message to be passed on by the thalamic relay cell, whilst the modulators can be conceptualized as those afferents to the thalamus that influence how this message is passed on by the thalamic relay cell. In other words, the drivers may 'make' the message, whilst the modulators 'adjust' the message.

### **First order and higher order nuclei**

The nuclei of the dorsal thalamus can be categorized according to the afferent fibres they receive (i.e., driver or modulator fibres) (see Figure 3). The cells of first order nuclei (or 'primary' nuclei; e.g., LGN, MGN, VP) are innervated by drivers originating from a peripheral or subcortical structure, and receive feedback inputs (modulator afferents) from pyramidal cells in layer VI of the ipsilateral cortex (these cortical afferents also send branches to the RTN and this circuitry appears to have a modulatory function). In the configuration of this connectivity, visual, auditory and somatosensory afferent fibres bring peripheral information pertaining to their respective sensory modality to the first order nuclei of the thalamus (Figure 3).

In contrast to first order nuclei, higher order nuclei (or association nuclei; e.g., pulvinar, MD) receive their primary excitatory inputs (or drivers) from pyramidal cells in layer V of the ipsilateral cortex. These particular inputs to the higher order nuclei resemble the main peripheral or subcortical inputs to the first order nuclei, not only in the nature of their structure and synapses they make, but also in that they lack a branch to the RTN (Guillery, 1995). In the configuration of this connectivity, cells of higher order nuclei are involved in the passage of information (for instance with regard to the current output of the driving cortical area) from one cortical area to another via a transthalamic pathway (Figure 3); at least half of the thalamus is thought to be involved with this kind of signaling. Whilst this challenges the traditional understanding of cortico-cortical communication, it is suggested that direct cortico-cortical pathways may be providing some other function (e.g., modulatory; Sherman and Guillery, 2006). Hence it has been proposed that the higher order nuclei, which are well developed in humans, have a significant role in higher cortical functions, with the implication

that impairments of such signaling could lead to dysfunctional cortical processing (see Guillery, 1995; see Sherman and Guillery, 2006).

### **Maps in the thalamus**

Some of the early studies of visual pathways reported rapid retrograde cell degeneration in a restricted column of visual thalamus (LGN) following localized lesions in the visual cortex, together with localized visual field losses (Kaas et al., 1972); subsequent trans-neuronal retrograde degeneration in the corresponding retinae were noted. These findings suggested there was a map of the visual field not only in the visual cortex, but also in the visual thalamus. It is now well established that many of the afferent and efferent connections of the thalamus are mapped (see example of sensorimotor mapping in Figure 4). This not only includes driver afferents to first order nuclei (such as visual afferents to LGN, auditory afferents to MGN, and somatosensory afferents to VP) but also conservation of these maps in thalamic circuitry, with topographically organized first and higher order thalamocortical and corticothalamic pathways.

One suggested mechanism in neurodegenerative disease is trans-synaptic neurodegeneration: it is proposed that deafferentation from damaged cortical neurons causes synaptic dysfunction and this process leads to a neuronal propagation of disease along the related and therefore susceptible neural circuits (Palop and Mucke, 2009; Jidahra et al., 2012; Looi and Walterfang, 2012). Trans-synaptic degeneration could be one of a number of processes that leads to subcortical pathologies seen in the striatum in Huntington's disease (HD), frontotemporal dementia (FTD) and Alzheimer's disease (AD) for instance, where there is subcortical neuronal loss (Looi and Walterfang, 2012; Looi et al., 2012). A parallel

explanation may also exist in the form of the putative propagation of proteopathies (protein misfolding or prions) along the same neural circuits, also resulting in topographically distinct patterns of neural loss in most age-related neurodegenerative disease (Warren et al., 2013). Indeed it is also possible that proteopathies may also contribute to trans-synaptic neurodegeneration, though of course this does not exclude deafferentation phenomena. Similar mechanisms are likely to be at play in the other circuit structures, or hubs (such as the thalamus) in neurodegenerative disorders (Looi et al., 2014). Given the topographical relationship that the thalamus has with the cortex, one would envisage that investigating thalamic morphology may provide disease-specific maps of structural change in the cortical afferent pathways in various neurodegenerative conditions (Power and Looi, 2014; Power et al., 2015). Not surprisingly, the effect of cortical lesions in animal studies has been shown to have different effects on the receptive field properties of cells in the first order versus higher order thalamic nuclei: receptive fields of cells in first order nuclei (which receive corticothalamic modulator afferents) survive, whereas those of the relay cells of the higher order nuclei (which receive corticothalamic driver afferents) are lost (see Sherman and Guillery, 2006).

### **A critical hub in the subcortical connectome**

There are numerous well-defined neural circuits involving the thalamus in addition to those already described, such as the fronto-subcortical circuits which are proposed to underpin motor activity and behaviour in humans (see Figure 5); further, fronto-subcortical circuit dysfunction may also explain the likeness of behavioral changes seen in a plethora of frontal cortical and subcortical disorders (Cummings, 1993; Tekin and Cummings, 2002; Haber and Calzavara, 2009; Looi et al., 2012).

Fronto-subcortical circuits are named according to their function or site of origin in the cortex (e.g., 'motor' circuits: motor, oculomotor; and 'cognitive' circuits: dorsolateral prefrontal, orbitofrontal, and anterior cingulate) (see Figure 5); importantly, the functional topography of cortex is maintained throughout these circuits. The circuits share a similar organization, originating in the prefrontal cortex, then projecting to the striatum (caudate, putamen, ventral striatum), having connections with the globus pallidus and substantia nigra, and thence to the thalamus, which 'closes' the loop by projecting back to the prefrontal cortex (Figure 5). There are also 'open' connections of each of these circuits, which are thought to integrate information from functionally related sites. Within each of these circuits there are both direct and indirect pathways, which can modulate input to the thalamus, the function of which is thought modulate overall circuit activities in response to different inputs (Tekin and Cummings, 2002). There is also emerging evidence that fronto-subcortical circuits can influence each other (see Haber and Calzavara, 2009), suggestive of integrative processing. This schema has provided a useful approach to neurodegenerative conditions on a neural circuit basis, on the rationale that delimited subsets of neuropsychiatric dysfunction may share a common neural circuit basis (Cummings, 1993; Looi et al., 2012). In neurodegenerative disease it is proposed that cortical or subcortical lesions may disconnect fronto-subcortical circuits, and it is the circuit dysfunction that underpins the neuropsychiatric presentation for that disease. Such fronto-subcortical circuit dysfunction is thought to mediate the cognitive and behavioral disturbances manifest in FTD, for instance (Hodges and Patterson, 2007; Looi et al., 2012; Looi and Walterfang, 2012).

In a similar framework, a large body of structural and functional imaging studies have defined the cerebellothalamocortical circuits, linking functional areas of cerebellar cortex through the thalamus with both motor and non motor cerebral cortex, as indicated in Figure 6 (see Middleton and Strick, 1994). Functional imaging during cognitive tasks, together with tractography demonstrates cerebellar projections through motor and intralaminar thalamus to prefrontal cortex, supporting the role of these circuits not only in motor but also cognitive processing (Prevosto and Summer, 2013). It has been proposed that dysfunction of cerebellothalamocortical circuits may underpin the manifest emotional and cognitive dysfunction in a range of neuropsychiatric conditions (Schmahmann, 2004; Konarski et al., 2005; Andreasen and Pearson, 2008).

As such, the thalamus may be considered a crucial hub in the network of subcortical structures that underpins significant intra- and inter-hemispheric circuit connectivity, known collectively as the subcortical connectome (see Looi et al., 2014). Therefore, further investigating the thalamus and its topographically distinct morphology is likely to yield important information across the broad spectrum of neuropsychiatric conditions.

### **Thalamic function and dysfunction**

Classically the thalamus has been referred to as ‘the gateway’ to the cortex as it was thought that the dorsal thalamus was limited to functioning as a relay of information; in this respect it has been regarded as a group of cells that are concerned with passing information on to the cerebral cortex about the activity of either the periphery or other parts of the central nervous system. The thalamus has also been linked to many more functions, for example in transferring information between different cortical areas (Guillery, 1995), influencing states



of arousal through its connections with the brainstem and basal forebrain (Steriade and Deschenes, 1984), sharpening or synchronization of input from the cortex (Sillito et al., 1994) and generating salience (Crick, 1984).

The current conceptualization of thalamic function is as a modulatory gate, with thalamic relay cells conveying the message from their driving afferent fibre (either cortical or subcortical) to the cortex. Transmission of the message occurs with the thalamic relay cell either in burst or tonic modes, without a significant change in the message from the driving afferent. The relay of information is influenced by a range of modulatory inputs, adjusting the way in which the information is relayed rather than altering the nature of the relayed information. One of the many but key challenges facing neuroscientists investigating the thalamus is to clarify precisely what benefit is obtained by sending information through the thalamus before it reaches the cortex. As postulated by Sherman and Guillery (2006), an advantage of higher order nuclei and transthalamic corticocortical communication could be that, “the thalamus could serve as the organ of reflection of cortical activity back upon itself”; they argue that the role of the thalamus in perceptual processing is likely to be significant and speculate that a function of thalamocortical inputs to cortex (either from relay cells of first order or higher order thalamic nuclei) could be to keep the cortex updated on the most recent motor commands (Sherman and Guillery, 2006).

Taken together, when considering the role of the thalamus in neurological and psychiatric disorders one could therefore consider dysfunction of the neural circuits involving the thalamus and a failure of modulatory gating, rather than neuropsychiatric symptoms somehow arising directly from the thalamus itself.

## **NEUROIMAGING THE THALAMUS**

Neuroimaging has been used as a means to visualize and measure the thalamus in vivo and we propose that this can lead towards a quantitative morphology, otherwise known as morphometry.

### **Modalities utilized for imaging the thalamus**

Whilst a range of functional imaging modalities can be utilized to estimate thalamic function, structural imaging techniques have a higher spatial resolution than functional imaging methods, ideal for investigating diminutive subcortical structures. With the evolution of structural MRI modalities and advanced image analytic methods, more precise quantification of changes in the size and shape in subcortical structures such as the thalamus can be achieved. In terms of structural MRI, meta-analyses have reported thalamic atrophy in schizophrenia (Adriano et al., 2010) and major depressive disorder (Du et al., 2012), but not in bipolar disorder (Hallahan et al., 2011). Thalamic atrophy has been reported in in both sporadic AD (de Jong et al., 2008) and in the pre-symptomatic stage of familial AD (Lee et al., 2013; Ryan et al., 2013), as well as in progressive supranuclear palsy (PSP) (Whitwell et al., 2011), FTD (Cardenas et al., 2007; Chow et al., 2008) and HD (Kassubek et al., 2005).

Analytical methods [(e.g., spherical harmonic point distribution method (SPHARM-PDM) (Styner et al., 2006); radial distance mapping (Madsen et al., 2010)] measure the surfaces of neural structures using 3 dimensional models (or mathematical ‘meshes’) allowing comparison of surface regions of a structure between diagnostic groups. These methods can

expose statistically significant regional volume differences in the thalamus, which can provide important information regarding which underlying subdivisions or nuclei of the thalamus could be affected in the disease state being investigated (see McKeown et al., 2008).

Thalamic nuclei can also be defined by their patterns of thalamocortical connectivity (see Table 1), hence diffusion tensor imaging (DTI) and tractography is a useful modality that enables one to visualize discrete white matter neural tracts, allowing the subdivisions and nuclei of thalamus to be imaged according to preselected cortical areas. DTI has been utilized to divide the thalamus into thalamocortical domains (Jakab et al., 2012), and this modality has the potential to yield specific localization of functional activations or lesions to putative thalamic nuclei. Given that most of the afferent and efferent fibres of the thalamus are mapped, DTI will be pivotal in further exploring the role of the thalamus in neurodegenerative disorders. Mapping of the thalamus within widespread networks will also be greatly facilitated by advances in resting state fMRI, and better understand the distinct spatio-temporal courses of various neurodegenerative disorders (Zhou et al., 2012).

Furthermore, merging these newer techniques (e.g., generated statistical shape models and connectivity maps) and advanced modalities (e.g., either DTI or PET and matching sophisticated MRI scanning and advanced analytical techniques) has the potential when correlated with clinical features to further enhance our understanding of various neuropsychiatric disorders (see McKeown et al., 2008; and Whitwell et al., 2011). Hence, advances in neuroimaging modalities will increasingly enable researchers to more precisely quantify the disease effect on thalamic morphology.

## Technical challenges

There are a number of challenges faced when attempting morphological analysis of the thalamus, namely associated with thalamic boundary definition within the constraints of the resolution afforded by current imaging technologies. Defining the inferior boundary is particularly problematic along the intercommissural distance, and utilizing distinctive nuclei (such as the red nucleus and subthalamic nucleus) and white matter tracts as landmarks is imperative (Figure 1); the nuclei of the ventral thalamus (in particular the RTN and ZI) that partly encapsulate the dorsal thalamus throughout its rostral-caudal extent can also enhance inferior and lateral boundary definition (rather than being included in morphological analysis with the dorsal thalamus) (see Power et al., 2015) (Figure 1). The rostral pole of the dorsal thalamus is particularly challenging, and in order to exclude it from the adjacent hypothalamus and capture the full extent of this boundary, it has been suggested thalamic tracing should ideally occur with brain slices no greater than 1mm thickness and proceed in a caudal to rostral direction (the caudal pole being readily identifiable as the pulvinar) (see Power et al., 2015). A number of automated approaches to mapping thalamic morphology, whilst having research utility as they can deal efficiently with a large numbers of brain scans, have thus been limited in their ability to precisely define thalamic boundaries (see Andreasen et al., 1994); studies utilizing automatic segmentation protocols often report larger mean thalamic volumes (Zarei et al., 2010; Ryan et al., 2013). Manual segmentation of the thalamus has therefore been utilized as the preferred approach, particularly in the setting of significant inter-individual variability of the thalamus and its component nuclei (see Spinks et al., 2002; Uylings et al., 2008).

A number of groups have published validated protocols for manual segmentation of the thalamus using structural MRI, however the majority lack detailed information regarding precise boundary definition (see Power et al., 2015 for review). Many studies employ the approach published by Portas and colleagues (1998) who detailed an approach manual segmentation in 20-21 consecutive coronal 1.5mm slices in a rostral-caudal direction; whilst providing a comprehensive description of adjacent land marks, there is little information to guide manual tracing of the challenging inferior boundary and rostral pole, for instance. There are similar limitations in the protocol published by Spinks and colleagues (2002), involving 12 coronal 1.5mm slices, however an advancement of their technique was the utilization of three imaging modalities (T1, T2 and PD weighted images) and functions within the software package (BRAINS2) to assist with boundary definition. Our own group has recently published a protocol of manual segmentation using 28-30 consecutive 1mm coronal slices using ANALYZE 11.0 software addressing many of the limitations and building on some of the advances of previous works (Power et al., 2015).

It is anticipated that advanced neuroimaging protocols for manual segmentation of the thalamus using structural MRI will drive the emergence of technologies towards more precise automated segmentation techniques of the human thalamus, which would improve efficiency both in the clinical and research setting. For the time being, further research is required in order to investigate the correlation of newer protocols with existing automated techniques. Whatever strategies emerge, they will need to be widely accessible, inexpensive (e.g., using software freely available on the web) and generalizable (i.e., use techniques that can be incorporated across a variety of software packages) in order for them to be relevant.

## THALAMIC MORPHOLOGY IN NEURODEGENERATIVE DISORDERS

### **Conceptualization of neurodegenerative disorders on a neural circuit basis.**

Two key features characterize most age-related neurodegenerative disorders, the first being abnormal folding and accumulation of disease-specific proteins (sometimes termed 'proteopathic' agents) such as tau, beta amyloid or synuclein, and the second being progressive pathological change across the neuraxis (Braak and Braak, 1991; Braak et al., 2003; Deng et al., 2004; Kril and Halliday, 2011) (see Figure 7). The mechanism of disease 'spread', particularly by extant neuronal networks, has become an important research focus, on the rationale that by better understanding such mechanisms one could potentially develop treatment modalities to halt the spread of disease throughout the brain.

Stemming from advances in the understanding the mechanism by which abnormal prion proteins lead to neurodegenerative processes (Prusiner, 1982; Aguzzi and Polymenidou, 2004), similar frameworks have been applied to investigating neurodegeneration in a range of disorders. Researchers have attempted to 'seed' proteopathic agents such as beta amyloid and tau in animal models, and various lines of evidence have suggested that spread of seeded protein aggregates occurs in distinct spatial (i.e., anatomical) and temporal patterns (for review see Walker and LeVine, 2012). Researchers subsequently proposed that different neurodegenerative disorders have patterns of disease spread that is characteristic, with the clinical correlate being a distinctive clinical syndrome for that disorder (i.e., a characteristic temporal constellation of cognitive, emotional, behavioral and motor features) (see Brundin et al., 2010; and Polymenidou and Cleveland, 2012). Following advances in methods such as graph theory to better understand neural circuitry (Bullmore and Sporns, 2009), and

combined with structural and functional neuroimaging, a more recent conceptualization of neurodegenerative disorders on a neural circuit basis has emerged (Brundin et al., 2010) (see Figure 7). Researchers propose that proteopathic agents take seed in a specific part of the neuraxis and then spread throughout the brain's intrinsic pathways over time, causing neural damage and/ or dysfunction through a range of mechanisms in both cortical and subcortical structures (Seeley et al., 2009; Zhou et al., 2012; Raj et al., 2012; Warren et al., 2013).

Neuroimaging studies in the common neurodegenerative disorders have tended to focus on dysfunctional neocortical rather than subcortical circuits, the most parsimonious explanation being that neocortex dysfunction was thought to underpin the cognitive dysfunction that often presents early in disease. There is a burgeoning body of literature identifying the important role of subcortical structures in these circuits and contributing to cognitive disturbance in neurodegenerative disorders, such as the striatum in AD, behavioral variant FTD, progressive nonfluent aphasia (PNFA) and stroke (de Jong et al., 2008; Seeley et al., 2009; Looi et al., 2009; Zhou et al., 2012; Looi et al., 2012). To date, relatively few studies have investigated thalamic morphology in the neurodegenerative disorders; as a pivotal structure in the subcortical connectome such investigations are likely to be fruitful (see Looi et al., 2014; Power and Looi, 2014; Power et al., 2014).

### **Thalamic morphology in healthy aging**

In a study of 57 healthy subjects ranging in age from 21-82 years of age who underwent neurocognitive testing (Stroop test and Pencil Memory Scanning Test) and structural MRI, a decrease in thalamic volume was reported across the lifespan (van der Werf et al., 2001); this decrease in thalamic volume was reported to be independent of the decrease in total brain

volume, and found to occur prior to it. Thalamic atrophy was found to start early in the lifespan and have a linear association with advancing age; the same study reported that thalamic atrophy correlated with diminished performance on tests of processing speed (van der Werf et al., 2001). More normative data is needed regarding thalamic morphology across the lifespan.

### **Thalamic morphology in Alzheimer's dementia**

Thalamic atrophy on MRI has been reported in sporadic AD relative to controls (Callen et al., 2001; de Jong et al., 2008; Zarei et al., 2010). Further, thalamic atrophy in AD is associated independently with cognitive deterioration using the CAMCOG-R and MMSE in a cohort of memory clinic patients diagnosed with probable AD (n=69) relative to those without objective memory deficits ("memory complainers", n=70) when controlled for age, gender, educational level, intra cranial volume and neocortical grey matter volume (de Jong et al., 2008). Combining shape and connectivity analysis in 16 patients with AD compared with 22 healthy controls, Zarei and colleagues (2010) reported bilateral atrophy in the regions of the MD nuclei of the thalamus (in regions connected with prefrontal and temporal cortex, and hippocampus), as well as bilateral atrophy in anterodorsal regions of the thalamus (which they attributed to possible internal medullary lamina atrophy). Their findings are, in part, consistent with reports of amyloid deposits and neurofibrillary tangles in the limbic nuclei of the thalamus, especially the MD and sub regions of the AN, and involving the IL nuclei (Braak and Braak, 1991; Xuereb et al., 1991).

In familial AD, thalamic atrophy (Lee et al., 2013; Ryan et al., 2013) and increased fractional anisotropy of the thalamus bilaterally (Ryan et al., 2013) has been reported in the pre-



symptomatic stage of disease, consistent with amyloid imaging studies demonstrating that amyloid deposition first occurs in the striatum and thalamus in pre-symptomatic cohorts (see Knight et al., 2011). Longitudinal studies of thalamic morphology in both sporadic and familial AD are warranted.

### **Thalamic morphology in parkinsonian disorders**

In the early stages of PSP and PD, these disorders can be difficult to distinguish, and definitive diagnosis is established by postmortem observation of characteristic histological abnormalities and regional pathology. Whilst neuronal loss is seen post mortem in the intralaminar thalamic nuclei in both PSP and PD, degeneration in motor thalamus is reported in PSP, but not PD (Henderson et al., 2000; Halliday et al., 2005); the authors speculate that dysfunction of cerebellothalamic pathways in PSP may be an important distinguishing feature. Hence, the identification of distinguishing features on MRI between PSP and PD (and other parkinsonian disorders, such as corticobasal syndrome (CBS)) may improve diagnostic accuracy in vivo.

Thalamic atrophy on MRI has been reported in cohorts with PSP relative to controls, but not in patients with PD, multisystem atrophy, CBS or dementia with Lewy bodies (DLB) (Cordato et al., 2005; Boxer et al., 2006; Watson et al., 2009; Messina et al., 2011); it should be noted that at least some DTI data has suggested different topographical involvement of the thalamus in CBS relative to PSP (Erbeta et al., 2009; Hess et al., 2014), but these studies are difficult to interpret.

A number of multimodal studies, both cross sectional and longitudinal, have reported involvement of particular thalamic nuclei in PSP. In a small cross sectional involving 14 patients with 'mild' PSP and 14 healthy controls undergoing DTI and structural MRI, Padovani and colleagues (2006) reported thalamic atrophy involving the pulvinar, MD and AN bilaterally. In a multi-modal imaging study, 18 patients with probable PSP and 18 healthy controls underwent resting state fMRI, DTI and structural MRI; atrophy in the thalamus in the PSP group on MRI was reported, with reduced thalamic functional connectivity using fMRI, and DTI data implicating the VL (or motor) thalamus (Whitwell et al., 2011). Moreover, a PET and fMRI study in 16 patients with PSP suggested imbalance and falls correlated with thalamic dysfunction (Zwergal et al., 2011). In a longitudinal study Whitwell and colleagues (2011), 16 patients with 'probable' PSP had serial MRIs and clinical measures (including the PSP rating scale) at 6 months and 12 months of follow up; progressive thalamic atrophy over time was observed, however no correlation between thalamic atrophy and clinical measures was observed.

Recent imaging data suggests there may be subtle nuances with regard to thalamic morphology in PD. Automated MRI data suggests left thalamic atrophy in PD with dementia compared to those with PD without dementia (Summerfield et al., 2005) and, furthermore, using spherical harmonic-based representations shape (but not volume) changes have been reported in the thalami in PD (McKeown et al., 2008). McKeown and colleagues (2008) suggest these shape differences may represent selective non-dopaminergic degeneration reported in the caudal IL nuclei of the thalamus in PD (Henderson et al., 2000), and that detecting these subtle changes may be limited by the resolution of MRI (McKeown et al., 2008).

### **Thalamic morphology in other neurodegenerative disorders**

Thalamic morphology has been investigated in a range of additional neurodegenerative disorders. Thalamic atrophy has been reported in patients with FTD compared with controls (Cardenas et al., 2007; Chow et al., 2008), however few studies have investigated whether these morphological features characterize the spectrum of FTDs, and whether thalamic morphology could assist in delineating various subtypes of this entity. Rohrer and colleagues (2010) investigated 18 FTD patients who had antemortem MRI and postmortem confirmation of the TDP-43 subtype of FTD (positive immunoreactive inclusions), and using voxel-based morphometry reported that thalamic atrophy was useful in distinguishing FTD TDP-43 type 3 relative to types 1 and 2. Sharon and colleagues (2012) investigated patterns of brain atrophy in FTD patients who were carriers for chromosome open reading frame 72 (C9ORF72) expansions, and reported greater thalamic atrophy (left>right) in carriers vs non carriers of this expansion.

Thalamic atrophy on MRI has been reported in HD in the regions of MD, and the VL and IL nuclear groups bilaterally (Kassubek et al., 2005), consistent with postmortem findings (Heinsen et al., 1999). However, not all studies have reported thalamic atrophy in HD (Rosas et al., 2003). In a study with 44 HD patients (genetically confirmed) and 22 controls, using the Stroop color word and Digit Symbol tests, thalamic atrophy correlated with cognitive impairment but not motoric dysfunction in the early clinical stages of disease (Kassubek et al., 2005).

### **Thalamic morphology in multiple sclerosis**

Thalamic atrophy appears to be an important feature in multiple sclerosis (MS) (for review see Minagar et al., 2013), and has been correlated post mortem with neuronal loss or altered cytoarchitecture in the thalamus, in particular in the MD and LGN (Cifelli et al., 2002; Verceillino et al., 2009). Thalamic atrophy has been reported in pediatric populations with MS (Kerbrat et al., 2012) and in adults with MS it is one of the earliest and most prominent features of subcortical grey matter pathology when patients present with clinically isolated syndrome (CIS) (Calabrese et al., 2011). Thalamic atrophy has been demonstrated in the spectrum of MS subtypes, and has been correlated with cognitive and functional impairment in MS (Houtchens et al., 2007; Mesaros et al., 2011; Batista et al., 2012). Multimodal longitudinal studies are warranted to elucidate the interplay of these findings in MS, and better define the utility of thalamic morphology in MS from a clinical perspective.

## **TOWARDS THALAMIC ENDOPHENOTYPES AND BIOMARKERS IN NEURODEGENERATIVE DISEASE**

### **Towards endophenotypes and biomarkers**

The concept of intermediate phenotypes (or endophenotypes) has been described as, “measurable components unseen by the unaided eye along the pathway between disease and distal genotype” (Gottesman and Gould, 2003). This concept has already been applied to the morphology of subcortical structures in neurodegenerative disorders, such as the striatum (Looi and Walterfang, 2012). As outlined, there is a growing body of literature reporting thalamic involvement across a broad range of neurodegenerative disorders. Whilst further studies are required to ascertain whether genetic factors are associated with thalamic volume, there is evidence of distinct patterns of altered thalamic morphology in many

neurodegenerative disorders, and some evidence of an association between morphology and clinical features in those disorders. Should further evidence converge suggesting that distinctive genetic, morphological and clinical features are associated with the thalamus, this may provide a basis for thalamic endomorphotypes. Leading on from this argument, investigating thalamic morphology (as a measurable characteristic of disease) therefore has the potential to yield neuroimaging biomarkers in the neurodegenerative disorders.

### **Potential utility of the thalamus as a morphological biomarker in neurodegenerative disease**

Neuroimaging investigation of subcortical structures is likely to contribute knowledge regarding how the morphology (shape and volume) of structures, such as the thalamus, underpins the neural circuits subserving cognition, emotion, movement and behaviour. Utilizing thalamic morphology in neurodegenerative disorders has the potential not only to assist with diagnostic clarification, but is likely to contribute to better understanding the spatio-temporal course in various diseases. Further, characterizing the disease effects on this strategic 'hub' in the subcortical connectome will enable neuroimaging to be utilized to map the onset, progression and ultimately (when disease-modifying agents are accessible), response to treatment modalities in a form directly related to the neuropsychiatric symptoms and signs of disease (e.g., cognitive, emotional, behavioral and motor dysfunction).

### **FUTURE DIRECTIONS AND CHALLENGES**

Further multifaceted studies will be required to advance the frontiers of knowledge of the subcortical connectome, in order better comprehend the complexity of brain disease on a

neural circuit basis. With regards to the thalamus as a central hub in the connectome, additional studies are required to better understand the genetic basis of thalamic morphology, including processes of neurodevelopment, neurogenesis and apoptosis in the thalamus. Neuroimaging studies will need to investigate associations of thalamic morphology with a range of clinical markers in health and disease, including neurocognitive function, emotion and behavior, and motoric function. Longitudinal studies are warranted to ascertain the temporal and spatial effects of disease processes on thalamic morphology, particularly in patient cohorts with well-established genetic vulnerabilities.

Given the challenges of thalamic boundary definition and variability of methods employed between neuroimaging studies, widely available and validated protocols for segmentation of the thalamus on MRI using sophisticated imaging techniques and brain analysis software will need to be established in order for morphological studies to progress and be reproducible. These protocols may well lead to more reliable automated segmentation techniques, in essence rendering automated techniques redundant in the future. Multimodal neuroimaging approaches will be essential (such as combining structural MRI, with DTI and shape analysis) in order to fully appreciate the impact of disease processes on different thalamic nuclei, and (through the well-established topographical relationships of the thalamus) better appreciate the diseased brain circuitry.

In the *Odyssey*, Book 19 comes an early usage of thalamos: “ἡ δ' ἔεν ἐκ θαλάμοιο περίφρων Πηνελόπεια, Ἀρτέμιδι ἰκέλη ἠὲ χρυσῆν Ἀφροδίτην”; translated by Fagles (1996), “Now down from her chamber came reserved Penelope, looking for all the world like Artemis or golden Aphrodite”). Emerging from the chamber of thalamic morphology we may come upon the

vista of neural circuit dysfunction in neurodegenerative disorders and, given its particular relationship with cortex, perhaps it may be one of the most panoramic.

## **ACKNOWLEDGEMENTS**

BDP conceived and wrote the first draft of the manuscript, and is guarantor for this paper; JCLL co-conceived the work as the research network coordinator. All authors contributed to the final version of the manuscript. Given the restrictions on the number of references, only limited citations are provided on the section Basic and Clinical Neuroanatomy of the Thalamus.

This research received no specific grant from any funding agency in the public, commercial or not-for-profit sectors. BDP's academic time is supported by the School of Medicine Fremantle, The University of Notre Dame Australia, and JCLL's academic time by the Research Centre for the Neurosciences of Ageing, Academic Unit of Psychiatry and Addiction Medicine, Australian National University Medical School.

### **Declaration of conflicting of interests**

The authors declare that there is no conflict of interest. The authors alone are responsible for the content and writing of the paper.



## REFERENCES

Adriano F, Spoletini I, Caltagirone C, Spalletta G (2010) Updated meta-analyses reveal thalamus volume reduction in patients with first-episode and chronic schizophrenia. *Schizophrenia Research* 123: 1-14.

Aguzzi A, Polymenidou M (2004) Mammalian prion biology: one century of evolving concepts. *Cell* 116: 313-327.

Andreasen NC, Arndt S, Swayze V, et al. (1994) Thalamic abnormalities in schizophrenia visualized through magnetic resonance image averaging. *Science* 266: 294-298.

Andreasen NC, Pearson R (2008) The role fo the cerebellum in schizophrenia. *Biological Psychiatry* 64: 81-88.

Batista S, Zivadinov R, Hoogs M, et al. (2012) Basal ganglia, thalamus and neocortical atrophy predicting slowed cognitive processing in multiple sclerosis. *Journal of Neurology* 259: 139-146.

Blackshaw S, Scholpp S, Placzek M, Ingraham H, Simerly R, Shimogori T (2010) Molecular pathways controlling development of thalamus and hypothalamus: from neural specification to circuit formation. *Journal of Neuroscience* 30: 14925-14930.

Bosman LWJ, Houweling AR, Owens CB, et al. (2011) Anatomical pathways involved in generating and sensing rhythmic whisker movements. *Frontiers in Integrative Neuroscience* 5: 53.

Bourassa J, Pinault D, Deschenes M (1995) Corticothalamic projections from the cortical barrel field to the somatosensory thalamus in rats: a single-fibre study using biocytin as an anterograde tracer. *European Journal of Neuroscience* 7: 19-30.

Boxer AL, Geschwind MD, Belfor N, et al. (2006) Patterns of brain atrophy that differentiate corticobasal degeneration syndrome from progressive supranuclear palsy. *Archives of Neurology* 63: 81-86.

Braak H, Braak E (1991) Alzheimer's disease effects limbic nuclei of the thalamus. *Acta Neuropathologica* 81: 261-268.

Braak H, Rub U, Gai WP, Del Tredici K (2003) Idiopathic Parkinson's disease: possible routes by which vulnerable neuronal types may be subject to neuroinvasion by an unknown pathogen. *Journal of Neural Transmission* 110: 517-536.

Brucato N, Guadalupe T, Franke B, Fisher SE, Francks C (2015) A schizophrenia-associated HLA locus affects thalamic volume and asymmetry. *Brain Behavior and Immunology* DOI: 10.1016/j.bbi.2015.02.021.

Brundin P, Melki R, Kopito R (2010) Prion-like transmission of protein aggregates in neurodegenerative disease. *Nature Reviews Molecular Cell Biology* 11: 301-307.

Bulfone A, Puelles L, Porteus MH, Frohman MA, Martin GR, Rubenstein JL (1993) Spatially restricted expression of Dlx-1, Dlx-2 (Tes-1), Gbx-2, and Wnt-3 in the embryonic day 12.5 mouse forebrain defines potential transverse and longitudinal segmental boundaries. *Journal of Neuroscience* 13: 3155-3172.

Bullmore E, Sporns O (2009) Complex brain networks: graph theoretical analysis of structural and functional system. *Nature Reviews Neuroscience* 10: 186-198.

Byne W, Hazlett EA, Buchsbaum MS, Kemether E (2009) The thalamus and schizophrenia: current status of research. *Acta Neuropathologica* 117: 347-368.

Calabrese M, Rinaldi F, Mattisti I, et al. (2011) The predictive value of gray matter atrophy in clinically isolated syndromes. *Neurology* 77: 257-263.

Callen DJ, Black SE, Gao F, Caldwell CB, Szalai JP (2001) Beyond the hippocampus: MRI volumetry confirms widespread limbic atrophy in AD. *Neurology* 57: 1669-1674.

Cardenas VA, Boxer AL, Chao LL, et al. (2007) Deformation-based morphometry reveals brain atrophy in frontotemporal dementia. *Archives of Neurology* 64: 873-877.

Chow TW, Izenberg A, Binns MA, et al. (2008) Magnetic resonance imaging in frontotemporal dementia shows subcortical atrophy. *Dementia and Geriatric Cognitive Disorders* 26: 79-88.

Cifelli A, Arridge M, Jezzard P, Esiri MM, Palace J, Matthews PM (2002) Thalamic neurodegeneration in multiple sclerosis. *Annals of Neurology* 52: 650-653.

Cordato NJ, Duggins AJ, Halliday GM, Morris JG, Pantelis C (2005) Clinical deficits correlate with regional cerebral atrophy in progressive supranuclear palsy. *Brain* 128: 1259-1266.

Crick F (1984) Function of the thalamic reticular complex: The searchlight hypothesis. *Proceedings of the National Academy of Science USA* 81: 4586-4590.

Cummings JL (1993) Frontal subcortical circuits and human behavior. *Archives of Neurology* 5: 873-880.

Darien-Smith C, Tan A, Edwards S (1999) Comparing thalamocortical and corticothalamic microstructure and spatial reciprocity in the macaque ventral posterolateral nucleus (VPLc) and medial pulvinar. *Journal of Comparative Neurology* 410: 211-234.

de Jong LW, van der Hiele K, Veer IM, et al. (2008) Strongly reduced volumes of putamen and thalamus in Alzheimer's disease: an MRI study. *Brain* 131: 3277-3285.

Deng YP, Albin RL, Penney JB, Young AB, Anderson KD, Reiner A (2004) Differential loss of striatal projection systems in Huntington's disease: a quantitative immunohistochemical study. *Journal of Chemical Neuroanatomy* 27: 143-164.

Du MY, Wu QZ, Yue Q et al. (2012) Voxelwise meta-analysis of gray matter reduction in major depressive disorder. *Progress in Neuro-Psychopharmacology and Biological Psychiatry* 36: 11-16.

Erbetta A, Mandelli ML, Savoiardo M, et al. (2009) Diffusion Tensor Imaging shows different topographic involvement of the thalamus in progressive supranuclear palsy and corticobasal degeneration. *American Journal of Neuroradiology* 30: 1482-1487.

Fagles, R., 1996. Homer: The Odyssey. Penguin Books Australia Ltd, Ringwood Australia.

Gottesman II, Gould TD (2003) The endophenotype concept in psychiatry: etymology and strategic intentions. *American Journal of Psychiatry* 160: 636-645.

Guillery RW (1995) Anatomical evidence concerning the role of the thalamus in corticocortical communication: a brief review. *Journal of Anatomy* 187: 583-592.

Haber S, Calzavara R (2009) The cortico-basal ganglia integrative network: The role of the thalamus. *Brain Research Bulletin* 78: 69-74.

Hallahan B, Newell J, Soares JC, et al. (2010) Structural magnetic resonance imaging in bipolar disorder: an international collaborative mega-analysis of individual adult patient data. *Biological Psychiatry* 69: 326-35.

Halliday GM, Macdonald V, Henderson JM (2005) A comparison of degeneration in motor thalamus and cortex between progressive supranuclear palsy and Parkinson's disease. *Brain* 128: 2272-2280.

Heinsen H, Rub U, Bauer M et al. (1999) Nerve cell loss in the thalamic mediodorsal nucleus in Huntington's disease. *Acta Neuropathologica* 97: 613-622.

Henderson JM, Carpenter K, Cartwright H, Halliday GM (2000) Loss of thalamic intralaminar nuclei in progressive supranuclear palsy and Parkinson's disease: clinical and therapeutic implications. *Brain* 123: 1410-1421.

Hess CP, Christine CW, Apple AC, Dillon WP, Aminoff MJ (2014) Changes in the thalamus in atypical parkinsonism detected using shape analysis and diffusor tensor imaging. *American Journal of Neuroradiology* 35: 897-903.

Houtchens MK, Benedict RH, Killiany R, et al. (2007) Thalamic atrophy and cognition in multiple sclerosis. *Neurology* 69: 1213-1223.

Jakab A, Blanc R, Berenyi EL, Szekely G (2012) Generation of individualized thalamus target maps using statistical shape models and thalamocortical tractography. *American Journal of Neuroradiology* 33: 2110-2116.

Jindahra P, Petrie A, Plant GT (2012) The time course of retrograde trans-synaptic degeneration following occipital lobe damage in humans. *Brain* 135: 534-541.

Jones EG (2007) *The Thalamus*, second ed. Cambridge University Press, Cambridge UK.

Kaas JH, Hall WC, Killackey HP, Diamond IT (1972) Visual cortex of the tree shrew (*Tupaia glis*): architectonic subdivisions and representations of the visual field. *Brain Research* 42, 491-496.

Kassubek J, Juengling FD, Ecker D, Landwehrmeyer GB (2005) Thalamic atrophy in Huntington's Disease co-varies with cognitive performance: a morphometric MRI analysis. *Cerebral Cortex* 15: 846-853.

Kerbrat A, Aubert-Broche B, Fonov V et al. (2012) Reduced head and brain size for age and disproportionately smaller thalami in child-onset MS. *Neurology* 78: 194-201.

Knight WD, Okello AA, Ryan NS et al. (2011) Carbon-11-Pittsburgh compound B positron emission tomography imaging of amyloid deposition in presenilin 1 mutation carriers. *Brain* 134: 293-300.

Kolmac CI, Power BD, Mitrofanis J (2000) Dorsal thalamic connections of the ventral lateral geniculate nucleus. *Journal of Neurocytology* 29: 31-41.

Konarski JZ, McIntyre RS, Grupp LA, Kennedy SH (2005) Is the cerebellum relevant in the circuitry of neuropsychiatric disorders? *Journal of Psychiatry and Neuroscience* 30: 178-186.

Kril JJ, Halliday GM (2011) Pathological staging of frontotemporal lobar degeneration. *Journal of Molecular Neuroscience* 45: 379-383.

Lee GJ, Lu PH, Medina LD, Rodriguez-Agudelo Y, Melchor S, Coppola G (2013) Regional brain volume differences in symptomatic and presymptomatic carriers of familial Alzheimer's disease mutations. *Journal of Neurology, Neurosurgery and Psychiatry* 84: 154-162.

Looi JCL, Tatham V, Kumar R et al. (2009) Caudate nucleus volumes in stroke and vascular dementia. *Psychiatry Research* 174: 67-75

Looi JCL, Walterfang M (2012) Striatal morphology as a biomarker in neurodegenerative disease. *Molecular Psychiatry* 18: 417-424.

Looi JCL, Walterfang M, Velakoulis D, Macfarlane MD, Svensson L, Wahlund LO (2012) Frontotemporal Dementia as a frontostriatal disorder: neostriatal morphology as a biomarker and structural basis for an endophenotype. *Australian and New Zealand Journal of Psychiatry* 46: 422-434.



Looi JCL, Walterfang M, Nilsson C, et al. (2014) The subcortical connectome: hubs, spokes and the space between. *Australian and New Zealand Journal of Psychiatry* 48: 306-309.

Madsen SK, Ho AJ, Hua X, et al. (2010) 3D maps localize caudate nucleus atrophy in 400 AD, MCI, and healthy elderly subjects. *Neurobiology of Aging* 31: 1312-1325.

McKeown MJ, Uthama A, Abugharbieh R, Palmer S, Lewis M, Huang X (2008) Shape (but not volume) changes in the thalami in Parkinson disease. *BioMed Central Neurology* 8, 8 DOI:10.1186/1471-2377-8-8.

Mesaros S, Rocca MA, Pagani E, et al. (2011) Thalamic damage predicts the evolution of primary-progressive multiple sclerosis at 5 years. *American Journal of Neuroradiology* 32: 1016-1020.

Messina D, Cerasa A, Condino F et al. (2011) Patterns of brain atrophy in Parkinson's disease, progressive supranuclear palsy and multiple system atrophy. *Parkinsonism and Related Disorders* 17: 172-176.

Middleton FA, Strick PL (1994) Anatomical evidence for cerebellar and basal ganglia involvement in higher cognitive function. *Science* 266: 458-461.

Minagar A, Barnett MH, Benedict RHB, et al. (2013) The thalamus and multiple sclerosis. *Neurology* 80: 210-219.

Mitrofanis J (2005) Some uncertainty for the “zone of uncertainty”? Exploring the function of the zona incerta. *Neuroscience* 130: 1-15.

Padovani A, Borroni B, Brambati SM, et al. (2006) Diffusion tensor imaging and voxel based morphometry study in early progressive supranuclear palsy. *Journal of Neurology, Neurosurgery and Psychiatry* 77: 457-463.

Palop JJ, Mucke L, (2009) Synaptic depression and aberrant excitatory network activity and Alzheimer’s disease: two faces of the same coin? *Neuromolecular Medicine* 12: 48-55.

Polymenidou M, Cleveland DW (2012) Prion-like spread of protein aggregates in neurodegeneration. *Journal of Experimental Medicine* 209: 889-893.

Portas CM, Goldstein JM, Shenton ME, et al. (1998) Volumetric evaluation of the thalamus in schizophrenic male patients using magnetic resonance imaging. *Biological Psychiatry* 43: 649-659.

Power BD, Kolmac CI, Mitrofanis J (1999) Evidence for a large projection from the zona incerta to the dorsal thalamus. *Journal of Comparative Neurology* 404: 554-565.

Power BD, Wilkes FA, Santillo A, et al. (2015) Validation of a protocol for manual segmentation of the thalamus on magnetic resonance imaging scans. *Psychiatry Research-Neuroimaging*. doi: 10.1016/j.psychresns.2015.02.001.

Power BD, Looi JCL (2014) The thalamus as a putative biomarker in neuropsychiatry. *OA Neurosciences* 2: 6.

Prevosto V, Sommer MA (2013) Cognitive control of movement via the cerebellar-recipient thalamus. *Frontiers in Systems. Neuroscience* 7: 56.

Prusiner SB (1982) Novel proteinaceous infectious particles cause scrapie. *Science* 216: 136-144.

Puelles L, Rubenstein JL (2003) Forebrain gene expression domains and the evolving prosomeric model. *Trends in Neuroscience* 26: 469-476.

Raj A, Kuceyeski A, Weiner MA (2012) Network diffusion model of disease progression in dementia. *Neuron* 73: 1204-1215.

Rohrer JD, Geser F, Zhou J, et al. (2010) TDP-43 subtypes are associated with distinct atrophy patterns in frontotemporal dementia. *Neurology* 75: 2204-2211.

Rosas HD, Koroshetz WJ, Chen YI, et al. (2003) Evidence for more widespread cerebral pathology in early HD: an MRI-based morphometric analysis. *Neurology* 60: 1615-1620.

Ryan NS, Keihaninejad S, Shakespeare TJ, et al. (2013) Magnetic resonance imaging evidence for presymptomatic change in thalamus and caudate in familial Alzheimer's disease. *Brain* 136: 1399-1414.

Schmahmann JD (2004) Disorders of the cerebellum, dysmetria of thought, and the cerebellar cognitive affective syndrome. *Journal of Neuropsychiatry and Clinical Neuroscience* 16: 367-378.

Scholpp S, Delogu A, Gilthorpe J, Peukert D, Schindler S, Lumsden A (2009) Her6 regulates the neurogenetic gradient and neuronal identity in the thalamus. *Proceedings of the National Academy of Science USA* 106: 19895-19900.

Seeley WW, Crawford RK, Zhou J, Miller BL, Greicius MD (2009) Neurodegenerative diseases target large-scale human brain networks. *Neuron* 62: 42-52.

Sharon JS, Takada LT, Rankin KP, et al. (2012) Frontotemporal dementia due to C9ORF72 mutations Clinical and imaging features. *Neurology* 79: 1002-1011.

Sherman SM, Guillery RW (2006) Exploring the thalamus and its role in cortical function. second ed. MIT Press, Cambridge USA.

Sillito AM, Jones HE, Gerstein GL, West DC (1994) Feature-linked synchronisation of thalamic relay cell firing induced by feedback from the visual cortex. *Nature* 369: 479-482.

Spinks R, Magnotta VA, Andreasen NC, et al. (2002) Manual and automated measurement of the whole thalamus and mediodorsal nucleus using magnetic resonance imaging. *Neuroimage* 17: 631-642.

Steriade M, Deschenes M (1984) The thalamus as a neuronal oscillator. *Brain Research Reviews* 8: 1-63.

Styner M, Oguz I, Xu S, Brechbühler C, et al. (2006) Framework for the Statistical Shape Analysis of Brain Structures using SPHARM-PDM. *Insight Journal* 1071: 242-250.

Summerfield C, Junqué C, Tolosa E, et al. (2005) Structural brain changes in Parkinson disease with dementia voxel-based morphometry study. *Archives of Neurology* 62: 281-285.

Tekin S, Cummings JL, (2002) Frontal-subcortical neuronal circuits and clinical neuropsychiatry: an update. *Journal of Psychosomatic Research*. 53: 647-654.

Uylings HB, Amunts K, Mohlberg H, Pool CW, Zilles K, Smeets WJ (2008) 3D Probabilistic map of cytoarchitectonically defined human thalamic nuclei in standard MRI. *Frontiers in Neuroinformatics* 01/2008; DOI:10.3389/conf.neuro.11.2008.01.057.

van der Werf YD, Tisser DJ, Visser PJ, et al. (2001) Thalamic volume predicts performance on tests of cognitive speed and decreases in healthy aging. A magnetic resonance imaging-based volumetric analysis. *Cognitive Brain Research* 11: 377-385.

Vercellino M, Masera S, Lorenzatti M, et al. (2009) Demyelination, inflammation, and neurodegeneration in multiple sclerosis deep gray matter. *Journal of Neuropathology and Experimental Neurology* 68: 489-502.

Volkman J, Daniels C, Witt K (2010) Neuropsychiatric effects of subthalamic neurostimulation in Parkinson disease. *Nature Reviews Neurology* 6: 487-498.

Warren JD, Rohrer JD, Schott JM, Fox NC, Hardy J, Rosser MN (2013) Molecular nexopathies: a new paradigm of neurodegenerative disease. *Trends in Neuroscience* 36: 561-569.

Watson R, Blamire AM, O'Brien JT (2009) Magnetic resonance imaging in Lewy Body dementias. *Dementia and Geriatric Cognitive Disorders* 28: 493-506.

Walker LC, LeVine H (2012) Corruption and spread of pathogenic proteins in neurodegenerative disease. *Journal of Biological Chemistry* 287: 33109-33115.

Whitwell JL, Avula R, Master A et al. (2011) Disrupted thalamocortical connectivity in PSP: a resting state fMRI, DTI, VBM study. *Parkinsonism and Related Disorders* 17: 599-605.

Whitwell JL, Xu J, Mandrekar JN, Gunter JL, Jack CR, Josephs KA (2012) Rates of brain atrophy and clinical decline over 6 and 12-month intervals in PSP: determining sample size for treatment trials. *Parkinsonism and Related Disorders* 18: 252-256.

Xuereb JH, Perry RH, Candy JM, Marshall E, Bonham JR (1991) Nerve cell loss in the thalamus in Alzheimer's disease and Parkinson's disease. *Brain* 114: 1363-1379.

Zarei M., Patenaude B, Damoiseaux J, et al. (2010) Combining shape and connectivity analysis: an MRI study of thalamic degeneration in Alzheimer's disease. *Neuroimage* 49: 1-8.

Zhou J, Gennatas ED, Kramer JH, Miller BL, Seeley WW (2012) Predicting regional neurodegeneration from the healthy brain functional connectome. *Neuron* 73: 1216-1227.

Zwergal A, La Fougere C, Lorenzl S et al. (2011) Postural imbalance and falls in PSP correlate with functional pathology of the thalamus. *Neurology* 77: 101-109.

## LIST OF FIGURES AND TABLES

### Figure 1. Figure showing sections through the thalamus.

(A) and (B) are MRI T1 weighted images of the same section of human thalamus (traced in red), with intensity settings inverted (using ANALYZE 11.0 software); images provided by the authors.

(C) is a Nissl stained coronal section through Macaca Mulatta thalamus; abbreviations of relevant thalamic structures labelled: 3V=third ventricle; CL=central lateral nucleus; CM=centre median nucleus; LD=lateral dorsal nucleus; LP=lateral posterior nucleus; MD=medial dorsal nucleus; Pa=paratenial nucleus; Pf=parafascicular nucleus; R=reticular thalamic nucleus; VM=ventral medial nucleus; VPL=ventral posterolateral nucleus; VPM=ventral posteromedial nucleus. The image in (C) is adapted and sourced from BrainMaps.org, available via open access from <http://brainmaps.org/ajax-viewer.jpg>; (where additional abbreviations can be found), with license: <http://creativecommons.org/licenses/by/3.0>.

### Figure 2. Schematic diagram of the thalamus (right) showing subdivisions and nuclei

From Wikimedia Commons, reproduced via open access (Creative Commons); image available at [http://commons.wikimedia.org/wiki/User:Rocket000/SVGs/Biology/Human\\_anatomy](http://commons.wikimedia.org/wiki/User:Rocket000/SVGs/Biology/Human_anatomy). License: <http://creativecommons.org/licenses/by-sa/3.0/legalcode>.



### **Figure 3. Schematic diagram showing first order and higher order relays**

A first order thalamic relay represents the first relay of peripheral or subcortical information of a particular type to a first order or primary cortical area. A higher order relay relays information from layer 5 of one cortical area to another cortical area; this can be between first order and higher order cortical area or between two higher order cortical areas. The difference is the driver input, which is subcortical for a first order relay and from layer 5 of cortex for a higher order relay. Abbreviations: FO=first order; HO=higher order; LGN=lateral geniculate nucleus; MGNd and MGNv=dorsal and ventral portions of the medial geniculate nucleus; PO=posterior nucleus; Pul=pulvinar; TRN=thalamic reticular nucleus; VP=ventral posterior nucleus.

From Sherman (2006), reprinted through open access from Scholarpedia: Thalamus, 1(9):1583 (<http://www.scholarpedia.org/article/Thalamus>). Link to the license: <http://creativecommons.org/licenses/by-nc-sa/3.0/legalcode>.

### **Figure 4. Maps in the thalamus.**

Schematic representation of the trigemino-thalamo-cortical pathways. The arrowheads indicate the termination areas of the axons. Note that (in the cerebral cortex) the postsynaptic cells may have their somata in other layers. The line thickness indicates the relative importance of the pathways. The barreloids in VPM are indicated in an oblique

coronal slice, the barrelettes of the trigeminal nuclei in coronal slices. D = dorsal; L=lateral; LD=laterodorsal nucleus of the thalamus; Pom=medial posterior nucleus of the thalamus; PrV=primary trigeminal nucleus; R=rostral; SpVic=caudal part of spinal trigeminal nucleus pars interpolaris; SpVio=oral part of SpVi; SpVo=spinal trigeminal nucleus pars oralis; VPMdm=dorsomedial part of the ventroposterior medial nucleus of the thalamus; VPMh="head" area of VPM; VPMvl=ventrolateral part of VPM; wM1=whisker motor cortex; wS1=whisker part of primary sensorimotor cortex; wS2=whisker part of secondary sensorimotor cortex.

From Bosman and colleagues (2011), reproduced from *Frontiers* via open access; figure available from <http://journal.frontiersin.org/Journal/10.3389/fnint.2011.00053/full>.

### **Figure 5. Fronto-subcortical loops involving the thalamus**

Schematic diagram illustrating the organisation of the fronto-subcortical loops within human brain. (a) Motor loops; (b) Associative loops; and (c) Limbic loops. Abbreviations: GPi=globus pallidus internal; GPe=globus pallidus external; STN=subthalamic nucleus.

From Volkman and colleagues (2010), reprinted with permission from Nature Publishing Group: Neuropsychiatric effects of subthalamic neurostimulation in Parkinson disease. *Nature Reviews Neurology* 6, 487-498.

### **Figure 6. Cerebellothalamocortical circuits**

A) Lateral view of the rhesus monkey brain with hemispheres separated to expose mesial wall on top. Arrows schematically represent cerebello-cortical pathways relayed via cerebellar territories in lateral (left, violet) and central thalamus(right, green). (B) Two representative sections of the thalamus of *Macaca mulatta*, viewed from a lateral anterior perspective. Cerebellar domains in lateral and central thalamus are presented in violet and green, respectively. (C) Same sections as (B), but illustrating effector-related *functional*, as opposed to *hodological*, compartments. Hatching shows the rough somatotopic locations of regions related to arm (vertical)and eye (diagonal) movements. Abbreviations: DN=dentate nucleus; MIP=medial intraparietal area; LIP=lateral intraparietal area; M1=primary motor cortex; PMd=dorsal premotor cortex; PMv=ventral premotor cortex; FEF=frontal eye fields; PFC=prefrontal cortex; SMA=supplementary motor area; pre-SMA= pre-supplementary motor area; VLo=ventrolateral nucleus pars oralis;VPLO= ventroposterolateral nucleus pars oralis; MD=mediodorsal nucleus; VLc=ventrolateral nucleus pars caudalis; X= nucleus X of the thalamus.

From Prevosto and Summer (2013), reprinted via open access from Frontiers: Cognitive control of movement via the cerebellar-recipient thalamus. Frontiers in Systems Neuroscience 7, 56.

### **Figure 7. Conceptualization of neurodegenerative disorders on a neural circuit basis**

A. Intracellular protein aggregates can be released from neurons by exocytosis or cell death. The aggregates are taken up by, for example, adjacent neuronal cell bodies and are either retained in the cell soma (local spread of pathology) or transported anterogradely by axons.

Alternatively, they are taken up by axon terminals and transported retrogradely to the cell soma. The protein aggregates can spread between brain regions by axonal transport. B-D. Three drawings propose principles for how neuropathological changes in Parkinson's, Alzheimer's and Huntington's diseases spread spatiotemporally during disease progression. The earlier the neuropathology develops in a given brain region, the darker the shading in the diagram. As only one view (mid-sagittal for Parkinson's and Alzheimer's diseases; lateral for Huntington's disease) of the brain is depicted for each disorder, not all relevant anatomical structures and details of the spreading patterns (indicated by arrows) are presented.

From Brundin and colleagues (2010), reproduced with permission from Nature Publishing Group: Prion-like transmission of protein aggregates in neurodegenerative disease. *Nature Reviews Molecular Cell Biology* 11, 301-307 (Figure 3).

### **Table 1 Classification, connections and functions of the dorsal thalamic nuclei**

Adapted from: Power and Looi (2015).

## Abbreviations

AD: Alzheimer's dementia

AN: anterior nucleus of the thalamus

CAMCOG-R: Cambridge Cognitive Assessment - Revised

CBS: corticobasal syndrome

CJD: Creutzfeldt-Jakob disease

CL: central lateral nucleus of the thalamus

CM: centre median nucleus of the thalamus

DLB: Dementia with Lewy bodies

DTI: diffusion tensor imaging

DWI: Diffusion-weighted imaging

eml: external medullary lamina

EPSP: excitatory postsynaptic potentials

FO: first order thalamic nuclei

FGF: fibroblast growth factor

fMRI: functional magnetic resonance imaging

FLAIR: fluid attenuation inversion recovery

FTD: frontotemporal dementia

GABA:  $\gamma$ -aminobutyric acid

HD: Huntington's disease

HO: higher order thalamic nuclei

IML: internal medullary lamina

IL: intralaminar nuclei of the thalamus

LD: lateral dorsal nucleus of the thalamus

LGN: lateral geniculate complex of the thalamus

MD: medial dorsal nucleus of the thalamus

MGN: medial geniculate nucleus of the thalamus

ML: midline nuclei of the thalamus

MMSE: mini mental state examination

MS: multiple sclerosis

MRI: magnetic resonance imaging

NGN1: Neurogenin1

PD: Parkinson's disease

PET: positron emission tomography

Pf: parafascicular thalamic nucleus

PNFA: progressive nonfluent aphasia

PSP: progressive supranuclear palsy

Pt: paratenial thalamic nucleus

Re: reunions thalamic nucleus

RTN: thalamic reticular nucleus

SHH: Sonic hedgehog

SPECT: single photon emission computed tomography

SPHARM-PDM: spherical harmonic point distribution method

STN: subthalamic nucleus

VA: ventral anterior nucleus of the thalamus

VL: ventral lateral nucleus of the thalamus

VP: ventral posterior nucleus of the thalamus

VPL: ventral posterolateral nucleus of the thalamus

VPM: ventral posteromedial nucleus of the thalamus

ZI: the zona incerta

## LIST OF FIGURES AND TABLES

### Figure 1. Figure showing sections through the thalamus.

(A) and (B) are MRI T1 weighted images of the same section of human thalamus (traced in red), with intensity settings inverted (using ANALYZE 11.0 software); images provided by the authors.

(C) is a Nissl stained coronal section through Macaca Mulatta thalamus; abbreviations of relevant thalamic structures labelled: 3V=third ventricle; CL=central lateral nucleus; CM=centre median nucleus; LD=lateral dorsal nucleus; LP=lateral posterior nucleus; MD=medial dorsal nucleus; Pa=paratenial nuclues; Pf=parafasciular nucleus; R=reticular thalamic nucleus; VM=ventral medial nucleus; VPL=ventral posterolateral nucleus; VPM=ventral posteromedial nucleus. The image in (C) is adapted and sourced from BrainMaps.org, available via open access from <http://brainmaps.org/ajax-viewer.jpg>; (where additional abbreviations can be found), with license: <http://creativecommons.org/licenses/by/3.0>.

### Figure 2. Schematic diagram of the thalamus (right) showing subdivisions and nuclei

From Wikimedia Commons, reproduced via open access (Creative Commons); image available at [http://commons.wikimedia.org/wiki/User:Rocket000/SVGs/Biology/Human\\_anatomy](http://commons.wikimedia.org/wiki/User:Rocket000/SVGs/Biology/Human_anatomy). License: <http://creativecommons.org/licenses/by-sa/3.0/legalcode>.

### Figure 3. Schematic diagram showing first order and higher order relays

A first order thalamic relay represents the first relay of peripheral or subcortical information of a particular type to a first order or primary cortical area. A higher order relay relays information from layer 5 of one cortical area to another cortical area; this can be between first order and higher order cortical area or between two higher order cortical areas. The difference is the driver input, which is subcortical for a first order relay and from layer 5 of cortex for a higher order relay. Abbreviations: FO=first order; HO=higher order; LGN=lateral geniculate nucleus; MGNd and MGNv=dorsal and ventral portions of the medial geniculate nucleus; PO=posterior nucleus; Pul=pulvinar; TRN=thalamic reticular nucleus; VP=ventral posterior nucleus.

From Sherman (2006), reprinted through open access from Scholarpedia: Thalamus, 1(9):1583 (<http://www.scholarpedia.org/article/Thalamus>). Link to the license: <http://creativecommons.org/licenses/by-nc-sa/3.0/legalcode>.

### Figure 4. Maps in the thalamus

Schematic representation of the trigemino-thalamo-cortical pathways. The arrowheads indicate the termination areas of the axons. Note that (in the cerebral cortex) the postsynaptic cells may have their somata in other layers. The line thickness indicates the relative importance of the pathways. The barreloids in VPM are indicated in an oblique coronal slice, the barrelettes of the trigeminal nuclei in coronal slices. D = dorsal; L=lateral; LD=laterodorsal nucleus of the thalamus; Pom=medial posterior nucleus of the thalamus; PrV=primary trigeminal nucleus; R=rostral; SpVic=caudal part of spinal trigeminal nucleus pars interpolaris; SpVio=oral part of SpVi; SpVo=spinal trigeminal nucleus pars oralis; VPMdm=dorsomedial part of the ventroposterior medial nucleus of the thalamus; VPMh="head" area of VPM; VPMvl=ventrolateral part of VPM; wM1=whisker motor cortex; wS1=whisker part of primary sensorimotor cortex; wS2=whisker part of secondary sensorimotor cortex.

From Bosman and colleagues (2011), reproduced from Frontiers via open access; figure available from <http://journal.frontiersin.org/Journal/10.3389/fnint.2011.00053/full>.

### Figure 5. Fronto-subcortical loops involving the thalamus

Schematic diagram illustrating the organisation of the fronto-subcortical loops within human brain. (a) Motor loops; (b) Associative loops; and (c) Limbic loops. Abbreviations: GPi=globus pallidus internal; GPe=globus pallidus external; STN=subthalamic nucleus.

From Volkman and colleagues (2010), reprinted with permission from Nature Publishing Group: Neuropsychiatric effects of subthalamic neurostimulation in Parkinson disease. *Nature Reviews Neurology* 6, 487-498.

### Figure 6. Cerebellothalamocortical circuits

A) Lateral view of the rhesus monkey brain with hemispheres separated to expose mesial wall on top. Arrows schematically represent cerebello-cortical pathways relayed via cerebellar territories in lateral (left, violet) and central thalamus(right, green). (B) Two representative sections of the thalamus of *Macaca mulatta*, viewed from a lateral anterior perspective. Cerebellar domains in lateral and central thalamus are presented in violet and green, respectively. (C) Same sections as (B), but illustrating effector-related *functional*, as opposed to *hodological*, compartments. Hatching shows the rough somatotopic locations of regions related to arm (vertical)and eye (diagonal) movements. Abbreviations: DN=dentate nucleus; MIP=medial intraparietal area; LIP=lateral intraparietal area; M1=primary motor cortex; PMd=dorsal premotor cortex; PMv=ventral premotor cortex; FEF=frontal eye fields; PFC=prefrontal cortex; SMA=supplementary motor area; pre-SMA= pre-supplementary motor area; VLo=ventrolateral nucleus pars oralis;VPLo= ventroposterolateral nucleus pars oralis; MD=mediodorsal nucleus; VLc=ventrolateral nucleus pars caudalis; X= nucleus X of the thalamus.

From Prevosto and Summer (2013), reprinted via open access from Frontiers: Cognitive control of movement via the cerebellar-recipient thalamus. *Frontiers in Systems Neuroscience* 7, 56.

### Figure 7. Conceptualization of neurodegenerative disorders on a neural circuit basis

A. Intracellular protein aggregates can be released from neurons by exocytosis or cell death. The aggregates are taken up by, for example, adjacent neuronal cell bodies and are either retained in the cell soma (local spread of pathology) or transported anterogradely by axons. Alternatively, they are taken up by axon terminals and transported retrogradely to the cell soma. The protein aggregates can spread between brain regions by axonal transport. B-D. Three drawings propose principles for how neuropathological changes in Parkinson's, Alzheimer's and Huntington's diseases spread spatiotemporally during disease progression. The earlier the neuropathology develops in a given brain region, the darker the shading in the diagram. As only one view (mid-sagittal for Parkinson's and Alzheimer's diseases; lateral for Huntington's disease) of the brain is depicted for each disorder, not all relevant anatomical structures and details of the spreading patterns (indicated by arrows) are presented.

From Brundin and colleagues (2010), reproduced with permission from Nature Publishing Group: Prion-like transmission of protein aggregates in neurodegenerative disease. *Nature Reviews Molecular Cell Biology* 11, 301-307 (Figure 3).

### Table 1 Classification, connections and functions of the dorsal thalamic nuclei



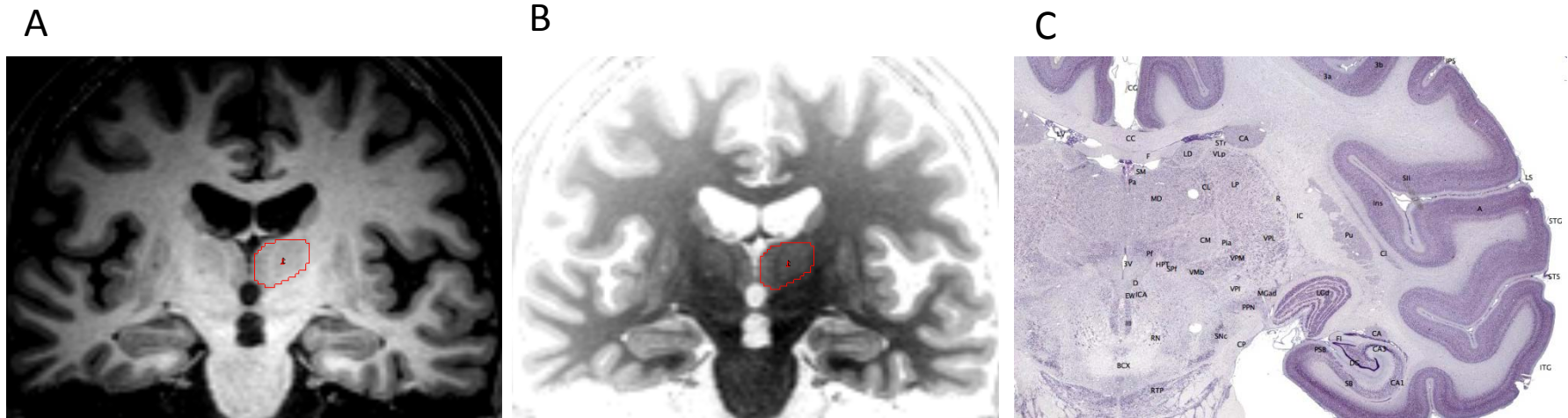
Adapted from: Jones, E.G., 2007. *The Thalamus*, 2<sup>nd</sup> edition. Cambridge: Cambridge University Press (Table 3.1); Kandel, E.R., Schwartz, J.H., Jessell, T.M., 1991. *Principles of Neural Science*. 3<sup>rd</sup> ed., Prentice Hall, Sydney (Table 20-1); and Power and Looi (2014).

**Table 1. Classification, connections and functions of the dorsal thalamic nuclei (first order and higher order)**

Classification	Nuclei	Afferents	Efferents	Proposed functional domain
<b>First order</b>	AN	subiculum and presubiculum, mammillary nuclei	anterior limbic cortex, cingulate, subiculum, retrosplenial and presubiculum	limbic
	LGN	retinal ganglion cells	visual cortex	vision
	MGN	inferior colliculus	auditory cortex of temporal lobe	hearing
	VA	substantia nigra	diffuse prefrontal and cingulate	motor
	VL	globus pallidus, deep cerebellar nuclei, vestibular nuclei, anterolateral tract	motor and premotor cortices	motor
	VM	substantia nigra, taste, vagal, spinal	diffuse, frontal, cingulate, primary somatosensory and gustatory, medial frontal cortices	integration of visceromotor information
	VP	medial and trigeminal lemnisci, spinothalamic tract	primary and secondary somatosensory cortex	somatic sensation of body and face
<b>Higher order</b>	LP	parietal lobe, superior colliculus and pretectum	parietal lobe (area 5)	integration of sensory information
	LD	cingulate gyrus, fornix, pretectum, hypothalamus	cingulate gyrus, retrosplenial cortex	emotional expression
	MD	amygdaloid nuclear complex, olfactory cortex, hypothalamus, spinal, superior colliculus	prefrontal cortex, including frontal eye field, orbitofrontal and lateral frontal, and basal olfactory structures	limbic
	pulvinar	superior colliculus and pretectum, temporal, parietal and occipital lobes	temporal, parietal, occipital lobes (area 5, superior temporal gyrus) and prestriate cortex	integration of sensory information

Adapted from: Power et al., 2015 (Table 1).

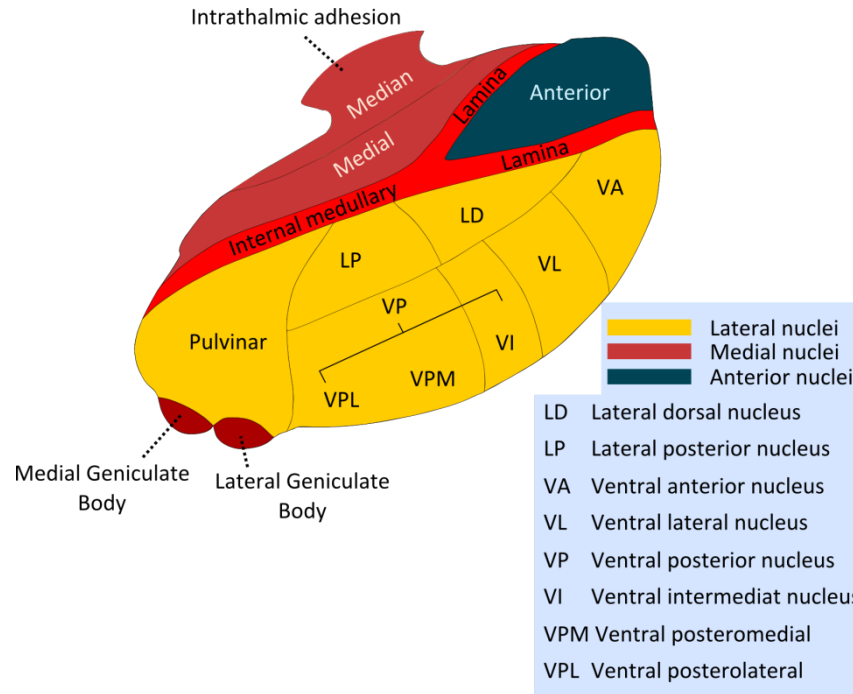
**Figure 1. Figure showing sections through the thalamus**



(A) and (B) are MRI T1 weighted images of the same section of human thalamus (traced in red), with intensity settings inverted (using ANALYZE 11.0 software); images provided by the authors.

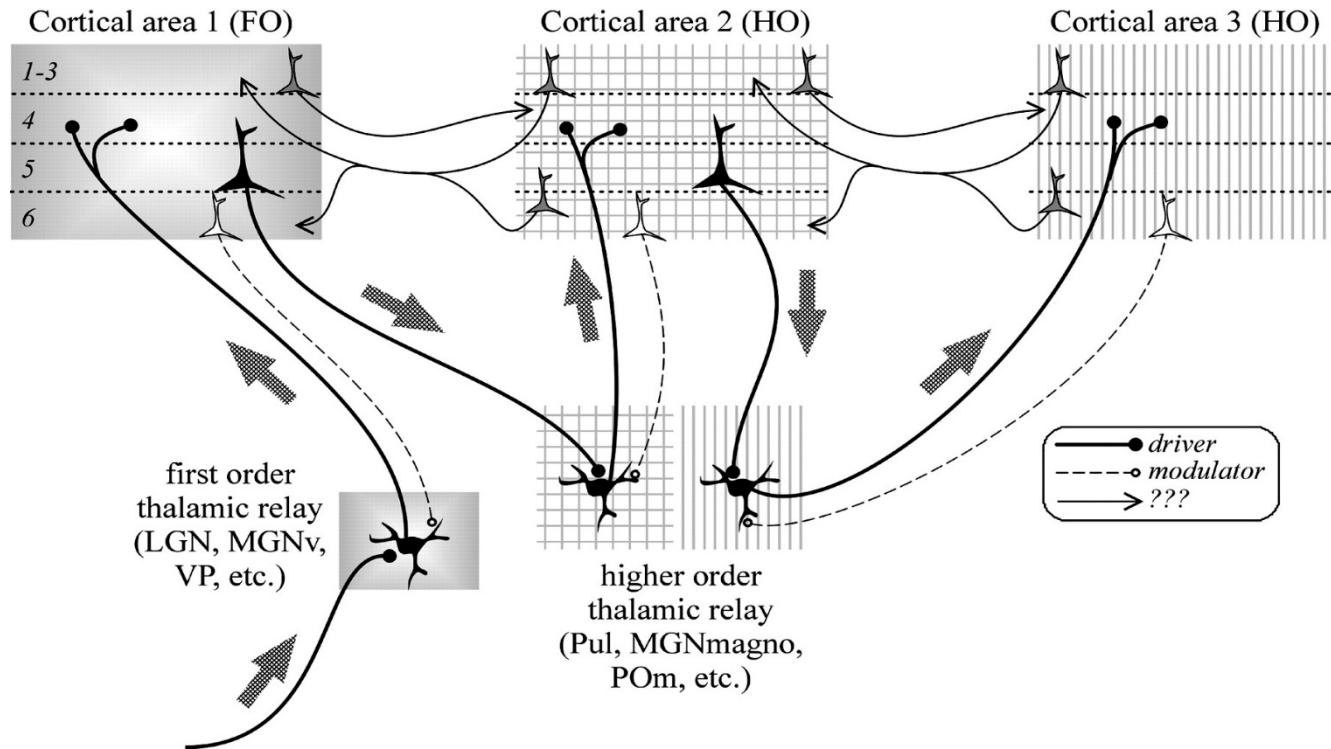
(C) is a Nissl stained coronal section through Macaca Mulatta thalamus; abbreviations of relevant thalamic structures labelled: 3V=third ventricle; CL=central lateral nucleus; CM=centre median nucleus; LD=lateral dorsal nucleus; LP=lateral posterior nucleus; MD=medial dorsal nucleus; Pa=paratenial nuclues; Pf=parafascicular nucleus; R=reticular thalamic nucleus; VM=ventral medial nucleus; VPL=ventral posterolateral nucleus; VPM=ventral posteromedial nucleus. The image in (C) is adapted and sourced from BrainMaps.org, available via open access from <http://brainmaps.org/ajax-viewer.jpg>; (where additional abbreviations can be found), with license: <http://creativecommons.org/licenses/by/3.0>.

**Figure 2. Schematic diagram of the thalamus (right) showing subdivisions and nuclei**



From Wikimedia Commons, reproduced via open access (Creative Commons); image available at [http://commons.wikimedia.org/wiki/User:Rocket000/SVGs/Biology/Human\\_anatomy](http://commons.wikimedia.org/wiki/User:Rocket000/SVGs/Biology/Human_anatomy). License: <http://creativecommons.org/licenses/by-sa/3.0/legalcode>.

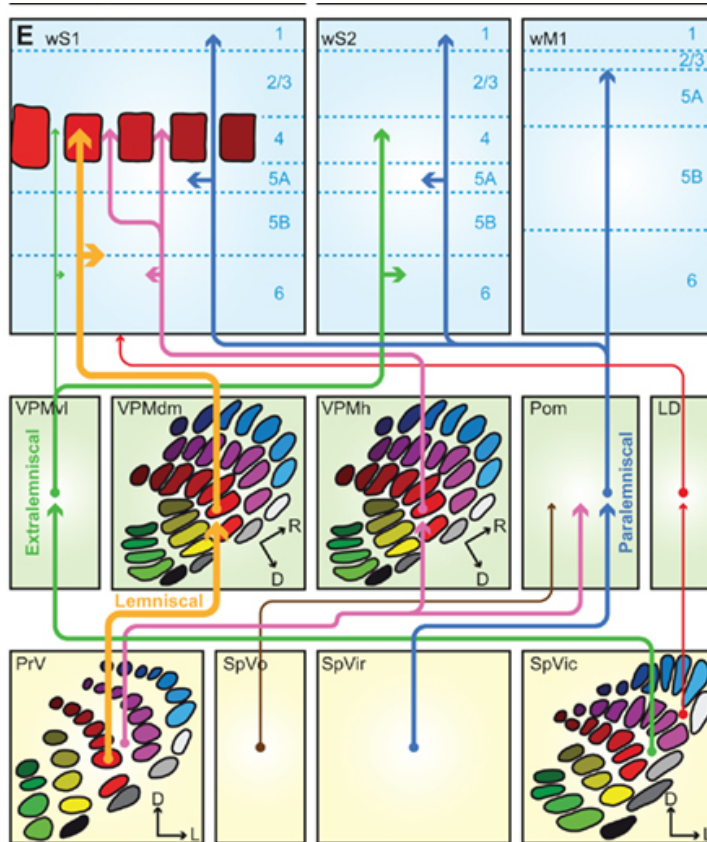
**Figure 3. Schematic diagram showing first order and higher order relays**



A first order thalamic relay represents the first relay of peripheral or subcortical information of a particular type to a first order or primary cortical area. A higher order relay relays information from layer 5 of one cortical area to another cortical area; this can be between first order and higher order cortical area or between two higher order cortical areas. The difference is the driver input, which is subcortical for a first order relay and from layer 5 of cortex for a higher order relay. Abbreviations: FO=first order; HO=higher order; LGN=lateral geniculate nucleus; MGNd and MGNv=dorsal and ventral portions of the medial geniculate nucleus; PO=posterior nucleus; Pul=pulvinar; TRN=thalamic reticular nucleus; VP=ventral posterior nucleus.

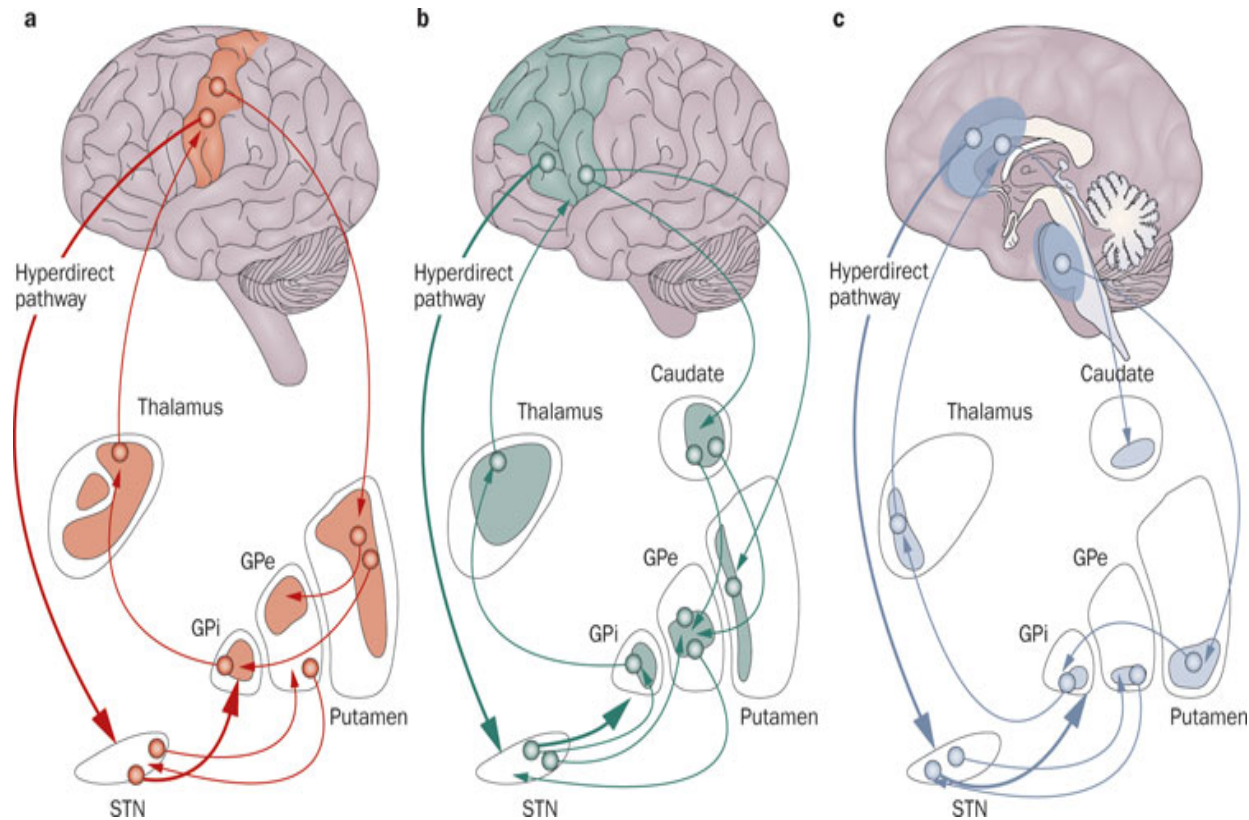
From Sherman (2006), reprinted through open access from Scholarpedia: Thalamus, 1(9):1583 (<http://www.scholarpedia.org/article/Thalamus>). Link to the license: <http://creativecommons.org/licenses/by-nc-sa/3.0/legalcode>.

## Figure 4. Maps in the thalamus



Schematic representation of the trigemino-thalamo-cortical pathways. The arrowheads indicate the termination areas of the axons. Note that (in the cerebral cortex) the postsynaptic cells may have their somata in other layers. The line thickness indicates the relative importance of the pathways. The barreloids in VPM are indicated in an oblique coronal slice, the barrelettes of the trigeminal nuclei in coronal slices. D = dorsal; L=lateral; LD=laterodorsal nucleus of the thalamus; Pom=medial posterior nucleus of the thalamus; PrV=primary trigeminal nucleus; R=rostral; SpVic=caudal part of spinal trigeminal nucleus pars interpolaris; SpVio=oral part of SpVi; SpVo=spinal trigeminal nucleus pars oralis; VPMdm=dorsomedial part of the ventroposterior medial nucleus of the thalamus; VPMh="head" area of VPM; VPMvl=ventrolateral part of VPM; wM1=whisker motor cortex; wS1=whisker part of primary sensorimotor cortex; wS2=whisker part of secondary sensorimotor cortex. From Bosman and colleagues (2011), reproduced from Frontiers via open access; figure available from <http://journal.frontiersin.org/Journal/10.3389/fnint.2011.00053/full>.

## Figure 5. Fronto-subcortical loops involving the thalamus

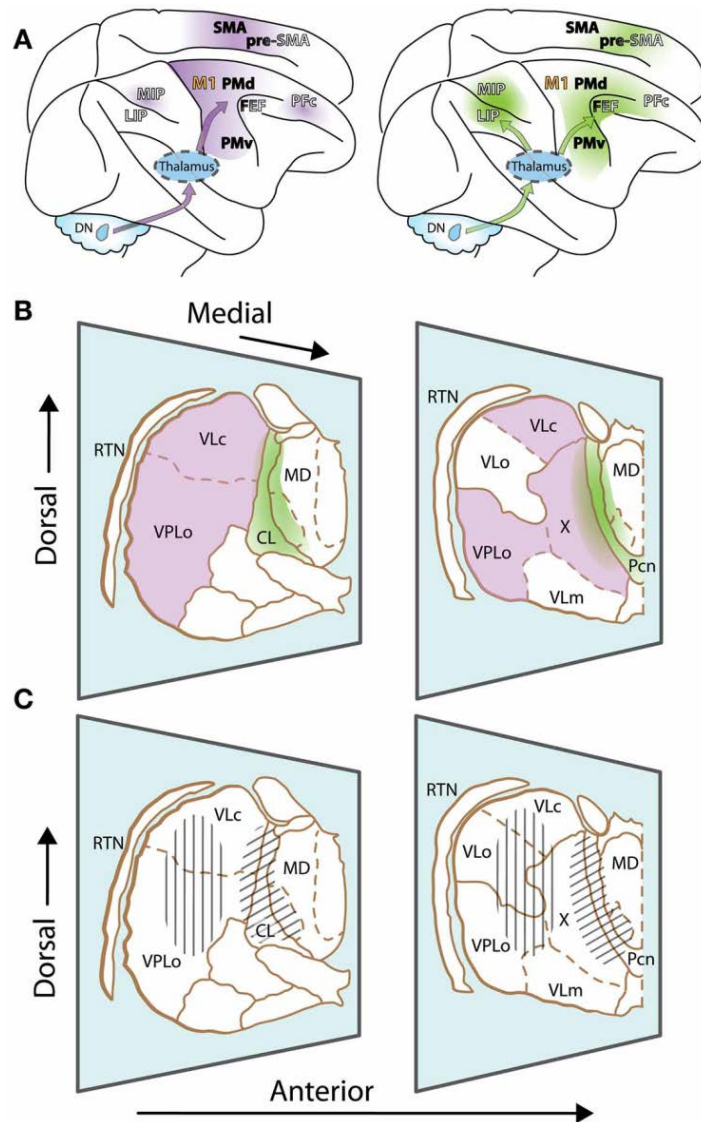


Schematic diagrams illustrating the organisation of the fronto-subcortical loops within human brain. (a) Motor loops; (b) Associative loops; and (c) Limbic loops. Abbreviations: GPi=globus pallidus internal; GPe=globus pallidus external; STN=subthalamic nucleus.

From Volkman and colleagues (2010), reprinted with permission from Nature Publishing Group: Neuropsychiatric effects of subthalamic neurostimulation in Parkinson disease. *Nature Reviews Neurology* 6, 487-498.



## Figure 6. Cerebellothalamocortical circuits

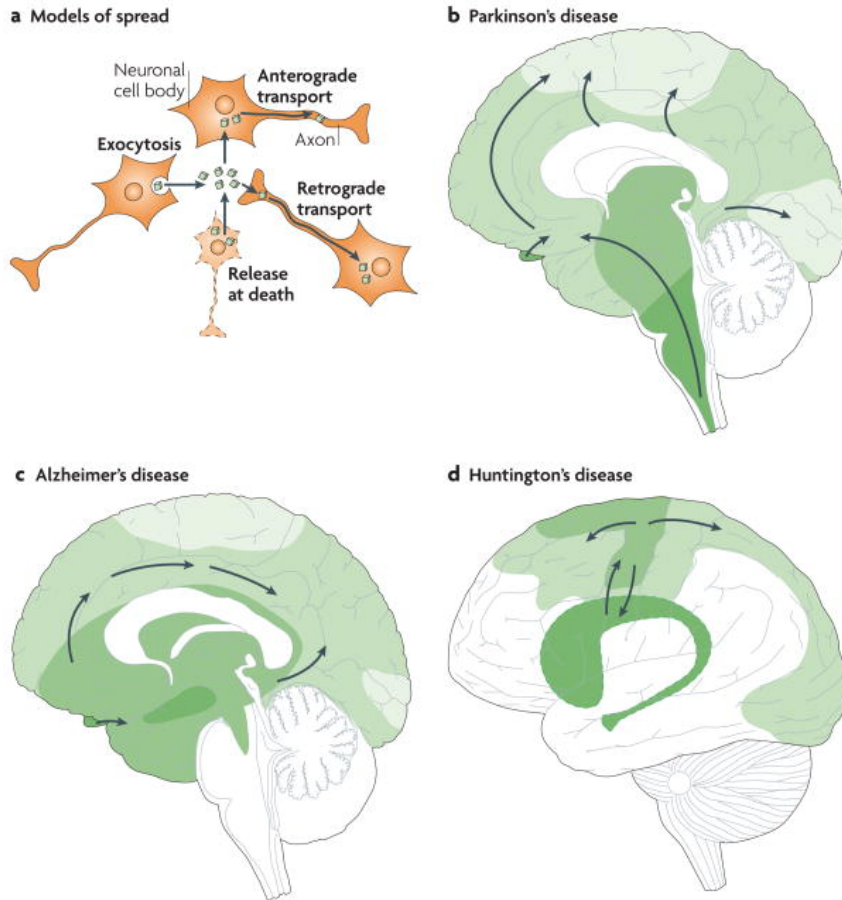


A) Lateral view of the rhesus monkey brain with hemispheres separated to expose mesial wall on top. Arrows schematically represent cerebello-cortical pathways relayed via cerebellar territories in lateral (left, violet) and central thalamus (right, green). (B) Two representative sections of the thalamus of *Macaca mulatta*, viewed from a lateral anterior perspective. Cerebellar domains in lateral and central thalamus are presented in violet and green, respectively. (C) Same sections as (B), but illustrating effector-related *functional*, as opposed to *hodological*, compartments. Hatching shows the rough somatotopic locations of regions related to arm (vertical) and eye (diagonal) movements. Abbreviations: DN=dentate nucleus; MIP=medial intraparietal area; LIP=lateral intraparietal area; M1=primary motor cortex; PMd=dorsal premotor cortex; PMv=ventral premotor cortex; FEF=frontal eye fields; PFC=prefrontal cortex; SMA=supplementary motor area; pre-SMA=pre-supplementary motor area; VLo=ventrolateral nucleus pars oralis; VPLo=ventroposterolateral nucleus pars oralis; MD=mediodorsal nucleus; VLc=ventrolateral nucleus pars caudalis; X=nucleus X of the thalamus.

From Prevosto and Summer (2013), reprinted via open access from Frontiers: Cognitive control of movement via the cerebellar-recipient thalamus. Frontiers in Systems Neuroscience 7, 56.



# Figure 7. Conceptualization of neurodegenerative disorders on a neural circuit basis



a). Intracellular protein aggregates can be released from neurons by exocytosis or cell death. The aggregates are taken up by, for example, adjacent neuronal cell bodies and are either retained in the cell soma (local spread of pathology) or transported anterogradely by axons. Alternatively, they are taken up by axon terminals and transported retrogradely to the cell soma. The protein aggregates can spread between brain regions by axonal transport. (b-d). Three drawings propose principles for how neuropathological changes in Parkinson's, Alzheimer's and Huntington's diseases spread spatiotemporally during disease progression. The earlier the neuropathology develops in a given brain region, the darker the shading in the diagram. As only one view (mid-sagittal for Parkinson's and Alzheimer's diseases; lateral for Huntington's disease) of the brain is depicted for each disorder, not all relevant anatomical structures and details of the spreading patterns (indicated by arrows) are presented.

From Brundin and colleagues (2010), reproduced with permission from Nature Publishing Group: Prion-like transmission of protein aggregates in neurodegenerative disease. *Nature Reviews Molecular Cell Biology* 11, 301-307 (Figure 3).