

The logo for ResearchOnline@ND, featuring the text "ResearchOnline@ND" in white on a dark blue rectangular background.

University of Notre Dame Australia  
ResearchOnline@ND

---

Medical Papers and Journal Articles

School of Medicine

---

2015

## Meningitis or septicaemia in a backpacker?

Sascha Fulde

Gordian Fulde

University of Notre Dame Australia, [Gordian.Fulde@nd.edu.au](mailto:Gordian.Fulde@nd.edu.au)

Follow this and additional works at: [http://researchonline.nd.edu.au/med\\_article](http://researchonline.nd.edu.au/med_article)



Part of the [Medicine and Health Sciences Commons](#)

This article was originally published as:

Fulde, S., & Fulde, G. (2015). Meningitis or septicaemia in a backpacker?. *Medicine Today*, 16 (3), 61-63.

Original article available here:

<http://medicinetoday.com.au/2015/march/regular-series/meningitis-or-septicaemia-backpacker>

---

This article is posted on ResearchOnline@ND at

[http://researchonline.nd.edu.au/med\\_article/711](http://researchonline.nd.edu.au/med_article/711). For more information,  
please contact [researchonline@nd.edu.au](mailto:researchonline@nd.edu.au).



This article originally published: -

Fulde, Sascha and Fulde, Gordian. (2015) Meningitis or septicaemia in a backpacker?  
*Medicine Today, 16(3): 61-63.*

Permission granted by Medicine Today for use on ResearchOnline@ND.

© Medicine Today 2015 (<http://www.medicinetoday.com.au>).

# Meningitis or septicaemia in a backpacker?

SASCHA FULDE MB BS, BSc

GORDIAN FULDE MB BS, FRACS, FRCS(Ed), FRCS/FRCP(A&E)Ed, FACEM

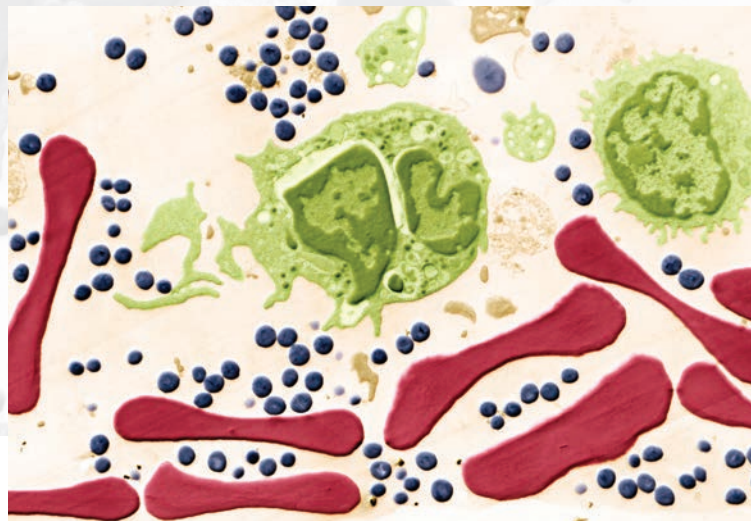
**Negative blood test results for meningitis but positive for *Staphylococcus aureus* in a young patient with suspected meningitis and a recent joint injury led to a diagnosis of staphylococcal septicaemia with septic arthritis as the source of the infection.**

**A**s a GP working in your own practice and in the emergency department of the local hospital, you probably see more cases of life-threatening shock than most GPs. It is commonly acknowledged that the virulence of organisms and their resistance to antibiotics are increasing, but when a young person is brought into the emergency department in life-threatening shock, it is very distressing and challenging.

## The case

At 3 a.m. one morning while you were on night-shift at the local emergency department, a 25-year-old patient, a Swedish backpacker who was travelling alone, was brought in by ambulance to with a diagnosis of meningitis and shock (Box 1). The ambulance officers gave a history of three days of intermittent fever preceding the development of head and shoulder pain, lethargy and mottled peripheries. They had also noted a nonblanching body rash, but no neck stiffness.

The woman's reported observations were a temperature of 38.5°C, oxygen saturation of 92% on room air, blood pressure 77/38 mmHg, heart rate of 143 beats per minute and Glasgow Coma Scale of 15 (fully awake). The ambulance officers had given her benzylpenicillin 1.2 g intravenously and 500 mL of intravenous



fluid. She had also been given oxygen at a rate of 8 L per minute. Her pain score was 5/10.

## A re-presentation

Routine review of previous presentations revealed that this patient had presented two days previously to the Emergency Department with a three-week history of left shoulder pain that had begun while she was working as a cleaner. There had been no particular incident; the pain was of gradual onset some 12 hours after she had been working. Her pain had gradually worsened and on presentation was graded as 9/10 on full movement. She was unable to use her arm. There were no neurovascular abnormalities and there was no previous history of shoulder injury or surgery.

Her observations at that previous presentation had shown her to be afebrile with a blood pressure of 105/60 mmHg and pulse rate of 104 beats per minute. She had been fully clerked by a

### 1. LEARNING POINTS: ACUTE BACTERIAL MENINGITIS IN ADULTS<sup>1,2</sup>

- Meningitis is among the 10 most common infectious disease causes of death.<sup>1</sup>
- Major causes of community-acquired bacterial meningitis are *Streptococcus pneumoniae* (Gram-positive diplococci) and *Neisseria meningitidis* (Gram-negative diplococci).<sup>1,2</sup>
- Clinical presentation is severe headache and the classic triad of fever, neck stiffness and altered mental status. All three of the classic features are present in only about 45% of cases of bacterial meningitis but virtually all patients have at least one of these features. Patients with meningitis caused by *N. meningitidis* may have a characteristic petechial rash and palpable purpura.<sup>1,2</sup>
- Prognosis: high risk (56%) of adverse outcome (mortality and morbidity). The mortality rate in adults increases with increasing age, and is over 20% in those age 65 years and older. About 10% of discharged patients have a neurological deficit.<sup>1</sup> Outcomes vary with the causative organism, with the mortality rate being higher among patients with pneumococcal meningitis than among those with meningococcal meningitis.<sup>2</sup>

MedicineToday 2015; 16(3): 61-63

Dr Sascha Fulde is a Registrar in Emergency Medicine at St Vincent's Hospital, Sydney. Professor Gordian Fulde is Director of Emergency Medicine at St Vincent's Hospital, Sydney; Professor in Emergency Medicine at the University of Notre Dame, Sydney; and Associate Professor in Emergency Medicine at The University of New South Wales, Sydney, NSW.

## 2. LEARNING POINTS: STAPHYLOCOCCAL TOXIC SHOCK SYNDROME AND SEPTICAEMIA<sup>3</sup>

- Many strains of *Staphylococcus aureus* produce exotoxins that lead to three associated syndromes:
  - food poisoning, caused by ingestion of enterotoxin
  - scalded skin syndrome, caused by exfoliative toxin
  - toxic shock syndrome (TSS), caused by toxic shock syndrome toxin-1 and other enterotoxins.
- Centers for Disease Control and Prevention (CDC) clinical criteria for toxic shock syndrome include fever, malaise, headache, sore throat, myalgias, fatigue, vomiting, diarrhoea, abdominal pain and orthostatic dizziness or syncope.
  - Hypotension, skin manifestations and multiorgan involvement occur quickly.
  - Diagnosis (CDC): fever >38.9°C, hypotension, diffuse erythroderma, desquamation and involvement of at least three organ systems. A high suspicion is considered a probable case.
- Prognosis: mortality due to nonmenstrual TSS (approximately 6%) is higher than that due to menstrual (tampon-related) TSS.
- Human normal immunoglobulin can be effective in some cases of toxic shock syndrome, especially if the patient is immunocompromised. It is also used in cases not responding to therapy with fluids and vasopressors.

final-year medical student and reviewed by an emergency Medicine registrar, and also assessed by a physiotherapist. At that time, she had been diagnosed as having shoulder bursitis. Her arm had been put into a sling and she had been prescribed ibuprofen 400 mg three times daily.

### Investigations and treatment

At this emergency presentation, the patient was immediately taken to a resuscitation cubicle. Her observations were similar to those obtained by the ambulance officers (as noted above). She gave an additional history of photophobia for one day, vomiting three times, decreased oral intake, drowsiness and a sore throat for three days. She denied having symptoms of any other sources of infection (i.e. no dysuria, frequency or diarrhoea), and she was not aware

## 3. LEARNING POINTS: SEPTIC ARTHRITIS IN ADULTS<sup>4,5</sup>

Most cases of septic arthritis in adults have a predisposing factor. Predisposing factors include:

- age over 80 years
- diabetes mellitus
- rheumatoid joint
- prosthetic joint
- recent joint surgery
- skin infection, cutaneous ulcers
- intravenous drug abuse, alcoholism
- previous intra-articular corticosteroid injection

of having been in contact with any people who were sick. She had not used tampons. She had been in Australia for one month, and had a stopover in Asia on her way from Sweden.

In the emergency department, full precautions were taken with regards to a possibly infectious patient. Specialists in intensive care and in infectious diseases were involved in the patient's management from the outset. Fluid resuscitation was commenced immediately with 4 L of a crystalloid solution and 500 mL of a colloid solution being given over the next hour, but there was little, if any, improvement.

A nonblanching petechial rash was noted on examination, and there were also splinter haemorrhages in her fingernails bilaterally. Her beta human chorionic gonadotropin level was normal, indicating she was not pregnant, and her vaginal examination was normal. Among other blood tests, general blood cultures and a meningococcal polymerase chain reaction (PCR) test were organised. Blood gases showed a metabolic acidosis (pH of 7.28, base excess of -12 mmol/L and lactate of 6.3 mmol/L). Her sodium and potassium levels and haematology were unremarkable but she was seen to be in oliguric acute renal failure. Her chest X-ray demonstrated signs of acute respiratory distress syndrome and there was evidence of multiorgan failure.

Ceftriaxone, clindamycin, vancomycin and human normal immunoglobulin were commenced on the advice of the infectious diseases specialist.

The patient was intubated and central venous access was established. Dialysis was also organised. As her blood pressure remained low, she was commenced on vasopressors, beginning with metaraminol and then adding noradrenaline (both intravenously).

While these measures were being undertaken for the patient, the ambulance officers who had brought her to the hospital and three members of the hospital staff who had been in contact with her were counselled regarding the infectious nature of her problem. They were commenced on the broad-spectrum antibiotic ciprofloxacin as a precaution.

Further investigations were then undertaken. A transoesophageal echocardiograph demonstrated that there were no vegetations in the patient's heart. The meningococcal PCR was negative, as was also a malaria screen. These results meant that there was no obvious source of her infection.

The following day, however, blood cultures demonstrated *Staphylococcus aureus*. A diagnosis of staphylococcal septicaemia was made (Box 2). As the particular strain of *S. aureus* was found to be resistant to both penicillin and clindamycin, intravenous flucloxacillin was therefore commenced. At this stage, on day three after presentation, the patient was still suffering from multiorgan failure and shock.

Ultrasound examination of the left shoulder and left elbow were undertaken. This showed an effusion of the left shoulder with inflamed synovium, which was thought by the radiologist

to be amenable to aspiration. There was a lesser effusion of the left elbow.

Urgent orthopaedic consultation was followed by an ultrasound-guided aspiration of the shoulder joint that yielded 15 mL of pus. This septic arthritis was the likely source of the staphylococcal septicaemia. The patient's recent shoulder injury was probably a predisposing factor for the septic arthritis (Box 3). A formal operative aspiration and 3-L wash-out of both infected joints was subsequently performed. During the operation, the rotator cuff and cartilage were seen to be intact.

### Outcome

On day four post-admission, the rash resolved and the patient's condition began to improve. She continued to require a ventilator and dialysis and to be treated with intravenous flucloxacillin 12 g per day. On day five, the patient was able to be extubated, and after 17 days in hospital she was discharged.

She planned to return to Sweden the following week but on her return to the backpacker hostel where she had been staying she found that her backpack containing her personal possessions, including her travel documents, laptop and camera, had gone missing. A sad consequence of her sudden emergency trip to hospital and extended stay resulting from her life-threatening illness.

### Conclusion

The reported case of a young woman brought to the emergency department with suspected meningitis illustrates the importance

of obtaining an accurate history. Checking of hospital records in this case revealed that the patient had presented only a few days earlier and been diagnosed with shoulder bursitis. At that time, she had no signs of infection, and indeed infection is a rare cause of shoulder bursitis. Her re-presentation with signs of severe infection but no headache or neck stiffness, followed by a negative test result for meningitis but a positive result for *S. aureus* led to the diagnosis of septic arthritis in her left shoulder, which was the source of the septicaemia and the shock reaction. **MT**

### References

1. Tunkel AR. Clinical features and diagnosis of acute bacterial meningitis in adults. UpToDate 2015. Available online at: [http://www.uptodate.com/contents/clinical-features-and-diagnosis-of-acute-bacterial-meningitis-in-adults?source=see\\_link%20-%20H](http://www.uptodate.com/contents/clinical-features-and-diagnosis-of-acute-bacterial-meningitis-in-adults?source=see_link%20-%20H) (accessed March 2015).
2. Tunkel AR. Initial therapy and prognosis of bacterial meningitis in adults. UpToDate 2015. Available online at: <http://www.uptodate.com/contents/initial-therapy-and-prognosis-of-bacterial-meningitis-in-adults> (accessed March 2015).
3. Chu VH. Staphylococcal toxic shock syndrome. UpToDate. Available online at: <http://www.uptodate.com/contents/staphylococcal-toxic-shock-syndrome> (accessed March 2015).
4. Goldenberg DL, Sexton DJ. Septic arthritis in adults. UpToDate. Available online at: <http://www.uptodate.com/contents/septic-arthritis-in-adults> (accessed March 2015).
5. Margaretten ME, Kohlwes J, Morre D, Bent S. Does this adult patient have septic arthritis? JAMA 2007; 297: 1478-1488.

---

COMPETING INTERESTS: None.