



Contents lists available at ScienceDirect

Journal of Pediatric Surgery

journal homepage: www.sciencedirect.com/journal/journal-of-pediatric-surgery

A Population-Based Cohort Study on Diagnosis and Early Management of Anorectal Malformation in the UK and Ireland

Anna-May Long ^{a, b, 1}, Joseph R. Davidson ^{c, d, 1}, Athanasios Tyraskis ^e, Marian Knight ^b, Paolo De Coppi ^{c, d, *}, on behalf of BAPS-CASS

^a Department of Paediatric Surgery, Cambridge University Hospitals, United Kingdom

^b National Perinatal Epidemiology Unit, Nuffield Department of Population Health, University of Oxford, United Kingdom

^c Department of Stem Cells and Regenerative Medicine, UCL-GOS Institute of Child Health, London, United Kingdom

^d NIHR Biomedical Research Centre and Specialist Neonatal and Paediatric Surgery, Great Ormond Street Hospital for Children, London, United Kingdom

^e Institute of Liver Studies, King's College London, United Kingdom

ARTICLE INFO

Article history:

Received 1 August 2023

Received in revised form

7 March 2024

Accepted 12 March 2024

Keywords:

Anorectal malformation
Late diagnosis
National cohort study
BAPS CASS

ABSTRACT

Background: This study describes the presentation and initial management of anorectal malformation (ARM); evaluating the frequency, causes and consequences of late diagnosis.

Methods: A prospective, population cohort study was undertaken for newly diagnosed ARMs in the UK and Ireland from 01/10/2015 and 30/09/2016. Follow-up was completed at one year.

Data are presented as n (%), appropriate statistical methods used. Factors associated with late diagnosis; defined as: detection of ARM either following discharge or more than 72 h after birth were assessed with univariable logistic regression.

Results: Twenty six centres reported on 174 cases, 158 of which were classified according to the type of malformation and 154 had completed surgical data. Overall, perineal fistula was the most commonly detected anomaly 43/158 (27%); of the 41 of these children undergoing surgery, 15 (37%) had a stoma formed. 21/154 (14%, CI₉₅{9–20}) patients undergoing surgery experienced post-operative complications. Thirty-nine (22%) were diagnosed late and 12 (7%) were detected >30 days after birth. Factors associated with late diagnosis included female sex (OR 2.06; 1.0–4.26), having a visible perineal opening (OR 2.63; 1.21–5.67) and anomalies leading to visible meconium on the perineum (OR 18.74; 2.47–141.73). 56/174 (32%) had a diagnosis of VACTERL association (vertebral, anorectal, cardiac, tracheal, oesophageal, renal and limb); however, not all infants were investigated for commonly associated anomalies. 51/140 (36%) had a cardiac anomaly detected on echocardiogram.

Conclusion: There is room for improvement within the care for infants born with ARM in the UK and Ireland. Upskilling those performing neonatal examination to allow timely diagnosis, instruction of universal screening for associated anomalies and further analysis of the factors leading to clinically unnecessary stoma formation are warranted.

Level of Evidence: II (Prospective Cohort Study <80% follow-up).

© 2024 The Authors. Published by Elsevier Inc. This is an open access article under the CC BY license (<http://creativecommons.org/licenses/by/4.0/>).

1. Introduction

The term ‘anorectal malformation’ (ARM) describes a group of congenital anatomical anomalies where the rectum terminates outside of its usual location (within the external sphincter). It may end blindly, connect to the urinary or reproductive tracts, or open

on the skin anterior to the sphincter. ARM occurs in approximately one in every five thousand live births [1–3]. The spectrum of deviation from normal anatomy ranges from milder variants requiring minimal intervention and carrying an excellent outlook for continence to more significant anomalies often conferring a poorer bowel, bladder and sexual functional outcome despite surgical reconstruction [4–7].

In order to understand and compare the outcomes of infants born with ARM, it is essential that clinicians use a consistent system of classification. Although there is an international consensus on the classification of the types of ARM devised at the Krickenbeck

* Corresponding author. Specialist Neonatal and Paediatric Surgery, Great Ormond Street Hospital for Children, London WC1N 3JH, United Kingdom.

E-mail address: paolo.decoppi@gosh.nhs.uk (P. De Coppi).

¹ Contributed equally in the preparation of this manuscript.

meeting in 2005 (see Table 1); for some subtypes, consensus on the anatomical characteristics that define the variants included in this classification is absent, notably regarding definitions of anterior anus and perineal fistula.

ARM is frequently concomitantly found with other developmental structural anomalies; most commonly VACTERL association (vertebral, anorectal, cardiac, tracheal, oesophageal, renal and limb [8]). Screening for those anomalies that are not evident on clinical examination has been recommended to for all infants born with ARM (i.e. skeletal x-rays, cardiography and renal tract ultrasound [9]). Moreover, there are recognised increased incidence in individuals with chromosomal anomalies, of which, Trisomy 21 is the most common [10].

ARM should be detected at birth and delayed diagnosis may cause distress to care-givers and may result in deviations from preferred surgical management. Previous work has indicated that a significant number of infants born with ARM have the diagnosis missed at birth and present later [11–13], some with significant resultant complications, including death [14–16].

Much of our understanding of the demographics, management and outcome of ARM is derived from single centre retrospective data or regional multi-centre collaborations with a lack of whole-population data to describe presentation and early management of these infants [1,2]. Here, we describe these on a population level for the UK and Ireland with the aim of determining a contemporary picture of care of infants with ARM in the UK. We will derive benchmarks for further analysis and parental counselling and provide a stimulus for quality improvement.

As well as assessing the timing of ARM detection for infants and children in the UK, we investigate the characteristics of the infants in whom the diagnosis is made late to identify those at greatest risk. Furthermore, we aim to investigate the clinical consequences of this late diagnosis.

2. Methods

2.1. Study design

Using an established population-based surveillance system [17–22], the British Association of Paediatric Surgeons-Clinical Anomalies Surveillance System (BAPS-CASS) clinicians were prospectively asked to report all newly diagnosed cases of ARM, irrespective of age at presentation or any additional anomalies, over a 12-month period (01/10/2015–30/09/2016). All those reported were included. An initial data collection form was sent to reporting clinicians to collect data on demographics, presentation, and management of those meeting the case-definition. A second data collection form was sent 12-months after presentation.

2.2. Ethics committee approval

This study was approved by the NRES Committee South Central-Oxford A (Ref: 12/SC/0416).

2.3. Definitions

Anorectal malformation was defined as any child with imperforate anus, absence or narrowing of the communication canal between the rectum and anus with or without fistula to adjacent structures.

Anomaly type was defined by the reporting clinician and classified according to the Krickenbeck classification (Table 1, [23]). Importantly, as there is no consensus definition of anterior anus,

Table 1
Krickenbeck classification of ARM [23].

Major Clinical Groups	Rare/regional variants
Perineal (cutaneous) fistula	Pouch colon
Rectourethral fistula	Rectal atresia/stenosis
- Prostatic	
- Bulbar	
Rectovesical fistula	Rectovaginal fistula
Vestibular fistula	H-fistula
Cloaca	Others
No fistula	
Anal Stenosis	

the questionnaire did not define the condition and therefore this relied on the reporting clinician's own assessment. Therefore, in cases reported as anterior anus or perineal fistula, data were collected on distance from the opening to the centre of the sphincter complex, opening size (using a Hegar dilator for calibration) and surgeon-estimated proportion of the opening that was surrounded by sphincter muscle.

Late diagnosis of ARM was defined as: diagnosis after 72 h from birth or detection after discharge from hospital. VACTERL was defined as a coincidence of ≥ 3 associated anomalies, including ARM in the same individual. Vertebral (bony) and spinal (CNS) anomalies were recorded separately.

In order to calculate population-based incidence of ARM, the number of live births was derived using data from ONS, NRS Scotland, NISRA and CSO (Ireland), for the year 2015. Infants diagnosed before one year after birth were included in this calculation.

2.4. Statistical analysis

Stata 14.2 was used for statistical analysis. Continuous data are presented as median and interquartile range. Categorical data are presented as n/N (%), with 95% confidence intervals ($CI_{95}\{-\}$) where appropriate. Categorical data were compared using Fisher's Exact or χ^2 tests with a p value of <0.05 considered significant. Factors that may be associated with late diagnosis were explored using univariable logistic regression analysis. Covariates explored were: infant sex, birthweight, the presence of VACTERL (defined as ≥ 2 anomalies within the acronym *in addition to* an ARM) and ARM type. For the latter, anomalies were divided two ways: firstly anomalies with a visible fistula (e.g. anterior anus, anal stenosis, funnel anus or perineal fistula) vs all others, and secondly, anomalies producing meconium onto the perineum (those listed previously with a visible fistula plus vaginal fistula and cloaca) vs those who do not (including urinary tract fistulae and infants with no fistula).

3. Results

3.1. Presentation

3.1.1. Population incidence and characteristics

Of 28 tertiary paediatric centres surveyed, 26 reported 211 cases in the study period; overall data entry exceeded 80% (174/211). The total live-births in the UK and the Republic of Ireland in 2015 was 842,701; giving an incidence of ARM in the observation period of 1:4,842, $CI_{95}\{1:4173-1:5617\}$. The demographic characteristics of the population are shown in Table 2.

Most, but not all, infants were screened for VACTERL associated anomalies. Only 140/174 (80%) had an echocardiogram, 162/174 (93%) had a renal ultrasound and 154/174 (88%) had a spinal ultrasound.

Table 2
Population characteristics.

	n/N (%)
Patient Sex	
Male	95/174 (55)
Female	78/174 (45)
Indeterminate	1/174 (1)
Ethnicity	
White	125/160 (78)
Other	35/160 (22)
Gestational age at birth (weeks)^d	38 (37–40)
Birthweight (g)^d	3000 (2510–3433)
Maternal age (years)^d	31 (27–35)
Associated abnormalities^a	
Cardiac (non PFO/PDA)	51/140 (36)
Renal	49/162 (30)
Hypospadias ^b	13/95 (14)
Gynaecological ^b	5/78 (6)
Limb	19/174 (11)
Craniofacial	7/174 (4)
Brain	10/26 ^c (38)
Spinal Cord	27/154 (16)
Vertebral	14/154 (9)
Sacral	29/154 (19)
Spinal	51/154 (33)
Other Gastrointestinal	31/164 (19)
OA-TOF	16/174 (9)
VACTERL^e	56/174 (32)
Syndrome or known genetic abnormality	17/174 (10)

^a Denominator = those investigated.

^b % of relevant sex.

^c Had a Cranial Ultrasound Scan/MRI.

^d Median, IQR.

^e VACTERL defined as 2 or more from Vertebral, Cardiac, Tracheoesophageal, Renal and Limb anomalies in addition to ARM.

3.1.2. Types of anomaly

The most common type of anorectal malformation was perineal fistula, present in 43/158 (27%). The type of malformation was unknown in 16 infants; 4 of these died before classification, the other 12 had no data on reconstructive surgery. Fig. 1 a–b show the distribution of the known types of abnormality among the cohort by infant sex. The most common variants in girls and boys were vestibular fistula and perineal fistula respectively.

3.1.3. Morphology of anomalies classified as anterior anus vs. perineal fistula

There was no clear consensus on the definition of anterior anus and perineal fistula. As shown in Fig. 2, there was a degree of overlap between the anatomical characteristics of abnormalities classified into the two groups. The distance measured from the perineal opening to the centre of the muscle complex was similar between anomalies regardless of how they had been clinically defined. There was no statistical difference in the size of the opening although those defined as perineal fistula tended to be of smaller calibre. Those openings defined as perineal fistula were, however, less surrounded by the external sphincter complex (Median [IQR]: 50{0–67.5}% vs. 80{63–99}%; $p = 0.006$).

3.1.4. Timing of presentation

Four infants (2%) had features on prenatal imaging that suggested a diagnosis of surgical pathology antenatally and underwent fetal MRI, which identified a dilated rectum as a feature of an ARM in only two cases. The other two infants had features of other VACTERL anomalies but no reported features of ARM. All of these mothers had received antenatal surgical counselling. Across the whole cohort, the median age at presentation was 1 day after birth (IQR 1–2 days). The oldest child presented at four and a half years of age. Thirty nine (39/174, 22% CI₉₅{16–29})

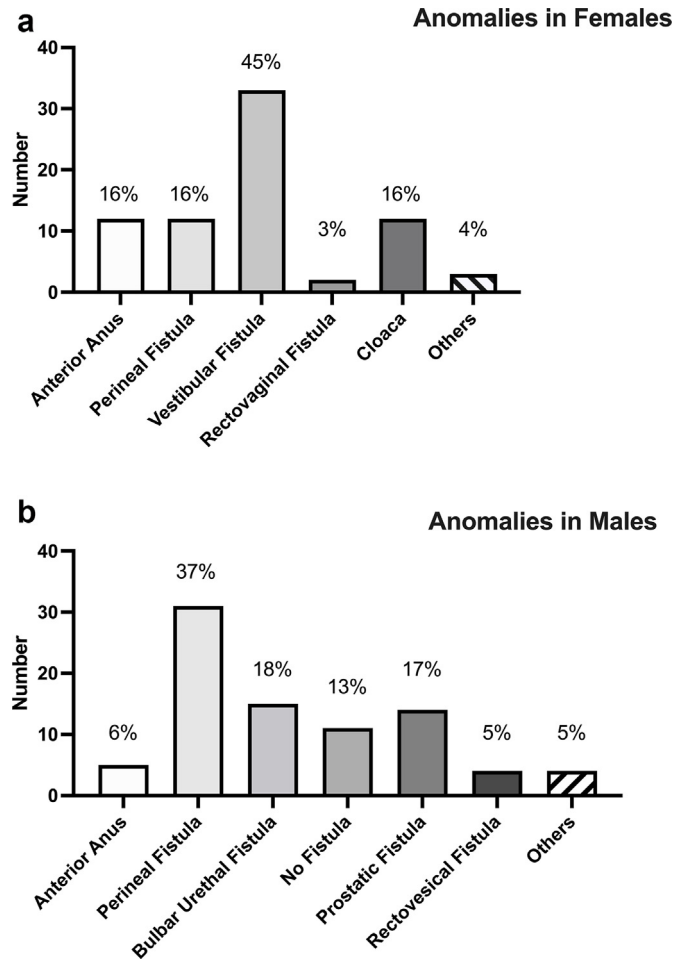


Fig. 1. Distribution of Anomalies by Infant Sex. a. Distribution of anomalies among females; b. Distribution of anomalies among males.

infants in the cohort were diagnosed late (>72 h of age or after initial discharge from hospital). Thirty-three (18%) were >24 h old at presentation and 31 (18%) were discharged home before the diagnosis was made. Twelve (7%) infants were older than 30 days at presentation and two (1%) were over one year. Factors associated with late presentation were explored and are shown in Table 3.

Almost 1/3 (23/78; 29%, CI₉₅{20–41}) of girls in the cohort were diagnosed late, while ARM in infants with VACTERL association was less likely to be missed. Type of anomaly was strongly associated with late diagnosis. Infants with anomalies with a visible opening and those producing meconium onto the perineum were more likely to have the diagnosis missed. It is noteworthy that 14 infants with no visible anal opening were also diagnosed late (8% of the cohort, 15% of infants with no opening).

Where it was known who first suspected an anomaly ($n = 36$), half of the infants and children with late diagnosis of ARM were detected by paediatricians (18/36). 5/36 (14%) of the abnormalities were first suspected by parents.

3.2. Management

3.2.1. Early surgical management

171 infants had data on their first operative surgical procedure. 156 (91%) had or were planned for definitive correction; the others had assessment with or without dilatation only. Of the 156 that had definitive correction, 116 (74%) had a stoma formed before, or at the

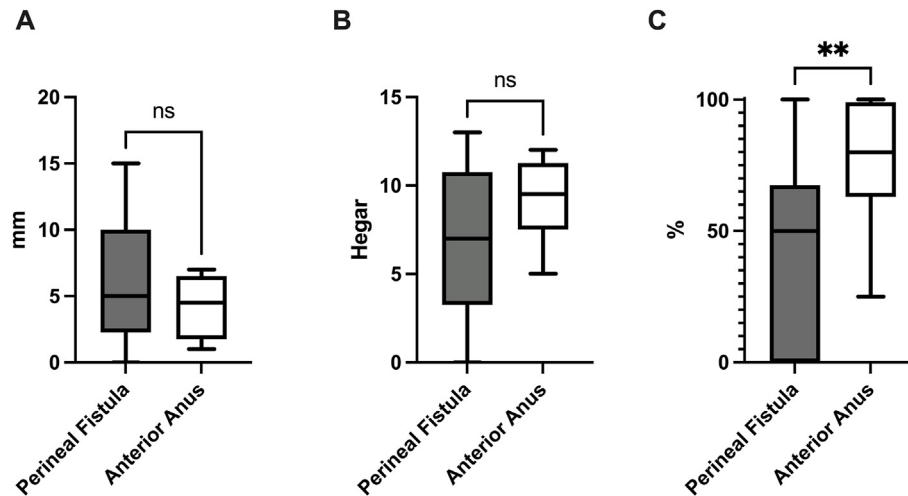


Fig. 2. Anatomical characteristics of defects classified as Anterior Anus or Perineal Fistula. A: Distance in mm from the opening to the centre of the sphincter muscle; B: Hegar dilator size, perineal opening admits on initial calibration; C: Percentage of the perineal opening surrounded by sphincter muscle.

Table 3

Factors associated with late presentation, NB number of patients in each group varies depending on completeness of data.

	n/N (%)	Unadjusted OR (CI ₉₅)	P
Sex	F: 23/78 (29) M: 16/95 (17)	2.06 [1.0–4.26]	0.048
Prematurity	Term: 24/109 (22) Pre-term: 10/57 (18)	0.75 [0.33–1.71]	0.49
VACTERL	Yes 5/58 (9) No 34/116 (29)	4.4 [1.62–11.95]	0.001
Visible anal opening ^a	Yes: 21/65 (32) No: 14/91 (15)	2.63 [1.21–5.67]	0.013
Anomaly with meconium ^b	Yes: 34/112 (30) No: 1/44 (2)	18.74 [2.47–141.73]	<0.00001

^a Anomalies with a visible opening; perineal fistula, anterior anus, funnel anus, 'H' fistula.

^b Visible opening anomalies plus, recto-vestibular fistula, cloaca and rectovaginal fistula.

same time as, correction. Two further infants had unplanned stoma formation after definitive correction due to complications. Therefore, overall, 76% of children undergoing surgery managed with a stoma at some point during their reconstruction. Table 4 shows the surgical management of individuals with the most common anomalies.

Anterior anus and perineal fistula are anomalies that may be corrected without a covering stoma [24–26]. 16/46 (35%) infants with these anomalies that underwent correction had a stoma formed as part of their surgical management. This was 15/41 (37%) of babies with perineal fistula and one of five babies with anterior anus. Reasons for stoma formation included planned surgical approach (i.e. 3-stage) in nine (56%), emergency need for decompression in five (31%) and associated other gastrointestinal anomalies in the remaining two (13%). Twenty-five of 32 babies with vestibular fistula (78%) were repaired with a covering stoma.

3.3. Outcomes

3.3.1. Complications and mortality

Four infants died in the first month after birth (2%, CI₉₅{1–7}). Three had severe associated anomalies, the cause of death in the other was unknown. No infant had bowel perforation prior to ARM diagnosis.

3.3.2. Early post-operative outcomes of first operative procedure

154 infants that underwent operative surgical management had complete data on complications. Twenty-six out of 154 children

(17%, CI₉₅{11–24}) had a complication during their index admission, of whom 18 (12%, CI₉₅{7–18}) had a complication related to their ARM or its treatment. Among these 18 related complications, there was a single Clavien-Dindo Grade IV, two Grade IIIa/b, eleven Grade II and four Grade Ib [27]. Wound infection and/or dehiscence was the most common complication, and this accounted for 12/18 (66%).

17/113 (15%, CI₉₅{9–23}) who had a stoma only prior to definitive correction had a complication of stoma formation. Eight of these were wound infection or skin dehiscence. One infant had a life-threatening complication. Of the 39 (25%) infants that had definitive repair without a stoma as their primary procedure and complete data, five had a complication (13%, CI₉₅{4–27}). Three of these were wound infections and two were dehiscence. One infant with dehiscence underwent emergency defunctioning stoma formation.

3.3.3. Clinical consequences of late diagnosis

The numbers of individuals with each variant are too small to robustly analyse the impact of late diagnosis on surgeons' choice whether to cover definitive repair with a stoma in infants with perineal fistula, anterior anus and vestibular fistula who underwent surgical correction. Covering stoma was formed in 4/14 (29%, CI₉₅{8–58}) infants with perineal fistula or anterior anus diagnosed late and 12/32 (38%, CI₉₅{21–56}) diagnosed early. Covering stoma was formed in 10/12 (83%, CI₉₅{52–98}) infants with vestibular fistula diagnosed late and 15/20 (75%, CI₉₅{51–91}) diagnosed early.

Table 4
Initial surgical management by abnormality n (%).

	N undergoing procedure	EUA ^a /Dilatation only (%)	Correction without stoma (%)	Correction with Stoma (%)	Stoma only with/without EUA/dilatation (%)
Total	147	14	37	3	93
Anterior Anus	17	12 (71)	4 (23)	0	1 ^b (6)
Perineal Fistula	43	2 (5)	26 (60)	2 (5)	13 (30)
Vestibular Fistula	32	0	7 (22)	1 (3)	24 (75)
Urinary Fistula	31	0	0	0	31 (100)
Vaginal Fistula	2	0	0	0	2 (100)
Cloaca	11	0	0	0	11 (100)
No Fistula	11	0	0	0	11 (100)

^a Examination under anaesthesia.

^b Formed due to another congenital anomaly.

4. Discussion

In this prospective population cohort study, the incidence of ARM was 1:4842 live births, consistent with other studies across Europe (EUROCAT). Most babies were born at term and a significant proportion had other comorbidities; one third of those investigated had a cardiac anomaly, a fifth had another gastrointestinal anomaly and one in ten had a known genetic anomaly or syndrome. As other authors have noted, screening for associated anomalies was not consistent or universal and this requires improvement [9].

While prenatal diagnosis is rare, anorectal malformations should be identified at birth. Unfortunately, this prospective study confirms previous retrospective findings showing that among this population there was a high rate of late diagnosis of ARM [11,13]. More than one in five infants overall, and almost one third of girls were diagnosed late. When the factors associated with late diagnosis were assessed, it was clear that anomalies most closely resembling a normal anus and those that lead to the production of meconium on the perineum, were more likely to be detected late [28]. It is likely that the production of meconium in the perineum may lead to the assumption of normal anatomy. In the United Kingdom, current neonatal practice guidelines dictate that newborns should be examined within the first 24 h after birth, ideally within the first 6 h [29]. This examination needs to include a full inspection of the perineum. In Ireland, the newborn clinical examination handbook states: 'anal atresia can easily be overlooked. The presence of meconium on the nappy does not exclude anal atresia because it may have been passed through a perineal, recto-vaginal or a recto-vesical fistula' [30].

There is clearly a widespread gap in knowledge, skills or experience regarding the variants that most closely resemble normality, such as the example shown in Fig. 2. The data in Table 3 suggest that those performing neonatal examinations may not be looking beyond the normal passage of meconium on to the perineum. Education about cleaning of the area and confirmation of an anal opening in the normal position is warranted and has been the subject of a recent and timely targeted review related to practice in the United Kingdom [31]. Late diagnosis has been recognised as a significant issue in institutional series from the UK and other high-income countries [32–34]. The rate of missed diagnosis has been reported to be far lower in other European centres, suggesting that rate of late diagnosis could be improved [11,12]. Delay in diagnosis has potentially significant consequences, with emergency presentation leading to morbidity and mortality reported in the published literature [14,35–37]. Some authors also suggest it may lead to more post-operative complications [16].

Among this population-based cohort, the consequences of late diagnosis could not be robustly assessed due to small numbers of infants in whom this could be assessed. It is notable that 12

individuals were diagnosed over a year after birth. Data were not collected on symptoms at presentation, but it is known that children presenting late with ARM may have significant problems with constipation leading to distress for these children and their caregivers [38]. The longer-term outcomes of these children with late-diagnosis merit further analysis, outside the scope of this current work. Comparing long-term functional outcomes against similar variants with timely diagnosis would be informative to fully inform the consequences of the practice gap that undoubtedly exists.

Robust analysis of the management and outcomes of the ARM requires consistent classification of anatomical variants, particularly of the difference between anterior anus and perineal fistula. This has long been contentious. In 2004, Alberto Peña proposed a definition of anterior anus to include only those with a perineal opening completely within a sphincter complex, albeit anterior to its expected position on the perineum [39]. Unfortunately, the data shown in Fig. 2A-C suggest inconsistency among surgeons in the UK and Ireland about the anatomical characteristics defining these anomalies. Consensus in classification is essential for future research and outcome benchmarking studies, and a recent publication from the ARM-Net consortium has laid out consensus guidelines from surgeons across Europe regarding definitions of anal position, relative size and assessment of sphincter coverage, in an attempt to drive clinicians towards speaking a common language related to variants of Anterior Anus and Perineal Fistula [40].

Three quarters (75%) of infants in the cohort had a stoma formed as part of their management. In anomalies requiring complex anorectal reconstruction such as those with urinary tract fistulae or cloaca, this was inevitable, but a surprising number were formed in infants undergoing corrective surgery with variants potentially correctable without a stoma, notably 37% of those with perineal fistula and 78% with vestibular fistula. Fifteen per cent who had a stoma only, prior to definitive correction, had a complication of stoma formation and one of these was life-threatening. This rate correlates to that of other published series of colostomy formation in ARM [41,42]. Stoma closure may also incur further complications; and while not assessed specifically in this cohort, these occurred in up to 45% in a large published series from Cincinnati Children's Hospital [43]. Performing staged repair also increases the number of general anaesthetics children undergo (i.e. 3 versus 1) [44]. While trial data are reassuring regarding the neurocognitive impact of a single, short general anaesthetic episode [45], there are clear differences when considering the operative interventions in necessary to manage infants with ARM.

Repair of perineal fistula without covering colostomy is a well-established practice [24,46]. Repair of vestibular fistula without covering colostomy is controversial in the UK but has long been supported internationally by some specialised colorectal centres [25,47]. Meta-analysis of 3 published series demonstrates an

increased incidence of peri-operative complications of ano-rectoplasty when performed as a single stage procedure, however, there appeared to be no difference in long-term faecal control [48]. It is noteworthy that 33 females with vestibular fistula presented within one year in the UK and Ireland, this is just over one per centre highlighting the low frequency with which individual surgeons encounter this anomaly.

The frequency of stoma formation among the population of infants that may be amenable to single-stage repair requires further investigation. Individualised factors such as prematurity, severe associated comorbidities and the presence of other structural anomalies requiring treatment may affect management choice. The decision to form a stoma is at the discretion of the treating surgeon but the findings from this population cohort study may suggest lack of available specialist surgical expertise to perform primary repair. These results are similar to those identified in a UK population cohort study of infants born with Hirschsprung's disease (HD) that also used the BAPS-CASS system [18]. Bradnock and co-authors identified that 36% of infants had a stoma formed prior to definitive surgery for HD; more than double the rate that surgeons had suggested would be their intention in a survey of practice [49].

Previously published population-based or international registry studies have focussed on birth outcomes and maternal risk factors for babies born with ARM [50–54]. Others have focussed on associated anomalies [55,56]. This is the first population-based cohort study to combine a description of the anatomical classification, along with timing and manner of diagnosis and surgical management of infants with ARM. We have therefore been able to assess factors related to late presentation and contemporary management on a large scale.

As noted previously, the heterogeneity of this population is considerable. Associated structural anomalies are common and many are likely to impact significantly on infants' course and outcome. In addition, types of anomaly were diverse with relatively small numbers in each category (Fig. 1.) diagnosed within a one-year period in the UK. For illustration, approximately one male per centre per year presented with a urinary tract fistula. This makes risk-adjusted outcome assessment challenging and provides further evidence of the need to elucidate variable surgical management at a population-level, providing a stimulus for discussion and improvement. The optimum organisation of services to ensure the best care with the minimum number of procedures for infants born with ARM requires further debate; however, centralisation of care for complex congenital anomalies has formed a headline recommendation of the recent Getting it Right First Time report (GIRFT) [57]. It should also be noted that the dataset presented was reported in 2016, and as such there may have since been changes to clinical practice leading to different outcomes – particularly in light of the UK's Royal College of Paediatrics and Child Health Policy changes that all clinicians performing newborn screening should have specific training on the diagnosis of ARM [31]. It would be important to analyse whether such interventions have successfully modified the rate of late diagnosis by repeating such a survey. As this study cohort would now be well into school age, there would also be an opportunity to continue this work with continence evaluation related to both anomaly type and delays in diagnosis and presentation.

5. Conclusion

This population-based study of anorectal malformation in the UK and Ireland provides important insights into the incidence, characteristics and current management of children born with this anomaly. We have identified several areas for improvement, particularly in the timely diagnosis of ARM. This study should further raise awareness of this issue, which needs to be addressed

at a national level. This should involve a comprehensive educational package for those performing newborn examinations including an online competency package with detailed information about how to assess for ARM [31]. Pictorial representations of more subtle variants may help to avoid missing cases. This may be implemented using innovative digital tools as has been used for image-guided diagnosis of conditions such as skin cancer [58].

Further research will be needed to address the optimal management for infants born with vestibular fistula and the risks and benefits of performing repair without a stoma. The diversity of this population-based cohort illustrates the likely need for international collaboration to answer this and other research questions about the surgical management of infants with ARM in order to improve early diagnosis and peri-operative outcomes.

Acknowledgements

This project was funded through a National Institute for Health Research (NIHR) Professorship award to Marian Knight (NIHR-RP-011-032). Marian Knight is an NIHR Senior Investigator. Paolo De Coppi P.D.C. is supported by NIHR-RP-2014-04-046 and the Great Ormond Street Hospital NIHR BRC. The views expressed are those of the author(s) and not necessarily those of the NHS, the NIHR or the Department of Health.

References

- [1] Cassina M, Fascetti Leon F, Ruol M, Chiarenza SF, Scirè G, Midrio P, et al. Prevalence and survival of patients with anorectal malformations: a population-based study. *J Pediatr Surg* 2019;54:1998–2003. <https://doi.org/10.1016/j.jpedsurg.2019.03.004>.
- [2] Theron A, Numanoglu A. Birth prevalence of anorectal malformations for the western cape province, South Africa, 2005 to 2012. *Eur J Pediatr Surg* 2017;27:449–54. <https://doi.org/10.1055/s-0036-1597945>.
- [3] Michikawa T, Nitta H, Sekiyama M, Kuroda T, Nakayama SF, Isobe T, et al. Maternal intake of one-carbon metabolism-related B vitamins and anorectal malformations in the Japan Environment and Children's Study. *Br J Nutr* 2020;124:865–73. <https://doi.org/10.1017/S0007114520001816>.
- [4] Kyrklund K, Pakarinen MP, Rintala RJ. Long-term bowel function, quality of life and sexual function in patients with anorectal malformations treated during the PSARP era. *Semin Pediatr Surg* 2017;26:336–42. <https://doi.org/10.1053/j.sempedsurg.2017.09.010>.
- [5] Danielson J, Karlsson U, Graf W, Olsen L, Wester T. Posterior sagittal anorectoplasty results in better bowel function and quality of life in adulthood than pull-through procedures. *J Pediatr Surg* 2015;50:1556–9. <https://doi.org/10.1016/j.jpedsurg.2015.02.004>.
- [6] Borg HC, Holmdahl G, Gustavsson K, Doroszkiewicz M, Sillén U. Longitudinal study of bowel function in children with anorectal malformations. *J Pediatr Surg* 2013;48:597–606. <https://doi.org/10.1016/j.jpedsurg.2012.10.056>.
- [7] Iwai N, Deguchi E, Kimura O, Kubota Y, Ono S, Shimadera S. Social quality of life for adult patients with anorectal malformations. *J Pediatr Surg* 2007;42:313–7. <https://doi.org/10.1016/j.jpedsurg.2006.10.004>.
- [8] Quan L, Smith DW. The VATER association. Vertebral defects, Anal atresia, T-E fistula with esophageal atresia, Radial and Renal dysplasia: a spectrum of associated defects. *J Pediatr* 1973;82:104–7. [https://doi.org/10.1016/s0022-3476\(73\)80024-1](https://doi.org/10.1016/s0022-3476(73)80024-1).
- [9] England RJ, Eradi B, Murthi GV, Sutcliffe J. Improving the rigour of VACTERL screening for neonates with anorectal malformations. *Pediatr Surg Int* 2017;33:747–54. <https://doi.org/10.1007/s00383-017-4094-3>.
- [10] Marcellis C, de Blaauw I, Brunner H. Chromosomal anomalies in the etiology of anorectal malformations: a review. *Am J Med Genet* 2011;155:2692–704. <https://doi.org/10.1002/ajmg.a.34253>.
- [11] Aldeiri B, Davidson J, Eaton S, Coletta R, Cardoso Almeida A, Long A-M, et al. Variations in the detection of anorectal anomalies at birth among European cities. *Eur J Pediatr Surg* 2019. <https://doi.org/10.1055/s-0039-1687868>.
- [12] Theron AP, Brisighelli G, Theron AE, Leva E, Numanoglu A. Comparison in the incidence of anorectal malformations between a first- and third-world referral center. *Pediatr Surg Int* 2015;31:759–64. <https://doi.org/10.1007/s00383-015-3740-x>.
- [13] Tareen F, Coyle D, Aworanti OM, Gillick J. Delayed diagnosis of anorectal malformation—a persistent problem. *Ir Med J* 2013;106:238–40.
- [14] Haider N, Fisher R. Mortality and morbidity associated with late diagnosis of anorectal malformations in children. *Surgeon* 2007;5:327–30.
- [15] Eltayeb AA. Delayed presentation of anorectal malformations: the possible associated morbidity and mortality. *Pediatr Surg Int* 2010;26:801–6. <https://doi.org/10.1007/s00383-010-2641-2>.

- [16] Lindley RM, Shawis RN, Roberts JP. Delays in the diagnosis of anorectal malformations are common and significantly increase serious early complications. *Acta Paediatr* 2006;95:364–8. <https://doi.org/10.1080/08035250500437523>.
- [17] Bethell GS, Long A-M, Knight M, Hall NJ. Congenital duodenal obstruction in the UK: a population-based study. *Arch Dis Child Fetal Neonatal* 2020;105:178–83. <https://doi.org/10.1136/archdischild-2019-317085>.
- [18] Bradnock TJ, Knight M, Kenny S, Nair M, Walker GM. The use of stomas in the early management of Hirschsprung disease: findings of a national, prospective cohort study. *J Pediatr Surg* 2017;52:1451–7. <https://doi.org/10.1016/j.jpedsurg.2017.05.008>.
- [19] Brownlee E, Wragg R, Robb A, Chandran H, Knight M, McCarthy L. Current epidemiology and antenatal presentation of posterior urethral valves: outcome of BAPS CASS National Audit. *J Pediatr Surg* 2019;54:318–21. <https://doi.org/10.1016/j.jpedsurg.2018.10.091>.
- [20] Burge DM, Shah K, Spark P, Shenker N, Pierce M, Kurinczuk JJ, et al. Contemporary management and outcomes for infants born with oesophageal atresia. *Br J Surg* 2013;100:515–21. <https://doi.org/10.1002/bjs.9019>.
- [21] Long A-M, Bunch KJ, Knight M, Kurinczuk JJ, Losty PD. Early population-based outcomes of infants born with congenital diaphragmatic hernia. *Arch Dis Child Fetal Neonatal* Ed 2018;103:F517–22. <https://doi.org/10.1136/archdischild-2017-313933>.
- [22] Owen A, Marven S, Johnson P, Kurinczuk J, Spark P, Draper ES, et al. Gastro-schisis: a national cohort study to describe contemporary surgical strategies and outcomes. *J Pediatr Surg* 2010;45:1808–16. <https://doi.org/10.1016/j.jpedsurg.2010.01.036>.
- [23] Holschneider A, Hutson J, Peña A, Beket E, Chatterjee S, Coran A, et al. Preliminary report on the international conference for the development of standards for the treatment of anorectal malformations. *J Pediatr Surg* 2005;40:1521–6. <https://doi.org/10.1016/j.jpedsurg.2005.08.002>.
- [24] Kumar B, Kandpal DK, Sharma SB, Agrawal LD, Jhamariya VN. Single-stage repair of vestibular and perineal fistulae without colostomy. *J Pediatr Surg* 2008;43:1848–52. <https://doi.org/10.1016/j.jpedsurg.2008.03.047>.
- [25] Menon P, Rao KLN. Primary anorectoplasty in females with common anorectal malformations without colostomy. *J Pediatr Surg* 2007;42:1103–6. <https://doi.org/10.1016/j.jpedsurg.2007.01.056>.
- [26] Short SS, Bucher BT, Barnhart DC, Van Der Watt N, Zobel S, Allen A, et al. Single-stage repair of rectoperineal and rectovestibular fistulae can be safely delayed beyond the neonatal period. *J Pediatr Surg* 2018;53:2174–7. <https://doi.org/10.1016/j.jpedsurg.2018.02.048>.
- [27] Dindo D, Demartines N, Clavien P-A. Classification of surgical complications: a new proposal with evaluation in a cohort of 6336 patients and results of a survey. *Ann Surg* 2004;240:205–13. <https://doi.org/10.1097/01.sla.0000133083.54934.ae>.
- [28] Aldeiri B, Johal NS, De Coppi P. Meconium is not enough: look for the hole! *Case Reports*, 2012; 2012. <https://doi.org/10.1136/bcr-2012-007456>.
- [29] NHS England. Newborn physical examination. Your pregnancy and baby guide. 2018. <https://www.nhs.uk/conditions/pregnancy-and-baby/newborn-physical-exam/>.
- [30] Murphy J, Jennings P. Examination of the anus. *The newborn clinical handbook*. Health Service Executive; 2017. p. 33.
- [31] Murthi GVS, McEwan T, Walker GM, Bustani P. Missed or delayed diagnosis of anorectal malformations: a review of the literature, current training and practice in the UK in relation to detection via the NIPE programme. *Arch Dis Child Fetal Neonatal* Ed 2023. <https://doi.org/10.1136/archdischild-2022-324667>.
- [32] Kruger P, Teague WJ, Khanal R, Hutson JM, King SK. Delayed diagnosis of anorectal malformations in neonates. *ANZ J Surg* 2019;89:1253–5. <https://doi.org/10.1111/ans.15374>.
- [33] Wilson BE, Etheridge CE, Soundappan SV, Holland AJ. Delayed diagnosis of anorectal malformations: are current guidelines sufficient? *J Paediatr Child Health* 2010;46:268–72. <https://doi.org/10.1111/j.1440-1754.2009.01683.x>.
- [34] Jonker JE, Trzpis M, Broens PMA. Underdiagnosis of mild congenital anorectal malformations. *J Pediatr* 2017;186:101–104.e1. <https://doi.org/10.1016/j.jpeds.2017.03.054>.
- [35] Turowski C, Dingemann J, Gillick J. Delayed diagnosis of imperforate anus: an unacceptable morbidity. *Pediatr Surg Int* 2010;26:1083–6. <https://doi.org/10.1007/s00383-010-2691-5>.
- [36] Kayima P, Kitya D, Punchak M, Anderson GA, Situma M. Patterns and treatment outcomes of anorectal malformations in mbarara regional referral hospital, Uganda. *J Pediatr Surg* 2019;54:838–44. <https://doi.org/10.1016/j.jpedsurg.2018.07.019>.
- [37] Govender S, Wiersma R. Delayed diagnosis of anorectal malformations (ARM): causes and consequences in a resource-constrained environment. *Pediatr Surg Int* 2016;32:369–75. <https://doi.org/10.1007/s00383-016-3866-5>.
- [38] Divya G, Kundal VK, Debnath PR, Addagatla R, Garbhapu AK, Sen A, et al. Delayed presentation of anorectal malformations in a tertiary care hospital in India. *Pediatr Surg Int* 2021;37:451–6. <https://doi.org/10.1007/s00383-020-04843-5>.
- [39] Peña A. Comments on anterior ectopic anus. *Pediatr Surg Int* 2004;20:902. <https://doi.org/10.1007/s00383-002-0724-4>.
- [40] Amerstorfer EE, Schmiedeke E, Samuk I, Sloots CEJ, van Rooij IALM, Jenetzky E, et al. Clinical differentiation between a normal anus, anterior anus, congenital anal stenosis, and perineal fistula: definitions and consequences—the ARM-net consortium consensus. *Children* 2022;9. <https://doi.org/10.3390/children9060831>.
- [41] Youssef F, Arbash G, Puligandla PS, Baird RJ. Loop versus divided colostomy for the management of anorectal malformations: a systematic review and meta-analysis. *J Pediatr Surg* 2017;52:783–90. <https://doi.org/10.1016/j.jpedsurg.2017.01.044>.
- [42] Mullassery D, Iacona R, Cross K, Blackburn S, Kiely E, Eaton S, et al. Loop colostomies are safe in anorectal malformations. *J Pediatr Surg* 2018;53:2170–3. <https://doi.org/10.1016/j.jpedsurg.2018.05.022>.
- [43] Bischoff A, Levitt MA, Lawal TA, Peña A. Colostomy closure: how to avoid complications. *Pediatr Surg Int* 2010;26:1087–92. <https://doi.org/10.1007/s00383-010-2690-6>.
- [44] Peña A, Migotto-Krieger M, Levitt MA. Colostomy in anorectal malformations: a procedure with serious but preventable complications. *J Pediatr Surg* 2006;41:748–56. <https://doi.org/10.1016/j.jpedsurg.2005.12.021>. discussion 748–56.
- [45] Davidson AJ, Disma N, de Graaff JC, Withington DE, Dorris L, Bell G, et al. Neurodevelopmental outcome at 2 years of age after general anaesthesia and awake-regional anaesthesia in infancy (GAS): an international multicentre, randomised controlled trial. *Lancet* 2016;387:239–50. [https://doi.org/10.1016/S0140-6736\(15\)00608-X](https://doi.org/10.1016/S0140-6736(15)00608-X).
- [46] Pakarinen MP, Goyal A, Koivusalo A, Baillie C, Turnock R, Rintala RJ. Functional outcome in correction of perineal fistula in boys with anoplasty versus posterior sagittal anorectoplasty. *Pediatr Surg Int* 2006;22:961–5. <https://doi.org/10.1007/s00383-006-1789-2>.
- [47] van der Steeg HJJ, Schmiedeke E, Bagolan P, Broens P, Demirogullari B, Garcia-Vazquez A, et al. European consensus meeting of ARM-Net members concerning diagnosis and early management of newborns with anorectal malformations. *Tech Coloproctol* 2015;19:181–5. <https://doi.org/10.1007/s10151-015-1267-8>.
- [48] Lauriti G, Di Renzo D, Lelli Chiesa P, Zani A, Piarro A. One-stage repair of anorectal malformations in females with vestibular fistula: a systematic review and meta-analysis. *Pediatr Surg Int* 2019;35:77–85. <https://doi.org/10.1007/s00383-018-4378-2>.
- [49] Bradnock TJ, Walker GM. Evolution in the management of Hirschsprung's disease in the UK and Ireland: a national survey of practice revisited. *Ann R Coll Surg Engl* 2011;93:34–8. <https://doi.org/10.1308/003588410X12771863936846>.
- [50] Vermes G, László D, Á Mátrai, Czeizel AE, Ács N. Maternal factors in the origin of isolated anorectal malformations - a population-based case-control study. *J Matern Fetal Neonatal Med* 2016;29:2316–21. <https://doi.org/10.3109/14767058.2015.1085014>.
- [51] Svenningsson A, Gunnarsdottir A, Wester T. Maternal risk factors and perinatal characteristics of anorectal malformations. *J Pediatr Surg* 2018;53:2183–8. <https://doi.org/10.1016/j.jpedsurg.2018.04.021>.
- [52] Wijers CHW, van Rooij IALM, Bakker MK, Marcellis CLM, Addor MC, Barisic I, et al. Anorectal malformations and pregnancy-related disorders: a registry-based case-control study in 17 European regions. *BJOG* 2013;120:1066–74. <https://doi.org/10.1111/1471-0528.12235>.
- [53] Wijers CHW, van Rooij IALM, Rassouli R, Wijnen MH, Broens PMA, Sloots CEJ, et al. Parental subfertility, fertility treatment, and the risk of congenital anorectal malformations. *Epidemiology* 2015;26:169–76. <https://doi.org/10.1097/EDE.0000000000000226>.
- [54] Bidondo MP, Groisman B, Gili JA, Liasovich R, Barbero P, Pingray V, et al. Study on the prevalence and neonatal lethality in patients with selected congenital anomalies as per the data of the National Registry of Congenital Anomalies of Argentina. *Arch Argent Pediatr* 2015;113:295–302. <https://doi.org/10.5546/aap.2015.295>.
- [55] van de Putte R, Wijers CHW, de Blaauw I, Marcellis CLM, Sloots CEJ, Brooks AS, et al. Previous miscarriages and GLI2 are associated with anorectal malformations in offspring. *Hum Reprod* 2017;32:299–306. <https://doi.org/10.1093/humrep/dew327>.
- [56] Stoll C, Dott B, Alembik Y, Roth M-P. Associated anomalies in cases with anorectal anomalies. *Am J Med Genet* 2018;176:2646–60. <https://doi.org/10.1002/ajmg.a.40530>.
- [57] Kenny S. Paediatric surgery and urology. 2021. *Getting it Right First Time Programme National Speciality Report*.
- [58] Smak Gregoor AM, Sangers TE, Bakker LJ, Hollestein L, Uyl – de Groot CA, Nijsten T, et al. An artificial intelligence based app for skin cancer detection evaluated in a population based setting. *NPJ Digit Med* 2023;6:90. <https://doi.org/10.1038/s41746-023-00831-w>.