

ORIGINAL INVESTIGATIONS

Complicated Carotid Artery Plaques and Risk of Recurrent Ischemic Stroke or TIA



Anna Kopczak, MD,^{a,*} Andreas Schindler, MD,^{b,c,*} Dominik Sepp, MD,^d Anna Bayer-Karpinska, MD,^{a,e} Rainer Malik, PhD,^a Mia L. Koch, MD,^f Julia Zeller, MA,^g Christoph Strecker, MD,^h Daniel Janowitz, MD,^a Frank A. Wollenweber, MD,^{a,i} Johann-Martin Hempel, MD,^j Tobias Boeckh-Behrens, MD,^d Clemens C. Cyran, MD,^b Andreas Helck, MD,^k Andreas Harloff, MD,^h Ulf Ziemann, MD,^g Sven Poli, MD,^g Holger Poppert, MD,^{f,l} Tobias Saam, MD,^{b,m,†} Martin Dichgans, MD^{a,n,o,†}

ABSTRACT

BACKGROUND Complicated nonstenosing carotid artery plaques (CAPs) are an under-recognized cause of stroke.

OBJECTIVES The purpose of this study was to determine whether complicated CAP ipsilateral to acute ischemic anterior circulation stroke (icCAP) are associated with recurrent ischemic stroke or transient ischemic attack (TIA).

METHODS The CAPIAS (Carotid Plaque Imaging in Acute Stroke) multicenter study prospectively recruited patients with ischemic stroke restricted to the territory of a single carotid artery. Complicated (AHA-lesion type VI) CAP were defined by multisequence, contrast-enhanced carotid magnetic resonance imaging obtained within 10 days from stroke onset. Recurrent events were assessed after 3, 12, 24, and 36 months. The primary outcome was recurrent ischemic stroke or TIA.

RESULTS Among 196 patients enrolled, 104 patients had cryptogenic stroke and nonstenosing CAP. During a mean follow-up of 30 months, recurrent ischemic stroke or TIA occurred in 21 patients. Recurrent events were significantly more frequent in patients with icCAP than in patients without icCAP, both in the overall cohort (incidence rate [3-year interval]: 9.50 vs 3.61 per 100 patient-years; $P = 0.025$, log-rank test) and in patients with cryptogenic stroke (10.92 vs 1.82 per 100 patient-years; $P = 0.003$). The results were driven by ipsilateral events. A ruptured fibrous cap (HR: 4.91; 95% CI: 1.31-18.45; $P = 0.018$) and intraplaque hemorrhage (HR: 4.37; 95% CI: 1.20-15.97; $P = 0.026$) were associated with a significantly increased risk of recurrent events in patients with cryptogenic stroke.

CONCLUSIONS Complicated CAP ipsilateral to acute ischemic anterior circulation stroke are associated with an increased risk of recurrent ischemic stroke or TIA. Carotid plaque imaging identifies high-risk patients who might be suited for inclusion into future secondary prevention trials. (Carotid Plaque Imaging in Acute Stroke [CAPIAS]; [NCT01284933](https://doi.org/10.1016/j.jacc.2022.03.376)) (J Am Coll Cardiol 2022;79:2189-2199) © 2022 The Authors. Published by Elsevier on behalf of the American College of Cardiology Foundation. This is an open access article under the CC BY-NC-ND license (<http://creativecommons.org/licenses/by-nc-nd/4.0/>).



Listen to this manuscript's audio summary by Editor-in-Chief Dr Valentin Fuster on www.jacc.org/journal/jacc.

From the ^aInstitute for Stroke and Dementia Research, University Hospital, LMU Munich, Munich, Germany; ^bDepartment of Radiology, University Hospital, LMU Munich, Munich, Germany; ^cDepartment of Neuroradiology, University Hospital, LMU Munich, Munich, Germany; ^dDepartment of Neuroradiology, Klinikum rechts der Isar, Technical University of Munich (TUM), Munich, Germany; ^eKlinikum Fürstentfeldbruck, Neurology, Fürstentfeldbruck, Germany; ^fDepartment of Neurology, Klinikum rechts der Isar, Technical University of Munich (TUM), Munich, Germany; ^gDepartment of Neurology and Stroke, and Hertie Institute for Clinical Brain Research, University of Tübingen, Tübingen, Germany; ^hDepartment of Neurology and Neurophysiology, Medical Center - University of Freiburg, Faculty of Medicine, University of Freiburg, Freiburg, Germany; ⁱDepartment of Neurology, Helios Dr Horst-Schmidt-Kliniken, Wiesbaden, Germany; ^jDepartment of Diagnostic and Interventional Neuroradiology, University of Tübingen, Tübingen, Germany; ^kRadiology and Neuroradiology Zurich, Hirslanden/Klinik im Park, Zurich, Switzerland; ^lDepartment of Neurology, Helios Klinikum München West, Munich, Germany; ^mRadiologisches Zentrum Rosenheim, Rosenheim, Germany; ⁿMunich Cluster for Systems Neurology (SyNergy), Munich, Germany; and the ^oGerman Center for Neurodegenerative Diseases (DZNE), Munich, Germany. *Drs Kopczak and Schindler contributed equally to this work. †Drs Saam and Dichgans contributed equally to this work.

**ABBREVIATIONS
AND ACRONYMS****AHA** = American Heart Association**cCAP** = complicated carotid artery plaques**DWI** = diffusion-weighted imaging**FLAIR** = fluid-attenuated inversion recovery**IPH** = intraplaque hemorrhage**MRI** = magnetic resonance imaging**TIA** = transient ischemic attack

Stroke is a leading cause of death and disability and a major cause of cognitive decline.^{1,2} Recurrence rates vary depending on stroke etiology.³⁻⁵ We recently demonstrated a role of complicated (American Heart Association [AHA] lesion type VI) nonstenosing carotid artery plaques (cCAP) as an under-recognized cause of ischemic stroke.^{6,7} Estimates of the risk of recurrent ischemic cerebrovascular events in patients with acute ischemic stroke and cCAP are required to counsel patients and inform prevention trials, but are currently unavailable.

SEE PAGE 2200

cCAP are defined by the presence of a ruptured fibrous cap, intraplaque hemorrhage (IPH), or mural thrombus⁸ and can be accurately and reliably detected by multisequence, black-blood carotid magnetic resonance imaging (MRI) using dedicated surface coils and contrast agent.⁹⁻¹¹ Previous carotid MRI studies in patients with symptomatic carotid artery stenosis have suggested an association between high-risk features of carotid plaques, in particular IPH, and an increased risk of recurrent ischemic stroke or transient ischemic attack (TIA).¹²⁻¹⁵ However, there was substantial delay in these studies between the qualifying event and imaging (>1 month on average),¹²⁻¹⁷ and they might thus not be reflective of the risks associated with cCAP in the acute phase of stroke. Also, these studies included patients selected for the presence of carotid artery stenosis and typically used imaging protocols that do not permit the detection of a ruptured fibrous cap.

To our knowledge, there are no studies that have related the presence of cCAP or IPH as assessed in the first days after stroke to recurrent ischemic stroke or TIA. Such information is needed, particularly for patients with nonstenosing carotid artery plaques and no recognizable cause of stroke (cryptogenic stroke), to optimize strategies for risk prediction and potentially also for stratifying patients into future secondary prevention trials.

To better define the role of cCAP ipsilateral to acute ischemic anterior circulation stroke and the association with recurrent ischemic stroke or TIA, we initiated CAPIAS (Carotid Plaque Imaging in Acute Stroke;

NCT01284933) as a prospective, observational, multicenter study. CAPIAS employed multisequence, contrast-enhanced carotid MRI at 3-T within 10 days from stroke onset using dedicated carotid coils. Baseline results on index events have previously been published.⁷ The current study examined the association of ipsilateral cCAP with recurrent ischemic stroke or TIA over 3 years of follow-up with a particular emphasis on patients with cryptogenic stroke. We further analyzed associations of individual cCAP characteristics (fibrous cap rupture, IPH, mural thrombus) with recurrent ischemic stroke or TIA. Finally, we explored the association of ipsilateral cCAP with new brain lesions in patients undergoing brain MRI at 12 months after the index event. Our pre-specified hypothesis was that recurrent ischemic stroke or TIA would be more frequent in patients with ipsilateral cCAP compared with patients without ipsilateral cCAP.

METHODS

STUDY PARTICIPANTS. CAPIAS is an observational, prospective, multicenter cohort study conducted at 4 tertiary care centers in Germany: Ludwig-Maximilian-University Munich, Technical University Munich, University of Tübingen, and University of Freiburg. The study was approved by the local ethics committees. All participants provided written informed consent. The study design including eligibility criteria have previously been published.^{7,18} In brief, eligible patients were older than 49 years of age, had an acute ischemic stroke within the last 7 days, and had a corresponding unilateral infarct restricted to the territory of a single carotid artery as defined by a diffusion-weighted imaging (DWI)-positive lesion on brain MRI at 3-T. Eligible patients further had unilateral (independent of side) or bilateral carotid artery plaques with a thickness of ≥ 2 mm as determined by duplex ultrasound. Key exclusion criteria were carotid artery stenosis $\geq 70\%$ (NASCET),¹⁹ carotid artery dissection, intracranial atherosclerosis as the presumed stroke etiology, competing etiologies, and incomplete evaluation.⁷ Stroke etiology was classified according to TOAST criteria.^{7,20} The recruitment period was February 2011 to July 2018.

The authors attest they are in compliance with human studies committees and animal welfare regulations of the authors' institutions and Food and Drug Administration guidelines, including patient consent where appropriate. For more information, visit the [Author Center](#).

Manuscript received November 4, 2021; revised manuscript received January 31, 2022, accepted March 21, 2022.

PROCEDURES. All study participants underwent high-resolution, multisequence carotid MRI within 10 days of symptom onset. Imaging was done on 3-T MRI systems using dedicated 4-channel carotid coils and contrast agent as previously described.⁷ Magnetic resonance plaque imaging allows differentiation of specific AHA-lesion types (Table 1). Complicated (AHA-LT VI) carotid artery plaques were assessed on the basis of published criteria (Table 1, Supplemental Table 1).⁸ Patients with incomplete carotid MRI data were excluded, leaving 196 patients for analysis (Figure 1, Supplemental Table 2).⁷ The magnetic resonance plaque imaging results were archived centrally and were not communicated to the study participants or treating physicians.

Patients were followed up through telephone interviews conducted at 3, 12, 24, and 36 months after the index stroke. Assessments were done centrally by qualified investigators. Standardized questionnaires were used to assess new clinical events, medical treatment, and cardiovascular risk factors. If a patient was unable to take part in the interview, the information was obtained from a caregiver or other suitable proxy. Details on the approach used for data ascertainment are described in Supplemental Figure 1. In case of a positive screening for any cerebrovascular outcome event, the information was validated by contacting the hospital, treating neurologist, and general practitioner, in that order.

CLINICAL OUTCOMES. The primary outcome was the composite endpoint of recurrent ischemic stroke or TIA. Secondary outcomes included recurrent ischemic stroke and recurrent ipsilateral ischemic stroke or TIA. Ischemic stroke was defined as an episode of neurological dysfunction caused by focal cerebral infarction as documented by a corresponding DWI-positive lesion on brain MRI. TIA was defined as a transient episode of neurological dysfunction suggestive of focal cerebral ischemia without acute infarction. All information recorded from the patient, their hospital records, their neurological records, their general practice records, and their brain imaging results, were used for the adjudication of outcome events. Outcome events were adjudicated on the basis of clinical records. Adjudication was performed by 2 board-certified stroke experts (D.J. and A.K.), who independently reviewed all available records and were blinded to the plaque imaging data. Ipsilateral ischemic events were defined as any event in the distribution of the symptomatic carotid artery or of uncertain vascular distribution.²¹ Death was classified into cardiovascular death and noncardiovascular death following consensus criteria.²² Patients

TABLE 1 AHA-LT Classification Used for MR Plaque Imaging

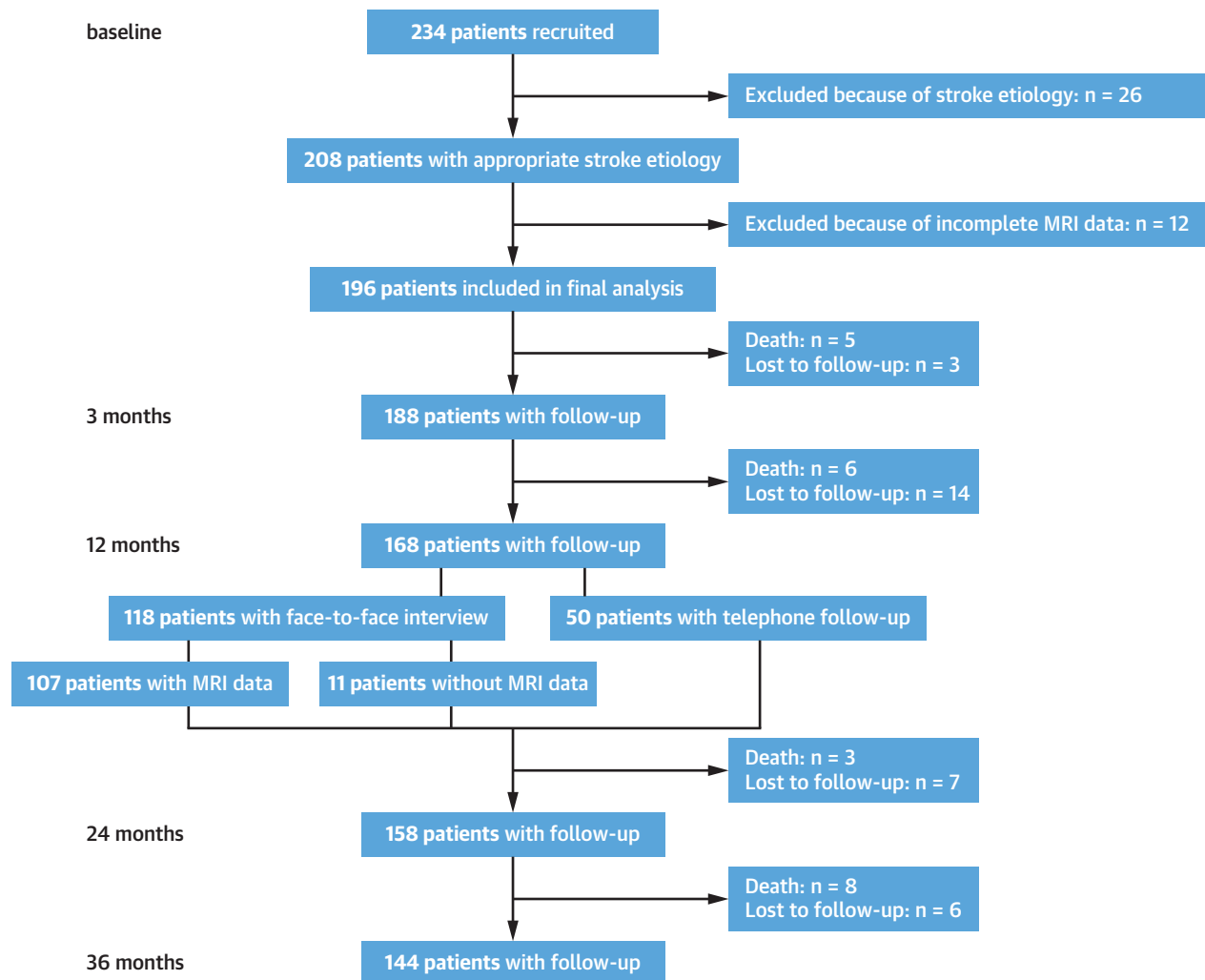
AHA-LT	Definition
AHA-LT I/II	Near-normal wall thickness, no calcification
AHA-LT III	Diffuse intimal thickening or small eccentric plaque, no calcification
AHA-LT IV/V	Plaque with a lipid or necrotic core surrounded by fibrous tissue with possible calcification
AHA-LT VI	Complicated plaque with possible surface defect, hemorrhage, or thrombus
AHA-LT VII	Calcified plaque
AHA-LT VIII	Fibrotic plaque without lipid core and with possible small calcifications

Magnetic resonance (MR) imaging allows for differentiation of the following American Heart Association lesion types (AHA-LT) in carotid arteries: AHA-LT I/II, AHA-LT III, AHA-LT IV/V, AHA-LT VI, AHA-LT VII, and AHA-LT VIII. Modified from Cai et al.⁸

undergoing revascularization were censored at the time of the intervention.

NEW BRAIN LESIONS. Patients were invited for a second brain MRI scan 12 months after stroke for the detection of new brain lesions. Imaging was done on 3-T MRI systems. The core protocol consisted of a 2-dimensional (2D) fluid-attenuated inversion recovery (FLAIR) sequence (repetition time: 7,000-9,000 milliseconds, echo time: 93-136 milliseconds, slice thickness: 3-4 mm). New brain lesions were detected by comparing the follow-up scans to the baseline brain MRI scans, which had been obtained in the context of clinical routine. Scans were independently reviewed by 2 experienced radiologists (A.S. and D.S.) who were blinded to the clinical status. In case of disagreement, a third expert radiologist (T.S.) was consulted and a consensus decision was made. New brain lesions were divided into 3 categories: 1) definitive new ischemic lesion; 2) progression of pre-existing small vessel disease; and 3) new brain lesions that could not be confidently attributed to a specific lesion type.

STATISTICAL ANALYSIS. Incident event rates were calculated as the number of incident events divided by the person-time at risk and expressed as incidence rates per 100 patient years. Kaplan-Meier curves along with log-rank tests were used to depict and test the differences of cumulative event rates between patients with and without ipsilateral cCAP. Analyses started at the time of stroke onset and terminated at the earliest occurrence of an outcome event. Analyses were censored at the time of last available follow-up, revascularization, or death, whichever came first. Multivariable Cox proportional hazards regression was used to estimate HRs with 95% CIs adjusted for age and sex. We added 3 sensitivity analyses: an analysis further correcting for minimal lumen area of both the ipsilateral and contralateral carotid artery as a quantitative measure of stenosis grade; a second analysis further correcting for the presence/absence

FIGURE 1 Study Profile

Study participants were followed up by telephone interviews conducted at 3, 12, 24, and 36 months after stroke. In addition, patients were invited for a second brain MRI scan 12 months after stroke for the detection of new brain lesions. MRI = magnetic resonance imaging.

of contralateral cCAP; and a third analysis further correcting for diabetes, hypertension, and history of myocardial infarction.

Proportional hazards assumptions were checked by inspecting scaled Schoenfeld residuals (all $P > 0.05$). New brain lesions on MRI were compared in patients with and without ipsilateral cCAP using logistic regression adjusted for age and sex. Categorical variables are presented as absolute and relative frequencies; continuous variables are presented as mean \pm SD. Subject characteristics were calculated with Student's *t*-test for numerical variables. Categorical variables were analyzed with chi-square or Fisher exact test. All analyses were performed using

R version 4.1.0 (R Project for Statistical Computing). A P value < 0.05 was considered statistically significant. Because of the exploratory nature of our analysis, P values and 95% CIs presented in this report have not been adjusted for multiplicity.

RESULTS

Among 196 eligible patients with complete carotid MRI data, 104 patients had cryptogenic stroke, 54 had cardioembolic stroke, 19 had large artery stroke, and 19 had small vessel stroke.⁷ In total, 188 patients attended at least 1 follow-up visit, and 144 patients completed the follow-up after 3 years (Figure 1).

A total of 22 patients died (8 cardiovascular deaths, 14 noncardiovascular deaths), and 30 patients were lost to follow-up.

Overall, 56 (29%) patients had ipsilateral cCAP at baseline (Table 2).⁷ In total, 13 patients underwent carotid endarterectomy (9 patients with large artery stroke, 2 with cryptogenic stroke) or stenting (2 with large artery stroke) during follow-up (median interval between the qualifying event and the intervention: 8 days [range 2-478 days]). Their characteristics are shown in Supplemental Table 3.

RECURRENT ISCHEMIC STROKE OR TIA. Overall, 21 patients experienced a recurrent ischemic stroke (n = 16) or TIA (n = 5), and 4 patients had multiple (n ≥1) recurrent events. The incidence rate (3-year interval) for the combined endpoint of recurrent ischemic stroke or TIA was significantly higher in patients with ipsilateral cCAP (9.50 per 100 patient-years) compared with patients without ipsilateral cCAP (3.61 per 100 patient-years; P = 0.025, log-rank test) (Central Illustration). In Cox regression models adjusting for age and sex, ipsilateral cCAP were associated with a 2.5-fold increased risk of recurrent ischemic stroke or TIA over 3 years (HR: 2.51; 95% CI: 1.03-6.11; P = 0.043) (Figure 2). Results remained significant when restricting the analysis to ipsilateral recurrent ischemic stroke or TIA (HR: 3.37; 95% CI: 1.21-9.38; P = 0.020) (Figure 2, Supplemental Figure 2A). Figure 2 further shows the HRs for the isolated endpoint of ischemic stroke, which did not reach statistical significance.

More than one-half of patients with recurrent ischemic stroke or TIA (11 of 21 patients, 52.4%) had been classified as having cryptogenic stroke based on their index stroke. Recurrent ischemic stroke or TIA were significantly more frequent in cryptogenic stroke patients with ipsilateral cCAP (incidence rate [3-year interval]: 10.92 per 100 patient-years) compared with cryptogenic stroke patients without ipsilateral cCAP (1.82 per 100 patient-years; P = 0.003, log-rank test) (Figure 3). In Cox regression models adjusting for age and sex, ipsilateral cCAP were associated with a 5.6-fold increased risk of recurrent ischemic stroke or TIA over 3 years (HR: 5.60; 95% CI: 1.43-21.83; P = 0.013) (Figure 2). Again, results remained significant when focusing on ipsilateral recurrent ischemic stroke or TIA (HR: 5.01; 95% CI: 1.25-20.05; P = 0.023) (Figure 2, Supplemental Figure 2B). Results for patients with other stroke etiologies are shown in Supplemental Table 4.

To account for differences in stenosis grade, we added a sensitivity analysis, further correcting for the minimal lumen area of the ipsilateral and

TABLE 2 Patient Characteristics

	With icCAP (n = 56)	Without icCAP (n = 140)	P Value
Demographic characteristics			
Age, y	73.7 ± 8.4	73.4 ± 10.1	0.859
Male	48 (86)	93 (66)	0.007
NIHSS			
0-5	46 (82)	99 (71)	0.099
6-10	8 (14)	26 (19)	0.474
>10	2 (4)	15 (11)	0.160
Vascular risk factors			
Hypertension	44 (79)	97 (69)	0.191
Hypercholesterolemia	21 (40)	44 (33)	0.316
Diabetes mellitus	13 (24)	31 (22)	0.822
BMI, kg/m ²	27.2 ± 3.6	26.3 ± 3.7	0.114
Current smoker	8 (22)	26 (36)	0.143
Ever smoker	36 (64)	72 (51)	0.102
History of cardiovascular disease			
Coronary heart disease	14 (26)	24 (17)	0.162
Myocardial infarction	6 (11)	17 (12)	0.862
TIA ^a	7 (13)	8 (6)	0.088
Stroke ^a	13 (23)	19 (14)	0.099
Stroke-related interventions			
Thrombolysis	5 (9)	33 (24)	0.022
Thrombectomy	2 (4)	14 (10)	0.162
Carotid plaque imaging			
Time interval from stroke, d	4.3 ± 2.4	4.1 ± 2.1	0.618
Contralateral cCAP	13 (23)	10 (7)	0.002
Ipsilateral min. lumen area, mm ²	12.6 ± 8.0	15.8 ± 7.3	0.009
Contralateral min. lumen area, mm ²	15.7 ± 6.2	16.6 ± 7.9	0.463

Values are mean ± SD or n (%). Baseline characteristics in patients with acute ischemic stroke restricted to the territory of a single carotid artery. Numerical variables were analyzed with Student's *t*-test. For categorical variables, chi-square or Fisher exact test was used. No corrections for multiple testing were applied. P values reaching statistical significance are shown in bold. ^aPrevious to the qualifying event.

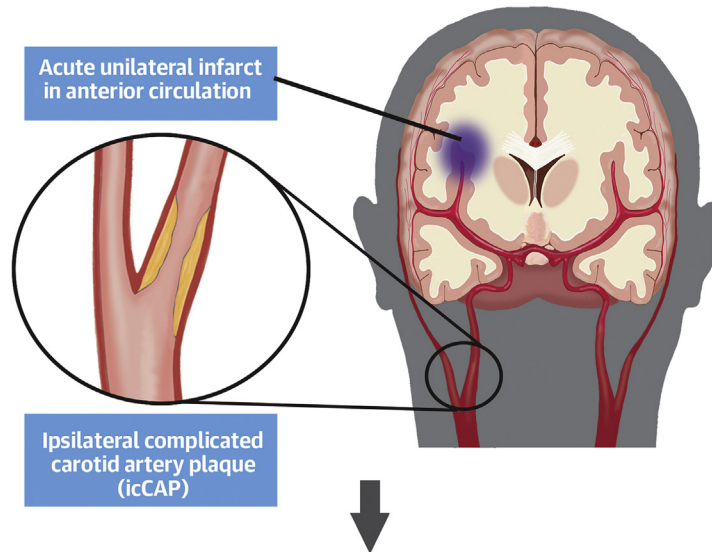
BMI = body mass index; cCAP = complicated carotid artery plaque; icCAP = ipsilateral complicated carotid artery plaque; NIHSS = National Institutes of Health Stroke Scale; TIA = transient ischemic attack.

contralateral carotid artery. The results for recurrent ischemic stroke or TIA remained significant both in the overall cohort and in patients with cryptogenic stroke (Supplemental Table 5). The same was seen in a second sensitivity analysis further correcting for the presence/absence of contralateral cCAP (Supplemental Table 5). Effects were even more pronounced in a third sensitivity analysis additionally adjusting for diabetes, hypertension, and history of myocardial infarction. We also explored associations between the presence of cCAP irrespective of side (ipsilateral, contralateral, or both) and recurrent ischemic stroke or TIA. The associations were attenuated both in the overall cohort (HR: 2.26; 95% CI: 0.93-5.49; P = 0.070) and in patients with cryptogenic stroke (HR: 4.79; 95% CI: 1.20-19.04; P = 0.026).

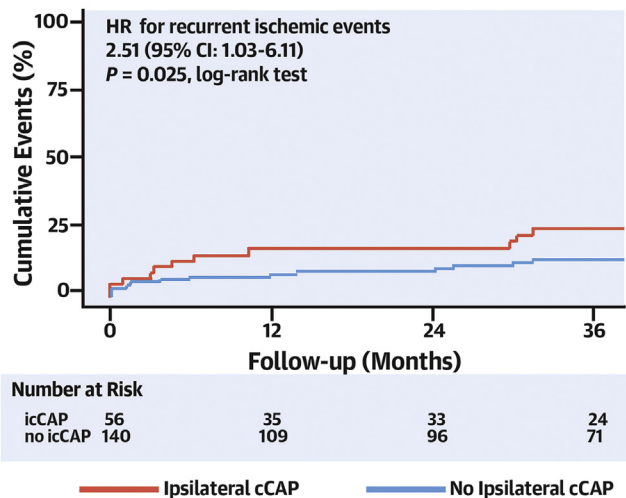
MRI PLAQUE CHARACTERISTICS DEFINING IPSILATERAL cCAP. The associations of individual MRI

CENTRAL ILLUSTRATION Study Concept and Main Study Results

Index Stroke



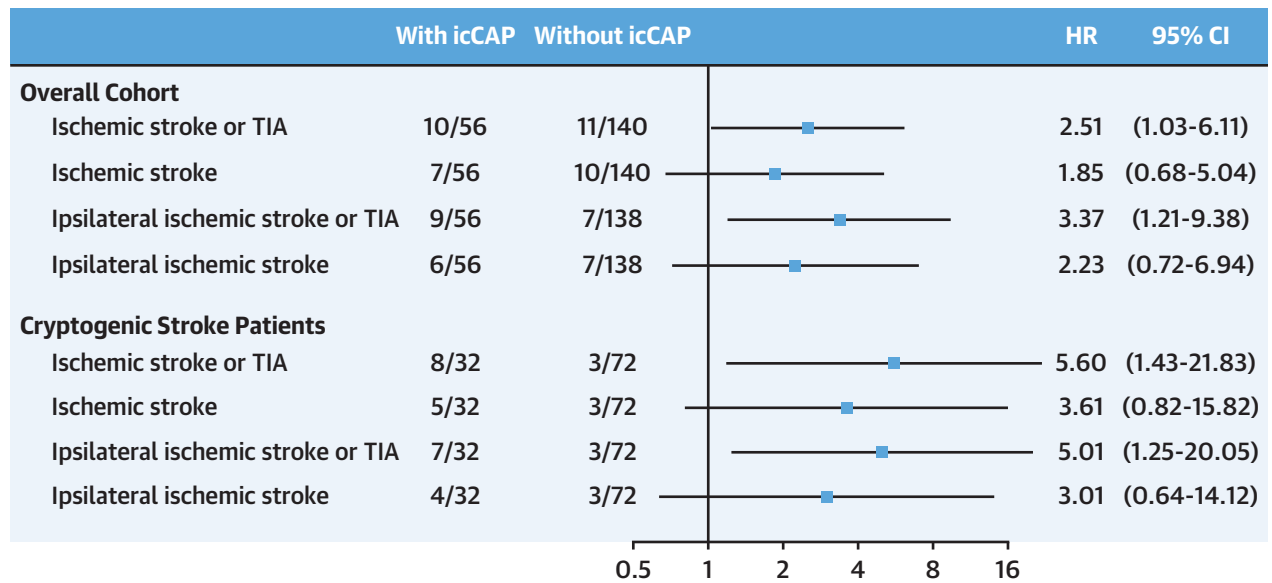
Recurrent Ischemic Stroke or TIA (ipsicontralateral or contralateral)



Kopczak A, et al. *J Am Coll Cardiol.* 2022;79(22):2189-2199.

The prospective CAPIAS (Carotid Plaque Imaging in Acute Stroke) study investigated the association between the presence of complicated carotid artery plaques ipsilateral to acute ischemic anterior circulation stroke and the risk of recurrent ischemic stroke or transient ischemic attack (TIA). Recurrence rates were significantly higher in patients with ipsilateral complicated carotid artery plaques than in patients without ipsilateral complicated carotid artery plaques. Shown are the results for the primary endpoint in the overall study cohort. Ipsilateral complicated carotid artery plaques were associated with a 2.5-fold increased risk of recurrent ischemic stroke or TIA. The results were driven by ipsilateral events.

FIGURE 2 Recurrent Ischemic Stroke or TIA in Patients With icCAP



Shown are the HRs and CIs for the combined primary endpoint of recurrent ischemic stroke and transient ischemic attack (TIA) in patients with ipsilateral complicated carotid artery plaques (icCAP). Also shown are results for ischemic stroke and for ipsilateral ischemic stroke or TIA as secondary endpoints. Results are adjusted for age and sex, without correction for multiple testing, and are displayed separately for the overall cohort and for patients with cryptogenic stroke. Data are n/N.

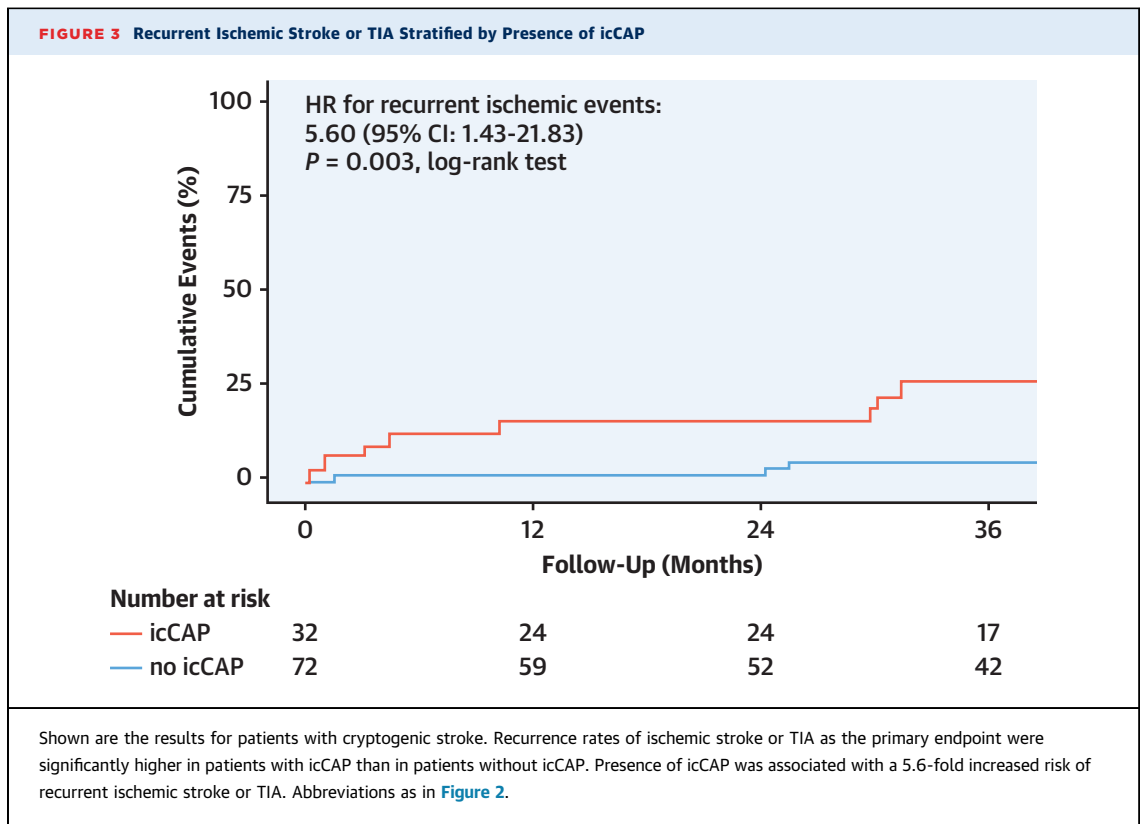
characteristics defining ipsilateral cCAP with risk of recurrent ischemic stroke or TIA are shown in [Table 3](#). Presence of a ruptured fibrous cap at baseline was associated with an increased risk of recurrent ischemic stroke or TIA both in the overall cohort (HR: 2.61; 95% CI: 1.01-7.05; $P = 0.041$) and in patients with cryptogenic stroke (HR: 4.91; 95% CI: 1.31-18.45; $P = 0.018$). Although presence of intraplaque hemorrhage did not reach significance in the overall cohort (HR: 2.34; 95% CI: 0.94-5.81; $P = 0.067$), it was associated with an increased risk of recurrent ischemic stroke or TIA in patients with cryptogenic stroke (HR: 4.37; 95% CI: 1.20-15.97; $P = 0.026$).

NEW BRAIN LESIONS ON 3-T MRI. A total of 118 patients (67 patients with cryptogenic stroke) returned for a face-to-face visit after 12 months. Follow-up brain MRI scans were obtained in sufficient quality in 107 patients ([Figure 1](#)). Reasons for not undergoing brain MRI are detailed in [Supplemental Figure 3](#). New brain lesions were detected in 35 of the 107 study participants with interpretable brain MRI scans. In 16 patients they were classified as definitive new ischemic lesions, in 11 patients they were classified as progression of pre-existing small vessel disease, and in 8 patients they could not be confidently attributed to a

specific lesion type. In total, 6 of the 107 patients with available brain MRI had experienced a recurrent ischemic stroke. In 4 of them, the corresponding brain lesion was still visible on the 12-month follow-up scan, whereas in 2 cases, the lesion was either not detectable or visible only as local atrophy ([Supplemental Figure 4](#)). In 12 patients, the new ischemic lesion was classified as silent ischemic brain infarct. There was no association between ipsilateral cCAP and new brain lesions ($P < 0.05$).

DISCUSSION

This study found ipsilateral cCAP as detected by high-resolution MRI within 10 days from ischemic stroke onset to be associated with a higher risk of recurrent ischemic stroke or TIA. The results were driven by the results in cryptogenic stroke patients and by events ipsilateral to the index stroke. Among patients with cryptogenic stroke, those with ipsilateral cCAP had a 5.6-fold increased risk of recurrent ischemic stroke or TIA when compared with those without ipsilateral cCAP, although the CI was large. We further found the presence of an ipsilateral ruptured fibrous cap and of IPH to be significantly associated with recurrent ischemic stroke or TIA.



The most important finding in terms of clinical implications is the association between IPH and an increased risk of recurrent ischemic stroke or TIA in patients with cryptogenic stroke. Compared with patients without an ipsilateral IPH, those with an ipsilateral IPH had a 4.4-fold increased risk of recurrent ischemic stroke or TIA, although the CI was large. Unlike other cCAP features, IPH can be reliably detected by standard coils and conventional native T₁-weighted sequences,^{10,11,23} implying that MR imaging for IPH detection could be integrated into the diagnostic workflow of anterior circulation stroke, as further suggested by a recent study that ascertained IPH from routine neck MR angiography.²⁴

The prevalence of ipsilateral IPH in our cohort was relatively high (27% of cryptogenic stroke patients, 26% of the overall sample)⁷ similar to a recent study in patients with acute anterior circulation stroke,²⁴ thus further highlighting the potential utility of this marker for risk stratification and the selection of patients into clinical trials. It should be noted, however, that our study participants had been selected for the presence of carotid artery plaque and were rather mildly affected, as reflected by the National Institutes of Health Stroke Scale at baseline. This, together with the relatively large CIs for recurrence rates, emphasizes the need for additional studies. We envision the next

step to be a multicenter study determining the precise prevalence of IPH and associated recurrence rates in unselected patients with anterior circulation stroke. Such a study would enable analyses in relevant subgroups to prepare for future prevention trials.

Treatment options in patients with cryptogenic stroke are limited. The NAVIGATE-ESUS (New Approach Rivaroxaban Inhibition of Factor Xa in a Global Trial versus ASA to Prevent Embolism in Embolic Stroke of Undetermined Source) and RESPECT ESUS (Randomized, Double-Blind, Evaluation in Secondary Stroke Prevention Comparing the Efficacy and Safety of the Oral Thrombin Inhibitor Dabigatran Etexilate versus Acetylsalicylic Acid in Patients with Embolic Stroke of Undetermined Source) trials found no benefit of anticoagulant treatment over aspirin in patients with embolic stroke of undetermined source,^{25,26} leaving these patients with standard antiplatelet therapy. Whether patients with cryptogenic stroke and ipsilateral IPH or other cCAP features would benefit from more intensive medical therapy or carotid interventions is currently unknown. Yet, our results of a substantially increased recurrence risk in cryptogenic stroke patients with cCAP suggest that it is reasonable to think about secondary prevention trials in high-risk patients defined on the basis of carotid plaque imaging.

The association of ipsilateral cCAP with recurrent ischemic stroke or TIA remained significant when controlling for the minimal lumen area, indicating that the association is not confounded by stenosis grade. Less than 10% of the study participants had large artery stroke and a NASCET 50%-69% stenosis. Almost one-half of them underwent carotid revascularization, typically within the first 2 weeks after the index event following contemporary guideline recommendations.^{27,28} These patients were censored with start of the intervention, thus limiting the contribution of patients with large artery stroke to the study results. Notably, 2 patients with cryptogenic stroke and nonstenosing ipsilateral cCAP also received carotid endarterectomy upon judgement of the treating physicians and were thus censored. Still, we found ipsilateral cCAP to be associated with a higher recurrence rate, highlighting the relevance of cCAP in medically treated patients.

The decision to focus on ipsilateral cCAP in our primary analysis was motivated by published data showing a higher risk of ischemic events in symptomatic compared with asymptomatic carotid artery stenosis and previous results from CAPIAS evidencing a causal relationship between ipsilateral cCAP and index events, particularly in patients with cryptogenic stroke.⁷ Lumping ipsilateral and contralateral cCAP into a combined exposure would have implied lumping lesions with potentially different properties and risks. Indeed, associations with recurrent ischemic stroke or TIA were attenuated with the combined exposure in the overall cohort, but given the small number of patients with contralateral cCAP, this observation should be interpreted cautiously. Studies in larger patient cohorts will allow determining the precise risks associated with ipsilateral and contralateral cCAP and the optimal strategy for risk prediction, including in patients with infarcts in multiple vascular territories, who were not represented in CAPIAS.

The association between a ruptured fibrous cap and recurrent ischemic stroke or TIA adds to previous studies in patients with symptomatic or asymptomatic carotid artery stenosis that found thinning or rupture of the fibrous cap to be associated with an increased risk of future stroke or TIA.^{13,15,16} Histopathological studies on carotid endarterectomy samples from patients with symptomatic or asymptomatic stenosis found a ruptured fibrous cap to be associated with symptomatic status^{29,30} and early stroke recurrence before revascularization.³¹ Our current results expand these findings by showing that a ruptured fibrous cap as assessed within the first days after stroke associates with recurrent ischemic stroke or TIA in patients with cryptogenic stroke.

TABLE 3 Association of Individual Plaque Characteristics With Recurrent Ischemic Stroke or TIA

	Recurrent Ischemic Stroke or TIA	
	HR (95% CI)	P Value
Overall cohort		
Ruptured fibrous cap	2.61 (1.01-7.05)	0.041
Intraplaque hemorrhage	2.34 (0.94-5.81)	0.067
Mural thrombus	1.47 (0.55-3.91)	0.443
Cryptogenic stroke patients		
Ruptured fibrous cap	4.91 (1.31-18.45)	0.018
Intraplaque hemorrhage	4.37 (1.20-15.97)	0.026
Mural thrombus	2.89 (0.84-10.01)	0.093

Shown is the association of plaque characteristics defining ipsilateral complicated carotid artery plaques with recurrent ischemic stroke or transient ischemic attack (TIA) as the combined primary endpoint. Multivariable Cox Proportional Hazards regression was used to estimate HRs with 95% CIs for the individual plaque characteristics. Results are adjusted for age and sex, without correction for multiple testing, and displayed separately for the overall cohort and for patients with cryptogenic stroke. P values reaching statistical significance are shown in **bold**.

Due to the widespread clinical use of 2D-FLAIR sequences at the time of study conception, our brain imaging protocol was not optimized for the detection of new brain lesions: baseline scans had been obtained in the context of clinical routine, and the core protocol for follow-up imaging consisted of a simple 2D-FLAIR sequence without harmonization with the baseline scans. Only 55% of the patients returned for study-related brain MRI, which might have introduced bias, and the follow-up interval was relatively short, thus limiting statistical power. Still, our results offer some insights. First, symptomatic infarcts that had been visible at the time of stroke recurrence were not reliably detected on the follow-up scans. Second, new ischemic lesions were often difficult to distinguish from other processes, in particular the progression of small vessel disease. Third, pre-existing white matter hyperintensities, which are common in stroke patients,³² might have masked the detection of new lesions on FLAIR images. Therefore, reliable assessment of the association between cCAP and new brain lesions may require alternative strategies, such as serial imaging with DWI sequences and 3D-FLAIR sequences.³³

STUDY STRENGTHS. CAPIAS was a prospective, multicenter study with imaging confirmed stroke, comprehensive diagnostic work-up, and plaque MRI obtained within 10 days after symptom onset. Sample size by far exceeded that of previous carotid plaque imaging studies employing high-resolution carotid MRI.^{6,34} We used high-resolution carotid MRI at 3-T, dedicated carotid coils, and a standardized multi-sequence imaging protocol including contrast-enhanced sequences,³⁵ thus enabling the assessment of plaque rupture and other plaque features. Analyses

were specified before study onset, and adjudication of endpoints was done centrally by experts blinded to the plaque imaging data.

STUDY LIMITATIONS. Our study also had limitations, in particular, the long recruitment period. This mostly related to our entry criteria and the requirement for a study-related MRI with injection of a contrast agent.⁷ Second, several patients, mostly with a NASCET 50%-69% stenosis, underwent early revascularization and were therefore censored from statistical analysis, although this did not affect the results in cryptogenic stroke patients. Additional limitations included a relatively low proportion of female patients, the limited age range, and the exclusion of patients with CAP <2 mm, which limited the results to stroke patients with some degree of atherosclerosis.

CONCLUSIONS

cCAP ipsilateral to acute ischemic anterior circulation stroke are associated with a substantially increased risk of recurrent ischemic stroke or TIA. Carotid plaque imaging identifies high-risk patients who might be suited for inclusion into future secondary prevention trials.

ACKNOWLEDGMENTS The authors are grateful to all of the staff that collaborated in the CAPIAS study, Marco Duering for advice in brain imaging analysis, and Ulrich Mansmann for advice in statistical analyses.

FUNDING SUPPORT AND AUTHOR DISCLOSURES

This work was supported by the Vascular Dementia Research Foundation and the German Research Foundation (DFG) as part of the Munich Cluster for Systems Neurology (EXC 2145 SyNergy, ID 390857198) and CRC 1123 (B3). Dr Schindler was supported by a grant from the German Research Foundation (DFG) (SCH1 1394/1-1). All other authors have reported that they have no relationships relevant to the contents of this paper to disclose.

ADDRESS FOR CORRESPONDENCE: Dr Martin Dichgans, Institute for Stroke and Dementia Research, University Hospital LMU Munich, Feodor-Lynen-Straße 17, D-81377 Munich, Germany. E-mail: martin.dichgans@med.uni-muenchen.de. Twitter: @ISD_Research.

PERSPECTIVES

COMPETENCY IN MEDICAL KNOWLEDGE: cCAP ipsilateral to acute ischemic anterior circulation stroke are associated with an increased risk of recurrent ischemic stroke or TIA.

TRANSLATIONAL OUTLOOK: In future studies, the presence of cCAP identified by noninvasive imaging could be used to select high-risk patients with prior stroke for clinical trials of novel secondary prevention strategies.

REFERENCES

- GBD 2019 Stroke Collaborators. Global, regional, and national burden of stroke and its risk factors, 1990-2019: a systematic analysis for the Global Burden of Disease Study 2019. *Lancet Neurol*. 2021;20:795-820.
- Pendlebury ST, Rothwell PM. Incidence and prevalence of dementia associated with transient ischemic attack and stroke: analysis of the population-based Oxford Vascular Study. *Lancet Neurol*. 2019;18:248-258.
- Lovett JK, Coull AJ, Rothwell PM. Early risk of recurrence by subtype of ischemic stroke in population-based incidence studies. *Neurology*. 2004;62:569-573.
- Arsava EM, Kim GM, Oliveira-Filho J, et al. Prediction of early recurrence after acute ischemic stroke. *JAMA Neurol*. 2016;73:396-401.
- Rothwell PM, Mehta Z, Howard SC, Gutnikov SA, Warlow CP. Treating individuals 3: from subgroups to individuals: general principles and the example of carotid endarterectomy. *Lancet*. 2005;365:256-265.
- Freilinger TM, Schindler A, Schmidt C, et al. Prevalence of nonstenosing, complicated atherosclerotic plaques in cryptogenic stroke. *J Am Coll Cardiol Img*. 2012;5:397-405.
- Kopczak A, Schindler A, Bayer-Karpinska A, et al. Complicated carotid artery plaques as a cause of cryptogenic stroke. *J Am Coll Cardiol*. 2020;76:2212-2222.
- Cai JM, Hatsukami TS, Ferguson MS, Small R, Polissar NL, Yuan C. Classification of human carotid atherosclerotic lesions with in vivo multi-contrast magnetic resonance imaging. *Circulation*. 2002;106:1368-1373.
- Saam T, Hatsukami TS, Takaya N, et al. The vulnerable, or high-risk, atherosclerotic plaque: noninvasive MR imaging for characterization and assessment. *Radiology*. 2007;244:64-77.
- Saba L, Moody AR, Saam T, et al. Vessel wall-imaging biomarkers of carotid plaque vulnerability in stroke prevention trials: a viewpoint from the Carotid Imaging Consensus Group. *J Am Coll Cardiol Img*. 2020;13:2445-2456.
- Saba L, Saam T, Jäger HR, et al. Imaging biomarkers of vulnerable carotid plaques for stroke risk prediction and their potential clinical implications. *Lancet Neurol*. 2019;18:559-572.
- Schindler A, Schinner R, Altaf N, et al. Prediction of stroke risk by detection of hemorrhage in carotid plaques: meta-analysis of individual patient data. *J Am Coll Cardiol Img*. 2020;13:395-406.
- Kwee RM, van Oostenbrugge RJ, Mess WH, et al. MRI of carotid atherosclerosis to identify TIA and stroke patients who are at risk of a recurrence. *J Magn Reson Imaging*. 2013;37:1189-1194.
- Hosseini AA, Simpson RJ, Altaf N, Bath PM, MacSweeney ST, Auer DP. Magnetic resonance imaging plaque hemorrhage for risk stratification in carotid artery disease with moderate risk under current medical therapy. *Stroke*. 2017;48:678-685.
- Lu M, Peng P, Cui Y, et al. Association of progression of carotid artery wall volume and recurrent transient ischemic attack or stroke: a magnetic resonance imaging study. *Stroke*. 2018;49:614-620.
- Gupta A, Baradaran H, Schweitzer AD, et al. Carotid plaque MRI and stroke risk: a systematic review and meta-analysis. *Stroke*. 2013;44:3071-3077.

17. Saam T, Hetterich H, Hoffmann V, et al. Meta-analysis and systematic review of the predictive value of carotid plaque hemorrhage on cerebrovascular events by magnetic resonance imaging. *J Am Coll Cardiol*. 2013;62:1081-1091.
18. Bayer-Karpinska A, Schwarz F, Wollenweber FA, et al. The carotid plaque imaging in acute stroke (CAPIAS) study: protocol and initial baseline data. *BMC Neurol*. 2013;13:201.
19. Barnett HJ, Taylor DW, Eliasziw M, et al. for the North American Symptomatic Carotid Endarterectomy Trial Collaborators. Benefit of carotid endarterectomy in patients with symptomatic moderate or severe stenosis. *N Engl J Med*. 1998;339:1415-1425.
20. Adams HP Jr, Bendixen BH, Kappelle LJ, et al. Classification of subtype of acute ischemic stroke. Definitions for use in a multicenter clinical trial. TOAST. Trial of Org 10172 in Acute Stroke Treatment. *Stroke*. 1993;24:35-41.
21. European Carotid Surgery Trialists' Collaborative Group. Randomised trial of endarterectomy for recently symptomatic carotid stenosis: final results of the MRC European Carotid Surgery Trial (ECST). *Lancet*. 1998;351:1379-1387.
22. Hicks KA, Mahaffey KW, Mehran R, et al. 2017 cardiovascular and stroke endpoint definitions for clinical trials. *J Am Coll Cardiol*. 2018;71:1021-1034.
23. Brinjikji W, DeMarco JK, Shih R, et al. Diagnostic accuracy of a clinical carotid plaque MR protocol using a neurovascular coil compared to a surface coil protocol. *J Magn Reson Imaging*. 2018;48:1264-1272.
24. Kamel H, Navi BB, Merkler AE, et al. Reclassification of ischemic stroke etiological subtypes on the basis of high-risk nonstenosing carotid plaque. *Stroke*. 2020;51:504-510.
25. Hart RG, Sharma M, Mundl H, et al. Rivaroxaban for stroke prevention after embolic stroke of undetermined source. *N Engl J Med*. 2018;378:2191-2201.
26. Diener HC, Sacco RL, Easton JD, et al. Dabigatran for prevention of stroke after embolic stroke of undetermined source. *N Engl J Med*. 2019;380:1906-1917.
27. Tendera M, Aboyans V, Bartelink ML, et al. ESC guidelines on the diagnosis and treatment of peripheral artery diseases: Document covering atherosclerotic disease of extracranial carotid and vertebral, mesenteric, renal, upper and lower extremity arteries: the Task Force on the Diagnosis and Treatment of Peripheral Artery Diseases of the European Society of Cardiology (ESC). *Eur Heart J*. 2011;32:2851-2906.
28. Brott TG, Halperin JL, Abbara S, et al. 2011 ASA/ACCF/AHA/AANN/AANS/ACR/ASNR/CNS/SAIP/SCAI/SIR/SNIS/SVM/SVS guideline on the management of patients with extracranial carotid and vertebral artery disease: a report of the American College of Cardiology Foundation/American Heart Association Task Force on Practice Guidelines, and the American Stroke Association, American Association of Neuroscience Nurses, American Association of Neurological Surgeons, American College of Radiology, American Society of Neuroradiology, Congress of Neurological Surgeons, Society of Atherosclerosis Imaging and Prevention, Society for Cardiovascular Angiography and Interventions, Society of Interventional Radiology, Society of NeuroInterventional Surgery, Society for Vascular Medicine, and Society for Vascular Surgery. *J Am Coll Cardiol*. 2011;57:e16-e94.
29. Redgrave JN, Lovett JK, Gallagher PJ, Rothwell PM. Histological assessment of 526 symptomatic carotid plaques in relation to the nature and timing of ischemic symptoms: the Oxford plaque study. *Circulation*. 2006;113:2320-2328.
30. Spagnoli LG, Mauriello A, Sangiorgi G, et al. Extracranial thrombotically active carotid plaque as a risk factor for ischemic stroke. *JAMA*. 2004;292:1845-1852.
31. Marnane M, Prendeville S, McDonnell C, et al. Plaque inflammation and unstable morphology are associated with early stroke recurrence in symptomatic carotid stenosis. *Stroke*. 2014;45:801-806.
32. Wen W, Sachdev PS. Extent and distribution of white matter hyperintensities in stroke patients: the Sydney Stroke Study. *Stroke*. 2004;35:2813-2819.
33. Ter Telgte A, Wiegertjes K, Gesierich B, et al. Contribution of acute infarcts to cerebral small vessel disease progression. *Ann Neurol*. 2019;86:582-592.
34. Kamtchum-Tatuene J, Wilman A, Saqqur M, Shuaib A, Jickling GC. Carotid plaque with high-risk features in embolic stroke of undetermined source: systematic review and meta-analysis. *Stroke*. 2020;51:311-314.
35. Saam T, Raya JG, Cyran CC, et al. High resolution carotid black-blood 3T MR with parallel imaging and dedicated 4-channel surface coils. *J Cardiovasc Magn Reson*. 2009;11:41.

KEY WORDS carotid artery, carotid plaque, intraplaque hemorrhage, ischemic stroke, MRI, stroke recurrence

APPENDIX For supplemental tables and figures, please see the online version of this paper.