

RESEARCH ARTICLE

Adult-Onset Neurodegeneration in Nucleotide Excision Repair Disorders (NERD_{ND}): Time to Move Beyond the Skin

Isabell Cordts, MD,^{1*} Demet Önder, MD,^{2,3} Andreas Träschütz, MD,^{4,5} Xenia Kobeleva, MD,^{2,3} Ivan Karin, MD,⁶ Martina Minnerop, MD,^{7,8,9} Peter Koertvelyessy, MD,¹⁰ Saskia Biskup, MD, PhD,¹¹ Stephan Forchhammer, MD,¹² Johannes Binder, MD,¹³ Andreas Tzschach, MD,¹⁴ Frank Meiss, MD,¹⁵ Axel Schmidt, MD,¹⁶ Martina Kreiß, MD,¹⁶ Kirsten Cremer, MD,¹⁶ Martin A. Mensah, MD,^{17,18} Joohyun Park, MD,¹⁹ Maren Rautenberg, PhD,¹⁹ Natalie Deininger, MSc,¹⁹ Marc Sturm, PhD,¹⁹ Paul Lingor, MD,¹ Thomas Klopstock, MD,^{6,20,21} Markus Weiler, MD,²² Franz Marxreiter, MD,^{23,24} Matthis Synofzik, MD,^{4,5} Christian Posch, MD, PhD,^{25,26} Judith Sirokay, MD,²⁷ Thomas Klockgether, MD,^{2,3} Tobias B. Haack, MD,^{19,28} and Marcus Deschauer, MD¹

¹Department of Neurology, Klinikum rechts der Isar, Technical University Munich, Munich, Germany

²Department of Neurology, University Hospital Bonn, Bonn, Germany

³German Center for Neurodegenerative Diseases, Bonn, Germany

⁴Department of Neurodegeneration, Hertie Institute for Clinical Brain Research, University of Tübingen, Tübingen, Germany

⁵German Center for Neurodegenerative Diseases, Tübingen, Germany

⁶Friedrich-Baur-Institute, Department of Neurology, University Hospital of the Ludwig-Maximilians-University (LMU) Munich, Munich, Germany

⁷Institute of Neuroscience and Medicine, Research Centre Jülich, Jülich, Germany

⁸Department of Neurology, Center for Movement Disorders and Neuromodulation, Medical Faculty, Heinrich-Heine University Düsseldorf, Düsseldorf, Germany

⁹Institute of Clinical Neuroscience and Medical Psychology, Medical Faculty, Heinrich-Heine University Düsseldorf, Düsseldorf, Germany

¹⁰Department of Neurology, Campus Benjamin Franklin, Charité-Universitätsmedizin Berlin, Corporate Member of Freie Universität Berlin and Humboldt-Universität zu Berlin, Berlin, Germany

¹¹CeGaT GmbH und Praxis für Humangenetik Tübingen, Tübingen, Germany

¹²Division of Dermatooncology, Department of Dermatology, University of Tübingen, Tübingen, Germany

¹³Zentrum für Nervenheilkunde, Herbolzheim, Germany

¹⁴Institute of Human Genetics, Medical Center-University of Freiburg, Faculty of Medicine, University of Freiburg, Freiburg, Germany

¹⁵Department of Dermatology and Venereology, Medical Center-University of Freiburg, Faculty of Medicine, University of Freiburg, Freiburg, Germany

¹⁶Institute of Human Genetics, University of Bonn, School of Medicine and University Hospital Bonn, Bonn, Germany

¹⁷Institute of Medical Genetics and Human Genetics, Charité-Universitätsmedizin Berlin, Berlin, Germany

¹⁸BIH Biomedical Innovation Academy, Digital Clinician Scientist Program, Berlin Institute of Health at Charité-Universitätsmedizin Berlin, Germany

¹⁹Institute of Medical Genetics and Applied Genomics, University of Tübingen, Tübingen, Germany

²⁰Munich Cluster for Systems Neurology (SyNergy), Munich, Germany

²¹German Center for Neurodegenerative Diseases, Munich, Germany

²²Department of Neurology, Heidelberg University Hospital, Heidelberg, Germany

²³Department of Molecular Neurology, University Hospital Erlangen, Friedrich-Alexander-Universität Erlangen-Nürnberg, Erlangen, Germany

²⁴Center for Rare Diseases (ZSEER), University Hospital Erlangen, Friedrich-Alexander-Universität Erlangen-Nürnberg, Erlangen, Germany

²⁵Department of Dermatology and Allergy, School of Medicine, German Cancer Consortium, Technical University of Munich, Munich, Germany

²⁶Faculty of Medicine, Sigmund Freud University Vienna, Vienna, Austria

²⁷Department of Dermatology and Allergy, University Hospital Bonn, Bonn, Germany

²⁸Centre for Rare Diseases, University of Tübingen, Tübingen, Germany

ABSTRACT: Background: Variants in genes of the nucleotide excision repair (NER) pathway have been associated with heterogeneous clinical presentations ranging

from xeroderma pigmentosum to Cockayne syndrome and trichothiodystrophy. NER deficiencies manifest with photosensitivity and skin cancer, but also developmental delay

This is an open access article under the terms of the [Creative Commons Attribution](#) License, which permits use, distribution and reproduction in any medium, provided the original work is properly cited.

***Correspondence to:** Dr. Isabell Cordts, Department of Neurology, Klinikum rechts der Isar, Technical University Munich, Ismaninger Straße 22, 81675 Munich, Germany. E-mail: isabell.cordts@tum.de

Relevant conflicts of interest/financial disclosures: Nothing to report.

Full financial disclosures and author roles may be found in the online version of this article.

Received: 5 January 2022; **Revised:** 6 March 2022; **Accepted:** 21 March 2022

Published online 14 June 2022 in Wiley Online Library (wileyonlinelibrary.com). DOI: 10.1002/mds.29071

and early-onset neurological degeneration. Adult-onset neurological features have been reported in only a few xeroderma pigmentosum cases, all showing at least mild skin manifestations.

Objective: The aim of this multicenter study was to investigate the frequency and clinical features of patients with biallelic variants in NER genes who are predominantly presenting with neurological signs.

Methods: In-house exome and genome datasets of 14,303 patients, including 3543 neurological cases, were screened for deleterious variants in NER-related genes. Clinical workup included in-depth neurological and dermatological assessments.

Results: We identified 13 patients with variants in *ERCC4* (n = 8), *ERCC2* (n = 4), or *XPA* (n = 1), mostly proven biallelic, including five different recurrent and six novel variants. All individuals had adult-onset progressive neurological deterioration with ataxia, dementia, and

frequently chorea, neuropathy, and spasticity. Brain magnetic resonance imaging showed profound global brain atrophy in all patients. Dermatological examination did not show any skin cancer or pronounced ultraviolet damage.

Conclusions: We introduce NER_{ND} as adult-onset neurodegeneration (_{ND}) within the spectrum of autosomal recessive NER disorders (NERD). Our study demonstrates that NER_{ND} is probably an underdiagnosed cause of neurodegeneration in adulthood and should be considered in patients with overlapping cognitive and movement abnormalities. © 2022 The Authors. *Movement Disorders* published by Wiley Periodicals LLC on behalf of International Parkinson and Movement Disorder Society.

Key Words: NER; ataxia; dementia; UV sensitivity; xeroderma pigmentosum

Nucleotide excision repair (NER) is a mechanism to repair DNA lesions caused by exogenous (eg, ultraviolet [UV] light) or endogenous (eg, reactive oxygen species) sources. Deficiencies of NER proteins caused by biallelic variants in NER-associated genes are responsible for a wide and varied range of cancer and premature aging phenotypes. Typical disorders resulting from deficient NER are xeroderma pigmentosum (XP), trichothiodystrophy (TTD), Cockayne syndrome (CS), and cerebro-oculo-facio-skeletal syndrome, a severe form of CS. A complex genetic and phenotypic architecture has been demonstrated in disorders associated with NER: variants in the same gene can cause multiple phenotypes; conversely, many different genes have been associated with the same clinical presentation. Furthermore, overlapping syndromes with combined clinical hallmarks are frequently observed. In fact, 12 NER genes have been linked to five distinct disease entities and five different overlapping phenotypes, with some genes being associated with greater pleiotropy than others.¹

TTD and CS are debilitating multisystem disorders with cutaneous, neurological, and growth abnormalities. Conversely, XP is characterized by an increased sensitivity to UV radiation-induced skin pigmentation and skin cancers on sun-exposed body parts. Many patients with XP show severe sunburn reactions and blistering on minimal sun exposure in childhood. Other typical findings are freckling-like maculae and telangiectasias, but also premalignant lesions and skin neoplasms, such as basal or squamous cell carcinomas and malignant melanomas.² Approximately 20% of patients with XP are affected by neurological abnormalities of variable severity.³ The neurological signs, including sensorineural deafness, ataxia, microcephaly, and cognitive deficits, usually have a childhood onset⁴ and are associated with shorter survival compared with patients with XP without

neurological degeneration (median age at death, 29 and 37 years, respectively).⁵ Interestingly, a few cases of adult-onset neurological impairment, such as ataxia and a choreiform movement disorder with at least mild cutaneous findings, have been reported, mostly in patients with variants in *ERCC4*^{6–8} and rarely in *ERCC3*,⁹ *ERCC5*,⁹ and *XPA*.^{10,11}

In this study, we identified an isolated neurological disorder with overlapping movement abnormalities and cognitive features in 13 individuals caused by variants in three different NER genes. We introduce the term NER_{ND} for the presented adult-onset neurodegeneration (_{ND}) within the spectrum of nucleotide excision repair disorders (NERD).

Subjects and Methods

Genetic testing and reanalysis of exome and genome data were performed according to the Declaration of Helsinki and approved by the ethical committee of the University of Tübingen (project number 066/2021BO2). All patients agreed to the publication, and written informed consent was obtained from all investigated subjects.

Patients were referred for diagnostic exome or genome sequencing from different neurological centers. Next-generation sequencing (NGS) analyses were performed at the Institute of Medical Genetics and Applied Genomics in Tübingen on genomic DNA from affected patients as previously described.^{12,13} In one patient (identification number [ID] 06), who was seen at the Department of Neurology of the Technical University Munich, genetic testing was performed at CeGaT GmbH earlier. In this study, all exome and genome datasets (n = 14,303) of the Institute of Medical

Genetics and Applied Genomics in Tübingen, including 3543 cases with diseases of the nervous system, were screened for biallelic variants in NER-associated genes. The pathogenicity of the identified variants was determined according to the American College of Medical Genetics and Genomics guidelines.¹⁴ Variant confirmation and carrier testing on available family members were conducted by Sanger sequencing. Primers and PCR conditions are provided on request.

After having obtained the genetic diagnosis, further clinical details were collected at nine different German centers by taking an in-depth medical history and performing an extensive clinical examination, including Scale for the Assessment and Rating of Ataxia for evaluation of ataxia, Unified Huntington's Disease Rating Scale to assess chorea, and Montreal Cognitive Assessment as a screening instrument for cognitive impairment. Routine laboratory tests of peripheral blood and cerebrospinal fluid were performed. In selected patients, neurofilament light chain protein levels were determined in blood. Whenever possible, brain magnetic resonance imaging (MRI), electroencephalography, audiometry, ophthalmological assessment, and dermatological examination were performed as part of the diagnostic workup. Pure-tone audiometry was done using standard methods, and type of hearing loss was classified based on air and bone conduction. Dermatological examination involved a clinical-dermatological examination, including a systematic skin cancer screening. Furthermore, the minimal erythema dose (MED-UVB, mJ/cm²) was determined in selected patients as described previously.¹⁵ Microscopic examination of hair samples from six patients was performed at one center using a Leica DM 3000 microscope according to a standardized technique.¹⁶

Results

Genetic Testing

Genetic and clinical findings are summarized in Table 1. A total of 13 patients, 11 sporadic cases, and 2 siblings with an adult-onset neurological phenotype and variants in NER-associated genes were detected. Of these patients, 12 were identified in our database of 14,303 individuals, containing exome and genome datasets from patients of all disease groups, as well as healthy individuals. At the time of our study, our database contained 3543 patients with "diseases of the nervous system," including both pediatric and adult patients but excluding those patients assigned to the disease group "mental, behavioral or neurodevelopmental disorders." Of these patients, 1206 patients were assigned with the Human Phenotype Ontology (HPO) term "ataxia" (or cerebellar atrophy) and 340 patients with "dementia" (or cognitive impairment). Both HPO terms "ataxia" (or cerebellar atrophy) and "dementia" (or cognitive impairment) have been determined in 139 patients. With regard to these subgroups, the

frequency of our neurological patients with variants in NER-associated genes was 0.4% (n = 12/3386) for all patients with diseases of the nervous system, 1.0% (n = 12/1206) for the subgroup of patients with ataxia, 3.5% (n = 12/340) for dementia, and 8.6% (n = 12/139) for patients assigned to both ataxia and dementia.

All variants detected in our patients were either rare or absent in gnomAD (<https://gnomad.broadinstitute.org/>) and predicted to be deleterious in silico (Supporting Information Table S1). Carrier testing on available family members (families I–III, VI, and IX–XII; see Supporting Information Fig. S1) showed full cosegregation of the identified variants with the clinical status in all families. None of the patients carried additional clinically relevant variants in genes associated with movement disorders, cognitive impairment, or other neurological phenotypes.

Eight patients (IDs 01–08) carried variants in *ERCC4* (NM_005236.3). Seven of these patients (IDs 01–07) harbored the previously reported missense variant c.2395C>T (p.Arg799Trp)¹⁷ in heterozygous state. In two of these seven unrelated patients (IDs 02 and 03), the second variant was the splice variant c.580_584 + 1delCCAAGG (p.?) that has been published in a similarly affected patient, also together with c.2395C>T.⁷ In five patients (IDs 01, 04, 05, 06, and 07), the respective second variant has not previously been described in the literature: the frameshift variant c.1069dup (p.Ile357AsnfsTer3), the frameshift variant c.516_517del (p.Thr173TrpfsTer37), the missense variant c.904G>T (p.Asp302Tyr), the frameshift variant c.1081dupA (p.Met361Asnfs*4), and the missense variant c.2248C>T (p.Arg750Cys). One patient (ID 08) carried the variant c.2248C>T (p.Arg750Cys) in homozygous state.

Variants in *ERCC2* (NM_000400.4) were identified in four patients (IDs 09–12), with all of them carrying the missense variant c.1726G>A (p.Glu576Lys) in heterozygous state. For this variant, which has not been previously described in the literature, a replacement of an evolutionarily highly conserved amino acid is predicted. In two brothers (IDs 09 and 10), the second variant was the truncating deletion c.1703_1704del (p.Phe568TyrfsTer2), which has been reported in a young girl with features of both XP and TTD.¹⁸ Furthermore, this variant has been described several times in heterozygous state in various cancers^{19,20} but was mainly classified as a variant of unclear significance. In two unrelated patients (IDs 11 and 12), the respective second variant was c.2150C>G (in *cis* with c.1381C>G [p.Leu461Val]). It has been shown that c.2150C>G leads to aberrant splicing by activating a cryptic donor splice site, resulting in a deletion of 15 amino acids (p.Val716_Arg730del).²¹ This change has been reported in patients with TTD,^{21–23} XP/CS crossover syndrome,^{24,25} and classical XP.^{26,27} Interestingly, p.Ala717Gly was expressed from the same allele as p.Val716_Arg730del

TABLE 1 Genetic and clinical findings in patients with variants in ERCC4, ERCC2, and XPA

Genetics	Patient 01 Family I	Patient 02 Family II	Patient 03 Family III	Patient 04 Family IV	Patient 05 Family V	Patient 06 Family VI	Patient 07 Family VII	Patient 08 Family VIII	Patient 09 Family IX	Patient 10 Family X	Patient 11 Family XI	Patient 12 Family XII	Patient 13 Family XIII
Gene	ERCC4	ERCC4	ERCC4	ERCC4	ERCC4	ERCC4	ERCC4	ERCC4	ERCC2	ERCC2	ERCC2	ERCC2	XPA
cDNA change	c.1069dup c.2395C>T	c.580_584+ 1delCCTAAGG c.2395C>T	c.580_584+ 1delCCTAAGG c.2395C>T	c.516_517del c.2395C>T	c.904G>T c.2395C>T	c.1081dupA c.2395C>T	c.2248C>T c.2395C>T	c.2248C>T c.2395C>T	c.1726G>A c.1703_1704del	c.1726G>A c.1703_1704del	c.1726G>A c.2150C>G	c.1726G>A c.2150C>G	c.772_785del c.619C>T
Protein change	p.Ile357AsnfsTer3 p.Arg799Trp	p. [?] p.Arg799Trp	p. [?] p.Arg799Trp	p.Thr173TprfsTer37 p.Arg799Trp	p.Arg302Tyr p.Arg799Trp	p.Met361Asnfs*4 p.Arg799Trp	p.Arg750Cys p.Arg750Cys	p.Arg750Cys p.Arg750Cys	p.Glu576Lys p.Phe568TyrfsTer2	p.Glu576Lys p.Val716_Arg730del	p.Glu576Lys p.Val716_Arg730del	p.Glu576Lys p.Val716_Arg730del	p.Arg258TyrfsTer5 p.Arg207Ter
Demographics													
Sex	Female	Male	Male	Female	Female	Female	Male	Male	Male	Female	Female	Female	Female
Age at onset/last examination (y)	54/60	43/48	37/42	44/54	38/57	25/45	60/67	45/53	37/51	38/49	53/61	54/69	41/49
Neurology													
Main syndrome in disease course	Cerebellar syndrome, cognitive impairment, chorea	Cerebellar syndrome, cognitive impairment, chorea	Cerebellar syndrome, cognitive impairment	Chorea, cerebellar syndrome	Cerebellar syndrome, cognitive impairment, chorea	Cognitive impairment, cerebellar syndrome	Chorea, cerebellar syndrome, cognitive impairment	Spastic paraparesis, cerebellar syndrome, cognitive impairment	Cerebellar syndrome, cognitive impairment (FTD-like)	Cerebellar syndrome, cognitive impairment (FTD-like)	Cerebellar syndrome	Cognitive impairment, cerebellar syndrome	Cerebellar syndrome, chorea
Cerebellar syndrome													
Saccadic eye movement	+	+	+	+	+	+	+	+	+	+	+	+	+
Ataxia gait/limb	+/+	+/+	-/+	+/+	+/+	+/+	+/+	+/-	+/+	+/+	+/+	+/+	+/+
Dysarthria	+	+	+	+	+	+	+	+	+	+	+	+	+
SARA score (0–40 points)	15	n/a	10	21	25	11	11	11	15	16.5	11.5	16	18
Cognitive function													
Cognitive impairment	+	+	+	+	+	+	+	+	+	+	+	+	+
Frontal lobe dysfunction	+	+	-	+	+	-	+	+	+	+	-	+	-
MoCA score (0–30 points)	11	20	13	n/a	n/a	22	15	25	16	13	15	18	20
Involuntary movements													
Chorea or motor impersistence	+	+	+	+	+	-	+	+	+	-	-	+	+
UHDRS-TMTSDIR124 (mild)	37	n/a	25	49	38	19	n/a	18	19	24	22	20	20
Athrosis	-	-	+	-	-	-	n/a	-	-	-	-	-	+
Dystonia	-	-	-	+	-	-	-	-	-	+	-	+	+
	-	-	-	-	-	-	-	-	+	+	-	-	-

(Continues)

TABLE 1 Continued

	Patient 01 Family I	Patient 02 Family II	Patient 03 Family III	Patient 04 Family IV	Patient 05 Family V	Patient 06 Family VI	Patient 07 Family VII	Patient 08 Family VIII	Patient 09 Family IX	Patient 10 Family IX	Patient 11 Family X	Patient 12 Family XI	Patient 13 Family XII
Postural tremor (hands)													
Pyramidal signs													
Spasticity	+	-	-	+	+	+	+	+	-	-	+	+	-
Hyperreflexia	+	-	-	+	+	+	+	+	+	+	+	+	-
Sensory impairment													
Impaired tactile sensitivity/vibration or joint position sense	-/+	-/+	-/+	-/+	+/+	-/+	-/+	-/+	-/+	-/+	-/+	-/+	+/+
Peripheral neuropathy	+	+	+	+	+	+	+	n/a	+	+	-	+	
Brain magnetic resonance imaging													
Global cerebral/cerebellar/brain stem atrophy	+/+/+	+/+/+	+/+/+	+/+/+	+/+/+	+/+/+	+/+/+	n/a	+/+/+	+/+/+	+/+/+	+/+/+	+/-/-
Other													
Hearing impairment (subjective)	-	+	+	+	+	+	+	+	+	+	+	+	-
Hearing loss on audiogram* (dB)	24/55	n/a	56/70	n/a	56/65	n/a	66/75	18/53	20/78	31/73	n/a	39/57	13/17
Urinary urgency/incontinence	+	+	+	-	+	-	n/a	-	-	-	+	+	+
Dermatology													
Dermatological examination													
Fitzpatrick skin type	I-II	n/a	II	II	II	II	II	III	III	III	II	II	I-II
Lentiginous pigmentation	+	n/a	+	+	+	+	+	+	-	-	+	-	+
Signs of premature aging	+	n/a	-	n/a	n/a	n/a	-	+	-	-	+	-	-
Telangiectasias	-	n/a	-	+	Rosacea (chin)	n/a	-	+	+	Rosacea (nose)	+	+	+
Premalignant lesions/skin cancer	-/-	n/a	-/-	-/-	-/-	-/-	-/-	Actinic keratosis ^b	-/-	-/-	-/-	-/-	-/-
Reduced MED-LUVB (in mJ/cm ²)	+	n/a	n/a	n/a	n/a	n/a	+	n/a	n/a	n/a	+	+	n/a

*Mean four-frequency (0.5, 1, 2, and 4 kHz) and mean high-frequency (4, 6, and 8 kHz) sensorineural hearing loss indicated for better ear on most recent audiogram.

^bActinic keratosis was suspected, but a skin biopsy for histopathological confirmation could not yet be performed.

FTD, frontotemporal dementia; SARA, Scale for the Assessment and Rating of Ataxia; n/a, not available; MoCA, Montreal Cognitive Assessment; UHDRS-TMS, Unified Huntington's Disease Rating Scale Total Motor Score; db, decibels; MED, minimal erythema dose.

by authentic splicing and was shown to partially rescue the loss of ERCC2 function, resulting in milder manifestations.²⁵

One individual (ID 13) carried biallelic variants in XPA (NM_000380.4): c.619C>T (p.Arg207Ter), which is a common variant in XP²⁸ and has also been reported in a young woman with XP and prominent neurological involvement in *trans* with c.772_785del (p.Arg258TyrfsTer5). The latter has been classified as variant of unclear significance in different cancers^{19,29} but was also reported in a Hungarian family with prominent neurological alterations.¹⁰

Clinical Characteristics (Table 1)

All individuals (n = 7 female and n = 6 male individuals) were alive at the time of the study, with ages at last examination ranging from 42 to 69 (median 53) years. The most common symptoms at onset were gait disturbance (54%, n = 7) and cognitive deficits (54%, n = 7), and disease onset ranged from age 25 to 60 (median 43) years. First neurological diagnoses were (hereditary) ataxia in six (IDs 02, 05, 09–12), choreatic movement disorder/Huntington's disease in two (IDs 01 and 04), an unspecified neurodegenerative syndrome in two (IDs 03, 13), and dementia in two patients (IDs 06 and 07), as well as amyotrophic lateral sclerosis in one patient (ID 08). Neurological signs were slowly progressive over years. At last examination, seven patients (IDs 03 and 06–11) were ambulatory without walking aids, one (ID 13) used walking sticks, four needed a wheeled walker (IDs 01, 04, 05, and 12), and one was wheelchair dependent (ID 02).

Clinical characteristics of each individual patient are listed in Table 1, and a summary of main neurological features and diagnostic findings is provided in Figure 1. The most frequent clinical findings in the course of the disease were a cerebellar syndrome in all patients with saccadic eye movements (100%), gait ataxia (92%, n = 13/13), limb ataxia (92%, n = 12/13), and cerebellar dysarthria (100%), resulting in a mean Scale for the Assessment and Rating of Ataxia score of 15.1 (standard deviation 4.6) points. Cognitive impairment was present in 100%, with a mean Montreal Cognitive Assessment score of 17.1 (standard deviation 4.3) points. Many patients (69%, n = 9/13) showed frontal lobe dysfunction. Involuntary movements ranging from full-blown chorea to rather subtle motor impersistence were present in more than half of the patients (69%, n = 9/13), while dystonia, athetosis, or postural tremor were observed only in individual cases. Furthermore, spasticity, mostly of lower limbs, was observed in 46% (n = 6/13) and hyperreflexia in 62% (n = 8/13) of patients. Some of the patients had signs of parkinsonism with hypomimia, postural instability, bradykinesia, and/or rigidity; however, proper evaluation was made difficult because of concomitant marked spasticity or ataxia. Sensory symptoms were stated by only a few patients (loss of feeling in 15%, n = 2/13). Clinical examination demonstrated sensory impairment in all individuals, and in the majority of patients (83%, n = 10/12), electrophysiological studies showed a mostly mixed axonal-demyelinating sensorimotor neuropathy. MRI of the brain demonstrated profound atrophy in all, mostly with severe global cerebral,

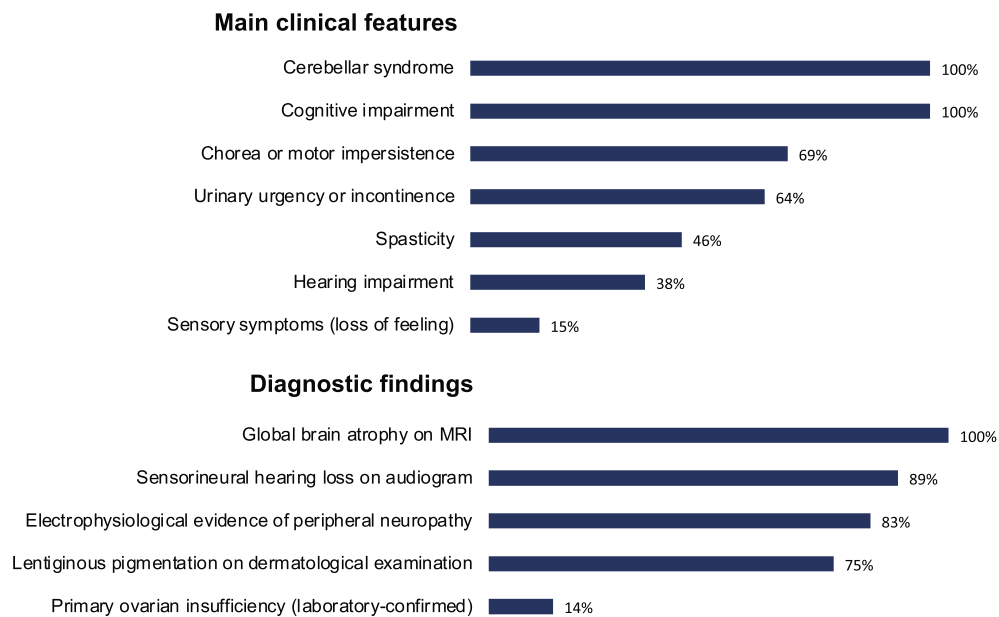


FIG. 1. Overview of the main clinical and diagnostic findings of patients with NERD_{ND} in this study. MRI, magnetic resonance imaging. [Color figure can be viewed at wileyonlinelibrary.com]

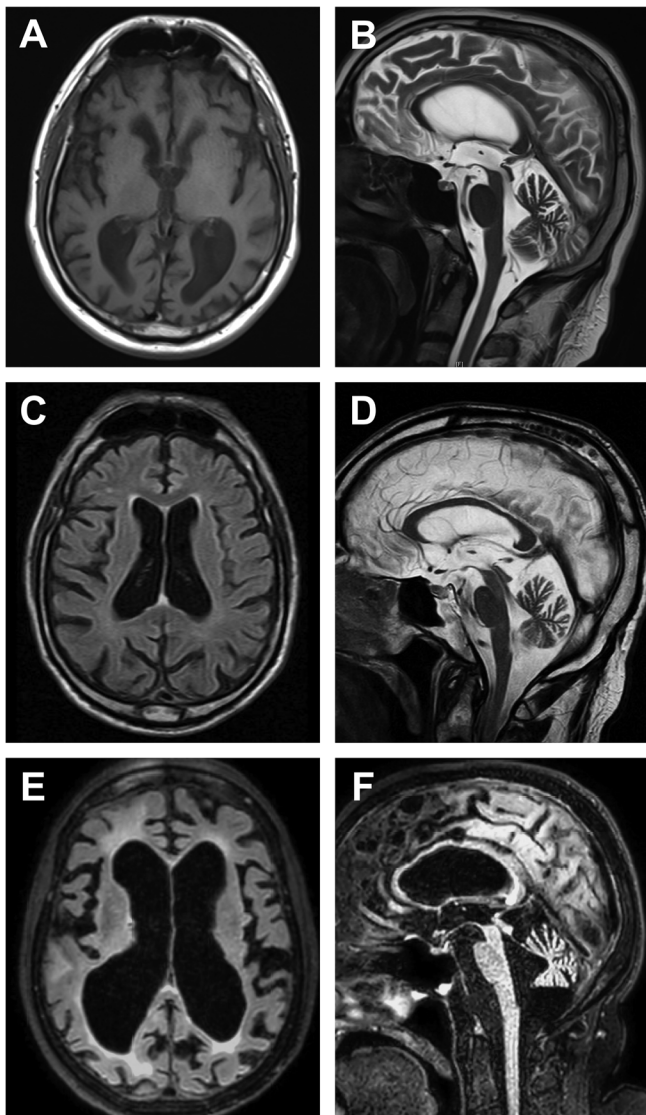


FIG. 2. Representative brain magnetic resonance images showing global cerebral (A, C, E) and infratentorial (B, D, F) atrophy. (A) Patient 10, T1 weighted, axial. (B) Patient 10, T2 weighted, midsagittal. (C) Patient 07, fluid-attenuated inversion recovery (FLAIR), axial. (D) Patient 07, T2 weighted, midsagittal. (E) Patient 01, FLAIR, axial. (F) Patient 01, FLAIR, midsagittal.

cerebellar, and brainstem atrophy (Fig. 2). Hearing impairment was stated by 38% ($n = 5/13$) of patients, four of which used hearing aids. Audiometry showed clinically significant hearing loss, defined as four-frequency (0.5, 1, 2, and 4 kHz) pure-tone average >25 dB sensorineural hearing loss,³⁰ in 56% ($n = 5/9$), and four of these patients reported abnormal hearing problems in daily life. Furthermore, high-frequency (4, 6, and 8 kHz) sensorineural hearing loss was found in three patients without subjective hearing impairment (IDs 01, 08, and 09). Urinary urgency or incontinence was reported by 64% ($n = 7/11$). None of the patients had seizures or relevant abnormalities on electroencephalogram.

Routine laboratory tests of peripheral blood and cerebrospinal fluid showed no specific abnormalities. Neurofilament light chain levels in blood were increased in the four individuals tested (60, 123, 47, and 51 pg/mL in individual IDs 01, 06, 08, and 12, respectively; cutoff value of the reference laboratory: 45 pg/mL, based on Verde et al.³¹).

Extraneurological signs associated with XP were examined whenever possible. In one case (14%, $n = 1/7$, ID 05), primary ovarian insufficiency was diagnosed based on gynecological and laboratory examinations and preceded neurological manifestation about one decade. Premature menopause (before age 40 years³¹) occurred in one woman (ID 06). She had no children, but there were no attempts to get pregnant. One woman (ID 01) had a history of an unfulfilled desire for pregnancy even after in vitro fertilization. There were seven live births in three of the women (see Supporting Information Fig. S1). One patient (ID 06) was diagnosed with hepatocellular carcinoma 20 years after the onset of neurological symptoms. Ocular symptoms such as photophobia or known eye diseases such as ocular surface cancer were not reported in any of the patients. However, a dedicated ophthalmological examination was performed in only four patients, showing a sicca syndrome (IDs 01 and 05), a keratopathy (ID 03), and no abnormalities (ID 04). After having obtained the genetic diagnosis, patients were specifically asked about skin symptoms, and an in-depth dermatological examination was recommended. Patients indicated that none of them had seen a dermatologist in the past for skin problems, in particular, none of the patients had a history of skin cancer. A dermatological examination was performed in 92% ($n = 12/13$). A history of sunburn on rather mild sun exposure, eg, in childhood, was reported by 50% ($n = 6/12$) of patients; however, Fitzpatrick skin type was classified as I/II in all of these individuals. Mild lentiginous pigmentation was stated in 75% ($n = 9/12$; examples are demonstrated in Fig. 3). Signs of premature skin aging, such as atrophy, dryness, wrinkling, or small dilatations of vessels, were seen in 33% ($n = 3/9$) and only in sun-exposed regions. Mild facial telangiectasias or rosacea was present in 55% ($n = 6/11$). None of the patients had skin cancer. In one patient, an actinic keratosis was suspected, but a skin biopsy for histopathological confirmation could not yet be performed. Overall, the patients' skin changes were classified as corresponding to age and Fitzpatrick skin type. However, MED was tested in three patients and showed values that correspond to increased light sensitivity. Fragile, brittle hair was not observed in any of the patients, and polarized light microscopic examination of hair shafts did not show any structural abnormalities or the tiger tail banding pattern typical of TTD ($n = 6/13$ analyzed; IDs 05, 07, 09, 10, 12, and 13).

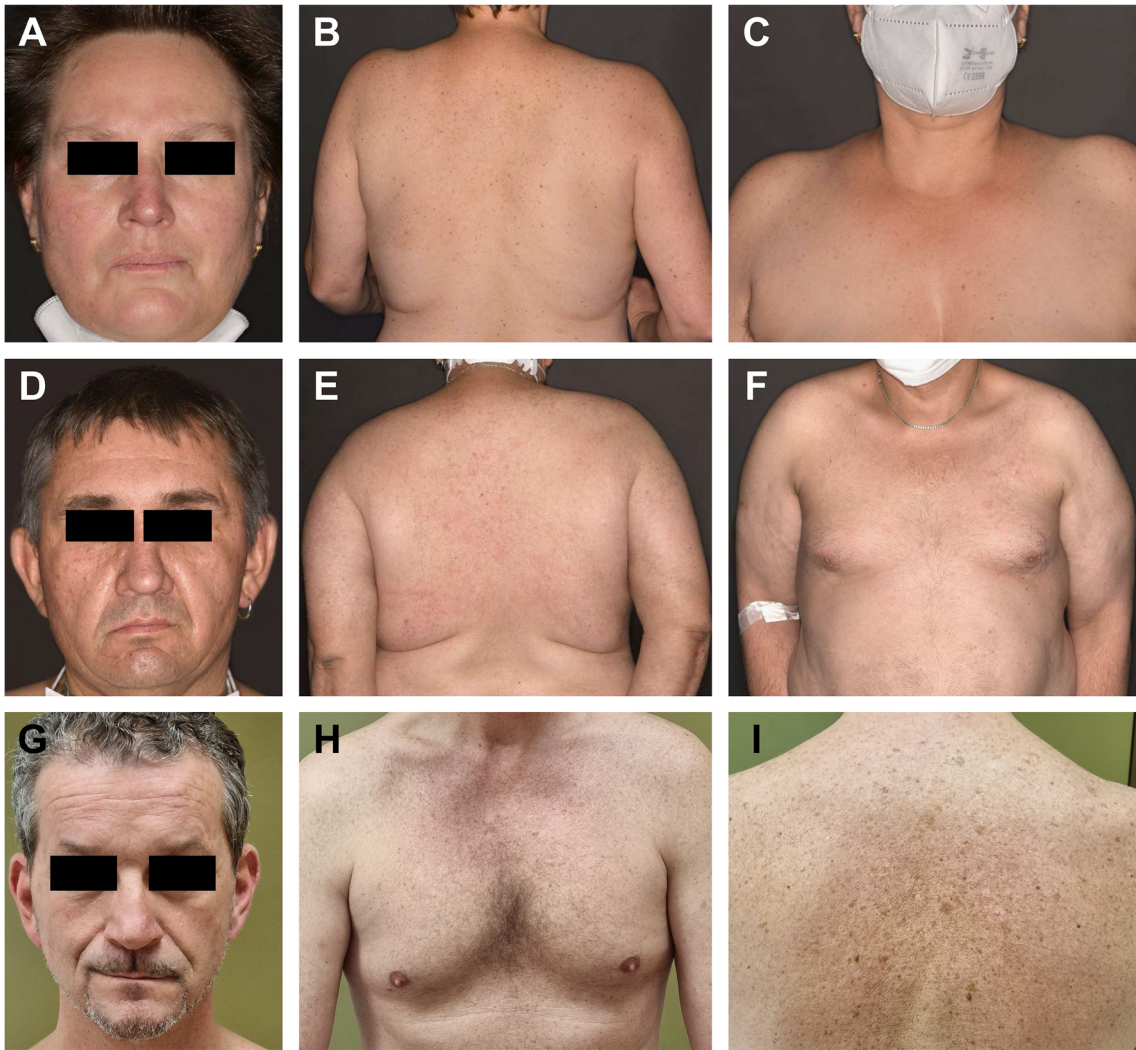

FIG. 3. Exemplary illustration of skin changes in three patients with NERD_{ND}. Patient 13 presents with mild telangiectasias on her cheeks and nose (A). She had mild lentiginous pigmentation on the back, shoulders, and upper arms (B), as well as on the décolleté (C). Patient 03 shows mild facial freckling (D), as well as subtle freckles on the upper body (E, F). Patient 08 demonstrates mild facial telangiectasias (G). There was lentiginous pigmentation on the upper body, but also some areas with hypopigmentation (H, I). [Color figure can be viewed at wileyonlinelibrary.com]

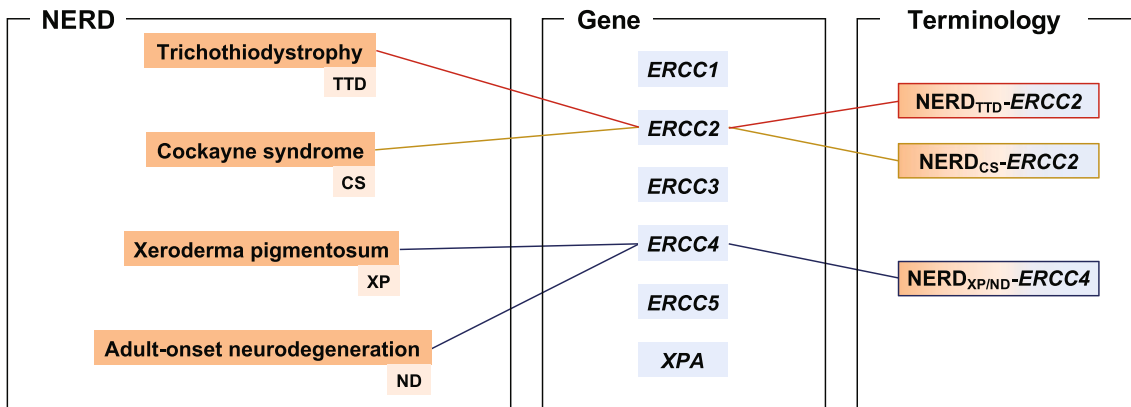


FIG. 4. Novel modular classification system for nucleotide excision repair disorders (NERD). Representative of the many phenotypes and NER genes, four examples of typical NER-related clinical conditions and six major pleiotropic genes are illustrated. The respective disease name is a composite of the umbrella term NERD, the main phenotype(s), and the disease-causing gene. This nomenclature allows to assign more than one phenotype to a gene, eg, NERD_{TTD}-ERCC2 (red line) or NERD_{CS}-ERCC2 (brown line), and to unite coexisting phenotypes, eg, NERD_{XP/ND}-ERCC4 (blue line). [Color figure can be viewed at wileyonlinelibrary.com]

Novel Modular Classification System for NERD

We introduce a new modular classification system (Fig. 4) to address the many different and often overlapping subtypes of NERD. The proposed systematic terminology includes (1) the umbrella term “NERD,” (2) the major phenotype(s), and (3) the disease-causing gene. This nomenclature allows not only to assign more than one phenotype to a gene (eg, NERD_{TTD}-*ERCC2* or NERD_{CS}-*ERCC2*) but also to unite coexisting phenotypes (NERD_{XP/ND}-*ERCC4*). The classification system is illustrated in Figure 4 for four typical NER-related conditions, as well as six major pleiotropic NER genes, based on former observations¹ and this study. It can be extended to any other NER-associated phenotypes and genes already reported or possibly being discovered in the future.

Discussion

We present NERD_{ND} as adult-onset neurodegeneration with overlapping movement and cognitive features within the various disease manifestations of NER deficiencies. This is the largest series of patients with variants in NER genes and a primarily neurological phenotype to date.

Within our genetic database the frequency of NERD_{ND} was 1% for all patients with ataxia, 3.5% for all patients with a cognitive impairment, and 8.6% for individuals assigned to both ataxia and dementia. However, these numbers refer to our “real-world” genetic database and have to be interpreted with caution in estimating frequency of NERD_{ND}. First, the groups are not representative of all (hereditary) ataxias or dementias, because in many of these patients, exome/genome sequencing was performed only after more common genetic causes had been previously ruled out, eg, by single-gene/gene panel analyses or repeat expansion detection assays. Second, not all patients are regularly assigned to all applicable HPO terms. One reason is that not all clinical findings are already present at the time when the genetic diagnosis is initiated but evolve later in the course of the disease. Moreover, less pronounced clinical features are not always communicated by the referring clinician, eg, cognitive impairment, when more prominent findings such as chorea or ataxia are leading. Nevertheless, NERD_{ND} is likely to be more frequent than previously assumed among hereditary causes of neurodegeneration in adulthood. NERD_{ND} should be considered in patients with cognitive impairment and overlapping movement abnormalities, such as cerebellar signs, or chorea, especially in case of additional diagnostic findings, including global brain atrophy, sensorineural hearing loss, peripheral neuropathy, UV sensitivity, or premature

menopause. Clinicians should keep in mind that some symptoms, eg, hearing impairment or sensory symptoms, are not reported by patients because of cognitive deficits.

The remarkably complex phenotype–genotype relationship of NERD, with, on the one hand, the same gene being linked to different clinical entities and, on the other hand, variants in distinct genes resulting in the same phenotype, is most likely explained by the multifunctional nature of the NER system. Besides the main NER pathways of global genomic repair and transcription-coupled repair of damage, NER factors are also involved in other DNA repair mechanisms, posttranslational modifications, and crosstalk with other cellular processes.^{1,32} However, the exact reasons for neurodegeneration are poorly understood. Growing evidence supports the relevance of alterations in oxidative damage repair leading to endogenous DNA lesions in NERD. Certain types of oxidative damage, such as cyclopurines, can be repaired only by NER and are therefore thought to accumulate over time in terminally differentiated postmitotic cells such as neurons. Furthermore, a pathophysiology beyond the impaired repair of DNA lesions, including mitochondrial dysfunction or non-DNA repair–related oxidative stress, has been suggested to play a role in the pathogenesis of ND in XP.^{33,34}

Few single patients with variants in *ERCC4* presenting with an adult-onset neurological deterioration syndrome have recently been documented. The clinical features reported were very similar compared with the neurological phenotype described in the study herein, with ataxia, cognitive decline, chorea, and neuropathy being the cardinal signs. However, although rather inconspicuous in some patients, all of the reported individuals presented with skin manifestations, mostly photosensitivity, skin freckling, and/or skin neoplasms.^{6–8,35–37,39} In patients with XP with variants in *XPA*, severe and childhood-onset neurological abnormalities with developmental delay, microcephaly, and cerebellar dysfunction beyond the dermatological findings are well known.^{4,36} Interestingly, individual families with neurological abnormalities and only discrete skin manifestations have also been reported.^{10,11} Patients with variants in *ERCC2* have been associated with TTD, cerebro-oculo-facio-skeletal syndrome, as well as XP with typical dermatological signs and sometimes also accompanying abnormalities of the central nervous system.³⁶ However, an adult-onset neurodegenerative syndrome as in our patients has, to the best of our knowledge, not been reported for *ERCC2* to date.

In this study, sensorineural hearing loss was identified in 89% of the patients examined and not always corresponded to patient-reported hearing impairment, possibly also because of concomitant dementia. Given the high frequency of hearing impairment among patients

with defects in DNA repair, even being a predictor of neurological degeneration in patients with XP and correlating with neurological decline,⁴⁰ clinicians should be aware, initiate early audiometric testing, and recommend hearing aids if needed. Premature menopause, a feature of premature aging, has been reported in almost one third of patients with XP, mostly with variants in *XPC* and *ERCC2*, and primary ovarian insufficiency was frequently diagnosed.³² In our study, primary ovarian insufficiency was documented in one patient and premature menopause and an unfulfilled desire for pregnancy were stated in one further woman, respectively. Interestingly, these women carried variants in *ERCC4*.

Interestingly, six of our seven patients with variants in *ERCC4* share the same missense variant p.Arg799Trp, which is a frequent variant¹⁷ that has been reported in patients with a neurological phenotype either in a homozygous^{6,7,36,39} or in a compound heterozygous state.^{6–8,37,39} A similarly affected patient harbored the same variant in *trans* with the splice variant c.580_584 + 1delCCAAGG,⁷ which was detected in two of our patients as well. Furthermore, two of our patients with variants in *ERCC4* carry the novel missense variant p.Arg750Cys, one in heterozygous state and the other homozygously. Similarly, all of our individuals with variants in *ERCC2* harbored the novel missense variant p.Glu576Lys, in two unrelated cases *in trans* with p.Val716_Arg730del. Finally, both variants in *XPA* detected in our patient, p.Arg207Ter and p.Arg258TyrfsTer5, have previously been reported in patients with prominent neurological features.¹⁰ We hereby demonstrate that such recurrent variants, likely being attributed to a mutational hot spot, can occur more frequently than anticipated in rare diseases and should not be missed when interpreting NGS data. Interestingly, specific genotype–phenotype correlations have been demonstrated in *XPA*-associated XP with patients carrying variants closer to the C-terminal coding region of *XPA* having milder neurological and cutaneous findings.^{41,42} Uncovering further genotype–phenotype correlations could be an important part to understanding the phenotypic variability within the different entities of NERD.

In contrast with the previously reported cases with predominant neurological impairment who all showed at least mild skin manifestations, the patients in our study had a freckling in UV-exposed regions, but no clear pathological skin involvement at the time of dermatological assessment. These differences in the extent of dermatological involvement even in patients sharing the same genetic change might be explained by additional influencing factors, such as differences in transcriptional regulations. Furthermore, UV damage is relevantly influenced by sun exposure and the use of sun protection. Therefore, the variable skin involvement observed between studies might also be because of

differences in lifetime UV exposure, possibly shaped by personal or cultural circumstances. Nevertheless, a certain UV sensitivity is probably present even in patients without obvious anamnestic or clinical evidence of skin involvement, which is supported by the reduced MED in our three tested patients.

Because variant interpretation of NGS data is fundamentally reliant on accurate annotation of phenotypes in databases such as Human Gene Mutation Database and Online Mendelian Inheritance in Man, it is crucial to know and define exact phenotypes. However, the predominantly neurological phenotype in patients with NER defects presented in this article and in previous case reports is currently referred to as XP (eg, XP with Huntington disease-like features¹). For severely neurologically affected patients, the nomenclatural assignment of their disease to a dermatological condition seems inappropriate and in the era of genetic diagnostics not up to date. The challenge of different phenotypes co-occurring in patients sharing the same genetic change, but also various genes being associated to distinct phenotypes as “extreme ends” of a disease continuum, has already been identified, eg, in other movement disorders such as ataxia and spasticity.⁴² Furthermore, diseases should be defined based on the responsible gene or pathway to allow an unbiased approach of phenotyping and also because gene-based nosology best aligns with the discovery of genotype-targeted treatments. Therefore, we introduce a systematic nomenclature for NER-associated disorders (Fig. 4), similar to the classification of genetically determined movement disorders recommended by the International Parkinson and Movement Disorder Society Task Force.⁴³

Our study expands the spectrum of NERD and demonstrates that NERD_{ND} is a probably underdiagnosed cause in adult neurological patients with a combined cognitive and movement disorder and a suspected hereditary etiology. Therefore, genetic defects in *ERCC2*, *ERCC3*, *ERCC4*, *ERCC5*, and *XPA* should not be missed in these patients, and additional NER genes will possibly be associated with NERD_{ND} in the future. The provided detailed clinical description from a neurological point of view can help clinicians to recognize this disorder and allow specialized patient care, including targeted symptomatic therapy of, eg, chorea and spasticity. Although skin manifestations can be inconspicuous, patients might have a subtle UV sensitivity and should ensure appropriate prophylaxis to prevent skin neoplastic complications. Further studies are needed to understand the molecular background behind ND and evaluate treatment strategies. ■

Acknowledgments: All authors thank the patients for their participation and consent to the publication. We are grateful to our colleagues of the Department of Diagnostic and Interventional Neuroradiology, Klinikum rechts der Isar, for providing the MRI images. Work on this project by M. Synofzik and A. Träschütz was supported by grant 779257 “Solve-RD” from the Horizon 2020 research and innovation programme. Open Access funding enabled and organized by Projekt DEAL.

Data Availability Statement

The data that support the findings of this study are available from the corresponding author upon reasonable request.

References

- Ferri D, Orioli D, Botta E. Heterogeneity and overlaps in nucleotide excision repair disorders. *Clin Genet* 2020;97(1):12–24.
- Moriwaki S, Kanda F, Hayashi M, et al. Xeroderma pigmentosum clinical practice guidelines. *J Dermatol* 2017;44(10):1087–1096.
- Nouspikel T. Nucleotide excision repair and neurological diseases. *DNA Repair* 2008;7(7):1155–1167.
- Anttinen A, Koulu L, Nikoskelainen E, et al. Neurological symptoms and natural course of xeroderma pigmentosum. *Brain* 2008;131(8):1979–1989.
- Bradford PT, Goldstein AM, Tamura D, et al. Cancer and neurologic degeneration in xeroderma pigmentosum: long term follow-up characterises the role of DNA repair. *J Med Genet* 2011;48(3):168–176.
- Doi H, Koyano S, Miyatake S, et al. Cerebellar ataxia-dominant phenotype in patients with ERCC4 mutations. *J Hum Genet* 2018;63(4):417–423.
- Carré G, Marelli C, Anheim M, et al. Xeroderma pigmentosum complementation group F: a rare cause of cerebellar ataxia with chorea. *J Neurol Sci* 2017;376:198–201.
- Shanbhag NM, Geschwind MD, DiGiovanna JJ, et al. Neurodegeneration as the presenting symptom in 2 adults with xeroderma pigmentosum complementation group F. *neurology. Genetics* 2018;4(3):e240.
- Garcia-Moreno H, Fassih H, Sarkany RP, et al. Xeroderma pigmentosum is a definite cause of Huntington's disease-like syndrome. *Ann Clin Transl Neurol* 2018;5(1):102–108.
- Zádori D, Szpisjak L, Németh IB, et al. Predominant neurological phenotype in a Hungarian family with two novel mutations in the XPA gene—case series. *Neurol Sci* 2020;41(1):125–129.
- Messaoud O, Ben Rekaya M, Kefi R, et al. Identification of a primarily neurological phenotypic expression of xeroderma pigmentosum complementation group a in a Tunisian family. *Br J Dermatol* 2010;162(4):883–886.
- Fritzen D, Kuechler A, Grimmel M, et al. De novo FBXO11 mutations are associated with intellectual disability and behavioural anomalies. *Hum Genet* 2018;137(5):401–411.
- Haack TB, Hogarth P, Krueger MC, et al. Exome sequencing reveals de novo WDR45 mutations causing a phenotypically distinct, X-linked dominant form of NBIA. *Am J Hum Genet* 2012;91(6):1144–1149.
- Richards S, Aziz N, Bale S, et al. Standards and guidelines for the interpretation of sequence variants: a joint consensus recommendation of the American College of Medical Genetics and Genomics and the Association for Molecular Pathology. *Genet Med* 2015;17(5):405–423.
- Welti M, Ramelyte E, Dummer R, Imhof L. Evaluation of the minimal erythema dose for UVB and UVA in context of skin phototype and nature of photodermatosis. *Photodermatol Photoimmunol Photomed* 2020;36(3):200–207.
- Liang C, Kraemer KH, Morris A, et al. Characterization of tiger tail banding and hair shaft abnormalities in trichothiodystrophy. *J Am Acad Dermatol* 2005;52(2):224–232.
- Pugh J, Khan SG, Tamura D, et al. Use of big data to estimate prevalence of defective DNA repair variants in the US population. *JAMA Dermatol* 2019;155(1):72–78.
- Broughton BC, Berneburg M, Fawcett H, et al. Two individuals with features of both xeroderma pigmentosum and trichothiodystrophy highlight the complexity of the clinical outcomes of mutations in the XPD gene. *Hum Mol Genet* 2001;10(22):2539–2547.
- Huang K-I, Mashl RJ, Wu Y, et al. Pathogenic germline variants in 10,389 adult cancers. *Cell* 2018;173(2):355–370.e314.
- Maxwell KN, Hart SN, Vijai J, et al. Evaluation of ACMG-guideline-based variant classification of cancer susceptibility and non-cancer-associated genes in families affected by breast cancer. *Am J Hum Genet* 2016;98(5):801–817.
- Takayama K, Danks DM, Salazar EP, Cleaver JE, Weber CA. DNA repair characteristics and mutations in the ERCC2 DNA repair and transcription gene in a trichothiodystrophy patient. *Hum Mutat* 1997;9(6):519–525.
- Zhou X, Khan SG, Tamura D, et al. Abnormal XPD-induced nuclear receptor transactivation in DNA repair disorders: trichothiodystrophy and xeroderma pigmentosum. *Eur J Hum Genet* 2013;21(8):831–837.
- Orioli D, Compe E, Nardo T, et al. XPD mutations in trichothiodystrophy hamper collagen VI expression and reveal a role of TFIID in transcription derepression. *Hum Mol Genet* 2013;22(6):1061–1073.
- Fujimoto M, Leech SN, Theron T, et al. Two new XPD patients compound heterozygous for the same mutation demonstrate diverse clinical features. *J Invest Dermatol* 2005;125(1):86–92.
- Horibata K, Kono S, Ishigami C, et al. Constructive rescue of TFIID instability by an alternative isoform of XPD derived from a mutated XPD allele in mild but not severe XP-D/CS. *J Hum Genet* 2015;60(5):259–265.
- Taylor EM, Broughton BC, Botta E, et al. Xeroderma pigmentosum and trichothiodystrophy are associated with different mutations in the XPD (ERCC2) repair/transcription gene. *Proc Natl Acad Sci U S A* 1997;94(16):8658–8663.
- Takayama K, Salazar EP, Lehmann A, Stefanini M, Thompson LH, Weber CA. Defects in the DNA repair and transcription gene ERCC2 in the cancer-prone disorder xeroderma pigmentosum group D. *Cancer Res* 1995;55(23):5656–5663.
- Satokata I, Tanaka K, Miura N, et al. Three nonsense mutations responsible for group a xeroderma pigmentosum. *Mutat Res* 1992;273(2):193–202.
- Salomao RPA, Pedroso JL, Barsottini OG. Neurological manifestations of xeroderma pigmentosum due to XPA gene mutation. *BMJ Publishing Group Ltd* 2018;18(6):489–491.
- Waszak SM, Northcott PA, Buchhalter I, et al. Spectrum and prevalence of genetic predisposition in medulloblastoma: a retrospective genetic study and prospective validation in a clinical trial cohort. *Lancet Oncol* 2018;19(6):785–798.
- Olusanya BO, Davis AC, Hoffman HJ. Hearing loss grades and the international classification of functioning, disability and health. *Bull World Health Organ* 2019;97(10):725.
- Verde F, Steinacker P, Weishaupt JH, et al. Neurofilament light chain in serum for the diagnosis of amyotrophic lateral sclerosis. *J Neurol Neurosurg Psychiatry* 2019;90(2):157–164.
- Merideth M, Tamura D, Angra D, et al. Reproductive health in xeroderma pigmentosum: features of premature aging. *Obstet Gynecol* 2019;134(4):814.
- Marteijn JA, Lans H, Vermeulen W, Hoeijmakers JH. Understanding nucleotide excision repair and its roles in cancer and ageing. *Nat Rev Mol Cell Biol* 2014;15(7):465–481.
- Abeti R, Zeitlberger A, Peelo C, et al. Xeroderma pigmentosum: overview of pharmacology and novel therapeutic strategies for neurological symptoms. *Br J Pharmacol* 2019;176(22):4293–4301.
- Krasikova Y, Rechkunova N, Lavrik O. Nucleotide excision repair: from molecular defects to neurological abnormalities. *Int J Mol Sci* 2021;22(12):6220.
- Sijbers AM, van Voorst Vader PC, Snoek JW, Raams A, Jaspers NG, Kleijer WJ. Homozygous R788W point mutation in the XPF gene of a patient with xeroderma pigmentosum and late-onset neurologic disease. *J Invest Dermatol* 1998;110(5):832–836.
- Fassih H, Sethi M, Fawcett H, et al. Deep phenotyping of 89 xeroderma pigmentosum patients reveals unexpected heterogeneity dependent on the precise molecular defect. *Proc Natl Acad Sci U S A* 2016;113(9):E1236–E1245.
- Ahmad A, Enzlin JH, Bhagwat NR, et al. Mislocalization of XPF-ERCC1 nuclease contributes to reduced DNA repair in XP-F patients. *PLoS Genet* 2010;6(3):e1000871.
- Imoto K, Boyle J, Oh K, et al. Patients with defects in the interacting nucleotide excision repair proteins ERCC1 or XPF show xeroderma

- pigmentosum with late onset severe neurological degeneration. *J Invest Dermatol* 2007;127:S92.
41. Totonchy MB, Tamura D, Pantell MS, et al. Auditory analysis of xeroderma pigmentosum 1971–2012: hearing function, sun sensitivity and DNA repair predict neurological degeneration. *Brain* 2013; 136(1):194–208.
 42. Messaoud O, Rekaya MB, Ouragini H, et al. Severe phenotypes in two Tunisian families with novel XPA mutations: evidence for a correlation between mutation location and disease severity. *Arch Dermatol Res* 2012;304(2):171–176.
 43. Takahashi Y, Endo Y, Sugiyama Y, et al. XPA gene mutations resulting in subtle truncation of protein in xeroderma pigmentosum group a patients with mild skin symptoms. *J Invest Dermatol* 2010; 130(10):2481–2488.
 44. Synofzik M, Schüle R. Overcoming the divide between ataxias and spastic paraplegias: shared phenotypes, genes, and pathways. *Mov Disord* 2017;32(3):332–345.
 45. Marras C, Lang A, van de Warrenburg BP, et al. Nomenclature of genetic movement disorders: recommendations of the international Parkinson and movement disorder society task force. *Mov Disord* 2016;31(4):436–457.

Supporting Data

Additional Supporting Information may be found in the online version of this article at the publisher's web-site.