

# Inner retinal layer thinning in radiologically isolated syndrome predicts conversion to multiple sclerosis

L. Aly<sup>a,b</sup>, J. Havla<sup>c,d</sup>, G. Lepennetier<sup>a,b</sup>, T. F. M. Andlauer<sup>a</sup>, C. Sie<sup>b</sup>, E.-M. Strauß<sup>a,b</sup>, M.-M. Hoshi<sup>a,e</sup>, T. Kümpfel<sup>c</sup>, M. Hiltensperger<sup>b</sup>, M. Mitsdoerffer<sup>a,b</sup>, M. Mühlau<sup>a</sup>, C. Zimmer<sup>f</sup>, B. Hemmer<sup>a,d,g</sup>, T. Korn<sup>a,b,g,\*</sup> and B. Knier<sup>a,b,\*</sup>

<sup>a</sup>Department of Neurology, Klinikum rechts der Isar, Technical University of Munich, Munich; <sup>b</sup>Institute of Experimental Neuroimmunology, Technical University of Munich, Munich; <sup>c</sup>Institute of Clinical Neuroimmunology, Ludwig-Maximilians University, Munich; <sup>d</sup>Data Integration for Future Medicine (DIFUTURE) Consortium, Technical University of Munich and Ludwig-Maximilians University, Munich; <sup>e</sup>Marianne-Strauß-Klinik, Berg; <sup>f</sup>Department of Neuroradiology, Klinikum rechts der Isar, Technical University of Munich, Munich; and <sup>g</sup>Munich Cluster for Systems Neurology (SyNergy), Munich, Germany

## Keywords:

multiple sclerosis, optical coherence tomography, prognosis, radiologically isolated syndrome

Received 19 May 2020  
Accepted 18 June 2020

*European Journal of Neurology* 2020, **27**: 2217–2224

doi:10.1111/ene.14416

## Abstract

**Background and purpose:** Individuals with radiologically isolated syndrome (RIS) are at increased risk of converting to multiple sclerosis (MS). Early identification of later converters is crucial for optimal treatment decisions. The purpose of this study was to assess the predictive potential of optical coherence tomography (OCT) measures in individuals with RIS regarding conversion to MS.

**Methods:** This prospective observational cohort study included 36 individuals with RIS and 36 healthy controls recruited from two German MS centers. All individuals received baseline OCT and clinical examination and were longitudinally followed over up to 6 years. The primary outcome measure was the conversion to MS.

**Results:** During clinical follow-up of 46 (26–58) months (median, 25%–75% interquartile range), eight individuals with RIS converted to MS. Individuals converting to MS showed a thinning of the peripapillary retinal nerve fiber layer (pRNFL) and the common ganglion cell and inner plexiform layer (GCIP) at baseline and during follow-up. Individuals with a pRNFL of 99  $\mu\text{m}$  or lower or a GCIP of 1.99  $\text{mm}^3$  or lower were at a 7.5- and 8.0-fold risk for MS conversion, respectively, compared to individuals with higher measures. After correction for other known risk factors, Cox proportional hazards regression revealed a hazard ratio of 1.08 for conversion to MS for each 1  $\mu\text{m}$  decline in pRNFL.

**Conclusions:** Reduction of the pRNFL might be a novel and independent risk factor for conversion to MS in individuals with RIS. OCT might be useful for risk stratification and therapeutic decision-making in individuals with RIS.

## Background

The wide availability of magnetic resonance imaging (MRI) has led to an increase in incidental findings, such as lesions suggestive of multiple sclerosis (MS),

Correspondence: B. Knier, Department of Neurology, Technical University of Munich, Ismaninger Str. 22, 81675 Munich, Germany (tel.: +49-89-4140-5666, fax: +49-89-4140-7681; e-mail: Benjamin.knier@tum.de).

\*T. Korn and B. Knier contributed equally to the paper.

in individuals without clinical deficits. The diagnosis of radiologically isolated syndrome (RIS) can be made in the absence of current or past neurological deficits and other explanatory conditions, if MRI lesions are disseminated in space as supposed in the 2017 revision of the McDonald criteria for the diagnosis of MS (MAGNIMS 2017 criteria) [1,2] or as described by the Barkhof criteria (Okuda criteria) [3,4]. RIS is observed in 0.1% of the general population [5], at

higher frequencies in headache patients [6], and in up to 2.9% of relatives of MS patients [7].

About one-third of individuals with RIS convert to MS within 5 years [8,9]. Retrospectively, RIS can be considered a preclinical form of MS in these converters. Based on our current understanding of MS [10], patients with preclinical central nervous system (CNS) inflammation might benefit from early immunomodulatory treatment. Thus, prediction of conversion to MS at a prodromal stage might be helpful for clinical decision-making. Risk factors for the conversion of RIS individuals to MS include younger age, male sex, spinal cord lesions [11], high numbers of T2 lesions on MRI [12] and visually evoked potential abnormalities [8]. Optical coherence tomography (OCT) is a non-invasive high-resolution imaging technique of the retina. Distinct changes in the retinal architecture may reflect neurodegenerative and inflammatory processes within the CNS during MS [13–16] and might be associated with paraclinical disease activity in individuals with RIS [17]. The aim of the current study was to assess whether retinal alterations in individuals with RIS can be used as prognostic markers for conversion to MS.

## Methods

### Study subjects

Individuals with RIS were retrospectively included from two ongoing observational studies at the neuroimmunological outpatient units from the Departments of Neurology of the Technical University of Munich (TUM) and the Ludwig-Maximilians University Munich (LMU). Both studies included regular clinical and OCT follow-up examinations on an annual basis. Regular and annual MRI follow-up examinations were only performed in a subgroup of individuals with RIS. All individuals with a diagnosis of RIS between 2013 and 2018 in both centers were screened. Individuals with RIS as defined by the MAGNIMS recommendations [2], who gave their written informed consent and who revealed a clinical follow-up period of at least 6 months, were included in the study. The same number of healthy controls (HCs) with similar age and sex were recruited as the control cohort. Eyes with any coexisting ocular pathology reported by the patient or apparent in OCT and eyes with the occurrence of optic neuritis (ON) during the study were excluded. At baseline, all individuals received a clinical neurological examination including assessment of the Expanded Disability Status Scale (EDSS) and retinal OCT examination. Data from cerebrospinal fluid (CSF) analysis and cerebral MRI were documented. During clinical follow-up,

study participants received a clinical neurological examination including EDSS assessment and retinal OCT examination at various time points with an annual standardized workup, including MRI. The primary outcome parameter was the conversion to MS fulfilling the 2017 McDonald criteria by the occurrence of a clinical relapse. The study was approved by the Ethics Commission of TUM, School of Medicine (permit number 166/16 S), and the Ethics Commission of LMU, Faculty of Medicine (permit numbers 427-14, 163-16), and was conducted following the Declaration of Helsinki. Full understanding of all participants was ensured. All participants gave written informed consent.

### Optical coherence tomography and MRI measurements

Both the LMU and TUM centers used a Spectralis spectral domain OCT (Heidelberg Engineering, Heidelberg, Germany) with activated eye tracker function. OCT was performed as reported previously without pupil dilation [17]. Briefly, the peripapillary retinal nerve fiber layer (pRNFL) was assessed by a 12° [3.4 mm, automatic real time (ART) 100] ring scan around the optic nerve head. The macular volumes were calculated within a 6-mm diameter cylinder centered on the fovea from a macular volume scan from either 61 (30 × 25°, ART 13, performed at TUM) or 25 (20 × 20°, ART 49, performed at LMU) vertical B-scans. Besides the pRNFL, the common ganglion cell and inner plexiform layer (GCIP), inner nuclear layer and combined outer nuclear and plexiform layer were analyzed. Follow-up OCT scans were acquired using the integrated follow-up mode allowing repeated OCT measurements at the exact same areas of the retina. Segmentation of all individual layers was performed semi-automatically using software by the manufacturer (HEYEX2, Eye Explorer 2.3) and corrected manually by an experienced rater if necessary. All scans were checked for sufficient quality according to the OSCAR-IB criteria [18]. The APOSTEL recommendations were adhered to for reporting [19]. Except for pRNFL (given in  $\mu\text{m}$ ), all OCT measures were quantified as volumes ( $\text{mm}^3$ ). Atrophy rates were estimated for each patient from all OCT examinations (minimum two examinations) and are displayed as the average annual change. MRI examinations originated from non-uniform protocols of different MRI units and included T1 and T2 sequences in axial, coronal or sagittal planes [20]. A subgroup of individuals with RIS ( $n = 20$ ) received standardized annual MRI follow-up examinations on the same scanner as previously described [20]. All MRI scans were centrally

evaluated by an MS specialized radiologist checking fulfillment of the MAGNIMS recommendations.

### Statistical analyses

For statistical analyses, GraphPad Prism 7 (San Diego, CA, USA) and R v3.5.3 (Vienna, Austria) with the package survival v2.44-1 were used. To account for inter-eye correlations of OCT measurements within each patient, a paired-eye statistical approach was used [21] as previously described [22]. Mean values of both eyes were calculated and used as one individual data point when both eyes were available for longitudinal analysis. If one eye was excluded due to our study criteria, OCT values of the remaining eye were used. To evaluate cross-sectional differences between three or more groups, an ordinary one-way ANOVA with Tukey's multiple comparisons test was performed if values were normally distributed or a non-parametric Kruskal–Wallis test with Dunn's multiple comparisons test if values were not normally distributed. Quantitative differences between two groups were analyzed using Student's *t* test or the non-parametric Mann–Whitney *U* test (two-tailed tests) depending on whether or not values followed a Gaussian distribution. Categorical differences were evaluated using bivariate analysis with Fisher's exact test. To test the impact of retinal layer thicknesses at baseline on conversion to MS, the *coxph* function was used to apply Cox proportional hazards regression. For additional survival analysis, the study participants were first dichotomized according to the mean value of the respective retinal layer measurements and the *survdiff* function in R was used to perform Kaplan–Meyer survival analyses with the log-rank test. For the proportional hazards model, GCIP volumes were scaled to 0.02 mm<sup>3</sup> units to improve interpretability of coefficients; pRNFL thickness is provided in 1 μm units. All Cox proportional hazards models were corrected for the covariates age, sex, application of immunotherapy and spinal cord lesions. The statistical significance threshold was *P* < 0.05. Values are provided as mean ± standard deviation if normally distributed, otherwise as median (25%–75% interquartile range).

### Data availability statement

The data that support the findings of this study are available on request from the corresponding author and after subscription of a data transfer agreement. The data are not publicly available due to privacy or ethical restrictions. Data not shown or raw data for analysis will be shared in an anonymized and numerical way on request from any qualified investigator.

OCT images are unique to each person and might allow identification of the respective participant. Original OCT images or OCT files outside approved studies cannot be shared due to the legal requirements of our departments (TUM, LMU).

## Results

### Baseline characteristics

Thirty-seven individuals with RIS were recruited from the neuroimmunological outpatient unit from the Department of Neurology of TUM (*n* = 30) and from the Department of Neuroimmunology of LMU (*n* = 7) and 36 HCs. The diagnosis was established after diagnostic MRI for different indications with the most frequent indications being headache and vertigo. One individual with RIS (LMU) due to bilateral uveitis and one eye of another RIS individual (TUM) due to mild papilledema were excluded. Thus, 71 eyes of 36 individuals with RIS and 72 eyes of 36 HCs were included in the study. Twelve individuals with RIS from TUM have already been reported in the past [17]. At OCT follow-up, which was available for 28 individuals in the RIS cohort, one eye was excluded due to low OCT quality and three eyes of three patients were excluded due to an acute ON occurring during the follow-up time. Therefore, 52 eyes from 28 RIS individuals were used for longitudinal OCT analysis and follow-up OCT was available for 18 HCs (36 eyes) (Table 1).

The demographics at study inclusion were comparable between individuals with RIS and HCs (Table 1).

**Table 1** Baseline characteristics of healthy controls and individuals with radiologically isolated syndrome

Clinical characteristics	HCs ( <i>n</i> = 36)	RIS ( <i>n</i> = 36)	<i>P</i> value
Female, no. (%)	22 (61)	24 (67)	0.81
Age, years	34 (29–43)	35 (29–45)	0.73
Clinical follow-up, months	10 (7–26)	46 (26–58)	<b>&lt;0.001</b>
OCT follow-up, months	10 (7–26)	44 (25–50)	<b>0.007</b>
OCT characteristics			
pRNFL, μm	104.9 ± 7.7	98.8 ± 12.0	<b>0.006</b>
GCIP, mm <sup>3</sup>	2.04 (1.99–2.17)	1.99 (1.83–2.09)	<b>0.003</b>
INL, mm <sup>3</sup>	0.99 ± 0.06	0.97 ± 0.07	0.14

Clinical characteristics of *n* = 36 healthy controls (HCs), *n* = 36 individuals with radiologically isolated syndrome (RIS) and results from optical coherence tomography (OCT) examination (RIS *n* = 71 eyes, HCs *n* = 72 eyes) at baseline. Values show mean ± SD or median (25%–75% interquartile range). Student's *t* test, Mann–Whitney *U* test or Fisher's exact test. Bold values indicate *P* < 0.05. GCIP, ganglion cell and inner plexiform layer; INL, inner nuclear layer; pRNFL, peripapillary retinal nerve fiber layer.

The diagnosis of RIS was established 7 (1–24) months [median (25%–75% interquartile range)] prior to baseline examination. No person with RIS received any immunomodulatory medication at baseline. Of the 33 individuals with RIS who had available information on CSF, 27 presented with CSF-specific oligoclonal bands (82%). CSF analysis was performed 6 (0–39) months before study inclusion. Ten of the 36 persons with RIS showed spinal cord lesions (28%). At baseline, individuals with RIS exhibited thinning of the pRNFL, total macular volume (TMV) and the GCIP compared to controls (Table 1), whereas no differences were detected within other layers. Our cohort was similar to those of other RIS studies [23].

### Clinical course and conversion to MS

During follow-up, eight individuals with RIS presented with a clinical episode suggestive of a demyelinating event and accordingly converted to MS fulfilling the 2017 McDonald criteria, which was the primary outcome parameter. Four patients developed an acute ON, three patients suffered from myelitis and one patient presented with sensory deficits of the right leg. Two individuals with RIS started first line immunotherapy (interferon beta-1a and glatiramer acetate) during follow-up and before conversion to MS. Baseline characteristics of RIS individuals without and with conversion to MS were compared and similar measurements were observed in clinical, CSF and MRI parameters (Table 2). Converters, however, displayed a significantly lower pRNFL baseline thickness and GCIP volume than non-converters (Table 2). In fact, non-converters exhibited similar retinal layer thicknesses to controls, whereas converters showed inner retinal layer thinning (Fig. 1). The volumes of other layers were not different. In all layers, inter-eye differences were not different between converters and non-converters (Table 2). Conversion rates were not different for males and females (data not shown) and the two nominally associated OCT measures pRNFL and GCIP did not differ significantly between male and female RIS individuals (data not shown). There were no differences in original symptoms leading to MRI examination and subsequent RIS diagnosis (Table 3). Analyzing initiated immunotherapies of individuals with RIS during follow-up, no differences were found between converters and non-converters (Table 2). Individuals with RIS and MRI progression during follow-up defined by the occurrence of new T2 lesions or Gd+ lesions revealed by trend lower GCIP volumes at baseline ( $1.87 \pm 0.18 \text{ mm}^3$ ) compared to individuals with stable MRI ( $2.00 \pm 0.13 \text{ mm}^3$ ;  $P = 0.08$ ) (data not shown).

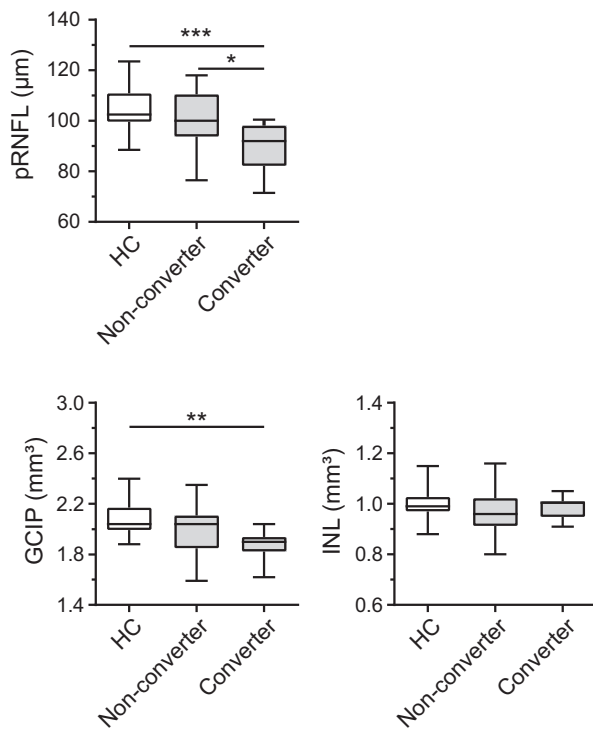
**Table 2** Baseline characteristics according to clinical course

Clinical characteristics	Non-converters ( <i>n</i> = 28)	Converters ( <i>n</i> = 8)	<i>P</i> value
Female, no. (%)	18 (64)	6 (75)	0.69
Age, years	$38 \pm 10$	$34 \pm 16$	0.41
Time since RIS diagnosis, months	6 (0–16)	18 (7–62)	0.06
Cerebrospinal fluid characteristics			
Oligoclonal bands, positive/no. tested (%)	19/25 (76)	8/8 (100)	0.30
Disease modifying therapy (DMT)			
DMT during follow-up, no. (%)	6 (21.4)	2 (25.0)	0.99
DMT start after baseline, months	3 (1–19)	1 (1–1)	0.43
MRI characteristics			
T2 lesions in cerebral MRI, no.	10 (6–14)	13 (5–22)	0.43
≥1 Gd+, no. (%)	3 (11)	2 (25)	0.57
≥1 infratentorial lesion, no. (%)	13 (46)	5 (63)	0.69
≥1 spinal cord lesion, no. (%)	8 (29)	2 (25)	1.0
OCT characteristics			
pRNFL, $\mu\text{m}$	$100.6 \pm 11.6$	$89.6 \pm 9.9$	<b>0.02</b>
GCIP, $\text{mm}^3$	$2.00 \pm 0.18$	$1.87 \pm 0.12$	<b>0.04</b>
INL, $\text{mm}^3$	$0.97 \pm 0.08$	$0.99 \pm 0.04$	0.45
Inter-eye difference pRNFL, $\mu\text{m}$	2 (1–5)	4 (2–7)	0.14
Inter-eye difference GCIP, $\text{mm}^3$	0.04 (0.02–0.06)	0.04 (0.01–0.11)	0.76

Individuals with sustained diagnosis of radiologically isolated syndrome (RIS) (non-converters, *n* = 28, 55 eyes) and conversion to multiple sclerosis (converters, *n* = 8, 16 eyes). Magnetic resonance imaging (MRI) and retinal optical coherence tomography (OCT) were obtained during study inclusion. Cerebrospinal fluid data reflects historical data obtained during diagnostic workup of suspected demyelinating disorder of the central nervous system before inclusion into the study. Time since RIS diagnosis describes the period between first RIS diagnosis by MRI and inclusion into the study. Values show mean  $\pm$  SD or median (25%–75% interquartile range). Student's *t* test, Mann–Whitney *U* test or Fisher's exact test. Bold values indicate  $P < 0.05$ . DMT, disease-modifying therapy; GCIP, ganglion cell and inner plexiform layer; INL, inner nuclear layer; pRNFL, peripapillary retinal nerve fiber layer.

### Longitudinal OCT changes and conversion to MS

When analyzing longitudinal changes in retinal architecture after baseline examination, individuals with RIS irrespective of later conversion showed a nominally significant annual loss in pRNFL thickness (HCs,  $0.01 \pm 0.96 \mu\text{m}$ ; RIS,  $-0.60 \pm 0.92 \mu\text{m}$  annualized change;  $P = 0.02$ , unpaired two-tailed *t* test) and GCIP volume (HCs,  $0.0 \pm 0.02 \text{ mm}^3$ ; RIS,  $-0.01 \pm 0.03$ ;  $P = 0.04$ , Mann–Whitney *U* test) compared to controls. This effect was mainly driven by individuals converting to MS (Fig. 2). There was no



**Figure 1** Retinal measures at baseline examination. Baseline retinal optical coherence tomography findings in healthy controls (HCs,  $n = 36$ ), individuals with radiologically isolated syndrome (RIS) that did not convert to multiple sclerosis (non-converters,  $n = 28$ ) and persons with RIS converting to multiple sclerosis (converters,  $n = 8$ ); box-and-whisker plot depicting median, 25th percentile, 75th percentile, minimum and maximum values; ordinary one-way ANOVA with Tukey's multiple comparisons test. \* $P < 0.05$ , \*\* $P < 0.01$ , \*\*\* $P < 0.001$ . pRNFL, peripapillary retinal nerve fiber layer; GCIP, ganglion cell and inner plexiform layer; INL, inner nuclear layer.

**Table 3** Initial symptoms leading to MRI examinations

Indication	Non-converters ( $n = 28$ )	Converters ( $n = 8$ )	$P$ value
Headache and pain, no. (%)	12 (42.9)	1 (12.5)	0.21
Vertigo, no. (%)	4 (14.3)	0 (0)	0.28
Paresthesia (duration <1 h), no. (%)	4 (14.3)	2 (25.0)	0.99
Psychiatric diseases, no. (%)	2 (7.1)	1 (12.5)	0.54
Commotio cerebri, no. (%)	2 (7.1)	0 (0)	0.99
Epilepsy, no. (%)	1 (3.6)	1 (12.5)	0.40
Other, no. (%)	3 (10.7)	3 (37.5)	0.11

Original symptoms leading to a magnetic resonance imaging (MRI) examination and subsequent diagnosis of radiologically isolated syndrome (RIS) in individuals with sustained RIS diagnosis (non-converters,  $n = 28$ ) and individuals converting to multiple sclerosis (converters,  $n = 8$ ). Fisher's exact test.

significant difference between HCs and individuals with a sustained RIS diagnosis (non-converters) alone.

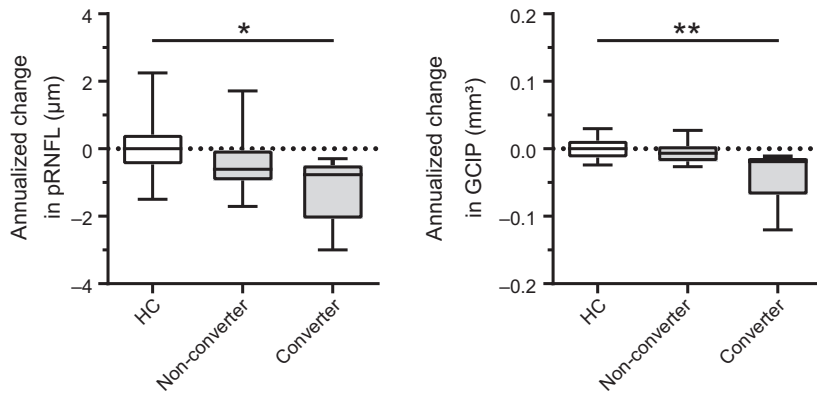
### Peripapillary retinal nerve fiber layer and GCIP as risk factors for conversion to MS

Based on these results, it was hypothesized that pRNFL and GCIP thinning might be risk factors for conversion to MS in individuals with RIS. To test this hypothesis, the study participants with RIS were dichotomized into two groups according to the mean value of their retinal layer measurements for pRNFL and GCIP and survival analyses were performed. During a clinical follow-up time of 46 (26–58) months, individuals with a pRNFL of 99  $\mu\text{m}$  or below had a 7.5-fold risk [hazard ratio 7.5, 95% confidence interval (CI) 1.9–29.9,  $P = 0.03$ ] for clinical conversion to MS compared to individuals with thicker pRNFL values (Fig. 3a). Using this cut-off, prediction of conversion in the same sample had a sensitivity of 88% and specificity of 61% (area under the curve 0.77, positive predictive value 39%, negative predictive value 94%, accuracy 65%). When correcting for age, sex, immunotherapy and the occurrence of spinal cord lesions, the hazard rate for conversion to MS was 1.08 for each 1  $\mu\text{m}$  decline in pRNFL at nominal significance in a Cox proportional hazards regression model ( $P = 0.04$ , 95% CI 1.003–1.171). A similar result was observed for GCIP. Individuals with RIS displaying a GCIP volume of 1.99  $\text{mm}^3$  or below had an 8.0-fold risk (hazard ratio 8.0, 95% CI 2.0–32.1,  $P = 0.02$ ) for clinical conversion to MS compared to those with higher GCIP volumes (Fig. 3b; sensitivity 88%, specificity 64%, area under the curve 0.74, positive predictive value 39%, negative predictive value 94%, accuracy 62%). Although the additional Cox proportional hazards regression analysis did not reach significance, the hazard for conversion to MS was 1.09 for each 0.02  $\text{mm}^3$  decrease in GCIP volume ( $P = 0.08$ , 95% CI 0.989–1.220). Taken together, these findings identify pRNFL and GCIP as measured by OCT as potential risk factors for conversion to MS in individuals with RIS independent of known risk factors.

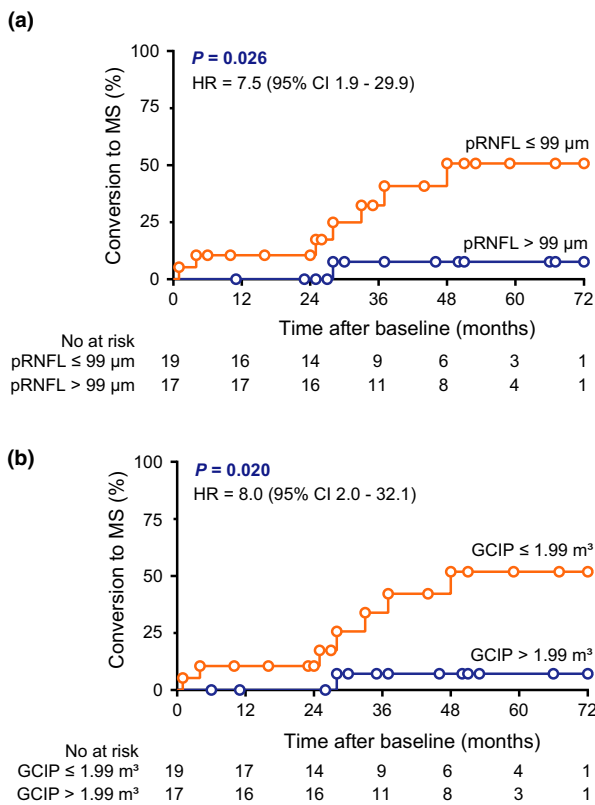
### Discussion

In the present study, it is demonstrated that pRNFL and GCIP thinning as measured by OCT are risk factors for subsequent conversion to MS in individuals with RIS. Thus, retinal OCT might be a suitable tool for risk stratification in individuals with RIS.

Retinal alterations in individuals with RIS have already been studied in recent years. Here, persons with RIS exhibited reduced volumes of RNFL similar



**Figure 2** Longitudinal retinal layer changes during follow-up. Annualized changes of the peripapillary retinal nerve fiber layer (pRNFL) and the ganglion cell and inner plexiform layer (GCIP) during follow-up in healthy controls (HCs,  $n = 18$ ), individuals with sustained diagnosis of radiologically isolated syndrome (RIS) (non-converters,  $n = 21$ ) and persons with RIS converting to multiple sclerosis (converters,  $n = 7$ ); box-and-whisker plot depicting median, 25th percentile, 75th percentile, minimum and maximum values; Kruskal–Wallis test with Dunn’s multiple comparison test. \* $P < 0.05$ , \*\* $P < 0.01$ .



**Figure 3** Association of baseline retinal layer measures with disease course. Cumulative fraction of individuals with radiologically isolated syndrome converting to multiple sclerosis in individuals stratified according to the population mean of their peripapillary retinal nerve fiber layer (pRNFL) thickness (a) or ganglion cell and inner plexiform layer (GCIP) volume (b). Survival analysis with the log-rank test. HR, hazard ratio; CI, confidence interval. [Colour figure can be viewed at [wileyonlinelibrary.com](http://wileyonlinelibrary.com)]

to patients with clinically isolated syndrome (CIS) [17]. Inner retinal layer thinning in RIS was associated with reduced total brain and thalamic volumes and has thus been suggested as a marker for neurodegeneration in preclinical stages of CNS autoimmunity [23]. Furthermore, patients with RIS showing spinal cord lesions revealed reduced GCIP thicknesses compared to RIS patients without spinal cord lesions or HCs [24]. To the best of our knowledge, the current study is the first to analyze the association of OCT measures with the conversion to MS in individuals with RIS in a prospective manner.

In our study, it was found that patients with pRNFL thickness and GCIP volume loss were at higher risk for clinical conversion to MS. Inner retinal layer thinning occurs early in the course of demyelinating CNS autoimmunity [25] and is most probably driven by retrograde trans-synaptic neurodegeneration [26] due to intrathecal inflammatory processes [22] and subsequent brain atrophy [14]. It has already been shown that reduced pRNFL and GCIP measures are risk factors for clinical progression with sustained disability worsening in both CIS and MS [13,16,22,27]. The decreased likelihood of achieving the status of no evidence of disease activity (NEDA-3) in individuals with low GCIP volumes argues for the predictive power of retinal layer alterations during the course of MS and its ‘precursor stages’ CIS and RIS [13]. The current study adds to the notion that RIS-MS converters, but not RIS individuals without MS conversion, display inner retinal layer thinning. Differences in OCT measures between HCs and individuals with RIS are mainly dependent on those individuals with RIS that will convert to MS. Thus, retinal OCT could

be a useful tool for risk stratification of persons with RIS. Whilst OCT might be capable of identifying those individuals with RIS with ongoing disease activity who are at a high risk for conversion to MS and might benefit from an immunomodulatory treatment, pRNFL and GCIP measures in persons with RIS who are in the range of measures of healthy individuals might justify a wait-and-see strategy.

Our study has several limitations. One limitation is the low sample size that might have led to falsely positive results. RIS, however, is a rare condition and, to our knowledge, this report represents the largest longitudinal OCT study in RIS to date. One further constraint of the present investigation is the short observation period in some individuals with RIS. It is possible that more conversion events occurred after study termination. Also, with a total of 82%, this study contains a high frequency of RIS individuals with CSF-specific oligoclonal bands, which is a potential selection bias towards a cohort with higher risk of conversion. Future studies should address this limitation with larger cohorts and longer follow-up periods. Also, there was no standard MRI protocol available for all RIS patients, impeding additional volumetric MRI analyses.

Taken together, our data support the hypothesis of different disease activity patterns amongst individuals with RIS. Based on the literature [8] and data from the present study, only a small fraction of individuals with RIS converts to MS within the first years after diagnosis. Here, OCT might be useful to distinguish individuals with actively ongoing inflammatory disease from non-active individuals with RIS. Further studies are needed to confirm the predictive value of OCT in individuals with RIS and should evaluate whether OCT can be a suitable tool for risk stratification and therapeutic decision-making in individuals with RIS.

## Conclusions

Individuals with lower pRNFL and GCIP at baseline were at higher risk of conversion to MS compared to RIS individuals with higher retinal measures. In contrast to non-converters, only converters presented accelerated atrophy rates of pRNFL and GCIP compared to HCs. Therefore, OCT might be a useful addition to risk stratification in individuals with RIS.

## Acknowledgements

Novartis are thanked for financial support of the study (Oppenheim program). Andrea Hennemann (TUM) and Angelika Bamberger (LMU) are thanked for expert assistance during OCT analysis. LA received funding from a clinician scientist program by the

Munich Cluster for Systems Neurology (SyNergy). JH reports a grant from the Friedrich-Baur-Stiftung and is funded by the German Federal Ministry of Education and Research. TKo received funding from SFBs (TR-128, SFB 1054), Synergy, European Research Council (CoG 647215) and Novartis (Oppenheim program). BK was supported by a Seed scholarship by the Kompetenznetzwerk Multiple Sklerose (German Federal Ministry of Education and Research), by intramural funding granted by TUM and a research grant from Novartis (Oppenheim program). Open access funding enabled and organized by Projekt DEAL.

## Disclosure of conflicts of interest

LA reports no disclosures. JH reports personal fees and non-financial support from Alexion, Merck, Novartis, Roche, Bayer Healthcare, Santhera, Biogen, Sanofi Genzyme and Heidelberg Engineering during the last 5 years, grants from Merck and the Friedrich-Baur-Foundation (all outside the submitted work) and non-financial support of the Guthy-Jackson Charitable Foundation. GL reports no disclosures. TFMA reports no disclosures. CS reports no disclosures. EMS reports no disclosures. MMH received grants from Bayer Health Care and personal fees from Biogen and Novartis. TKü has received speaker honoraria including advisory boards from Bayer Healthcare, Teva Pharma, Merck, Novartis Pharma, Sanofi-Aventis/Genzyme, Roche Pharma and Biogen as well as grant support from Novartis and Chugai Pharma in the past. MH reports no disclosures. MMi reports no disclosures. MMü reports no disclosures. CZ has served on scientific advisory boards for Philips and Bayer Schering and has received speaker honoraria from Bayer-Schering and Philips. He or his institution has received research support and investigator fees for clinical studies from Biogen Idec, Quintiles, MSD Sharp & Dome, Boehringer Ingelheim, Inventive Health Clinical UK Ltd, Advance Cor, Brainsgate, Pfizer, Bayer-Schering, Novartis, Roche, Servier, Penumbra, WCT GmbH, Syngis, SSS International Clinical Research, PPD Germany GmbH, Worldwide Clinical Trials Ltd, Phenox, Covidien, Actelion, Medivation, Medtronic, Harrison Clinical Research, Concentric, Pharmtrace, Reverse Medical Corp., Premier Research Germany Ltd, Surpass Medical Ltd, GlaxoSmithKline, AXON Neuroscience, Bristol-Myers Squibb, Genentech, Acandis, Eisai, NeuroRx, Italfarmaco, Bioclinica, MIAC and IXICO. BH has served on scientific advisory boards for F. Hoffmann-La Roche Ltd, Novartis and Bayer AG; he has served as DMSC member for AllergyCare and TG Therapeutics; he or his institution have received speaker

honoraria from Medimmune, Novartis, Desitin and F. Hoffmann-La Roche Ltd; his institution has received research support from Chugai Pharmaceuticals; holds part of two patents, one for the detection of antibodies and T cells against KIR4.1 in a subpopulation of MS patients and one for genetic determinants of neutralizing antibodies to interferon  $\beta$ . TKo reports no disclosures. BK received travel support and a research grant from Novartis. This study was partially funded by Novartis Pharma GmbH (Oppenheim research grant). No sponsor had any influence on the design and conduct of the study, collection, management, analysis and interpretation of the data, preparation, review or approval of the manuscript and decision to submit the manuscript for publication.

## References

- Swanton JK, Rovira A, Tintore M, *et al.* MRI criteria for multiple sclerosis in patients presenting with clinically isolated syndromes: a multicentre retrospective study. *Lancet Neurol* 2007; **6**: 677–686.
- De Stefano N, Giorgio A, Tintore M, *et al.* Radiologically isolated syndrome or subclinical multiple sclerosis: MAGNIMS consensus recommendations. *Mult Scler* 2018; **24**: 214–221.
- Barkhof F, Filippi M, Miller DH, *et al.* Comparison of MRI criteria at first presentation to predict conversion to clinically definite multiple sclerosis. *Brain* 1997; **120**: 2059–2069.
- Okuda DT, Mowry EM, Beheshtian A, *et al.* Incidental MRI anomalies suggestive of multiple sclerosis: the radiologically isolated syndrome. *Neurology* 2009; **72**: 800–805.
- Forslin Y, Granberg T, Jumah AA, *et al.* Incidence of radiologically isolated syndrome: a population-based study. *AJNR Am J Neuroradiol* 2016; **37**: 1017–1022.
- Liu S, Kullnat J, Bourdette D, *et al.* Prevalence of brain magnetic resonance imaging meeting Barkhof and McDonald criteria for dissemination in space among headache patients. *Mult Scler* 2013; **19**: 1101–1105.
- Gabelic T, Ramasamy DP, Weinstock-Guttman B, *et al.* Prevalence of radiologically isolated syndrome and white matter signal abnormalities in healthy relatives of patients with multiple sclerosis. *AJNR Am J Neuroradiol* 2014; **35**: 106–112.
- Lebrun C, Bensa C, Debouverie M, *et al.* Association between clinical conversion to multiple sclerosis in radiologically isolated syndrome and magnetic resonance imaging, cerebrospinal fluid, and visual evoked potential: follow-up of 70 patients. *Arch Neurol* 2009; **66**: 841–846.
- Okuda DT, Siva A, Kantarci O, *et al.* Radiologically isolated syndrome: 5-year risk for an initial clinical event. *PLoS One* 2014; **9**: e90509.
- Brown JW, Coles A, Horakova D, *et al.* Association of initial disease-modifying therapy with later conversion to secondary progressive multiple sclerosis. *JAMA* 2019; **321**: 175–187.
- Okuda DT, Mowry EM, Cree BA, *et al.* Asymptomatic spinal cord lesions predict disease progression in radiologically isolated syndrome. *Neurology* 2011; **76**: 686–692.
- Etemadifar M, Janghorbani M, Koushki MM, Etemadifar F, Esfahani MF. Conversion from radiologically isolated syndrome to multiple sclerosis. *Int J Prev Med* 2014; **5**(11): 1379–1386.
- Zimmermann HG, Knier B, Oberwahrenbrock T, *et al.* Association of retinal ganglion cell layer thickness with future disease activity in patients with clinically isolated syndrome. *JAMA Neurol* 2018; **75**: 1071–1079.
- Saidha S, Al-Louzi O, Ratchford JN, *et al.* Optical coherence tomography reflects brain atrophy in multiple sclerosis: a four-year study. *Ann Neurol* 2015; **78**: 801–813.
- Knier B, Schmidt P, Aly L, *et al.* Retinal inner nuclear layer volume reflects response to immunotherapy in multiple sclerosis. *Brain* 2016; **139**: 2855–2863.
- Martinez-Lapiscina EH, Arnow S, Wilson JA, *et al.* Retinal thickness measured with optical coherence tomography and risk of disability worsening in multiple sclerosis: a cohort study. *Lancet Neurol* 2016; **15**: 574–584.
- Knier B, Berthele A, Buck D, *et al.* Optical coherence tomography indicates disease activity prior to clinical onset of central nervous system demyelination. *Mult Scler* 2016; **22**: 893–900.
- Schippling S, Balk LJ, Costello F, *et al.* Quality control for retinal OCT in multiple sclerosis: validation of the OSCAR-IB criteria. *Mult Scler* 2015; **21**: 163–170.
- Cruz-Herranz A, Balk LJ, Oberwahrenbrock T, *et al.* The APOSTEL recommendations for reporting quantitative optical coherence tomography studies. *Neurology* 2016; **86**: 2303–2309.
- Muhlau M, Buck D, Forschler A, *et al.* White-matter lesions drive deep gray-matter atrophy in early multiple sclerosis: support from structural MRI. *Mult Scler* 2013; **19**: 1485–1492.
- Fan Q, Teo YY, Saw SM. Application of advanced statistics in ophthalmology. *Invest Ophthalmol Vis Sci* 2011; **52**: 6059–6065.
- Knier B, Leppenstier G, Wetzlmair C, *et al.* Association of retinal architecture, intrathecal immunity, and clinical course in multiple sclerosis. *JAMA Neurol* 2017; **74**: 847–856.
- Vural A, Okar S, Kurne A, *et al.* Retinal degeneration is associated with brain volume reduction and prognosis in radiologically isolated syndrome. *Mult Scler* 2020; **26**: 38–47.
- Filippatou A, Shoemaker T, Esch M, *et al.* Spinal cord and infratentorial lesions in radiologically isolated syndrome are associated with decreased retinal ganglion cell/inner plexiform layer thickness. *Mult Scler* 2019; **25**: 1878–1887.
- Oberwahrenbrock T, Ringelstein M, Jentschke S, *et al.* Retinal ganglion cell and inner plexiform layer thinning in clinically isolated syndrome. *Mult Scler* 2013; **19**: 1887–1895.
- Balk LJ, Twisk JW, Steenwijk MD, *et al.* A dam for retrograde axonal degeneration in multiple sclerosis? *J Neurol Neurosurg Psychiatry* 2014; **85**: 782–789.
- Rothman A, Murphy OC, Fitzgerald KC, *et al.* Retinal measurements predict 10-year disability in multiple sclerosis. *Ann Clin Transl Neurol* 2019; **6**: 222–232.