

University of Groningen

## Prefabricated fibula free flaps in reconstruction of maxillofacial defects

Huizinga, Martin P; Stenekes, Martin W; Kraeima, Joep; de Visscher, Sebastiaan A H J;  
Raghoobar, Gerry M; Werker, Paul M N; Witjes, Max J H

*Published in:*  
Head & Neck

*DOI:*  
[10.1002/hed.27542](https://doi.org/10.1002/hed.27542)

**IMPORTANT NOTE: You are advised to consult the publisher's version (publisher's PDF) if you wish to cite from it. Please check the document version below.**

*Document Version*  
Publisher's PDF, also known as Version of record

*Publication date:*  
2023

[Link to publication in University of Groningen/UMCG research database](#)

### *Citation for published version (APA):*

Huizinga, M. P., Stenekes, M. W., Kraeima, J., de Visscher, S. A. H. J., Raghoobar, G. M., Werker, P. M. N., & Witjes, M. J. H. (2023). Prefabricated fibula free flaps in reconstruction of maxillofacial defects: Two cases of transplanting a fractured fibula. *Head & Neck*, *45*(12), E67-E72. <https://doi.org/10.1002/hed.27542>

### **Copyright**

Other than for strictly personal use, it is not permitted to download or to forward/distribute the text or part of it without the consent of the author(s) and/or copyright holder(s), unless the work is under an open content license (like Creative Commons).

The publication may also be distributed here under the terms of Article 25fa of the Dutch Copyright Act, indicated by the "Taverne" license. More information can be found on the University of Groningen website: <https://www.rug.nl/library/open-access/self-archiving-pure/taverne-amendment>.


### **Take-down policy**

If you believe that this document breaches copyright please contact us providing details, and we will remove access to the work immediately and investigate your claim.

*Downloaded from the University of Groningen/UMCG research database (Pure): <http://www.rug.nl/research/portal>. For technical reasons the number of authors shown on this cover page is limited to 10 maximum.*

## CASE REPORT

# Prefabricated fibula free flaps in reconstruction of maxillofacial defects: Two cases of transplanting a fractured fibula

Martin P. Huizinga MD, DMD<sup>1</sup>  | Martin W. Stenekes MD, PhD<sup>2</sup> |  
 Joep Kraeima PhD<sup>1</sup> | Sebastiaan A. H. J. de Visscher MD, DMD, PhD<sup>1</sup> |  
 Gerry M. Raghoobar MD, DMD, PhD<sup>1</sup> | Paul M. N. Werker MD, PhD<sup>2</sup> |  
 Max J. H. Witjes MD, DMD, PhD<sup>1</sup>

<sup>1</sup>Department of Oral and Maxillofacial Surgery, University Medical Center Groningen, Groningen, The Netherlands

<sup>2</sup>Department of Plastic and Reconstructive Surgery, University Medical Center Groningen, Groningen, The Netherlands

## Correspondence

Martin P. Huizinga, Department of Oral and Maxillofacial Surgery, University Medical Center Groningen, Groningen, The Netherlands.

Email: [martin.huizinga@mst.nl](mailto:martin.huizinga@mst.nl)

**Section Editor:** Eben L. Rosenthal

## Abstract

**Background:** The two-staged prefabricated vascularized fibula free flap is used in maxillofacial reconstruction. We describe the possible cause and management of two cases of fibula fracture after implant placement.

**Methods:** The patients were treated with two-stage reconstruction with a prefabricated vascularized fibula free flap. Six dental implants were placed in both fibulas. Fibula fractures occurred during the osseointegration period before the second procedure. The reconstruction was continued as planned.

**Results:** Both fibulas fractured in the distal segment, possibly due to a thinner cortex more distally. Harvesting of a fractured fibula flap is more difficult than normally due to callus formation and fibrosis. Both transplants became fully functional with extended healing and additional surgery.

**Conclusion:** The fracture apparently did not compromise the vascularisation of the fibula and proved still sufficient for successful harvest and transfer of the flap. The patient should be made aware that additional corrective surgery may be indicated.

## KEYWORDS

fibula fracture, free fibula flap, maxillofacial reconstruction, oral, prefabrication

## 1 | INTRODUCTION

Segmental defects of the mandible or maxilla may result from the surgical treatment of oral cancer, benign tumors, trauma, osteomyelitis, or osteoradionecrosis. Bony reconstruction of these bony defects offers the possibility of dental rehabilitation using dental implants. Free

vascularized fibula grafts are routinely used in reconstructive surgery of the mandible or maxilla because it provides both a sufficient amount of bone and soft tissue.<sup>1-3</sup>

The use of a prefabricated fibula free flap, in which dental implants are placed during the same procedure in which the fibula is prelaminated with a skin graft prior to the actual transfer procedure, aims to improve implant

This is an open access article under the terms of the [Creative Commons Attribution-NonCommercial-NoDerivs](https://creativecommons.org/licenses/by-nc-nd/4.0/) License, which permits use and distribution in any medium, provided the original work is properly cited, the use is non-commercial and no modifications or adaptations are made.

© 2023 The Authors. *Head & Neck* published by Wiley Periodicals LLC.

osseointegration and to achieve a stable peri-implant soft tissue coverage.<sup>4</sup> To ensure adequate positioning of the free flap in the defect, as well as optimizing the soft tissue around the dental implants in the flap, the technique of prefabrication has been developed.<sup>5,6</sup> In previous articles we described our workflow for digital planning and guided surgery in these complex procedures.<sup>7-9</sup>

Prefabrication of the VFFF consists of two surgical steps. In the first procedure, dental implants are placed in the fibula bone in a preplanned position using a three-dimensionally (3D) printed drilling template (Figure 1). This is done according to a prosthetically driven digital planning. The implants are subsequently covered by a split thickness skin graft and a non-resorbable membrane. The skin graft will later function as a stable peri-implant epithelial layer and makes it possible to create a buccal vestibule. The implants are allowed to osseointegrate during at least 6 weeks, while the patient has normal leg function. In the time between the first and second surgery, the planning is completed and an implant-retained prosthesis is manufactured.

During the second procedure the fibula is harvested as a vascularized flap. While the blood supply of the flap is still attached to the leg, the osteotomies are made using a digitally planned and printed template (Figure 2), by means of a reciprocating saw. The most distal osteotomy is usually placed at least 7 cm from the lateral malleolus to maintain articular stability of the ankle. The bony segments are fixated in the right position with 2.0 mm osteosynthesis plates. The prefabricated denture is then fixed to the previously placed implants. In the meantime, a resection of the affected jaw is performed, also according to a digitally planned template.

Subsequently, the cut and fixed prefabricated fibula flap with osteosynthesis plates and prosthesis is transferred from the leg into the oral defect where the osteosynthesis plates are attached to the native mandible or maxilla stumps while the dental prosthesis is placed in occlusion. After suturing the soft tissues, the vascular anastomoses are performed.

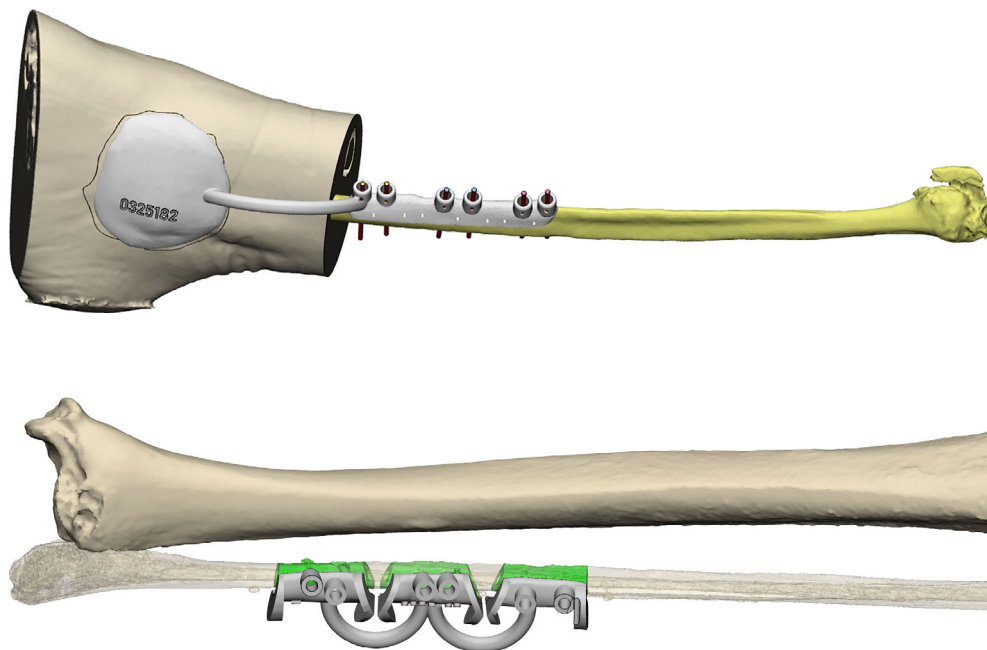
An advantage of this two-stage technique is that the reconstruction is prosthetically driven. Dental rehabilitation and occlusion are leading for the planning of osseous reconstruction and implant placement. The precise planning necessary to position the osseous fibula segments is nowadays easier to perform and more precise due to the advent of virtual planning.<sup>7</sup>

Due to the need of two surgical procedures at least 6 weeks apart, this procedure is not indicated for patients with active disease of head and neck cancer. Since 2008, over 20 cases have been treated according to this method in our clinic.

As with any surgical treatment we have experienced some setbacks and unforeseen obstacles. This case report describes two cases in which a fracture of the prefabricated fibula occurred between the first and second procedure. We describe how we managed these setbacks and the result we nevertheless were able to achieve.

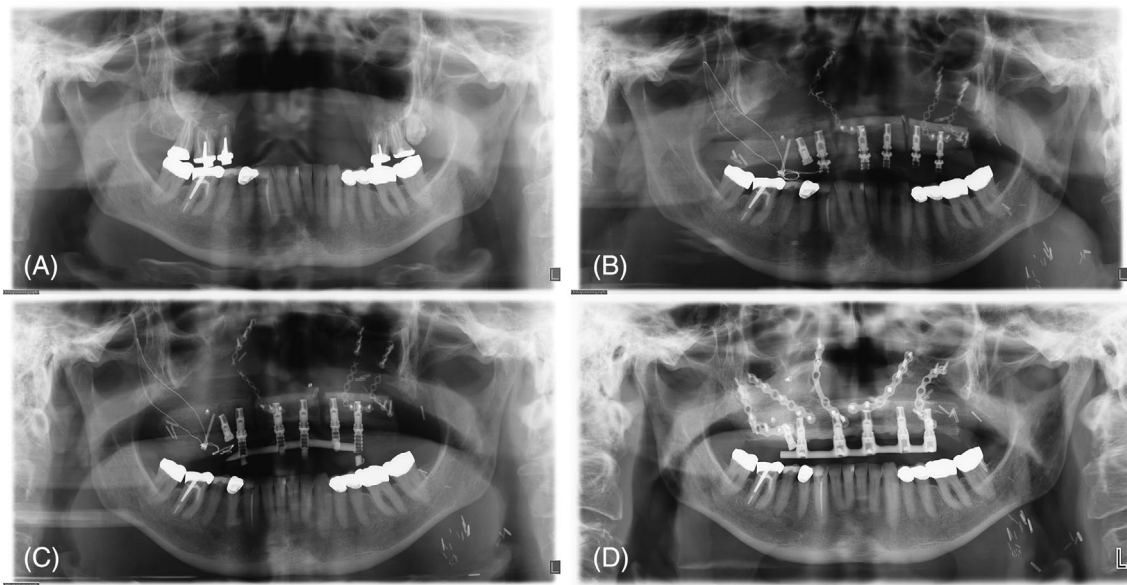
## 1.1 | Case 1

A 70-year-old woman was referred to our clinic for reconstruction of the anterior maxilla (Figure 3A). She underwent a partial anterior maxillectomy and postoperative radiotherapy 10 years earlier because of a



**FIGURE 1** 3D virtual surgical planning including the designed drilling guide, supported on the lateral malleolus for placement of six dental implants in the left fibula

**FIGURE 2** The template for the osteotomies of the fibula. It is secured on top of the previously placed implants. The tibia is also shown

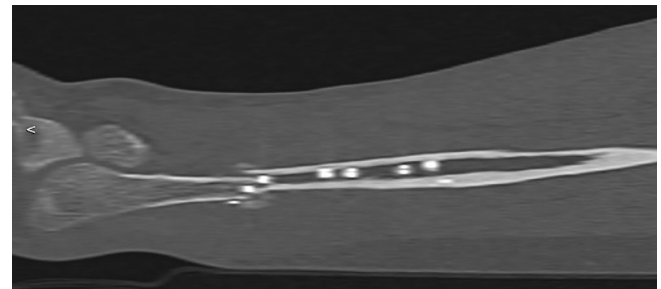


**FIGURE 3** Overview of panoramic X-rays of the first case. (A) Initial situation, anterior maxillary defect. (B) Direct postoperative situation. (C) Fracture of the osteosynthesis plates. (D) Osseointegration of the flap with stronger osteosynthesis plates

leiomyosarcoma in the nasal vestibule. Obturation was achieved by an obturator prosthesis supported by her remaining dentition. Due to mobility of the remaining teeth, her prosthetic obturation was failing. A two-staged reconstruction using a VFFF was virtually planned. During the first stage surgery, six dental implants (NobelParallel CC 3.75×10mm, Nobel Biocare, Zürich, Zwitzerland) were placed in the fibula of the right lower leg.

Seven weeks later, a regularly planned preoperative computed tomography scan (CT scan) showed a transverse fracture of the fibula shaft between the two most distal implants (Figure 4). There was slight displacement of the distal segment and callus formation around the fracture. The patient experienced no physical complaints, and no clinical fracture signs were apparent on the leg. She had no recollection of a possible causal event.

We decided to continue the reconstruction as planned. During the second stage procedure, 11 weeks after the first surgery, there was excessive amounts of edema and fibrosis in the lower leg. This made the harvest of the fibula transplant more difficult, especially as far as the dissection of the accompanying vessels was concerned. The osteotomies were performed as planned and the preoperatively fabricated fixed prosthesis was placed on the proximal five implants. The sixth implant, distal to the fracture could not be used due to displacement of the segment and callus formation. Five implants were osseointegrated. The status of the sixth implant was unclear due to the copious amount of callus formation. Extractions of the upper dentition and an additional partial maxillectomy were performed as planned. Due to the bulky callus formation, the fibula



**FIGURE 4** A fracture in the distal part of the fibula, between the fifth and sixth implant. Callus formation can be seen around the fracture

could not reach the planned position at the distal segment. Therefore, a more caudal position was accepted for this segment. The transplant was fixated to the remaining upper maxilla and zygoma with three 1.5 mm osteosynthesis plates (KLS Martin, Tuttlingen, Germany) and a peri-zygomatic steel wire attached to a position screw on the right side to prevent caudal dislocation of the flap (Figure 3B).

Directly postoperative, the transplant appeared to be mobile and there was excessive dental show due to the suboptimal caudal position. This was tentatively accepted for the benefit of graft survival. During follow-up the flap remained well vascularized and survived. A fistula on the hard palate remained, despite two attempts for closure with local flaps.

The osteosynthesis plates fractured due to the repetitive movement of the fibula transplant (Figure 3C). Nine months after the second surgery the fractured

osteosynthesis plates and peri-zygomatic wire were removed and the fibula transplant was positioned in a more anatomical, cranial position and fixated with thicker 2.0 mm plates. The remaining bony gaps were filled with a free bone transplant taken from the anterior iliac spine. This final surgery resulted in a completely stable osseointegration of the fibula transplant (Figure 3D). A new implant supported dental prosthesis was manufactured with a small obturator to cover the palatal fistula. Up to this moment, more than 7 years later, the result is fully functional and aesthetically pleasing.

## 1.2 | Case 2

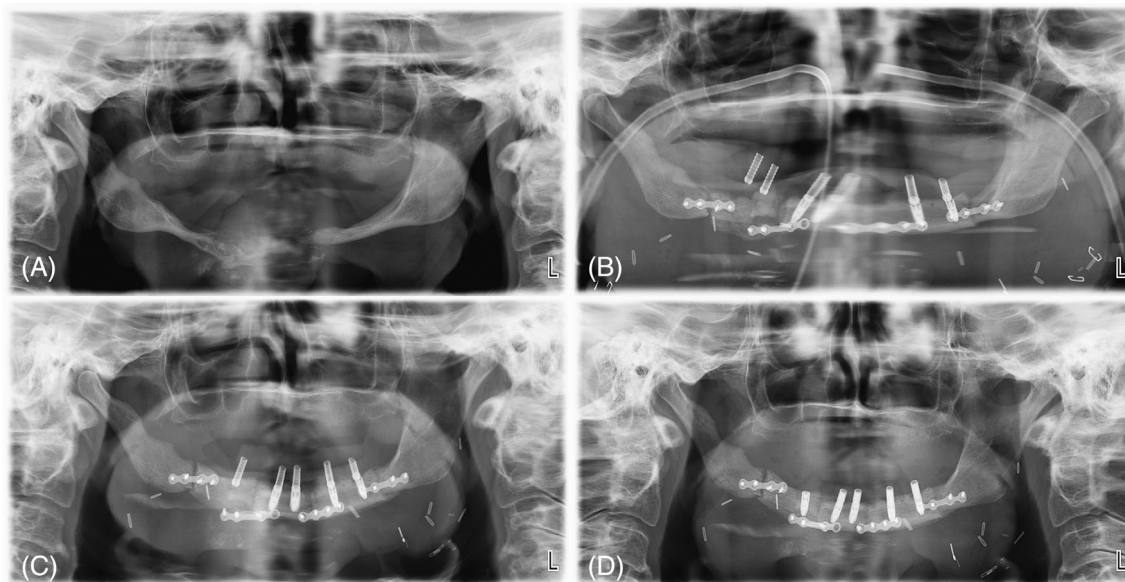
Seven years later an also 70-year-old, woman was referred to our clinic with a pathologic mandibular fracture due to osteomyelitis after a long history of peri-implantitis in a severely resorbed, edentulous mandible (Figure 5A).

A two staged prefabricated mandible reconstruction was digitally planned using a VFFF. The reconstruction was planned to consist of three bony segments (Figures 1, 2, and 6). During the first stage surgery six dental implants were placed, two implants per segment (NobelParallel CC 3.75×10mm, Nobel Biocare, Zürich, Switzerland). Prior to the implant placement, the outer cortex at the site where the implants were planned was flattened with a burr to obtain a flat surface. The postoperative CT scan of the lower leg taken the next day

showed adequate position of the implants and no fracture. During the following weeks the left lower leg became slightly swollen. The patient experienced mild complaints of pain but could function normally.

At the second stage surgery, after 9 weeks, there was no suspicion of a fracture. However, dissection of the vasculature and musculature around the fibula again appeared to be more difficult than usual. The two most distal implants showed excessive mobility and no osseointegration. They were easily removed. As a result, the distal bony segment was left without implants. The template for making the osteotomies could no longer be fixated on the failed two distal implants and was therefore fixated by additional position screws. The position screw to retain the Gore-Tex membrane near these implants could not be found.

Making the osteotomy of the distal segment revealed that the bone was remarkably soft and there was callus formation. The prefabricated fixed dental prosthesis was placed on the remaining four implants and the fibula graft was subsequently transplanted to the mandible. It took more effort to fix the osteosynthesis plates due to the copious amount of callus formation. However, the bony reconstruction fitted perfectly as planned. During soft tissue suturing, it became apparent that the plate that stabilized the middle to the distal segment had detached from the distal segment. A closer inspection of this segment revealed that a fragment of this bone segment had broken off. The missing position screw was found deep in the fracture gap. The plate was repositioned more caudally in the callus formation offering moderate stability



**FIGURE 5** Overview of panoramic X-rays of the second case. (A) Initial situation, pathologic mandibular fracture. (B) Directly postoperative situation; the fracture is visible on the right side of the mandible. (C) Four months postoperatively; ossification of the callus formation. (D) Five months postoperatively; new implant in the healed segment

(Figure 5B). After micro anastomosis of the vasculature there was some bleeding from the bone in the distal segment, which was a sign of vitality of the flap.

During the first 2 weeks after the second procedure, the flap was monitored as usual by daily clinical checks and by monitoring of infection parameters. The clinical condition of the flap seemed acceptable and showed no signs of failure. The patient was fed using a nasogastric tube feeding for several weeks and was prohibited from exerting biting forces. The infection parameters were consistently declining. The patient was discharged after 12 days and was then seen on the outpatient clinic on a weekly basis. The clinical aspect improved over time and there were no signs of sequestration. Radiographically, the callus formation slowly ossified (Figure 5C,D). Recently, an additional dental implant was placed in the distal fibula segment to replace the previously removed

implants. During osseointegration of this implant, the patient wore a temporary prosthesis on locators (Figure 5D).


## 2 | DISCUSSION

This article describes two cases of two-staged osseous reconstructions using a prefabricated fibula flap in which the fibula appeared to be fractured sometime after placement of the dental implants in the first stage surgery. Both patients had no recollection of an event in which the fracture could have occurred.

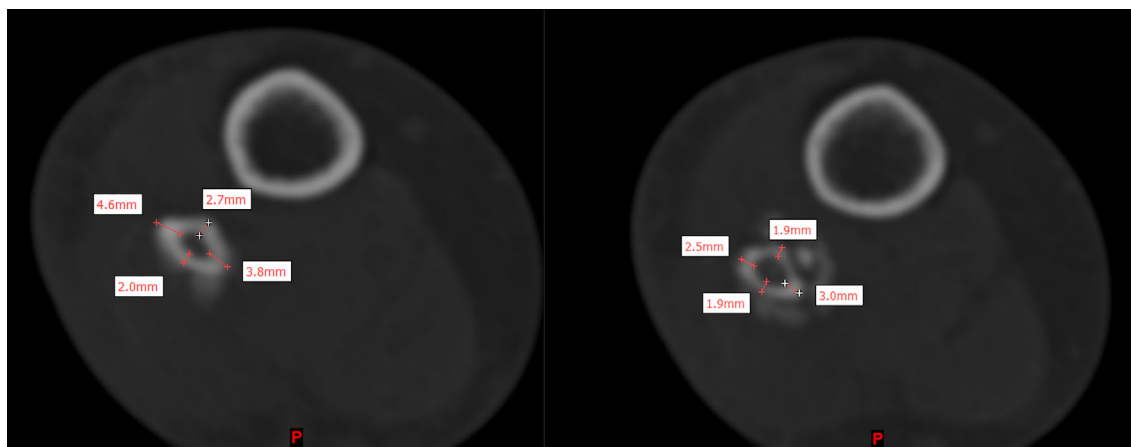
In the first case, the presence of the fracture was known before the second stage surgery. A conscious choice was made to proceed with the surgery as planned. It is unclear whether the implant placement itself caused the fracture or whether the fracture occurred later due to stress on the leg. As a result of the first case, a CT scan was added to the postoperative workflow in successive cases. In the second case, the fracture had not yet occurred at that moment or was not yet visible on the CT scan. The fracture was also unknown at the start of the second operation and only became apparent during the procedure.

Patel et al.<sup>10</sup> describe a case of a linear fracture of the fibula as a result of implant placement. They relate this to the high density of the fibula bone and recommend to always pre-tap the implant bed all the way to the apex. This has been done in both of our cases. Nevertheless, high stress on the dense cortical bone after placement of the implants is a likely causal factor. Even more than in intra-oral implant surgery, it seems advisable to predrill and place the implants and screws without applying force and to apply copious cooling.

In both cases, the fracture occurred in the distal part of the fibula transplant, near the two distal implants. It seems that the bone in the lower region of the fibula is



**FIGURE 6** Caudal view of the preoperative 3D planning of the mandible reconstruction consisting of three bony segments (case two). The osteotomy guides are also shown



**FIGURE 7** Thickness of the bony cortex of the fibula in the first case. Left: proximal. Right: Distally from the fracture

more vulnerable for unfavorable forces. The cortex of the fibula in our cases appeared to be thinner in the distal part around the fractures compared to the proximal part (Figure 7). In the second case, the cortex was even flattened and thereby made thinner for the implant placement. It is conceivable that the bone in the distal part is more weakened by the bicortically placed implants. That would explain why both fractures occurred at this position.

Both cases showed that a fracture can exist without obvious clinical signs. Both cases also showed that the intended planning can largely be adhered to and that a good result can be achieved in case of a fracture.

However, harvesting of the fractured fibula graft is significantly more complicated than usual by edema and fibrosis surrounding the graft and the vascular supply. This requires more time to safely dissect the blood vessels. Undoubtedly, an increased risk of vascular thrombosis and flap loss resulted from the subsequent inflammatory response.<sup>11</sup> The additional callus formation may hamper flap positioning and fixation. Time to healing and ossification of the transplant may be more uncertain. It seems prudent to avoid biting forces for a prolonged time to minimize movement of the bone segments. Even when rigid fixation cannot be achieved, the flap can survive, as long as the blood supply is adequate. With an adequate vascular perfusion of the flap, the callus formation will ossify into normal bone.

### 3 | CONCLUSION

These cases show that a fracture in complex oral reconstruction does not necessarily mean that the reconstruction will not be successful. Harvesting the flap will require more time and skill. Additional surgeries may be required to reposition or fixate the flap or to place additional implants. Flap survival is mostly dependent on a vital blood perfusion, which in case of closed fractures with healing tendency as described here might not be problematic yet challenging.

### ACKNOWLEDGMENTS

The authors thank F. J. Voskuil, MD, PhD, for his help in illustrating the manuscript.

### CONFLICT OF INTEREST STATEMENT

Paul M. N. Werker is DMC member for Fidia Ltd., Milan, Italy. Renumerations are used for research purposes.

### DATA AVAILABILITY STATEMENT

The data that support the findings of this study are available from the corresponding author upon reasonable request.

### ORCID

Martin P. Huizinga  <https://orcid.org/0009-0008-9087-6079>

### REFERENCES

1. Okay D, Shetawi AHA, Moubayed SP, Mourad M, Buchbinder D, Urken ML. Worldwide 10-year systematic review of treatment trends in fibula free flap for mandibular reconstruction. *J Oral Maxil Surg*. 2016;74:2526-2531.
2. Wijbenga JG, Schepers RH, Werker PMN, Witjes MJH, Dijkstra PU. A systematic review of functional outcome and quality of life following reconstruction of maxillofacial defects using vascularized free fibula flaps and dental rehabilitation reveals poor data quality. *J Plastic Reconstr Aesthetic Surg*. 2016;69:1024-1036.
3. Fatani B, Fatani JA, Fatani OA. Approach for mandibular reconstruction using vascularized free fibula flap: a review of the literature. *Cureus*. 2022;14:e30161.
4. Witjes MJH, Schepers RH, Kraeima J. Impact of 3D virtual planning on reconstruction of mandibular and maxillary surgical defects in head and neck oncology. *Curr Opin Otolaryngol*. 2018;26:108-114.
5. Rohner D, Kunz C, Bucher P, Hammer B, Prein J. Reconstruction of extended jaw defects using a prefabricated free vascularized fibula flap and ITI-implants. *Mund Kiefer Gesichtschir*. 2000;4:365-372.
6. Rohner D, Jaquiéry C, Kunz C, Bucher P, Maas H, Hammer B. Maxillofacial reconstruction with prefabricated osseous free flaps: a 3-year experience with 24 patients. *Plast Reconstr Surg*. 2003;112:748-757.
7. Schepers RH, Raghoobar GM, Vissink A, et al. Accuracy of fibula reconstruction using patient-specific CAD/CAM reconstruction plates and dental implants: a new modality for functional reconstruction of mandibular defects. *J Cranio Maxill Surg*. 2015;43:649-657.
8. Schepers RH, Kraeima J, Vissink A, et al. Accuracy of secondary maxillofacial reconstruction with prefabricated fibula grafts using 3D planning and guided reconstruction. *J Cranio Maxill Surg*. 2016;44:392-399.
9. Schepers RH, Raghoobar GM, Vissink A, et al. Fully 3-dimensional digitally planned reconstruction of a mandible with a free vascularized fibula and immediate placement of an implant-supported prosthetic construction. *Head Neck*. 2013;35:E109-E114.
10. Patel SY, Kim DD, Ghali GE. Maxillofacial reconstruction using vascularized fibula free flaps and endosseous implants. *Oral Maxil Surg Clin*. 2019;31:259-284.
11. Glass GE, Nanchahal J. Why haematomas cause flap failure: an evidence-based paradigm. *J Plastic Reconstr Aesthetic Surg*. 2012;65:903-910.

**How to cite this article:** Huizinga MP, Stenekes MW, Kraeima J, et al. Prefabricated fibula free flaps in reconstruction of maxillofacial defects: Two cases of transplanting a fractured fibula. *Head & Neck*. 2023;45(12):E67-E72. doi:10.1002/hed.27542