



Universiteit
Leiden

The Netherlands

Neonatal management and outcome in complicated monochorionic twins: what have we learned in the past decade and what should you know?

Groene, S.G.; Tollenaar, L.S.A.; Middeldorp, J.M.; Lopriore, E.

Citation

Groene, S. G., Tollenaar, L. S. A., Middeldorp, J. M., & Lopriore, E. (2022). Neonatal management and outcome in complicated monochorionic twins: what have we learned in the past decade and what should you know? *Best Practice And Research: Clinical Obstetrics And Gynaecology*, 84, 218-228. doi:10.1016/j.bpobgyn.2022.03.016

Version: Publisher's Version

License: [Licensed under Article 25fa Copyright Act/Law \(Amendment Taverne\)](#)

Downloaded from: <https://hdl.handle.net/1887/3753367>


Note: To cite this publication please use the final published version (if applicable).



Contents lists available at ScienceDirect

Best Practice & Research Clinical Obstetrics and Gynaecology

journal homepage: www.elsevier.com/locate/bpobgyn



19

Neonatal management and outcome in complicated monochorionic twins: What have we learned in the past decade and what should you know?



Sophie G. Groene^{a, b, *, 1}, Lisanne S.A. Tollenaar^{c, 1},
Johanna M. Middeldorp^c, Enrico Lopriore^a

^a Division of Neonatology, Willem-Alexander Children's Hospital, Dept. of Pediatrics, Leiden University Medical Center, Leiden, the Netherlands

^b Division of Molecular Epidemiology, Dept. of Biomedical Data Sciences, Leiden University Medical Center, Leiden, the Netherlands

^c Division of Fetal Therapy, Dept. of Obstetrics, Leiden University Medical Center, Leiden, the Netherlands

A B S T R A C T

Keywords:

Monochorionic twins
Twin-twin transfusion syndrome
Twin anemia polycythemia sequence
Selective fetal growth restriction
Monoamniotic twins

Monochorionic (MC) twin pregnancies are at increased risk of neonatal morbidity and mortality due to the shared placenta with vascular connections that can give rise to various complications, including twin-twin transfusion syndrome, twin anemia polycythemia sequence (TAPS), selective fetal growth restriction, and other hematological imbalances at birth. Each complication presents its own challenges and considerations in the neonatal period. Measurement of hemoglobin levels and reticulocyte count is required to establish a correct diagnosis. Placenta dye injection is needed to properly distinguish between the various conditions. Risk factors for adverse outcome in MC twins include prematurity, severe cerebral injury, and the type of MC pregnancy complication. We, therefore, recommend cerebral ultrasound examinations in all complicated MC twins at birth to rule out a severe brain injury. Lastly, we strongly encourage screening for hearing loss using automated auditory brainstem response in all spontaneous TAPS donors to prevent permanent speech development delay.

© 2022 Published by Elsevier Ltd.

* Corresponding author. Department of Pediatrics, Leiden University Medical Center, J6-S, Albinusdreef 2, 2333 ZA Leiden, the Netherlands.

E-mail address: S.G.Groene@lumc.nl (S.G. Groene).

¹ Both authors contributed equally to this work.

Introduction

Approximately, 70% of identical twins are monochorionic (MC), indicating that they share a single placenta with vascular connections on its surface allowing for intertwin blood flow [1]. This shared placenta can give rise to a spectrum of complications, among which twin-twin transfusion syndrome (TTTS), twin anemia polycythemia sequence (TAPS), selective fetal growth restriction (sFGR), and other hematological imbalances at birth (Fig. 1). Moreover, a proportion of MC twins is also monoamniotic (MA). All these complications contribute to an overall increased risk of perinatal morbidity and mortality in MC twin pregnancies [2].

In general, MC twins are often delivered prematurely with consequently increased risk of associated neonatal morbidity and mortality. In specific, each type of MC twin pregnancy complication presents in turn its own challenges and considerations with regard to the neonatal period and requires a different neonatal management approach. Knowledge of the antenatal pathophysiology is essential to make a proper risk assessment. This literature review will provide a complete overview of neonatal outcomes and management in the various types of complicated MC twins.

Twin-twin transfusion syndrome

There are two forms of TTTS: the classic form of TTTS, also termed chronic TTTS, which usually develops in the second trimester of pregnancy, and a more rare and not well understood form of TTTS, termed acute peripartum TTTS, which may develop during delivery in previously uncomplicated MC twin pregnancies.

Chronic TTTS

Chronic TTTS arises due to unbalanced feto-fetal blood flow through relatively large vascular anastomoses at the surface of the shared placenta. In one fetus, the donor twin, the chronic loss of blood will lead to hypovolemia, with subsequent oliguria and oligohydramnios. In the other fetus, the recipient twin, the large amount of received blood will lead to a hypervolemic circulation, in turn resulting in polyuria and subsequent polyhydramnios. TTTS may occur in up to 10% of MC pregnancies and can develop between 14 weeks and 30 weeks of gestation, with a median gestation of 20 weeks [3]. The antenatal diagnosis of TTTS is based on a large amniotic fluid discrepancy, detected through an ultrasound. The severity of TTTS is antenatally classified according to the Eurofetus or Quintero criteria [4,5]. If left untreated, mortality in TTTS ranges from 75 to 100% [6]. This high percentage is explained

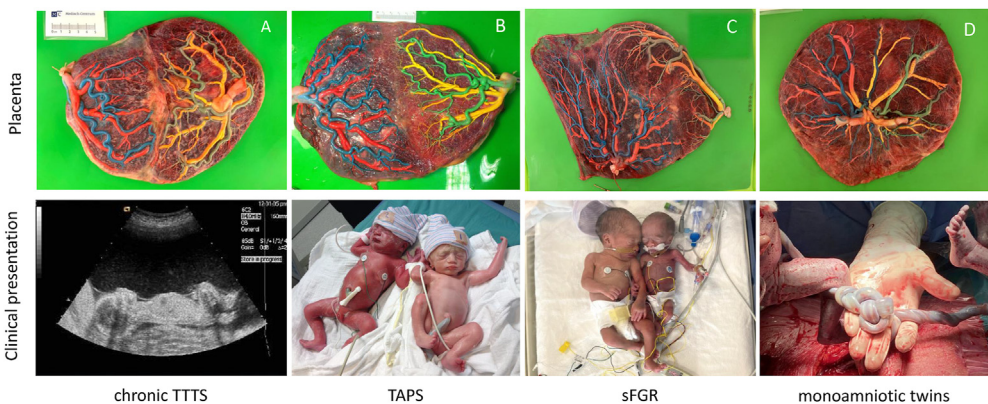


Fig. 1. An overview of MC twin placentas after colored dye injection and twin pairs per complication; (A) TTTS, (B) TAPS, (C) sFGR, and (D) MA twins with an example of an umbilical cord knot.

by an increased risk of premature preterm rupture of membranes (PPROM) and immature delivery, caused by the polyhydramnios putting pressure on the fetal membranes and the uterine wall.

Treatment options in TTTS are fetoscopic laser surgery, amniodrainage, and selective reduction. The best treatment for TTTS \geq stage 2 is fetoscopic laser surgery, an endoscopic intrauterine intervention in which the anastomoses at the placental surface are coagulated, thereby artificially separating the shared fetal circulation [7]. The preferred coagulation technique is the Solomon technique. With this approach, the anastomoses are coagulated one by one, whereafter a laser line is drawn from one placental margin to the other, connecting all coagulation spots, reducing the chance that minuscule invisible anastomoses are missed and left patent [8]. This procedure has lower rates of recurring TTTS and post-laser TAPS. In late TTTS (after 28 weeks), laser surgery is technically unfavorable, due to the greater distance to the placenta and the larger size of the anastomoses. When fetoscopic laser surgery is technically not feasible, or in case of brain injury or congenital abnormalities, selective reduction can be an option to increase the chances for healthy survival in the co-twin.

After the introduction of laser surgery, (intact) survival rates have greatly increased [7,9]. Overall survival is 73–74%, at least one survivor is reported in 85–87% of cases, and in 60–64% both children may survive [8]. However, the chances of adverse neonatal outcome still remain twice as high compared to the outcome of uncomplicated MC twins (26% vs. 13%, respectively) [10]. After laser surgery, the median gestational age at birth is 32 weeks [8]. Neonatal mortality occurs in approximately 5–8% of liveborn infants treated with laser [8,11]. Neonatal morbidity in TTTS treated with laser is mostly related to the degree of prematurity and includes respiratory distress syndrome (RDS), patent ductus arteriosus (PDA), necrotizing enterocolitis (NEC), and retinopathy of prematurity (ROP) [8,12]. The severe cerebral injury occurs in 5–10% of the treated TTTS survivors and can be a consequence of the TTTS itself or can be related to prematurity [9,13]. We, therefore, recommend to routinely perform cranial ultrasound examinations in all TTTS survivors at birth to rule out a severe cerebral injury. In the case of severe cerebral injury or a suspected case, MRI can be of additional value.

Some specific complications in TTTS may occur more in donors or recipients. Donors are more at risk for having coexisting FGR (which is detected in approximately two-third of treated TTTS cases) and therefore have a lower birth weight than their co-twins even after successful laser treatment [14]. Recipients are more at risk of cardiovascular disorders, in particular right ventricular outflow tract obstruction (RVOTO) in 3% of cases and persistent pulmonary hypertension of the neonate (PPHN) in 4% of cases [15,16]. Since the clinical presentation in the case of RVOTO and PPHN is associated with cyanosis and oxygen requirement, it may resemble other more common problems in preterm infants related to RDS. Neonatologists should be aware of this potential pitfall, as both disorders require prompt diagnosis and specific treatment with balloon valvotomy in case of RVOTO and inhaled nitric oxide and mechanical ventilation in the case of PPHN.

In rare cases, treated TTTS infants are born with amniotic bands wrapped around fingers or toes [17]. This so-called postprocedural pseudoamniotic band disruption sequence occurs in 2.2% of cases treated with laser surgery and primarily affects the lower extremities rather than the upper extremities, with risk for amputation in one-third of cases.

In TTTS not treated with laser, the risk of neonatal mortality and morbidity is very high, particularly due to the high risk of extreme preterm delivery [7]. The median gestational age at birth in TTTS treated with serial amnioreduction early in pregnancy is approximately 28 weeks. The risk of neonatal mortality is increased (up to 29%) as well as the risk of severe cerebral injury, particularly in recipient twins. As reported by Senat et al., the incidence of severe IVH in recipients was 9%, and the incidence of cystic PVL grade 3 or higher was 21% [7]. In 34% of donors, short-term renal dysfunction is detected shortly after birth [18]. This is likely to be a result of chronic hypovolemia and oliguria. Furthermore, in half of the TTS donors, low albumin and total protein levels are found, possibly as a result of chronic loss, or due to decreased production by the liver [19]. In recipients, limb ischemia can be seen, probably as a result of severe hyperviscosity and polycythemia [20].

After birth, color dye injection of the placenta is crucial to understand the pathophysiology of TTTS and evaluate whether the laser procedure is complete. Placentas from TTTS twins mainly show arterio-venous (AV) and veno-arterial (VA) anastomoses [21]. Compared to uncomplicated MC placentas, arterio-arterial (AA) anastomoses in TTTS placentas are less common. It is thought that AA anastomoses can compensate for differences in blood volumes due to their bidirectional character. The absence of an

AA anastomosis can therefore potentially contribute to the onset and progression of TTTS. Interestingly, VV anastomoses are more frequently seen in TTTS placentas than in placentas from uncomplicated twins [22]. The exact role of VV anastomoses is not understood. When examining the placenta, one should also pay attention to the placental sharing and type of umbilical cord insertion. Donors usually have a smaller placental share and a marginal/velamentous cord insertion, which is congruent with their relatively lower birth weight [14]. In placentas treated with laser, completeness of the laser surgery should be evaluated as residual anastomoses are associated with recurrent TTTS or post-laser TAPS [23].

Acute peripartum TTTS

Acute peripartum TTTS is a rare event that may occur in approximately 2% of MC twins during delivery [24]. Acute peripartum TTTS is thought to result from a rapid shift of blood through large bidirectional placental anastomoses from one fetus to the other, causing the donor twin to become hypovolemic and anemic, and the recipient twin to become hypervolemic and polycythemic. The exact pathological mechanism underlying this condition is not fully understood. Possibly, uterine contractions in combination with the relative positioning of the fetuses might lead to sudden differences in blood pressure, thereby creating a pressure gradient and affecting the blood flow between the twins. Cardiotocography registration during labor may show a sinusoidal pattern in the donor twin, indicating fetal anemia.

At birth, the donor twin is pale and may have signs of acute hemorrhagic shock, needing resuscitation with rapid fluid bolus and respiratory support. In severe cases, acute hemorrhage can lead to perinatal asphyxia in one-third of donors or even death [24]. Recipients have a plethoric skin color and may need a partial exchange transfusion to treat acute polycythemia.

Diagnosis of acute peripartum TTTS at birth is based on two criteria [1]: intertwin hemoglobin difference >8.0 g/dL with a reticulocyte count ratio <1.7 [2,24,25] presence of large superficial placental anastomoses (AA or VV) following color-dye injection [21]. Measurements of reticulocyte count are of primordial importance to distinguish acute peripartum TTTS from a more common cause of large intertwin Hb difference in MC twins, namely TAPS. The reticulocyte count ratio can be calculated by dividing the reticulocyte count (in ‰) of the donor by the reticulocyte count of the recipient. As donors in acute peripartum TTTS suffer from acute-onset anemia, there is no reticulocytosis, and therefore the reticulocyte count should be roughly comparable to that of the recipient twin. If color dye injection cannot be performed, the maternal surface of the placenta should be inspected. In contrast with TAPS, no color discordance between the two placental territories is found in acute peripartum TTTS [26].

Twin anemia polycythemia sequence

TAPS occurs as a result of slow chronic blood transfusion through minuscule placental anastomoses, leading to anemia in the donor twin and polycythemia in the recipient twin. TAPS may develop spontaneously in 3–5% of MC pregnancies or may arise in 2–16% of TTTS twins treated with laser surgery due to the presence of patent minuscule anastomoses [27–30]. In TAPS, there is no amniotic fluid discrepancy, as is seen in TTTS [31].

TAPS is diagnosed antenatally by ultrasound-Doppler measurement of the middle cerebral artery peak systolic velocity (MCA-PSV). The MCA-PSV value in the donor will be high, suggestive of fetal anemia, whereas the MCA-PSV value in the recipient will be low, suggestive of polycythemia. A difference in MCA-PSV > 0.5 multiples of the median (MoM) is indicative of TAPS [32]. The severity of TAPS antenatally is classified according to the updated classification system by Tollenaar et al. [32] Aside from Doppler measurement, other ultrasound markers may also suggest the presence of TAPS, including placental dichotomy with a hypopic hyperechogenic part for the donor twin and a flattened hypoechogenic part for the recipient twin [32]. Moreover, TAPS recipients may present with a starry-sky liver resulting from chronic polycythemia. In TAPS donors, cardiomegaly due to chronic anemia can be observed. The time of onset of spontaneous TAPS varies between 15 weeks and 35 weeks of gestation [33]. In post-laser TAPS, most cases are detected within the first month after laser for TTTS [34].

The optimal antenatal treatment for TAPS is unknown. Management options include expectant management, preterm delivery, intrauterine blood transfusion in the donor with or without an intrauterine partial exchange transfusion in the recipient (IUT/PET), fetoscopic laser surgery, and selective reduction. We are currently performing a randomized controlled trial (TAPS trial), comparing laser surgery to standard treatment (IUT/PET, expectant management, preterm delivery) ([clinicaltrials.gov](https://clinicaltrials.gov/identifier/NCT04432168) identifier NCT04432168).

Since MCA-PSV Doppler measurements are not part of routine care measured, TAPS is frequently missed antenatally and often first diagnosed only after birth [35,36]. The postnatal diagnosis of TAPS is based on an intertwin hemoglobin difference >8 g/dL [25]. To distinguish the condition from the similarly presenting acute peripartum TTTS, the reticulocyte count for both twins need to be measured, and the placenta should be injected with color dye. In contrast to acute peripartum TTTS, donors in TAPS have high reticulocyte counts due to chronic anemia, resulting in a reticulocyte count ratio >1.7 . Injection of a TAPS placenta will reveal the presence of only minuscule anastomoses (diameter <1 mm), mostly AV and VA, although minuscule AA and VV anastomoses are also reported in up to 17% and 9% of TAPS placentas, respectively [33,34]. The maternal side of the placenta typically shows a striking color difference, with a pale and sometimes hydropic placental territory for the donor and a plethoric placental share for the recipient [37]. This color difference is not observed in acute peripartum TTTS [26].

Results of an international TAPS registry have shown that spontaneous perinatal mortality occurs in 9% of spontaneous TAPS twins and 18% of post-laser TAPS twins, with donors having a 4-fold increased risk [33,34]. In spontaneous TAPS, perinatal mortality occurs in 12% of donors, compared to 5% of recipients [33]. In post-laser TAPS, the difference is even more striking: perinatal mortality occurs in 25% compared to 10% in recipients [34]. This difference in mortality between donors and recipients is primarily seen antenatally. After birth, spontaneous TAPS twins demonstrate similar risks for neonatal mortality [33]. In post-laser TAPS, donors are more at risk for neonatal mortality than recipients [34].

TAPS twins are born on average at 32 weeks of gestation [33,34]. Risk factors for neonatal morbidity in TAPS are low gestational age at birth and high antenatal TAPS stage. Both anemia and polycythemia can cause severe cerebral injury, which is reported to occur in 4% of spontaneous TAPS twins and 10% of post-laser TAPS twins, with similar rates for donors and recipients for both types of TAPS [33,34].

The neonatal management in TAPS calls for a different approach than in acute peripartum TTTS. In TAPS, donors with chronic anemia should be managed more cautiously, with a slower blood transfusion or, in case of mild anemia and sufficient erythropoiesis, no blood transfusion at all. Importantly, acute blood transfusions or volume bolus with saline in TAPS donors could even cause hemodynamic complications as these donors do not suffer from severe hypovolemia. Recipients in TAPS are at risk for developing polycythemia-hyperviscosity syndrome and may require treatment with PET to avoid complications such as skin necrosis and limb ischemia [20]. In addition, they often present with thrombocytopenia at birth, possibly due to impaired bone marrow production secondary to tissue hypoxia and impaired spleen perfusion [25]. Donor twins in TAPS often have low levels of albumin and total protein, which may partly explain the impaired fetal growth [38]. Furthermore, donors often have leukopenia and an increased risk for early-onset neonatal sepsis [39]. Preliminary data from our research group also shows that donors are also more often at risk of severe hypoglycemia, requiring prompt intervention with IV glucose bolus. Furthermore, donors are more prone to develop lactate acidosis at birth. Lactate acidosis may result from chronic intrauterine hypoxia caused by chronic fetal anemia, forcing the fetus to shift to anaerobic glycolysis. Just like in TTTS not treated with laser, TAPS donors may also experience short-term renal dysfunction shortly after birth, likely resulting from chronic renal hypoperfusion [40].

Studies into long-term outcome of TAPS twins have shown that donors are at risk for hearing impairment based on auditory neuropathy spectrum disorder (ANSD) [41]. This can be detected with neonatal hearing screening using automated auditory brainstem response (AABR). Importantly, ANSD will be missed with the standard neonatal hearing screening using otoacoustic emissions. To facilitate adequate treatment and prevent delay in language and speech development, neonatal AABR screening for all twins diagnosed with TAPS is strongly recommended.

Selective fetal growth restriction

sFGR occurs in up to 10–15% of MC twin pregnancies, sometimes in combination with other complications such as TTTS and TAPS and is characterized by a large intertwin growth discrepancy [42,43]. The pathophysiology of sFGR is associated with unequal placental sharing, resulting in discordant access to oxygen and nutrients *in utero* [44]. Multiple antenatal diagnostic criteria for sFGR are reported in the literature, such as an EFW discordance $\geq 20\%$, the combination of EFW < 10 th centile in one twin, an EFW discordance $\geq 25\%$, or the proposed Delphi consensus definition [45–47]. The postnatal diagnosis of sFGR is based on the presence of a birth weight discordance (BWD), calculated as follows: (birth weight larger twin - birth weight smaller twin)/birth weight larger twin $\times 100$ [45]. The cut-off for BWD in sFGR used in the literature varies between 20 and 25% [44,45,48].

In 2007, Gratacos et al. proposed an antenatal classification system for sFGR, which is currently widely used, based on the UA Doppler flow in the smaller twin [49]. Three types can be distinguished: Type I is characterized by positive end-diastolic flow (pEDF), Type II by persistent absent or reversed end-diastolic flow (A/REDF), and Type III by intermittent absent or reversed end-diastolic flow (iA/REDF). Each type is associated with its own specific placental characteristics following placental color dye injection as previously described by our group [44,50]. Type III cases present with the greatest placental share discordance and the largest diameter of arterio-arterial (AA) anastomoses. On the one hand, these large bidirectional anastomoses can be beneficial to the smaller twin, as they can allow for a rescue transfusion from the larger to the smaller twin that can compensate for the placental share discordance to some extent [51]. On the other hand, AA anastomoses can also lead to acute fetofetal transfusion in case of intrauterine fetal demise (IUFD) of one twin (in most cases, the smaller twin), in turn resulting in neurological damage or even IUFD of the other twin as well [52,53]. This makes the clinical course of sFGR Type III the most unpredictable [54,55].

At present, there is no consensus for the optimal antenatal management of MC twin pregnancies with sFGR [54,56–58]. This gap in knowledge still leads to high rates of (iatrogenic) prematurity following elective delivery when fetal distress is observed, especially in sFGR Type II and Type III. sFGR Type I cases are generally delivered between 33 and 36 weeks of gestational age, while Type II and Type III are delivered considerably earlier, namely between 30 and 32 weeks of gestational age [57,59–62]. Some case series even report a median gestational age at birth as low as 28 weeks [62]. As gestational age at birth is the main determinant of neonatal outcome, the discrepancies in the timing of delivery between the different types of sFGR lead to discrepancies in neonatal morbidity and mortality rates as well. Severe neonatal morbidity was reported in 0–28% of cases in Type I, 11–45% in Type II, and 18–62% in Type III [59,60]. Neonatal death occurred in 0–3% of Type I cases, 0–28% of Type II cases, and 1–19% of Type III cases [59,60]. Therefore, Type I appears to have the most favorable neonatal course.

Aside from the type of sFGR, the size of the twins can also be a risk factor for specific adverse neonatal outcomes. The larger twin is more at risk of acute respiratory distress at birth (34%) compared to the smaller co-twin (19%). In contrast, the smaller twin is more at risk of developing chronic lung disease later in life (17%) compared to the larger twin (7%) [48]. With regard to cerebral injury, a systematic review including eleven studies demonstrated that cerebral injury rates in sFGR were 8% (range: 0–33%) and associated with single IUFD, gestational age at birth ≤ 32 weeks, and UA Doppler abnormalities [52]. The risk of cerebral injury in the larger twin appears to occur primarily postnatally and seems to be related to the severity of prematurity. The smaller twin presents with more subtle changes in brain structure reflected as overall decrease in brain growth, which might have functional consequences later in life [63].

The effect of sFGR on long-term outcomes remains to be researched more extensively. A systematic literature review performed by our research group in 2018 identified five articles with varying validities, but all pointing to adverse neurodevelopmental outcomes for the smaller twin [64]. The current research focus on perinatal outcome after sFGR should increasingly be shifted to long-term outcome as well to provide both parents and caregivers with more insight into the childhood prognosis of sFGR.

Monoamniotic twins

Less than 1% of monozygotic twins are MA, sharing both a single placenta and a single amniotic sac during pregnancy. MA placentas are characterized by proximate cord insertions with large bidirectional anastomoses [65–68]. MA twins are at increased risk of perinatal morbidity and mortality due to a relatively high incidence of congenital abnormalities and the risk of umbilical cord entanglement or strangulation [69,70]. The most optimal gestational age at birth appears to be around 33, as this is the time when the prospective risk of IUFD becomes higher than the risk of neonatal morbidity and mortality [71]. Neonatal morbidity and mortality in MA twins are largely determined by prematurity and the presence of specific congenital abnormalities [70,72,73]. A recent review and meta-analysis including 685 MA twin pregnancies showed that MA twins are particularly at risk of respiratory morbidity and that this risk decreased with increasing gestational age at birth.

Monoamnioticity can also occur after fetoscopic laser surgery, when the intertwin membrane is perforated during the procedure. This is reported in 1–20% of cases [74–78]. Iatrogenic MA twins (iMAT) are at increased risk of PPROM and premature delivery when compared to lasered TTTS twins without membrane perforation, subsequently leading to a lower gestational age at birth and more neonatal morbidity and mortality [74–78]. This can be explained by the increased fetal surveillance and elective preterm delivery, similar to spontaneous MA twin pregnancies.

Other complications

A large Hb difference at birth in an otherwise uncomplicated MC twin pregnancy is a common phenomenon [79]. This unexpected Hb difference can occur due to acute peripartum TTTS, as described earlier in this review, or through placento-fetal transfusion during vaginal delivery. The latter may occur when, after cord clamping of the first-born twin, the second twin receives blood from both placental shares through large vascular anastomoses [79,80]. This phenomenon may explain why second-born twins in MC twins had a significantly higher Hb level at birth (16.7 vs. 15.9 g/dL) and more often presented with polycythemia (12% vs. 1%) as opposed to first-born twins [79,81]. Another potential cause of discordance in Hb levels at birth in twins is related to the timing of cord clamping. As previously suggested, obstetricians may tend to clamp the umbilical cord of the first-born twin earlier to focus their full attention to the delivery of the second twin [81]. Once the second twin is born and is doing well, obstetricians may then in turn tend to delay cord clamping. This may then lead to higher Hb levels in second-born twins and could also explain why a higher level of Hb is not only seen in second-born twins in MC twins but also in dichorionic twins [81]. Considering the multiple causes of Hb differences at birth in MC twins, we strongly advise to perform both hematological investigations (including Hb and reticulocyte count) and placental examination to distinguish between TAPS, acute TTTS, and placento-fetal transfusion [81].

Summary

MC twin pregnancies are at an increased risk of neonatal morbidity and mortality due to the shared placenta with vascular connections on its surface, which can give rise to various complications, including TTTS, TAPS, sFGR, and other hematological imbalances at birth. Moreover, a proportion of MC twins is also MA. Each complication in turn presents its own challenges and considerations during the neonatal period. In all complications, there is an increased risk of prematurity with its associated sequelae. Gestational age at birth remains the primary determinant of both short- and long-term outcome. Rate and type of neonatal morbidity and mortality also differ for donor and recipient in TTTS and TAPS, as well as for the larger and smaller twin in sFGR. We recommend to perform neonatal cerebral ultrasound in all complicated MC twins to rule out a severe brain injury. We also recommend to perform color dye examination of the placenta, in order to properly distinguish between the conditions. To establish a correct diagnosis, especially for acute TTTS, TAPS, or placento-fetal transfusion, a complete blood count should be measured, including hemoglobin and reticulocyte count. Lastly, TAPS donors should be screened for hearing loss using AABR to prevent permanent speech development delay.

Practice points

- TTTS survivors are at increased risk of cerebral injury, and recipient twins are at increased risk of cardiovascular complications including RVOTO and PPHN.
- Complete blood count, including hemoglobin and reticulocyte count, is required to reach a correct diagnosis, especially for acute TTTS, TAPS, or placento-fetal transfusion. This correct diagnosis is also crucial in making a proper risk assessment and applying appropriate neonatal treatment.
- Gestational age at birth is still one of the most important predictors of neonatal outcome.
- Colored dye injection of MC twin placentas after birth is recommended, as it provides insight into the pathophysiology of each specific MC twin complication.
- In general, TAPS donors are at increased risk for perinatal morbidity and mortality. Moreover, TAPS donors should be screened for hearing loss using AABR.
- In sFGR, the larger twin has an increased risk of acute respiratory distress at birth, while the smaller twin has an increased risk of chronic lung disease later in life.
- In MA twins, neonatal complications are largely determined by prematurity. The optimal gestational age for delivery is around 33 weeks.
- Long-term follow-up for all complicated MC twins is essential to further improve care for both twins and their parents.

Research agenda

- In TAPS, the best antenatal treatment option is still unknown. This is currently being investigated in the TAPS trial ([clinicaltrials.gov](https://clinicaltrials.gov/ct2/show/study/NCT04432168) identifier NCT04432168).
- The cause of increased risk for hearing loss and developmental delay in TAPS donors is not known and requires further investigation.
- In sFGR Types II and III, urgent studies are needed to determine the optimal timing for delivery, balancing between the risk of sudden fetal demise and the risk of prematurity.
- An adequate antenatal management protocol for sFGR needs to be determined to optimize both neonatal and long-term outcomes.

Acknowledgements

This work was supported by a grant from The Dutch Heart Foundation (S.G.) (Grant Number 2017T075).

Declaration of competing interest

The authors have no conflicts of interest.

References

- [1] Lewi L. Monochorionic diamniotic twins: what do I tell the prospective parents? *Prenat Diagn* 2020;40(7):766–75.
- [2] Lewi L, Jani J, Blickstein I, Huber A, Gucciardo L, Van Mieghem T, et al. The outcome of monochorionic diamniotic twin gestations in the era of invasive fetal therapy: a prospective cohort study. *Am J Obstet Gynecol* 2008;199(5).
- [3] Lewi L, Jani J, Blickstein I, Huber A, Gucciardo L, Van Mieghem T, et al. The outcome of monochorionic diamniotic twin gestations in the era of invasive fetal therapy: a prospective cohort study. *Am J Obstet Gynecol* 2008;199(5):514 e1–8.
- [4] Society for Maternal-Fetal M, Simpson LL. Twin-twin transfusion syndrome. *Am J Obstet Gynecol* 2013;208(1):3–18.
- [5] Quintero RA, Morales WJ, Allen MH, Bornick PW, Johnson PK, Kruger M. Staging of twin-to-twin transfusion syndrome. *J Perinatol* 1999;19:550–5.
- [6] Berghella V, Kaufmann M. Natural history of twin-twin transfusion syndrome. *J Reprod Med* 2001;46(5):480–4.
- [7] Senat MV, Deprest J, Boulvain M, Paupe A, Winer N, Ville Y. Endoscopic laser surgery versus serial amnioreduction for severe twin-to-twin transfusion syndrome. *N Engl J Med* 2004;351(2):136–44.

- [8] Slaghekke F, Lopriore E, Lewi L, Middeldorp JM, van Zwet EW, Weingertner AS, et al. Fetoscopic laser coagulation of the vascular equator versus selective coagulation for twin-to-twin transfusion syndrome: an open-label randomised controlled trial. *Lancet* 2014;383(9935):2144–51.
- [9] Slaghekke F, Lopriore E, Lewi L, Middeldorp JM, van Zwet EW, Weingertner AS, et al. Fetoscopic laser coagulation of the vascular equator versus selective coagulation for twin-to-twin transfusion syndrome: an open-label randomised controlled trial. *Lancet* 2014;383(9935):2144–51.
- [10] Lopriore E, Sueters M, Middeldorp JM, Oepkes D, Vandenbussche FP, Walther FJ. Neonatal outcome in twin-to-twin transfusion syndrome treated with fetoscopic laser occlusion of vascular anastomoses. *J Pediatr* 2005;147(5):597–602.
- [11] Senat MV, Deprest J, Boulvain M, Paupe A, Winer N, Ville Y. Endoscopic laser surgery versus serial amnioreduction for severe twin-to-twin transfusion syndrome. *N Engl J Med* 2004;351(2):136–44.
- [12] Tollenaar LSA, Slaghekke F, van Klink JMM, Groene SG, Middeldorp JM, Haak MC, et al. Twin-twin transfusion syndrome with anemia-polycythemia: prevalence, characteristics, and outcome. *J Clin Med* 2019;8(8).
- [13] Spruijt M, Steggerda S, Rath M, van Zwet E, Oepkes D, Walther F, et al. Cerebral injury in twin-twin transfusion syndrome treated with fetoscopic laser surgery. *Obstet Gynecol* 2012;120(1):15–20.
- [14] Groene SG, Tollenaar LSA, van Klink JMM, Haak MC, Klumper F, Middeldorp JM, et al. Twin-twin transfusion syndrome with and without selective fetal growth restriction prior to fetoscopic laser surgery: short and long-term outcome. *J Clin Med* 2019;8(7).
- [15] Eschbach SJ, ten Harkel ADJ, Middeldorp JM, Klumper FJCM, Oepkes D, Lopriore E, et al. Acquired right ventricular outflow tract obstruction in twin-to-twin transfusion syndrome: a prospective longitudinal study. *Prenat Diagn* 2018;38(13):1013–9.
- [16] Gijtenbeek M, Haak MC, ten Harkel DJ, de Pas AB, Middeldorp JM, Klumper FJCM, et al. Persistent pulmonary hypertension of the newborn in twin-twin transfusion syndrome: a case-control study. *Neonatology* 2017;112(4):402–8.
- [17] Knijnenburg PJ, Slaghekke F, Tollenaar LSA, Gijtenbeek M, Haak MC, Middeldorp JM, et al. Prevalence, risk factors, and outcome of postprocedural amniotic band disruption sequence after fetoscopic laser surgery in twin-twin transfusion syndrome: a large single-center case series. *Am J Obstet Gynecol* 2020;223(4).
- [18] Verbeek L, Joemmanbaks FA, Quak JME, Sukhai RN, Middeldorp JM, Oepkes D, et al. Renal function in neonates with twin-twin transfusion syndrome treated with or without fetoscopic laser surgery. *Eur J Pediatr* 2017;176(9):1209–15.
- [19] Verbeek L, Middeldorp JM, Hulzebos CV, Oepkes D, Walther FJ, Lopriore E. Hypoalbuminemia in donors with twin-twin transfusion syndrome. *Fetal Diagn Ther* 2013;33(2):98–102.
- [20] Lopriore E, Lewi L, Oepkes D, Debeer A, Vandenbussche FP, Deprest J, et al. In utero acquired limb ischemia in mono-chorionic twins with and without twin-to-twin transfusion syndrome. *Prenat Diagn* 2008;28(9):800–4.
- [21] de Villiers SF, Slaghekke F, Middeldorp JM, Walther FJ, Oepkes D, Lopriore E. Arterio-arterial vascular anastomoses in mono-chorionic placentas with and without twin-twin transfusion syndrome. *Placenta* 2012;33(8):652–4.
- [22] Zhao DP, Cambiaso O, Otano L, Lewi L, Deprest J, Sun LM, et al. Venovenous anastomoses in twin-twin transfusion syndrome: a multicenter study. *Placenta* 2015;36(8):911–4.
- [23] de Villiers SF, Slaghekke F, Middeldorp JM, Walther FJ, Oepkes D, Lopriore E. Placental characteristics in mono-chorionic twins with spontaneous versus post-laser twin anemia-polycythemia sequence. *Placenta* 2013;34(5):456–9.
- [24] Lopriore E, Holtkamp N, Sueters M, Middeldorp JM, Walther FJ, Oepkes D. Acute peripartum twin-twin transfusion syndrome: incidence, risk factors, placental characteristics and neonatal outcome. *J Obstet Gynaecol Res* 2014;40(1):18–24.
- [25] Lopriore E, Slaghekke F, Oepkes D, Middeldorp JM, Vandenbussche FP, Walther FJ. Hematological characteristics in neonates with twin anemia-polycythemia sequence (TAPS). *Prenat Diagn* 2010;30(3):251–5.
- [26] Tollenaar LSA, Zhao DP, Middeldorp JM, Oepkes D, Slaghekke F, Lopriore E. Can color difference on the maternal side of the placenta distinguish between acute peripartum twin-twin transfusion syndrome and twin anemia-polycythemia sequence? *Placenta* 2017;57:189–93.
- [27] Lopriore E, Slaghekke F, Middeldorp JM, Klumper FJ, Oepkes D, Vandenbussche FP. Residual anastomoses in twin-to-twin transfusion syndrome treated with selective fetoscopic laser surgery: localization, size, and consequences. *Am J Obstet Gynecol* 2009;201(1):66 e1–4.
- [28] Habli M, Bombrys A, Lewis D, Lim FY, Polzin W, Maxwell R, et al. Incidence of complications in twin-twin transfusion syndrome after selective fetoscopic laser photocoagulation: a single-center experience. *Am J Obstet Gynecol* 2009;201(4):417 e1–7.
- [29] Gucciardo L, Lewi L, Vaast P, Debska M, De Catte L, Van Mieghem T, et al. Twin anemia polycythemia sequence from a prenatal perspective. *Prenat Diagn* 2010;30(5):438–42.
- [30] Robyr R, Lewi L, Salomon LJ, Yamamoto M, Bernard JP, Deprest J, et al. Prevalence and management of late fetal complications following successful selective laser coagulation of chorionic plate anastomoses in twin-to-twin transfusion syndrome. *Am J Obstet Gynecol* 2006;194(3):796–803.
- [31] Lopriore E, Middeldorp JM, Oepkes D, Kanhai HH, Walther FJ, Vandenbussche FP. Twin anemia-polycythemia sequence in two mono-chorionic twin pairs without oligo-polyhydramnios sequence. *Placenta* 2007;28(1):47–51.
- [32] Tollenaar LSA, Lopriore E, Middeldorp JM, Haak MC, Klumper FJ, Oepkes D, et al. Improved prediction of twin anemia-polycythemia sequence by delta middle cerebral artery peak systolic velocity: new antenatal classification system. *Ultrasound Obstet Gynecol* 2019;53(6):788–93.
- [33] Tollenaar LSA, Slaghekke F, Lewi L, Colmant C, Lanna M, Weingertner AS, et al. Spontaneous twin anemia polycythemia sequence: diagnosis, management, and outcome in an international cohort of 249 cases. *Am J Obstet Gynecol* 2021 Feb 1; 224(2):213.e1–213.e11.
- [34] Tollenaar LSA, Lopriore E, Faiola S, Lanna M, Stirnemann J, Ville Y, et al. Post-laser twin anemia polycythemia sequence: diagnosis, management, and outcome in an international cohort of 164 cases. *J Clin Med* 2020;9(6).
- [35] Tollenaar LSA, Lopriore E, Faiola S, Lanna M, Stirnemann J, Ville Y, et al. Post-laser twin anemia polycythemia sequence: diagnosis, management, and outcome in an international cohort of 164 cases. *J Clin Med* 2020;9(6).
- [36] Slaghekke F, Kist WJ, Oepkes D, Pasman SA, Middeldorp JM, Klumper FJ, et al. Twin anemia-polycythemia sequence: diagnostic criteria, classification, perinatal management and outcome. *Fetal Diagn Ther* 2010;27(4):181–90.

- [37] Tollenaar LS, Zhao DP, Middeldorp JM, Slaghekke F, Oepkes D, Lopriore E. Color difference in placentas with twin anemia-polycythemia sequence: an additional diagnostic criterion? *Fetal Diagn Ther* 2016;40(2):123–7.
- [38] Verbeek L, Slaghekke F, Hulzebos CV, Oepkes D, Walther FJ, Lopriore E. Hypoalbuminemia in donors with twin anemia-polycythemia sequence: a matched case-control study. *Fetal Diagn Ther* 2013;33(4):241–5.
- [39] Visser GL, Tollenaar LSA, Bekker V, te Pas AB, Lankester AC, Oepkes D, et al. Leukocyte counts and other hematological values in twin-twin transfusion syndrome and twin anemia-polycythemia sequence. *Fetal Diagn Ther* 2020;47(2):123–8.
- [40] Verbeek L, Slaghekke F, Favre R, Vieujoz M, Cavigioli F, Lista G, et al. Short-term postnatal renal function in twin anemia-polycythemia sequence. *Fetal Diagn Ther* 2016;39(3):192–7.
- [41] Tollenaar LSA, Lopriore E, Slaghekke F, Oepkes D, Middeldorp JM, Haak MC, et al. High risk of long-term impairment in donor twins with spontaneous twin anemia polycythemia sequence. *Ultrasound Obstet Gynecol* 2020 Jan;55(1):39–46.
- [42] Zhu YD, Bian JY, Liao YP, Hu T, Wang MY, Chen YG, et al. Retrospective validation of 11–13 weeks' gestation ultrasound characteristics as predictive tools for twin-twin transfusion syndrome and selective intrauterine growth restriction in monochorionic diamniotic twin pregnancies. *Ann Transl Med* 2021;9(18).
- [43] Lewi L, Gucciardo L, Huber A, Jani J, Van Mieghem T, Done E, et al. Clinical outcome and placental characteristics of monochorionic diamniotic twin pairs with early- and late-onset discordant growth. *Am J Obstet Gynecol* 2008;199(5).
- [44] Groene SG, Tollenaar LSA, Slaghekke F, Middeldorp JM, Haak M, Oepkes D, et al. Placental characteristics in monochorionic twins with selective intrauterine growth restriction in relation to the umbilical artery Doppler classification. *Placenta* 2018;71:1–5.
- [45] Khalil A, Beune I, Hecher K, Wynia K, Ganzevoort W, Reed K, et al. Consensus definition and essential reporting parameters of selective fetal growth restriction in twin pregnancy: a Delphi procedure. *Ultrasound Obstet Gynecol* 2019;53(1):47–54.
- [46] Couck I, Ponnet S, Deprest J, Devlieger R, De Catte L, Lewi L. Outcome of monochorionic twin pregnancy with selective fetal growth restriction at 16, 20 or 30 weeks according to new Delphi consensus definition. *Ultrasound Obstet Gynecol* 2020;56(6):821–30.
- [47] Badr DA, Carlin A, Kang X, Sanchez TC, Olivier C, Jani JC, et al. Evaluation of the new expert consensus-based definition of selective fetal growth restriction in monochorionic pregnancies. *J Matern Fetal Neonatal Med* 2022 June;35(12):2338–44.
- [48] Groene SG, Spekman JA, Te Pas AB, Heijmans BT, Haak MC, van Klink JMM, et al. Respiratory distress syndrome and bronchopulmonary dysplasia after fetal growth restriction: lessons from a natural experiment in identical twins. *Eclinicalmedicine* 2021:32.
- [49] Gratacos E, Lewi L, Munoz B, Acosta-Rojas R, Hernandez-Andrade E, Martinez JM, et al. A classification system for selective intrauterine growth restriction in monochorionic pregnancies according to umbilical artery Doppler flow in the smaller twin. *Ultrasound Obstet Gynecol* 2007;30(1):28–34.
- [50] Lopriore E, Slaghekke F, Middeldorp JM, Klumper FJ, van Lith JM, Walther FJ, et al. Accurate and simple evaluation of vascular anastomoses in monochorionic placenta using colored dye. *JoVE* 2011;55:e3208.
- [51] Wang XJ, Shi HF, Li LY, Yuan PB, Zhao YY, Wei Y. The relationship between placental characteristics and birthweight discordance in different types of selective intrauterine growth restriction in monochorionic diamniotic twins: a single-center 7 year cohort study. *Prenat Diagn* 2021;41(12):1518–23.
- [52] Inklaar MJ, van Klink JM, Stolk TT, van Zwet EW, Oepkes D, Lopriore E. Cerebral injury in monochorionic twins with selective intrauterine growth restriction: a systematic review. *Prenat Diagn* 2014;34(3):205–13.
- [53] Townsend R, Khalil A. Twin pregnancy complicated by selective growth restriction. *Curr Opin Obstet Gynecol* 2016;28(6):485–91.
- [54] Bennasar M, Eixarch E, Martinez JM, Gratacos E. Selective intrauterine growth restriction in monochorionic diamniotic twin pregnancies. *Semin Fetal Neonatal Med* 2017;22(6):376–82.
- [55] Shinar S, Xing W, Pruthi V, Jianping C, Slaghekke F, Groene S, et al. Outcome of monochorionic twin pregnancy complicated by Type-III selective intrauterine growth restriction. *Ultrasound Obstet Gynecol* 2021;57(1):126–33.
- [56] Sukhwani M, Antolin E, Herrero B, Rodriguez R, de la Calle M, Lopez F, et al. Management and perinatal outcome of selective intrauterine growth restriction in monochorionic pregnancies. *J Matern Fetal Neonatal Med* 2021;34(23):3838–43.
- [57] Colmant C, Lapillonne A, Stirnemann J, Belaroussi I, Leroy-Terquem E, Kermovant-Duchemin E, et al. Impact of different prenatal management strategies in short- and long-term outcomes in monochorionic twin pregnancies with selective intrauterine growth restriction and abnormal flow velocity waveforms in the umbilical artery Doppler: a retrospective observational study of 108 cases. *BJOG An Int J Obstet Gynaecol* 2021;128(2):401–9.
- [58] Valsky DV, Eixarch E, Martinez JM, Crispi F, Gratacos E. Selective intrauterine growth restriction in monochorionic twins: pathophysiology, diagnostic approach and management dilemmas. *Semin Fetal Neonatal Med* 2010;15(6):342–8.
- [59] Townsend R, D'Antonio F, Sileo FG, Kumbay H, Thilaganathan B, Khalil A. Perinatal outcome of monochorionic twin pregnancy complicated by selective fetal growth restriction according to management: systematic review and meta-analysis. *Ultrasound Obstet Gynecol* 2019;53(1):36–46.
- [60] Buca D, Pagani G, Rizzo G, Familiari A, Flacco ME, Manzoli L, et al. Outcome of monochorionic twin pregnancy with selective intrauterine growth restriction according to umbilical artery Doppler flow pattern of smaller twin: systematic review and meta-analysis. *Ultrasound Obstet Gynecol* 2017;50(5):559–68.
- [61] Monaghan C, Kalafat E, Binder J, Thilaganathan B, Khalil A. Prediction of adverse pregnancy outcome in monochorionic diamniotic twin pregnancy complicated by selective fetal growth restriction. *Ultrasound Obstet Gynecol* 2019;53(2):200–7.
- [62] Aquino C, Baiao AER, de Carvalho PRN. Perinatal outcome of selective intrauterine growth restriction in monochorionic twins: evaluation of a retrospective cohort in a developing country. *Twin Res Hum Genet* 2021;24(1):37–41.
- [63] Groene SG, de Vries LS, Slaghekke F, Haak MC, Heijmans BT, de Bruin C, et al. Changes in structural brain development after selective fetal growth restriction in monochorionic twins. *Ultrasound Obstet Gynecol* 2022;59(6):747–55.
- [64] Groene SG, Tollenaar LSA, Oepkes D, Lopriore E, van Klink JMM. The impact of selective fetal growth restriction or birth weight discordance on long-term neurodevelopment in monochorionic twins: a systematic literature review. *J Clin Med* 2019;8(7).
- [65] Umur A, van Gemert MJC, Nikkels PGJ. Monoamniotic-versus diamniotic-monochorionic twin placentas: anastomoses and twin-twin transfusion syndrome. *Am J Obstet Gynecol* 2003;189(5):1325–9.

- [66] Murgano D, Khalil A, Prefumo F, Van Mieghem T, Rizzo G, Heyborne KD, et al. Outcome of twin-to-twin transfusion syndrome in monochorionic monoamniotic twin pregnancy: systematic review and meta-analysis. *Ultrasound Obstet Gynecol* 2020;55(3):310–7.
- [67] Zhao DP, Peeters SHP, Middeldorp JM, Klumper FJ, Duan T, Oepkes D, et al. Monochorionic placentas with proximate umbilical cord insertions: definition, prevalence and angio-architecture. *Placenta* 2015;36(2):221–5.
- [68] Hack KEA, van Gemert MJC, Lopriore E, Schaap AHP, Eggink AJ, Elias SG, et al. Placental characteristics of monoamniotic twin pregnancies in relation to perinatal outcome. *Placenta* 2009;30(1):62–5.
- [69] Lewi L. Cord entanglement in monoamniotic twins: does it really matter? *Ultrasound Obstet Gynecol* 2010;35(2):139–41.
- [70] Rossi AC, Prefumo F. Impact of cord entanglement on perinatal outcome of monoamniotic twins: a systematic review of the literature. *Ultrasound Obstet Gynecol* 2013;41(2):131–5.
- [71] van Mieghem T, Abbasi N, Shinar S, Keunen J, Seaward G, Windrim R, et al. Monochorionic monoamniotic twin pregnancies. *Am J Obstet Gynecol* 2022 Mar;4(S2).
- [72] Glinianaia SV, Rankin J, Khalil A, Binder J, Waring G, Sturgiss SN, et al. Prevalence, antenatal management and perinatal outcome of monochorionic monoamniotic twin pregnancy: a collaborative multicenter study in England, 2000–2013. *Ultrasound Obstet Gynecol* 2019;53(2):184–92.
- [73] Cordero L, Franco A, Joy SD. Monochorionic monoamniotic twins: neonatal outcome. *J Perinatol* 2006;26(3):170–5.
- [74] Peeters SHP, Stolk TT, Slaghekke F, Middeldorp JM, Klumper FJ, Lopriore E, et al. Iatrogenic perforation of intertwin membrane after laser surgery for twin-to-twin transfusion syndrome. *Ultrasound Obstet Gynecol* 2014;44(5):550–6.
- [75] Gordon BJ, Chon AH, Korst LM, Llanes A, Miller DA, Chmait RH. Incidental septostomy after laser surgery for twin-twin transfusion syndrome: perinatal outcomes and antenatal management. *Fetal Diagn Ther* 2018;44(4):285–90.
- [76] Li WF, Chao AS, Chang SD, Cheng PJ, Yang LY, Chang YL. Effects and outcomes of septostomy in twin-to-twin transfusion syndrome after fetoscopic laser therapy. *Bmc Pregnancy Childb* 2019;19(1).
- [77] Habli M, Bombrys A, Lewis D, Lim FY, Polzin W, Maxwell R, et al. Incidence of complications in twin-twin transfusion syndrome after selective fetoscopic laser photocoagulation: a single-center experience. *Am J Obstet Gynecol* 2009;201(4).
- [78] Brock CO, Bergh EP, Hernandez-Andrade EA, Ruano R, Johnson A, Papanna R. Risk factors and outcomes following septostomy during fetoscopic surgery for twin-to-twin transfusion syndrome. *J Clin Med* 2021;10(16).
- [79] Verbeek L, Zhao DP, Te Pas AB, Middeldorp JM, Hooper SB, Oepkes D, et al. Hemoglobin differences in uncomplicated monochorionic twins in relation to birth order and mode of delivery. *Twin Res Hum Genet* 2016;19(3):241–5.
- [80] Groene SG, Tollenaar LSA, van der Meeren LE, Slaghekke F, Verweij EJ, Hooper SB, et al. Large hemoglobin differences at birth in monochorionic twins with a placental chorangioma and delayed cord clamping twin. *Res Hum Genet* 2021 Oct;24(5):281–4.
- [81] Verbeek L, Zhao DP, Middeldorp JM, Oepkes D, Hooper SB, Te Pas AB, et al. Haemoglobin discordances in twins: due to differences in timing of cord clamping? *Arch Dis Child Fetal Neonatal Ed* 2017;102(4):F324–8.