

**MAXILLARY SINUS DIMENSIONS WITH RESPECT TO THE POSTERIOR SUPERIOR
ALVEOLAR ARTERY DECREASE WITH TOOTH LOSS**

Miguel Velasco-Torres¹, Miguel Padial-Molina¹, Jose A. Alarcón², Francisco O'Valle³,
Andrés Catena⁴, Pablo Galindo-Moreno¹.

1 Department of Oral Surgery and Implant Dentistry. School of Dentistry, University of Granada,
Granada (Spain).

2 Department of Orthodontics, Faculty of Odontology, University of Granada.

3 Department of Pathology. School of Medicine & IBIMER, University of Granada.

4 Department of Experimental Psychology. School of Psychology, University of Granada.

Corresponding author:

Dr. Pablo Galindo-Moreno

C/ Recogidas, 39 5º Izq.

18005 Granada, Spain

TEL: +34 958 520658

FAX: +34 958 520658

E-mail: pgalindo@ugr.es

Running title: Maxillary sinus shrinks as teeth are lost

Abstract word count: 249 **Manuscript word count:** 2837

Number of references: 25 **Number of figures:** 5

Number of tables: 4

ABSTRACT

Background: The posterior superior alveolar (PSA) artery is frequently encountered in the area where the lateral osteotomy is performed during direct sinus augmentation procedures.

Objective: To investigate the correlation between patient-dependent variables and measurements related to PSA using cone-beam computed tomography (CBCT) data.

Methods: A total of 394 individual CBCT scans were evaluated to assess the presence of the PSA artery and its diameter and distance to the sinus floor and to alveolar crest. Patient's age, gender and edentulism status (dentate, partially edentulous, or completely edentulous) were recorded.

Results: The PSA artery tends to be wider in older patients. Distance from the PSA artery to the sinus floor or the alveolar crest tend to be shorter in women and in partially and completely edentulous patients compared to dentate. Also, as those distances decrease, the medio-lateral width of the sinus increases.

Conclusions: Tooth loss leads to maxillary sinus vertical collapse with respect to the PSA artery. The position of the artery is stable, so the medio-lateral dimensions at different heights from the floor increase.

Practical Implications: The distances from the PSA to the sinus floor and the alveolar crest are smaller in edentulous patients, which potentially increases the risk of injury during a lateral window maxillary sinus lift. Because of the pyramidal shape of the sinus and the stable position of the artery, when the distance to the sinus floor decrease, the medio-lateral dimensions of the sinus at different heights increase, which may complicate the technique and decrease the outcomes.

Key Words: Computer Tomography, Radiology, Maxilla, Edentulism, Bone Loss

INTRODUCTION

The blood supply of the maxillary sinus is provided by the three main branches of the maxillary artery: the posterior superior alveolar (PSA) artery, the infraorbital artery, the descendent palatine artery and the sphenopalatine artery¹⁻³. The anatomical relations of these vessels are particularly relevant in dental implantology, among other oral surgery procedures. Maxillary sinus floor elevation prior to dental implant placement can be performed via either lateral or crestal approach. The lateral approach technique requires accessing the maxillary sinus via a lateral window. This procedure implies the risk of injuring blood vessels present in the area, typically the PSA artery. The likelihood and severity of the hemorrhage mainly depends on the diameter of the vessel⁴⁻⁶. Therefore, it is of extreme importance to perform an adequate presurgical study of the area using advanced imaging techniques, such as cone beam computed tomography (CBCT).

Following loss of posterior teeth, it is generally acknowledged that the maxillary sinus undergoes a remodeling process that has been classically described as pneumatization, which involves an increase in size and volume of the antral cavity. This would presumably modify the relative location of the main vessels in the area respective to other anatomical landmarks. Therefore, it is very important to know where those vessels are located prior to any surgical intervention. Several factors and patient's variables, such as age, gender, dentition status, as well as sinus volume, height and width, may influence the location of the artery. It is also important to know how osseous structures may change in relation to stable anatomical landmarks, such as the PSA artery, depending on those previously mentioned variables.

Therefore, it was the aim of this cross-sectional study to investigate the location of the PSA artery and the correlation that may exist between patient-dependent variables and dimensional variations of the maxillary sinus using cone-beam computed tomography (CBCT) scans.

MATERIAL AND METHODS

Population

This cross-sectional study was reviewed and approved by the Ethics Committee for Human Research of the University of Granada (approval number: 46/CEIH/2015). The population consisted of a random sample of 400 CBCTs obtained at the Center for Radiological Diagnosis (Granada, Spain) that was retrieved and unlabeled, except for age and gender. Patients were allocated into one of three possible subgroups of edentulism status (D=dentate; PE=partially edentulous; or E=completely edentulous), and subsequently organized by age and gender. Partially edentulous patients were defined as those missing any tooth by hemi-arcade, excluding third molars.

Cone-beam computed tomography (CBCT)

All samples were captured using the same equipment (Next Generation i-CAT, Imaging Sciences International Inc., Hatfield, PA, USA) and the same settings (120 KVp, 5 mA in complete rotatory mode, a 16x8 cm field of view, with an acquisition time of 8.9 sec and 0.3 mm as voxel size). CBCT images reflecting any movement artifact, or evident surgery or deformities in the area were excluded from the analysis.

Radiographic measurements

A proprietary software (i-CAT Vision, Imaging Sciences International, Inc. Hatfield Pennsylvania, USA) was used to obtain measurements related to both sinuses in each patient (R=right; L=left). A calibrated, experienced oral and maxillofacial radiologist (MVT) performed all the measurements. All measurements were repeated twice after at least one week to minimize any measurement bias.

First, all reconstructions were reformatted to position the Frankfurt plane horizontally, and the mid sagittal plane centered in the coronal and axial planes. Subsequently, the following measurements were performed:

1. Presence/absence of the PSA artery in the external wall of the maxillary sinus visualized in coronal planes. For diameter measurements, only vessels bigger than 1mm in diameter were considered.
2. Distance from the PSA artery to the floor of the sinus and to the crest of the bone at the most caudal location of the artery (Figure 1).
3. Diameter of the PSA artery at the previously mentioned location.
4. Additional measurements of the maxillary sinus anatomy, including sinus volume, height from the alveolar crest and the sinus floor to the meatus and medio-lateral dimensions at different heights from the floor (5, 10 and 15 mm) were also used.

Statistical analysis

All measurements were included into an SPSS database (IBM SPSS Inc., v16.0, Chicago, IL, USA) and analyzed. Given the absence of normal distribution of the artery diameter and the distance to the sinus floor (Shapiro-Wilk test), logarithmic transformation of these data was performed to improve normality fitting, and was used for the analysis of variance. Correlations were then explored by Spearman's test. Partial correlations used the log-transformed values. Significance was established at an alpha value of 0.05. Unless otherwise noted, values were represented as a mean (SD) in mm.

RESULTS

A total of 394 individual CBCT scans were evaluated. The intra examiner reliability was 0.975.

The sample analyzed has been previously described in terms of volume, distances from the meatus to the sinus floor and the alveolar crest and medio-lateral dimensions at different heights (5, 10 and 15 mm) and correlated with age, gender and edentulism ⁷. For the current study, analysis of the images found 304 (77.15%) patients presenting bilateral arteries. 327 (82.99%) and 340 (86.29%) cases were located in the right and left sinus, respectively. Of these, only 71 (18.02%) and 101 (25.64%) (right and left, respectively) were wider than 1 mm in diameter. All relevant descriptive data is summarized in Tables 1-4.

Significant right to left positive correlations were found for the distances to the alveolar crest ($r=0.534$, $p<0.001$) and to the sinus floor ($r=0.537$, $p<0.001$), but not for artery diameter. Additionally, distance to the alveolar crest positively correlated to distance to the sinus floor on each hemi-maxilla ($r=0.229$, $p<0.001$; $r=0.187$, $p<0.001$; right and left, respectively).

With respect to artery diameter, it was observed that the older the patient, the wider the artery ($r=0.236$, $p<0.018$; left maxilla) (Figure 2). Distance from the artery to the sinus floor significantly correlated with gender ($r=-0.195$, $p<0.001$; $r=-0.203$, $p<0.001$; right and left), being shorter in women. Similarly, distance from the artery to the sinus floor also correlated with age ($r=-0.131$, $p<0.022$; right maxilla), being shorter as the age increases (Figure 3). In contrast, neither gender nor age correlated with distance to the alveolar crest. Controlling by edentulous status, distance from the artery to the sinus floor ($r=-0.136$, $p<0.017$, right maxilla) (Figure 4) and distance to the alveolar crest ($r=-0.173$, $p<0.002$; $r=-0.146$, $p<0.007$; right and left) (Figure 5) were significantly correlated. When analyzing this particular aspect in depth by ANOVA with Bonferroni post-hoc, the only significant differences were found for the distance to the alveolar crest comparing completely edentulous patients with dentate ($p<0.003$, $p<0.015$) and partially edentulous patients ($p<0.002$, $p<0.017$) (right, left).

Further analyses to clarify the specific influence of age, gender and edentulism were also performed. Thus, in dentate patients, artery diameter increased with age ($r=0.716$, $p<0.020$;

right maxilla), and distance to the alveolar crest correlated with distance to the sinus floor ($r=0.299$, $p<0.006$, right; $r=0.283$, $p<0.008$, left). When correlating these data with sinus volume in this group of patients, only distance to the sinus floor correlated with volume ($r=0.554$, $p<0.001$, right; $r=0.518$, $p<0.001$, left). No other significant correlations were found when performing partial correlation analysis controlled by age and gender, age alone or gender alone.

In partially edentulous subjects, distance to the alveolar crest positively correlated with distance to the sinus floor ($r=0.164$, $p<0.044$, right; $r=0.229$, $p<0.003$, left), but negatively with volume ($r=-0.200$, $p<0.020$, right; $r=-0.249$, $p<0.003$, left). No other significant correlations were found when performing partial correlation analysis controlled by age and gender, age alone or gender alone.

Finally, in completely edentulous patients, more distance to the alveolar crest correlated with more distance to the sinus floor ($r=0.259$, $p<0.034$, right) and less volume ($r=-0.286$, $p<0.021$, right; $r=-0.300$, $p<0.014$, left). However, more distance to the sinus floor was accompanied by more volume ($r=0.318$, $p<0.012$, right; $r=0.528$, $p<0.001$, left).

The analysis of the distances to the artery with previous data (distance from the sinus floor and the alveolar crest to the meatus and from the medial to the lateral wall) was also performed. Thus, 1) the distance from the floor to the meatus correlates with the distance from the floor to the artery ($r=0.547$, $p<0.001$; $r=0.521$, $p<0.001$; right and left); 2) the distance from the alveolar crest to the meatus correlates with the distance from the crest to the artery ($r=0.243$, $p<0.001$; $r=0.230$, $p<0.001$; right and left); 3) as the distance from the artery to crest increases, the medio-lateral measurements at 10 and 15 mm from the floor decrease ($r=0.218$, $p<0.001$ and $r=-0.220$, $p<0.001$; right, 10 and 15mm; $r=-0.226$, $p<0.001$; $r=-0.285$, $p<0.001$; left, 10 and 15mm); and, finally, 4) as the distance from the artery to the sinus floor increases,

the medio-lateral measurements decreases ($r=-0.208$, $p<0.001$; $r=-0.154$, $p<0.007$; right, 5 and 10mm; $r=-0.201$, $p<0.001$; left, 5 mm).

DISCUSSION

The PSA artery is located on the lateral wall of the maxillary sinus. In a range of 10 to 30 % of the cases, the artery is located in the area where the lateral window is created for sinus floor elevation techniques ^{8,9}. Depending on the artery diameter, the osteotomy can lead to artery damage and provoke profuse bleeding ¹⁰, which is the second most frequent complication of sinus floor elevation ^{4,11}. When this complication occurs, visibility is reduced and the possibility of Schneiderian membrane perforation is increased ¹². Management of this complication is difficult when the artery diameter is large. Some suggest that the use of piezoelectric devices to do the lateral osteotomy can be helpful to reduce the incidence of hemorrhages associated with PSA artery damage. Others recommend changing the osteotomy window shape and location ¹⁰. In any case, it is essential to conduct a profound presurgical study, so that the technique can be modified accordingly and potential complications may be limited. Cadaveric studies confirm the presence of the artery in 100% of the cases ^{1,2,13}. The use of CBCT images has been shown to be a good tool for diagnosing the area and identifying important anatomical structures such as the artery ^{14,15}, specifically when it is bigger than 0.5 mm ⁵. Presence and size of the artery has been correlated and classified according to the intraosseous canal in: 1) No identification of intraosseous canal; 2) Diameter of intraosseous canal < 1 mm; 3) Diameter of intraosseous canal 1–2 mm; 4) Diameter of intraosseous canal 2–3 mm ¹⁶. Additionally, arteries smaller than 1 mm can be successfully managed in the event of an injury and do not usually provoke brisk and prolonged hemorrhage ¹⁷. Therefore, in CBCT studies, a limit of 1 mm is usually established for measuring artery diameter ^{16,18,19}. Thus, the prevalence of arteries wider than 1 mm lowers to around 50 % ^{5,16,18,19}. In the current study, the artery was detectable in around 83-86% of the patients but only 20-25%

showed arteries wider than 1 mm. These findings are similar to those of Ilguy et al. (89.3%)²⁰ and Anamali et al. (92.7%)²¹ but higher than those reported by Guncu et al. (64.5%)²², Mardinger et al. (55%)¹⁶ and Rosano et al. (47%)¹³. These differences might be due to the use of CBCT equipments similar to the one used in the current study^{20,21} vs. conventional CTs^{13,16,22}, which are known to have less resolution, and, therefore, are less useful to identify small structures.

Previous studies have correlated the location of the artery with sinus anatomy and surgical procedures^{5,8,13,16,18-20,22,23}. An overall conclusion is, as mentioned earlier, that careful analysis of the vascular anatomy of the maxillary sinus is essential to prevent complications during surgical interventions. Similar to our observations, no differences were found between identification of the artery on the right and the left side¹⁹. Significant right to left positive correlations were found for the distances to the alveolar crest ($r=0.534$, $p<0.001$) and to the sinus floor ($r=0.537$, $p<0.001$). Additionally, distance to the alveolar crest positively correlated to distance to the sinus floor on each hemi-maxilla ($r=0.229$, $p<0.001$; $r=0.187$, $p<0.001$; right and left, respectively). These data reflect symmetry on artery location and, indirectly, on the height of alveolar crest, which is also similar to previous findings¹⁸. The average distance to the crest in our study (13.40 ± 3.72 mm) differs from previous reports. In a Turkish population, the mean distance to the crest was 18 ± 4.9 mm²², while in a Brazilian and Northamerican population it was 16.88 ± 3.46 mm²⁰ and 16.0 ± 3.5 mm⁵, respectively. These differences are important to be considered as they may reflect a population variability to take into account when performing a surgery on these patients. Also, the specific place where the measurement was taken may explain the discrepancy. As shown by Mardinger et al.¹⁶, the artery follows a descending and the ascending path in the antero-posterior direction, with the lowest point at approximately 20 mm from the posterior antral wall. In the current study, the measure was performed at the lowest point of the artery on its route while in other studies is

not specifically mentioned ^{5,20,22}. In addition, it is important to know the correlation between the location of the artery and the height of the ridge. Although the current study did not specifically measure this distance, a direct correlation between the distance to the crest and to the floor was observed in all patients. Similar findings have been previously reported ^{16,22}.

Artery diameter in the current study is similar to previous findings, approximately 1.2 mm ^{1,2,18,22}. It has been previously concluded that age does not significantly correlate with the diameter of the artery ²², although the contrary has also been reported ¹⁶. In the current sample population, age directly correlated with artery diameter, specifically on the left side: the older the patient, the wider the artery ($r=0.236$, $p<0.018$). As a consequence, the risk for major complications if the artery is severed during sinus augmentation is also related with age. Additionally, the older the patient, the lower distance from the artery to the sinus floor. This is important since the reduction of this distance determines a reduction on the area available to relocate the window to the sinus. Therefore, in older patients, more care has to be taken during window opening to avoid damaging the artery, which in fact tends to be of bigger size and, thus, complications could also be more problematic.

Other important findings in the current study were that the dentition status influenced the location of the artery in relation to the sinus floor, the alveolar crest, the sinus volume and the distances from the sinus floor and the alveolar crest to the meatus. These findings may also explain some of the previously mentioned differences in the distances to alveolar crest or the sinus floor when comparing this study with previous reports. Overall, the distance to the alveolar crest significantly decreases when teeth are lost, particularly in completely edentulous patients but not significant in partially edentulous, which was expected (i.e., the alveolar process resorbs and completely collapse when teeth are extracted). However, it has been usually described that after teeth are lost, beside the alveolar process resorption, the maxillary sinus also undergoes a pneumatization process that leads to its expansion ²⁴⁻²⁶. The

current study demonstrates the opposite. From the data obtained in this analysis, the distance from the artery to the sinus floor was not significantly influenced by dental status, although this distance correlated with maxillary sinus volume, which could have been expected. In other words, the sinus floor is stable with respect to the artery. Does this mean that the artery also move as teeth are lost? Further analysis including previous data from the same population into the current analysis makes it possible to answer “no” to that question based on 2 findings: 1) the distance from the floor of the sinus to the meatus decreases equally as the distance from the floor to the artery; and, 2) the distance from the alveolar crest to the meatus decreases equally as the distance from the crest to the artery. Therefore, considering the meatus to be a stable anatomical landmark not affected by tooth lost, the artery should also be considered a stable anatomical structure, at least in the vertical dimension. However, as the distances to either the sinus floor or the alveolar crest decrease, the distances from the medial to the lateral wall increase. Therefore, it can be concluded that as the teeth are lost, there is a vertical collapse that leads to an increase on the medio-lateral measurements at 5, 10 and 15 mm from the sinus floor given its pyramidal shape, which additionally influences histological results of the maxillary sinus grafting techniques ²⁷. To confirm if this is just a geometrical effect or a true lateral expansion due to changes in biomechanical requirements, more studies are needed.

CONCLUSION

As an important clinical consequence drawn from the data shown in the current study, when the teeth are lost the maxillary sinus collapse vertically and, as a consequence, the medio-lateral distances at different heights from the floor increase, as demonstrated by changes in the dimensions of the sinus with respect to the posterior superior alveolar artery.

ACKNOWLEDGEMENTS

The authors declare no conflict of interest, either directly or indirectly, in any of the products listed in the manuscript.

This investigation was partially supported by Research Groups #CTS-138 and #CTS-583 (Junta de Andalucía, Spain) and by the Andalucía Talent Hub Program from the Andalusian Knowledge Agency, co-funded by the European Union's Seventh Framework Program, Marie Skłodowska-Curie actions (COFUND – Grant Agreement n° 291780) and the Ministry of Economy, Innovation, Science and Employment of the Junta de Andalucía (MPM).

REFERENCES

1. Solar P, Geyerhofer U, Traxler H, Windisch A, Ulm C, Watzek G. Blood supply to the maxillary sinus relevant to sinus floor elevation procedures. *Clin Oral Implants Res.* 1999;10(1):34-44.
2. Traxler H, Windisch A, Geyerhofer U, Surd R, Solar P, Firbas W. Arterial blood supply of the maxillary sinus. *Clin Anat.* 1999;12(6):417-421. doi:10.1002/(sici)1098-2353(1999)12:6<417::aid-ca3>3.0.co;2-w.
3. Rosano G, Taschieri S, Gaudy J-F, Del Fabbro M. Maxillary sinus vascularization: a cadaveric study. *J Craniofac Surg.* 2009;20(3):940-943. doi:10.1097/SCS.0b013e3181a2d77f.
4. Chan HL, Wang HL. Sinus pathology and anatomy in relation to complications in lateral window sinus augmentation. *Implant Dent.* 2011;20(6):406-412. doi:10.1097/ID.0b013e3182341f79.
5. Elian N, Wallace S, Cho SC, Jalbout ZN, Froum S. Distribution of the maxillary artery as it relates to sinus floor augmentation. *Int J Oral Maxillofac Implants.* 2005;20(5):784-787.
6. Stern A, Green J. Sinus lift procedures: an overview of current techniques. *Dent Clin North Am.* 2012;56(1):219-233. doi:10.1016/j.cden.2011.09.003.
7. Velasco-Torres M, Padiál-Molina M, Avila-Ortiz G, O'Valle F, Catena A, Galindo-Moreno P. Maxillary sinus dimensions decrease as age and tooth loss increase. *Eval.*
8. Kang SJ, Shin SI, Herr Y, Kwon YH, Kim GT, Chung JH. Anatomical structures in the maxillary sinus related to lateral sinus elevation: a cone beam computed tomographic analysis. *Clin Oral Implants Res.* 2013;24 Suppl A100:75-81. doi:10.1111/j.1600-0501.2011.02378.x.
9. Rysz M, Cizek B, Rogowska M, Krajewski R. Arteries of the anterior wall of the

maxilla in sinus lift surgery. *Int J Oral Maxillofac Surg.* 2014;43(9):1127-1130. doi:10.1016/j.ijom.2014.02.018.

10. Rahpeyma A, Khajehahmadi S. Open sinus lift surgery and the importance of preoperative cone-beam computed tomography scan: A review. *J Int Oral Health.* 2015;7(9):127-133.

11. Katranji A, Fotek P, Wang HL. Sinus augmentation complications: etiology and treatment. *Implant Dent.* 2008;17(3):339-349. doi:10.1097/ID.0b013e3181815660.

12. Apostolakis D, Bissoon AK. Radiographic evaluation of the superior alveolar canal: measurements of its diameter and of its position in relation to the maxillary sinus floor: a cone beam computerized tomography study. *Clin Oral Implants Res.* 2014;25(5):553-559. doi:10.1111/clr.12119.

13. Rosano G, Taschieri S, Gaudy JF, Weinstein T, Del Fabbro M. Maxillary sinus vascular anatomy and its relation to sinus lift surgery. *Clin Oral Implants Res.* 2011;22(7):711-715. doi:10.1111/j.1600-0501.2010.02045.x.

14. Morant JJ, Salvado M, Hernandez-Giron I, Casanovas R, Ortega R, Calzado A. Dosimetry of a cone beam CT device for oral and maxillofacial radiology using Monte Carlo techniques and ICRP adult reference computational phantoms. *Dentomaxillofac Radiol.* 2013;42(3):92555893. doi:10.1259/dmfr/92555893.

15. Naitoh M, Katsumata A, Nohara E, Ohsaki C, Ariji E. Measurement accuracy of reconstructed 2-D images obtained by multi-slice helical computed tomography. *Clin Oral Implants Res.* 2004;15(5):570-574. doi:10.1111/j.1600-0501.2004.01034.x.

16. Mardinger O, Abba M, Hirshberg A, Schwartz-Arad D. Prevalence, diameter and course of the maxillary intraosseous vascular canal with relation to sinus augmentation procedure: a radiographic study. *Int J Oral Maxillofac Surg.* 2007;36(8):735-738.

doi:10.1016/j.ijom.2007.05.005.

17. Lee CY. Brisk, prolonged pulsatile hemorrhage during the sinus graft procedure: a case report with discussion on intra-operative hemostatic management. *Implant Dent.* 2010;19(3):189-195. doi:10.1097/ID.0b013e3181dec0c7.
18. Ella B, Sedarat C, Noble Rda C, et al. Vascular connections of the lateral wall of the sinus: surgical effect in sinus augmentation. *Int J Oral Maxillofac Implants.* 2008;23(6):1047-1052.
19. Hayek E, Nasseh I, Hadchiti W, et al. Location of posterosuperior alveolar artery and correlation with maxillary sinus anatomy. *Int J Periodontics Restor Dent.* 2015;35(4):e60-e65. doi:10.11607/prd.2418.
20. Ilguy D, Ilguy M, Dolekoglu S, Fisekcioglu E. Evaluation of the posterior superior alveolar artery and the maxillary sinus with CBCT. *Braz Oral Res.* 2013;27(5):431-437. doi:10.1590/s1806-83242013000500007.
21. Anamali S, Avila-Ortiz G, Elangovan S, et al. Prevalence of the posterior superior alveolar canal in cone beam computed tomography scans. *Clin Oral Implants Res.* 2015;26(1):e8-e12. doi:10.1111/clr.12318.
22. Guncu GN, Yildirim YD, Wang HL, Tozum TF. Location of posterior superior alveolar artery and evaluation of maxillary sinus anatomy with computerized tomography: a clinical study. *Clin Oral Implants Res.* 2011;22(10):1164-1167. doi:10.1111/j.1600-0501.2010.02071.x.
23. Flanagan D. Arterial supply of maxillary sinus and potential for bleeding complication during lateral approach sinus elevation. *Implant Dent.* 2005;14(4):336-338.
24. Hamdy RM, Abdel-Wahed N. Three-dimensional linear and volumetric analysis of maxillary sinus pneumatization. *J Adv Res.* 2014;5(3):387-395.

doi:10.1016/j.jare.2013.06.006.

25. Sharan A, Madjar D. Maxillary sinus pneumatization following extractions: a radiographic study. *Int J Oral Maxillofac Implants*. 2008;23(1):48-56.

26. Tolstunov L, Thai D, Arellano L. Implant-guided volumetric analysis of edentulous maxillary bone with cone-beam computerized tomography scan. Maxillary sinus pneumatization classification. *J Oral Implantol*. 2012;38(4):377-390. doi:10.1563/aid-joi-d-11-00212.

27. Avila G, Wang HL, Galindo-Moreno P, et al. The influence of the bucco-palatal distance on sinus augmentation outcomes. *J Periodontol*. 2010;81(7):1041-1050. doi:10.1902/jop.2010.090686.

TABLES

Table 1. Summary of population variables.

Total number of patients		394	
Age		47.16 (10-87)	
Gender			
Male		193 (48.98%)	
Female		201 (51.02%)	
Dental status		Right	Left
	Dentate	145 (36.80%)	159 (40.36%)
	Partially edentulous	125 (31.75%)	118 (28.95%)
	Completely edentulous	124 (31.47%)	117 (29.70%)
Artery		Right	Left
	Total	327 (82.99%)	340 (86.29%)
	> 1 mm in diameter	71 (18.02%)	101 (25.64%)

Table 2. Artery diameter by gender and edentulous status. Values are expressed as mean and standard deviation (in brackets).

Artery diameter		Right	Left
	TOTAL SAMPLE	1.24(0.18)	
		1.24(0.19)	1.24(0.18)
Gender	Male	1.23(0.16)	
		1.25(0.19)	1.26(0.22)
	Female	1.23(0.14)	
		1.24(0.18)	1.23(0.13)
Edentulous status	Dentate	1.21(0.18)	
		1.24(0.25)	1.19(0.13)
	Partially Edentulous	1.25(0.18)	
		1.25(0.19)	1.26(0.18)
	Completely edentulous	1.24(0.19)	
		1.23(0.15)	1.25(0.21)

Table 3. Distance between the artery and the sinus floor by gender and edentulous status.

Values are expressed as mean and standard deviation (in brackets).

Distance to sinus floor	TOTAL SAMPLE	Right	Left
		7.00(3.63)	6.73(3.31)
Gender	Male	7.43(3.20)	
		7.57(3.74)	7.41(3.41)
	Female	6.21(2.93)	
		6.43(3.43)	6.05(3.08)
Edentulous status	Dentate	7.57(3.62)	
		8.02(3.87)	7.14(3.35)
	Partially Edentulous	6.78(3.56)	
		6.94(3.67)	6.63(3.45)
	Completely edentulous	6.19(2.92)	
		5.94(2.91)	6.43(2.93)

Table 4. Distance between the artery and the alveolar crest by gender and edentulous status.

Values are expressed as mean and standard deviation (in brackets).

Distance to alveolar crest		Right	Left
	TOTAL SAMPLE	13.40(3.72)	
		13.57(3.90)	13.23(3.54)
Gender	Male	13.48(3.36)	
		13.65(3.89)	13.54(3.67)
	Female	13.08(3.25)	
		13.49(3.93)	12.91(3.37)
Edentulous status	Dentate	13.87(3.41)	
		14.09(3.58)	13.66(3.25)
	Partially Edentulous	13.71(3.74)	
		13.96(3.81)	13.47(3.66)
	Completely edentulous	12.10(3.78)	
		12.09(4.15)	12.11(3.40)

FIGURE LEGENDS

Figure 1. Most caudal location of the blood vessel in the lateral wall of the maxillary sinus and measurements of the diameter and the distances to the floor of the sinus and to the alveolar crest.

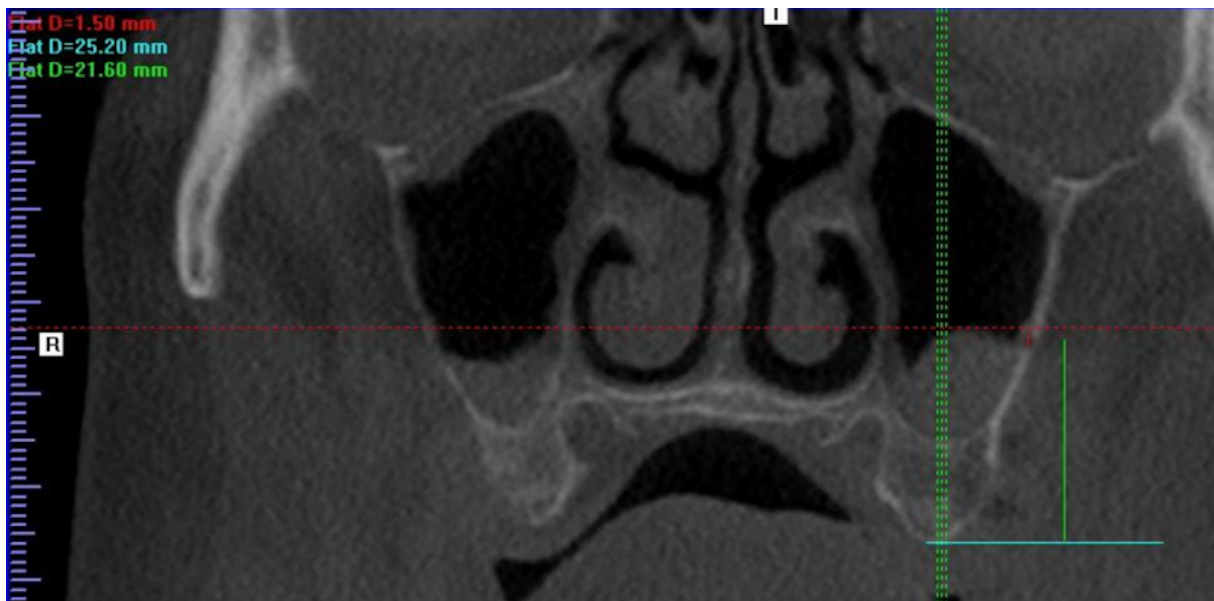


Figure 2. Artery diameter (in mm) by age interval (10% percentiles).

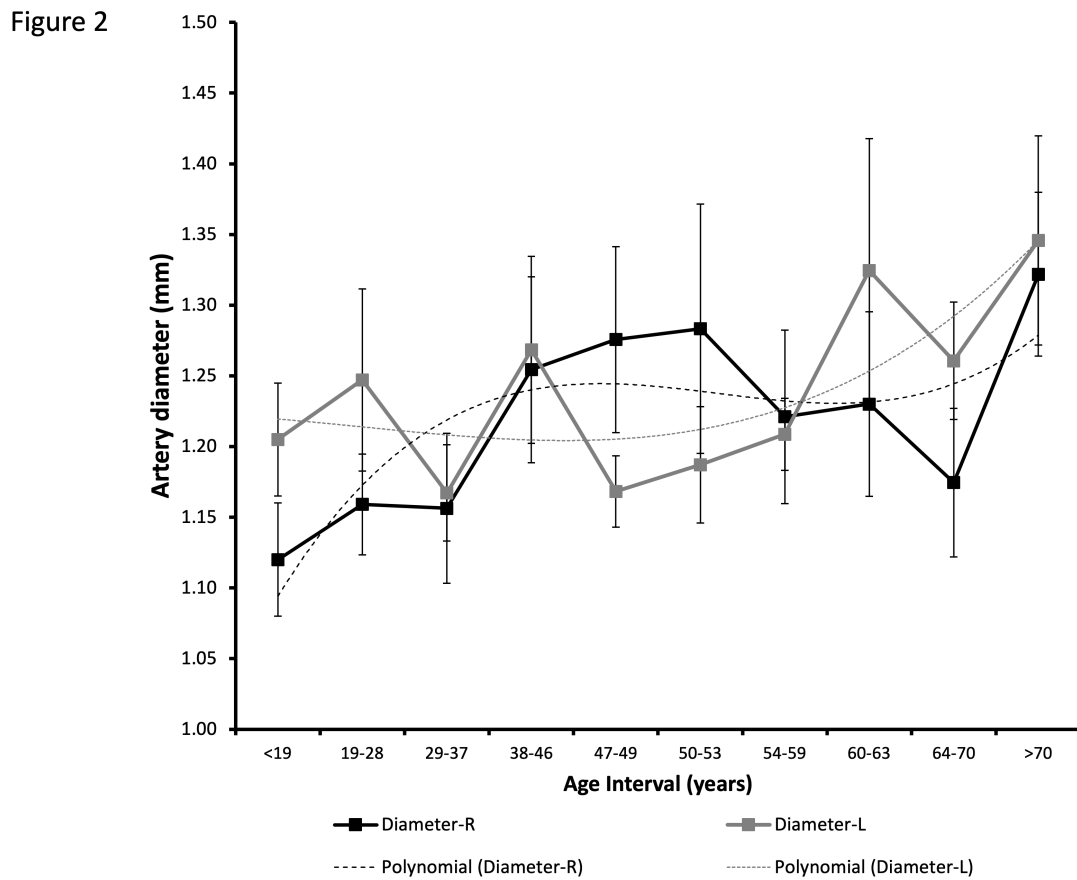


Figure 3. Distance from the artery to the sinus floor (in mm) by age interval (10% percentiles).

Figure 3

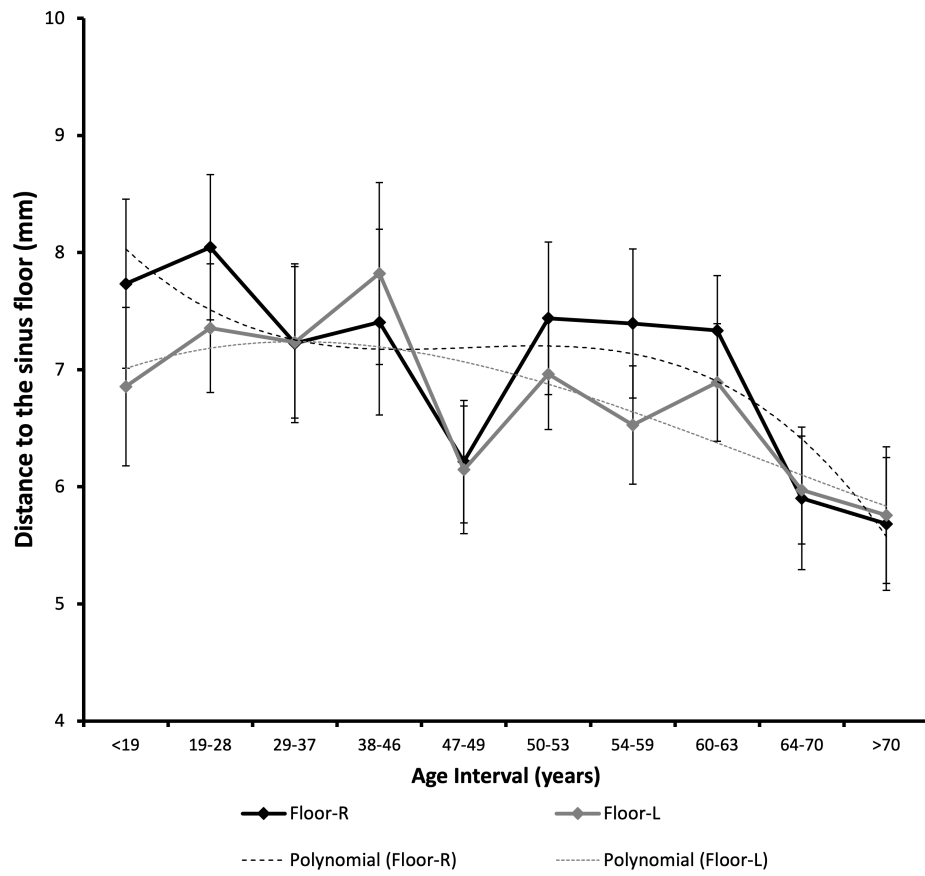


Figure 4. Distance from the artery to the sinus floor (in mm) by dental status.

Figure 4

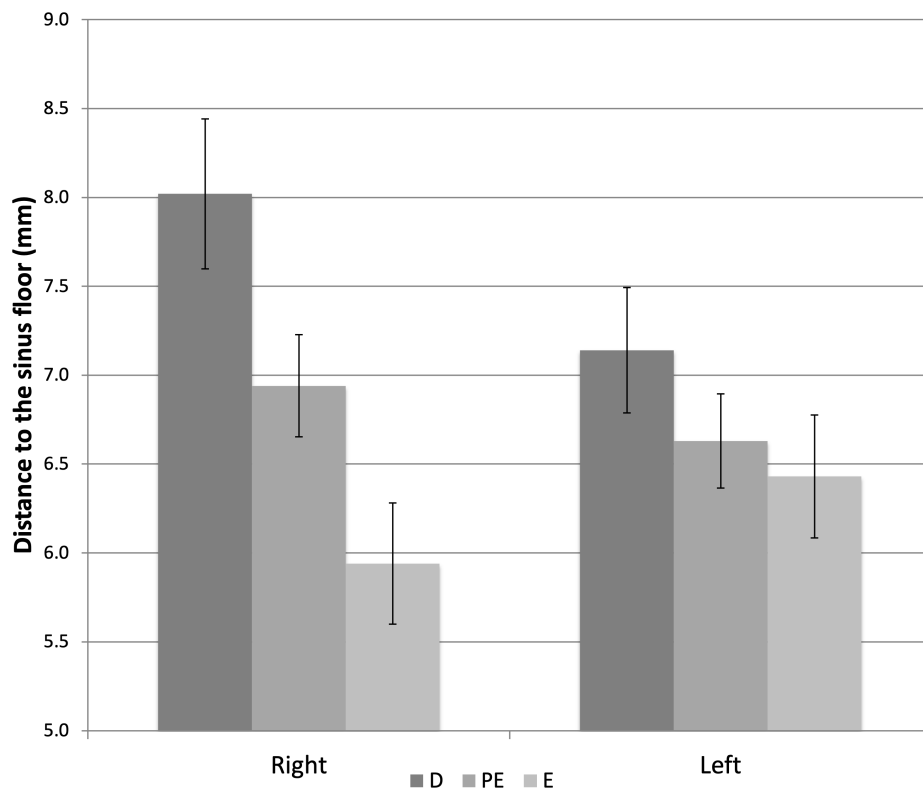


Figure 5. Distance from the artery to the alveolar crest (in mm) by dental status. ANOVA: significant on the right; Bonferroni post-hoc, no differences.

Figure 5

