

## CASE REPORT

# Vogt-Koyanagi-Harada disease in pregnancy: Case report and review of 32 patients in the literature

Toshihiko Matsuo<sup>1,2,3</sup>  | Kasumi Takahashi<sup>4</sup> | Tsunemasa Kondo<sup>4</sup>

<sup>1</sup>Graduate School of Interdisciplinary Science and Engineering in Health Systems, Okayama University, Okayama, Japan

<sup>2</sup>Department of Ophthalmology, Okayama University Hospital, Okayama, Japan

<sup>3</sup>Eye Clinic, Ochiai Hospital, Maniwa, Japan

<sup>4</sup>Division of Obstetrics and Gynecology, Ochiai Hospital, Maniwa, Japan

## Correspondence

Toshihiko Matsuo, Regenerative and Reconstructive Medicine (Ophthalmology), Graduate School of Interdisciplinary Science and Engineering in Health Systems, Okayama University, Shikata-cho 2-5-1, Okayama 700-8558, Japan.  
Email: [matsuot@cc.okayama-u.ac.jp](mailto:matsuot@cc.okayama-u.ac.jp)

## Key Clinical Message

Systemic prednisolone including steroid pulse therapy would be safe in 32 pregnant women, who developed Vogt-Koyanagi-Harada disease in the literature. Prednisolone administration would be shortened by monitoring of serous retinal detachment with optical coherence tomography.

## Abstract

A 30-year-old woman in 31 weeks of pregnancy with metamorphopsia and headache was diagnosed Vogt-Koyanagi-Harada disease. She underwent steroid pulse therapy and oral prednisolone 20 mg daily for 3 weeks until complete resolution of serous retinal detachment monitored by optical coherence tomography. Oral prednisolone was tapered and discontinued until uneventful delivery.

## KEYWORDS

delivery, optical coherence tomography, pregnancy, steroid pulse therapy, Vogt-Koyanagi-Harada disease

## 1 | INTRODUCTION

Vogt-Koyanagi-Harada disease is a distinct clinical entity of non-infectious uveitis, which shows granulomatous inflammation in the intraocular tissues of both eyes.<sup>1,2</sup> A hallmark of the clinical manifestations on the early stage are multifocal serous retinal detachment with intraretinal edema and choroidal bumpy thickening in the posterior pole of the eye involving the macula. Optic nerve papillitis or optic disc edema in both eyes may accompany the serous retinal detachment or may be a predominant sign of the disease. Iris nodules and mutton-fat keratic precipitates with aqueous cells as the presentation of granulomatous iritis or iridocyclitis would develop later in the time course of the active phase, sequel to the ocular fundus manifestation. In addition to ocular symptoms such as blurred

vision, acute vision decrease, and metamorphopsia, patients with the disease will present headache, nausea, and vomiting as the manifestation of meningitis, hearing loss and tinnitus as the manifestation of inner ear inflammation on the early phase of the active disease. Later in the chronic phase, patients will develop red-colored ocular fundus (sun-set glow fundus or depigmented fundus), vitiligo (spotty skin depigmentation), and depigmentation of the eyelashes and head hair as well as head hair loss (alopecia). All these manifestations can be explained by the immunological attack to melanocytes in the eye, meningeal tissue, inner ear, skin, and hair. Autoimmunity to melanocytes which underlies the disease will be further supported by Vogt-Koyanagi-Harada disease-like manifestations caused by the administration of anti-PD-1 antibodies as the treatment for malignant melanoma.<sup>3</sup>

This is an open access article under the terms of the [Creative Commons Attribution-NonCommercial](https://creativecommons.org/licenses/by-nc/4.0/) License, which permits use, distribution and reproduction in any medium, provided the original work is properly cited and is not used for commercial purposes.

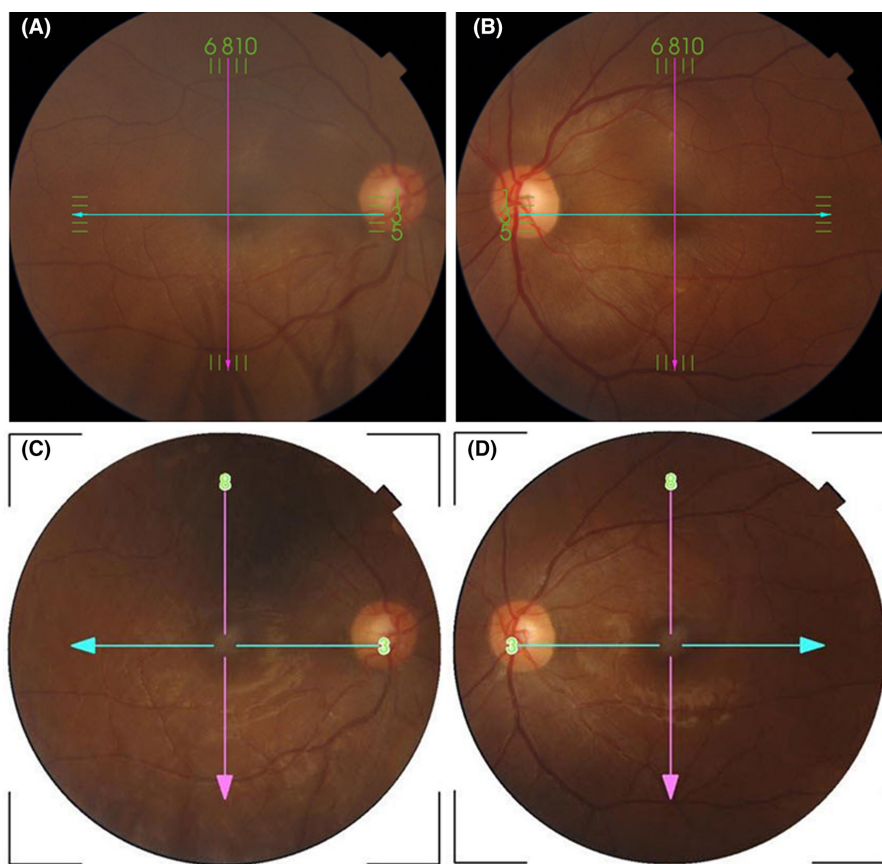
© 2024 The Authors. *Clinical Case Reports* published by John Wiley & Sons Ltd.

Vogt-Koyanagi-Harada disease is one of the three prevalent entities of uveitis in addition to sarcoidosis<sup>4,5</sup> and Behcet disease<sup>6–8</sup> in the Japanese population. The diagnosis is based on characteristic clinical manifestations, as described above, and the exclusion of other entities of uveitis: not only infectious uveitis caused by syphilis and tuberculosis but also non-infectious uveitis in association with tubulointerstitial nephritis<sup>9</sup> and inflammatory bowel disease<sup>10</sup> and so on. The standard of care for Vogt-Koyanagi-Harada disease is steroid pulse therapy with methylprednisolone 1000 mg daily for 3 days, followed by tapering of oral prednisolone in half a year.<sup>11</sup> Vogt-Koyanagi-Harada disease may occur in pregnancy and pose a problem how to apply the standard of care in a pregnant woman.<sup>12–14</sup> In this report, we described a patient who developed Vogt-Koyanagi-Harada disease in pregnancy and also summarized 32 patients with the disease in pregnancy in the literature to elucidate the outcome of treatment.<sup>15–44</sup>

## 2 | CASE REPORT

A 30-year-old woman in 31 weeks of pregnancy noticed metamorphopsia which was described as dented road surface and distorted lines in the left eye a week before, and also in the right eye a day before. She also had mild headache, but did not have tinnitus or hearing problems. She had no medication and no past history except for one uneventful delivery of a healthy baby. She did not undergo vaccination for COVID-19. At the initial visit, the best-corrected visual acuity in decimals was 1.0 in the right eye and 1.0 in the left eye. The intraocular pressure was 9 mmHg in both eyes. She did not have keratic precipitates or aqueous cells as the manifestation of iritis. She showed multifocal serous retinal detachment in the posterior pole of the ocular fundus of both eyes (Figures 1A,B and 2A,B). The optic disc in both eyes appeared normal.

In the diagnosis of Vogt-Koyanagi-Harada disease, obstetrician-gynecologists who followed the patient were



**FIGURE 1** Ocular fundus photographs in the right eye (A) and left eye (B) at the initial visit, showing multifocal serous retinal detachment in the posterior pole of the eye. The optic disc in each eye appears normal. Ocular fundus photographs in the right eye (C) and left eye (D), showing no serous detachment with macular ring reflex 5 weeks later when oral prednisolone at 15 mg daily is tapered to 10 mg daily. Photographs in A and C have shadow-like artifacts by eyelashes in the lower part. A vertical line and horizontal line in each photograph indicate the cutting sections by optical coherence tomography, as shown in Figure 2.

**FIGURE 2** Retinal cross-sectional images of optical coherence tomography at the initial visit (A, B), a week later (C, D), 3 week later (E, F), and 4 weeks later (G, H) from the initial visit. Images in the right eye are in the left column (A, C, E, and G) and images in the left eye are in the right column (B, D, F, and H). Each panel with alphabetical labelling shows color photograph (top left), red-free photograph (bottom left), horizontal section of the image from the nasal to the temporal side (top right), and vertical section of the image from the superior to the inferior side (bottom right). Note sequential decrease of subretinal fluid (arrows in A–F) in 3 weeks after steroid pulse therapy and oral prednisolone 20 mg daily, and no subretinal fluid in both eyes (G, H), 4 weeks later from the initial visit.

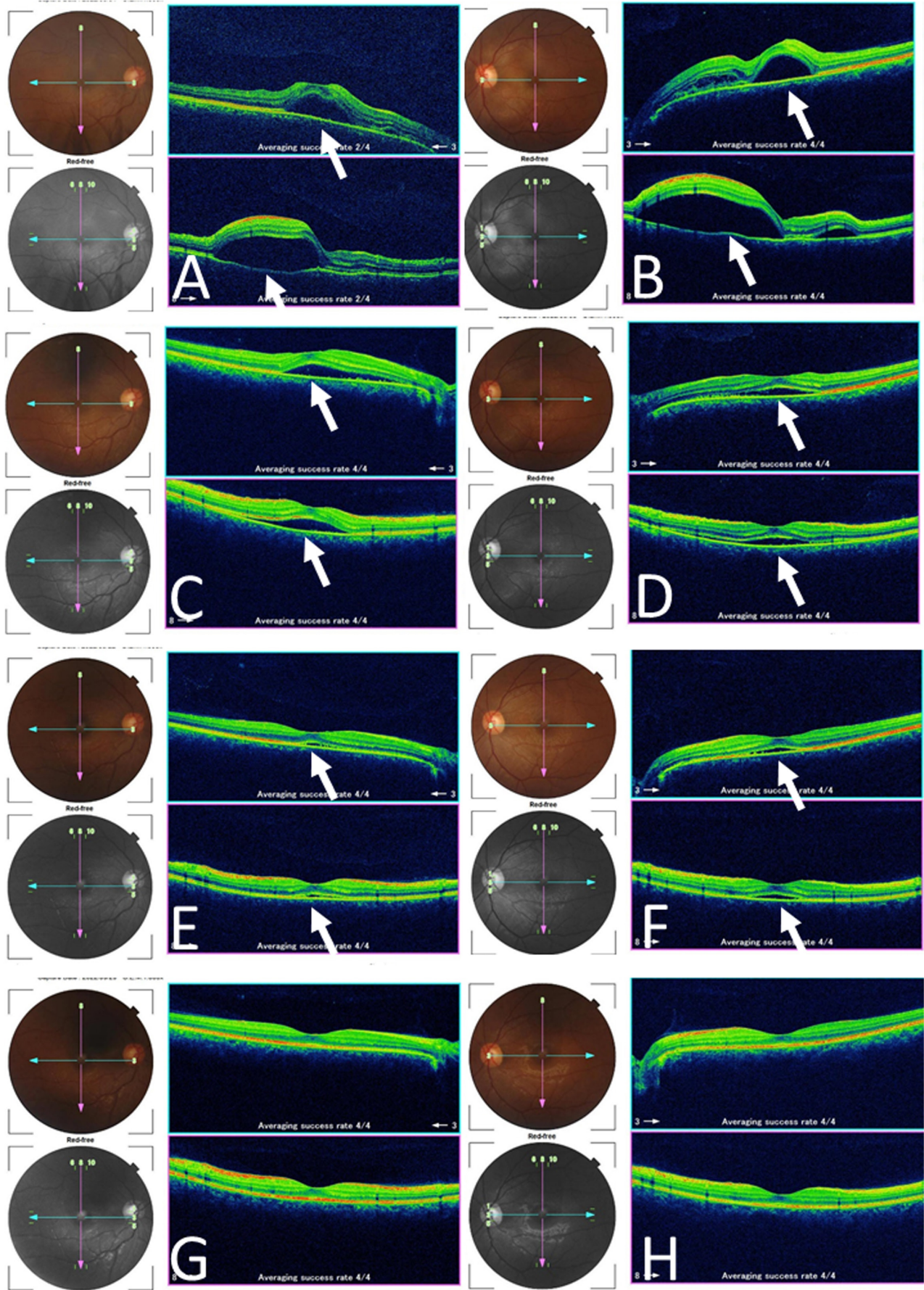


TABLE 1 Review of 33 patients with Vogt-Koyanagi-Harada disease in pregnancy, including the present patient.

Case no./age / laterality <sup>a</sup>	Pregnancy	Eye symptoms	Other symptoms	Other signs	Past history
1/20/Bilateral	28 weeks	Poor vision in both eyes	Headache	Lymphocytosis in lumbar puncture	One uneventful pregnancy
2/23/Bilateral	17 weeks	Blurred vision in both eyes	None	Lymphocytosis in lumbar puncture	One uneventful pregnancy
3/26/Bilateral	10 weeks	Blurred vision Metamorphopsia Photophobia in both eyes	Headache Nausea	Lymphocytosis in lumbar puncture	None
4/22/Bilateral	4 weeks?	Sudden vision decrease in both eyes	Headache Hearing loss Hair loss	Lymphocytosis in lumbar puncture	None
5/20/Bilateral	4 weeks?	Sudden vision decrease in both eyes	Headache Hearing loss Hair loss	None	Three pregnancies
6/29/Bilateral	29 weeks	Vision decrease Metamorphopsia in both eyes	Hair loss Tinnitus Hearing loss Headache	None	None
7/27/Bilateral	26 weeks	Sudden vision decrease in both eyes	None	Lymphocytosis in lumbar puncture	None
8/24/Bilateral	12 weeks	Blurred vision in both eyes	Headache Hearing loss	None	None
9/26/Bilateral	19 weeks	Vision decrease in both eyes	None	Lymphocytosis in lumbar puncture	None
10/33/Bilateral	28 weeks	Vision decrease in both eyes	Tinnitus Hearing loss	Lymphocytosis in lumbar puncture	None
11/30/Bilateral	10 weeks	Vision decrease in both eyes	Headache Tinnitus	None	None
12/26/Bilateral	16 weeks	Blurred vision in both eyes	Headache	Lymphocytosis in lumbar puncture	None
13/24/Bilateral	17 weeks	Blurred vision in both eyes	Headache Hearing loss	Lymphocytosis in lumbar puncture	None
14/40/Bilateral	13 weeks	Vision decrease in both eyes	None	None	Two uneventful deliveries and 3 induced abortions

Eye manifestations	Systemic treatment	Outcome	First author (year)
Iridocyclitis Optic disc edema Serous macular detachment	Topical steroid Systemic steroids tapered	Uneventful delivery Steroids discontinued No relapse in 4 years	Friedman (1980) <sup>15</sup>
Iridocyclitis Optic disc edema Serous macular detachment	Topical steroid Systemic steroids tapered	Uneventful delivery Steroids discontinued No relapse in 27 weeks	Friedman (1980) <sup>15</sup>
Optic disc edema Serous macular detachment	Topical and subconjunctival steroids only	Subsidence 4 weeks later No relapse at 8 months of pregnancy Uneventful delivery	Satoh (1986) <sup>16</sup>
Iridocyclitis with SIP Serous macular detachment	Topical steroid Systemic prednisolone tapered from 100 mg daily	Uneventful delivery Relapse in 1 month after delivery Systemic prednisolone tapered from 100 mg daily	Steahly (1990) <sup>17</sup>
Iridocyclitis Serous macular detachment	Systemic prednisolone tapered from 100 mg daily	Spontaneous abortion at 3 months of pregnancy Relapse in a month	Steahly (1990) <sup>17</sup>
Iridocyclitis Optic disc edema Serous macular detachment	Drip infusion prednisolone 150 mg daily tapered to 5 mg daily at delivery	Uneventful delivery Prednisolone increased to 20 mg daily and tapered No relapse	Yamagami (1991) <sup>18</sup>
Iridocyclitis Serous macular detachment	Prednisolone tapered from 80 mg daily	Uneventful delivery at 38 weeks of pregnancy Prednisolone 10 mg daily tapered and discontinued in 2 months No relapse	Watase (1995) <sup>19</sup>
Iridocyclitis Serous macular detachment	None	Spontaneous subsidence in a month Uneventful delivery No relapse	Nohara (1995) <sup>20</sup>
Optic disc edema Serous macular detachment	Prednisolone 200 mg daily tapered and discontinued 7 weeks later	Uneventful delivery No relapse	Miyata (1997) <sup>21</sup> (2001) <sup>24</sup>
Iridocyclitis Serous macular detachment	Prednisolone 200 mg daily tapered to 5 mg every other day	Uneventful delivery at 39 weeks of pregnancy Prednisolone 5 mg every other day discontinued in a month No relapse	Miyata (1997) <sup>21</sup> (2001) <sup>24</sup>
Iridocyclitis Optic disc edema Serous macular detachment	Topical 0.1% betamethasone only	Subsidence Uneventful delivery by caesarean section No relapse in 7 months	Taguchi (1999) <sup>22</sup>
Iridocyclitis Optic disc edema Serous macular detachment	Prednisolone 120 mg daily tapered and discontinued in 8 months	Delivery of a low-birth-weight infant (2160 g) at 37 weeks of pregnancy No relapse	Doi (2000) <sup>23</sup>
Iridocyclitis Serous macular detachment	Topical steroids only	Subsidence in 2 weeks Uneventful delivery No relapse	Miyata (2001) <sup>24</sup>
Iridocyclitis Optic disc edema Serous macular detachment	Topical and subconjunctival steroids only	Subsidence at 27 weeks of pregnancy, no relapse Delivery of a small-for-date infant (1724 g) by caesarean section at 36 weeks of pregnancy	Kawano (2005) <sup>25</sup>

(Continues)

TABLE 1 (Continued)

Case no./age / laterality <sup>a</sup>	Pregnancy	Eye symptoms	Other symptoms	Other signs	Past history
15/26/Bilateral	41 weeks	Sudden vision decrease in the right eye	None	None	None
16/31/Bilateral	12 weeks	Metamorphopsia in both eyes	None	Lymphocytosis in lumbar puncture	None
17/28/Bilateral	30 weeks	Vision decrease in both eyes	Headache Tinnitus	None	None
18/33/Bilateral	38 weeks	Vision decrease in both eyes	Headache	None	One uneventful delivery
19/33/Bilateral	38 weeks	Vision decrease in both eyes	Headache	None	Left ovarian tumor One uneventful delivery
20/32/Bilateral	28 weeks	Blurred vision in both eyes	None	None	Two pregnancies
21/27/Bilateral	19 weeks	Vision decrease in both eyes	None	None	None
22/31/Bilateral	14 weeks	Blurred vision and metamorphopsia in the right eye	Headache	None	None
23/36/Bilateral	29 weeks	Vision decrease in the right eye	Headache Tinnitus	None	One uneventful delivery
24/34/Bilateral	13 weeks	Vision decrease in both eyes	Headache	Lymphocytosis in lumbar puncture	One uneventful delivery One spontaneous abortion with 13 trisomy
25/29/Bilateral	34 weeks	Acute vision loss and metamorphopsia in both eyes	Headache	None	Oral prednisolone 5 mg daily for rheumatoid arthritis in 8 years
26/31/Bilateral	24 weeks	Sudden blurred vision in both eyes	None	None	None
27/37/Bilateral	20 weeks	Metamorphopsia in both eyes	Headache Nausea Dizziness	None	None
28/33/Bilateral	16 weeks	Metamorphopsia in both eyes	Headache Tinnitus	None	None
29/27/Bilateral	13 weeks	Vision decrease and metamorphopsia in both eyes	Headache Hearing loss	None	One uneventful delivery

Eye manifestations	Systemic treatment	Outcome	First author (year)
Serous macular detachment	After delivery, Steroid pulse therapy Oral prednisolone tapered from 60 mg daily	Uneventful delivery by caesarean section Subsidence and no relapse	Aoki (2006) <sup>26</sup>
Serous macular detachment	Topical steroids and sub-Tenon triamcinolone 20 mg injection once in both eyes	Subsidence Uneventful delivery No relapse	Matsumoto (2006) <sup>27</sup>
Iridocyclitis Serous macular detachment	Prednisolone tapered from 200 mg daily	Stillbirth at 35 weeks of pregnancy Prednisolone 55 mg daily discontinued in 6 months No relapse	Ohta (2007) <sup>28</sup>
Iridocyclitis Serous macular detachment	After delivery, Steroid pulse therapy, Topical steroid	Uneventful delivery by caesarean section at 38 weeks of pregnancy Subsidence in 5 weeks	Hashimoto (2008) <sup>29</sup>
Iridocyclitis Optic disc edema Serous macular detachment	After delivery, Steroid mini-pulse therapy Oral prednisolone 50 mg daily tapered and discontinued in a month	Uneventful delivery by caesarean section at 38 weeks of pregnancy Subsidence in a month	Ohkawara (2009) <sup>30</sup> Matsubara (2011) <sup>31</sup>
Iridocyclitis Optic disc edema Serous macular detachment	Steroid pulse therapy	Subsidence Uneventful delivery at full term No relapse	Tien (2009) <sup>32</sup>
Iridocyclitis Serous macular detachment	Topical steroids and sub-Tenon triamcinolone 20 mg injection twice in both eyes	Uneventful delivery No relapse	Masaki (2011) <sup>33</sup>
Serous macular detachment	Steroid pulse therapy Oral prednisolone 25 mg daily tapered and discontinued 3.3 months later	Subsidence in 2 weeks Uneventful delivery by caesarean section at 38 weeks of pregnancy No relapse in 1 year	Tominaga (2012) <sup>34</sup>
Iridocyclitis Optic disc edema Serous macular detachment	No treatment	Spontaneous subsidence Uneventful delivery at 37 weeks of pregnancy No relapse in 5 years	Kasahara (2014) <sup>35</sup>
Iridocyclitis Serous macular detachment	Steroid pulse therapy Oral prednisolone 40 mg daily tapered and discontinued in 6 months before delivery	Subsidence in 2 weeks Uneventful delivery at 38 weeks of pregnancy No relapse in 6 months	Kobayashi (2015) <sup>36</sup>
Iridocyclitis Serous macular detachment	Topical 0.1% betamethasone only	Subsidence in 3 weeks Uneventful delivery at 37 weeks of pregnancy No relapse in 6 months	Sugita (2015) <sup>37</sup>
Serous macular detachment	None	Spontaneous subsidence in 2 weeks Uneventful delivery 3 months later	Babu (2016) <sup>38</sup>
Serous macular detachment	Prednisolone 200 mg daily tapered and discontinued in 6 months	Uneventful delivery No relapse	Saitoh (2017) <sup>39</sup>
Iridocyclitis Serous macular detachment	Topical 0.1% betamethasone and sub-Tenon triamcinolone injection 20 mg once in both eyes	Subsidence in 2 weeks Uneventful delivery at 41 weeks of pregnancy No relapse in 13 months	Nakamura (2018) <sup>40</sup>
Iridocyclitis Optic disc edema Serous macular detachment	Steroid pulse therapy, Oral prednisolone tapered from 50 mg daily Then, azathioprine 100–200 mg daily	Uneventful delivery of a baby with 1900 g by caesarean section at 31 weeks of pregnancy No relapse with prednisolone 7.5 mg daily and azathioprine 150 mg daily	Ingolotti (2019) <sup>41</sup>

(Continues)

TABLE 1 (Continued)

Case no./age / laterality <sup>a</sup>	Pregnancy	Eye symptoms	Other symptoms	Other signs	Past history
30/27/Bilateral	37 weeks	Blurred vision in both eyes	Headache Tinnitus	None	One uneventful delivery
31/30/Bilateral	33 weeks	Blurred vision in both eyes	Headache	None	None
32/31/Bilateral	18 weeks	Vision loss in both eyes	Headache Tinnitus Nausea	None	None
33/30/Bilateral	31 weeks	Metamorphopsia in both eyes	Headache	None	One uneventful delivery

Note: Iridocyclitis indicates keratic precipitates, aqueous cells, vitreous cells, or their combinations. SIP, synechia iris posterior. Steroid pulse therapy, intravenous drip infusion of methylprednisolone 1000 mg daily for 3 days. Steroid mini-pulse therapy, intravenous drip infusion of methylprednisolone 500 mg daily for 3 days.

<sup>a</sup>Age at the onset of Vogt-Koyanagi-Harada disease and the laterality of the involved eye.

consulted for steroid pulse therapy as the standard treatment. The patient did not have hypertension or diabetes mellitus and was stable in the third trimester. She, thus, underwent one course of steroid pulse therapy with intravenous drip infusion of methylprednisolone 1000 mg daily for 3 days in outpatient clinic. She took oral prednisolone 30 mg daily next day but experienced back and neck pain. On the following day, she was well with a reduce dose of oral prednisolone at 20 mg daily, and she continued this dose for 3 weeks until she showed no subretinal fluid in both eyes by optical coherence tomography (Figure 2C–H). The dose of oral prednisolone was reduced to 15 mg daily in a week, 10 mg daily in a week (Figure 1C,D), and 10 mg every other day in a week, and discontinued before the delivery. She had uneventful delivery of a healthy female baby with the birthweight of 2992 g at 39 weeks of pregnancy. She did not show relapse of uveitis in 16 months after the delivery.

### 3 | METHODS

To analyze similar cases, we reviewed the Japanese literature with key words, “Vogt-Koyanagi-Harada disease” and “pregnancy” in the bibliographic database of medical literature in Japanese (Igaku Chuo Zasshi, Ichushi-Web), published by the Japan Medical Abstracts Society

(JAMAS, Tokyo, Japan). Old literature was collected from references cited in the articles identified during the literature search. PubMed and Google Scholar were also searched for the same key words. A sufficient description was found in 32 patients with Vogt-Koyanagi-Harada disease in pregnancy (Table 1).<sup>15–44</sup>

### 4 | RESULTS

Vogt-Koyanagi-Harada disease was reported to occur in 33 women (Table 1), including the present patient, of which 25 women were Japanese, at the age of the onset ranging from 20 to 40 years old (median, 29 years old). Of these 33 women, six were in the first trimester (1–12 weeks) of pregnancy, 17 in the second trimester (13–28 weeks), and 10 in the third trimester (29–40 weeks). The initial symptoms of the vision were vision decrease or loss in 20 patients, blurred vision in 10, and metamorphopsia in eight, and photophobia in one: these symptoms overlapped in some patients. The other non-ophthalmic symptoms were headache in 21 patients, nausea in three, tinnitus in eight, hearing loss in seven, hair loss in three, and dizziness in one: these symptoms overlapped in some patients. In contrast, nine patients showed no other symptoms except for



Eye manifestations	Systemic treatment	Outcome	First author (year)
Serous macular detachment	Two courses of steroid pulse therapy Oral prednisolone tapered from 40 mg daily	Subsidence in 2 weeks Uneventful delivery at 40 weeks of pregnancy Prednisolone discontinued in 7 months No relapse in 12 months	Okamoto (2020) <sup>42</sup>
Serous macular detachment	After delivery, Steroid pulse therapy Oral prednisolone 40 mg daily tapered and discontinued in 7 months	Uneventful delivery of dizygotic twin by caesarean section at 34 weeks of pregnancy	Kokehara (2021) <sup>43</sup>
Iridocyclitis Optic disc edema Serous macular detachment	Oral prednisolone 60 mg daily for 2 weeks Steroid mini-pulse therapy Oral prednisolone 60 mg daily Cyclosporine 200 mg daily and prednisolone 5 mg daily	Uneventful delivery by caesarean section at 35 weeks of pregnancy After delivery, Steroid pulse therapy, oral prednisolone 60 mg daily and cyclosporine 200 mg daily Recovery and no relapse with cyclosporine 200 mg daily in 6 months	Sanchez-Vicente (2022) <sup>44</sup>
Serous macular detachment	Steroid pulse therapy Oral prednisolone 20 mg daily tapered and discontinued in 1.5 months before delivery	Uneventful delivery at 39 weeks of pregnancy No relapse in 16 months	This case

the vision symptoms. All 33 patients presented serous retinal detachment involving the macula in both eyes. Additionally, iridocyclitis was described in 23 patients and optic disc edema was in 12 patients: these two signs overlapped in some patients. Lumbar puncture was done in 11 patients and all of them showed lymphocytosis in the cerebrospinal fluid. In the past history, 12 women had the previous delivery or pregnancy while the remaining 21 women were in the first pregnancy.

As for the treatment, steroid pulse therapy as a main treatment was done in eight patients during the pregnancy and in three after the delivery. Systemic prednisolone in the intravenous or oral route or their sequential combination was given in 11 patients in the pregnancy. Topical steroid only was given in three patients while topical steroid and subconjunctival steroid injection were given in two patients. Topical steroid and sub-Tenon injection of triamcinolone in both eyes were given once or twice in three patients. The observation with neither topical nor systemic treatment was done in the remaining three patients. In addition to systemic prednisolone, one patient (Case 29) took oral azathioprine and another patient (Case 32) took oral cyclosporine both in the period before and after the delivery. Uneventful delivery was described in 31 patients of which nine patients underwent caesarean section. No relapse of uveitis was described in 27 patients after the

delivery. Only two patients were described to have relapse after the delivery (Case 4) and spontaneous abortion (Case 5), respectively, and one had systemic prednisolone again (Case 4).

One patient (Case 5) with Vogt-Koyanagi-Harada disease in the early phase of the first trimester had spontaneous abortion at 3 months of pregnancy after systemic prednisolone tapered from 100 mg daily.<sup>17</sup> Another patient (Case 17) with the onset of the disease at 30 weeks of pregnancy experienced stillbirth at 35 weeks of pregnancy at the dose of oral prednisolone 55 mg daily, 18 days after intravenous drip infusion of prednisolone 200 mg daily and its subsequent tapering. In the latter case (Case 17), no abnormalities were noted in the condition of the patient at the delivery, and the stillborn baby as well as the placenta appeared normal macroscopically, leading to the conclusion that no causal relationship would exist between systemic prednisolone and the stillbirth.<sup>28</sup>

## 5 | DISCUSSION

Optical coherence tomography is an imaging system to visualize retinal slices and used as the standard of clinical examinations to make the diagnosis of retinal diseases, especially macular diseases such as intraretinal and

subretinal fluid accumulation. The diagnosis and the staging of glaucoma can be also made by automatic analyzing system of optical coherence tomography to measure the nerve fiber layer thickness around the optic disc. From the practical point of view, images of optical coherence tomography can be obtained in the normal status of pupils without pharmacological mydriasis. In this patient, Vogt-Koyanagi-Harada disease was diagnosed with the aid of optical coherence tomography by the presentation of multifocal subretinal fluid accumulation and intraretinal fluid accumulation which were described clinically as multifocal serous retinal detachment and macular edema, respectively. In addition, optical coherence tomography was utilized to monitor these manifestations in response to steroid pulse therapy and oral prednisolone tapering.

In this patient, steroid pulse therapy was chosen on the basis of the following points in consultation with her obstetrician-gynecologist: (1) steroid pulse therapy is the standard of care for Vogt-Koyanagi-Harada disease, (2) the patient complained of vision problem caused by multifocal serous retinal detachment even though she maintained better visual acuity of 1.0 in decimals in both eyes, and (3) she was in the third trimester and had no complication of pregnancy such as pregnancy-induced hypertension and diabetes mellitus. In a dialogue with the patient, the dose of oral prednisolone after steroid pulse therapy was scheduled to be tapered at a fast pace and to be discontinued in a month or so until the delivery to expect no prednisolone in breast feeding. The initial dose of prednisolone 20 mg daily was chosen from the viewpoint of patient's acceptable state and was continued in about 3 weeks until no subretinal fluid was noted in both eyes by imaging with optical coherence tomography. The dose was, then, rapidly tapered and discontinued in half a month. It should be noted that the patient did not show the relapse of uveitis in 16 months after the delivery.

The administration of corticosteroids including steroid pulse therapy is considered as a basically safe procedure in pregnancy, especially in the second and third trimester.<sup>45,46</sup> The safety of corticosteroid administration in pregnancy is indicated from the standpoint of both maternal and fetal sides: the mother continues pregnancy with no apparent risks and the baby would have no increased risk for congenital anomalies. The review of 33 pregnant women with Vogt-Koyanagi-Harada disease in this study also supports the fundamental safety of systemic corticosteroid administration in pregnancy. The general line on systemic corticosteroid use in pregnancy would be to avoid the use, if possible, in the first trimester, and also to avoid the use in pregnant women who have systemic risks such as pregnancy-induced hypertension or diabetes mellitus.

In the present series of 33 pregnant women with Vogt-Koyanagi-Harada disease, spontaneous subsidence of serous retinal detachment in both eyes was noted by simple observation in a small number of patients. Furthermore, topical corticosteroid only, topical steroid and subconjunctival steroid injection, or topical steroid and sub-Tenon triamcinolone injection once or twice in both eyes did lead to the subsidence of uveitis in a small number of patients. Based on these facts, it would be a clinical option to watch the course without treatment, especially in patients who develop Vogt-Koyanagi-Harada disease in the first trimester of pregnancy. Sub-Tenon triamcinolone injection in both eyes would be a treatment option in pregnant women who have systemic risks such as pregnancy-induced hypertension or diabetes mellitus.

Vaccine-associated uveitis might be also considered in general for differential diagnosis of uveitis.<sup>47</sup> The present patient had pregnancy and delivery in the recent pandemics of COVID-19 from the year 2020. She did not suffer from COVID-19 and did not undergo vaccines for COVID-19, based on her choice. Vaccination for COVID-19 has been known as a precipitating factor for the development of uveitis,<sup>47</sup> retinal and vitreous hemorrhages,<sup>48</sup> and optic neuritis.<sup>49,50</sup> Vogt-Koyanagi-Harada disease is a most prevalent entity of uveitis among various entities of uveitis which develop or relapse after vaccination for COVID-19 in the Japanese population.<sup>51</sup> In the present patient, there was no prodromal symptoms such as viral infection including COVID-19 infection and vaccinations.

## 6 | CONCLUSIONS

Vogt-Koyanagi-Harada disease occurring in the third trimester of pregnancy in an otherwise healthy woman was treated with one course of steroid pulse therapy and the subsequent oral prednisolone 20 mg daily which was tapered and discontinued at a fast pace in 1.5 months before the uneventful delivery of a healthy baby. Monitoring of serous retinal detachment in both eyes by optical coherence tomography once every week was useful to visualize the subsidence, in order to make decision to maintain the dose of 20 mg daily until the complete resolution and then to taper the dose of oral prednisolone rapidly. The review of 32 pregnant women with Vogt-Koyanagi-Harada disease in the literature suggests the fundamental safety of prednisolone administration including steroid pulse therapy. In addition, most patients did not show relapse after the delivery. Based on the authors' impression, it is desirable to limit the duration of prednisolone administration as short as possible by monitoring the subsidence of serous retinal detachment with optical coherence tomography.

## AUTHOR CONTRIBUTIONS

**Toshihiko Matsuo:** Conceptualization; data curation; formal analysis; investigation; methodology; visualization; writing – original draft. **Kasumi Takahashi:** Data curation; investigation; writing – review and editing. **Tsunemasa Kondo:** Data curation; investigation; methodology; writing – review and editing.

## ACKNOWLEDGMENTS

None.

## FUNDING INFORMATION

The authors receive no financial support for the research, authorship, and/or publication of this article.

## CONFLICT OF INTEREST STATEMENT

The authors declare no potential conflicts of interest with respect to the research, authorship, and/or publication of this article.

## DATA AVAILABILITY STATEMENT

Additional data are available upon reasonable request to the corresponding author.

## ETHICS STATEMENT

Ethics committee review was not applicable due to the case report design, based on the Ethical Guidelines for Medical and Health Research Involving Human Subjects, issued by the Government of Japan.

## CONSENT

Written consent was obtained from the patient for her anonymized information to be published in this article.

## ORCID

Toshihiko Matsuo  <https://orcid.org/0000-0001-6570-0030>

## REFERENCES

1. Moorthy RS, Inomata H, Rao NA. Vogt-Koyanagi-Harada syndrome. *Surv Ophthalmol*. 1995;39:265-292.
2. Herbort CP Jr, Tugal-Tutkun I, Abu-El-Asrar A, et al. Precise, simplified diagnostic criteria and optimized management of initial-onset Vogt-Koyanagi-Harada disease: an updated review. *Eye (Lond)*. 2022;36:29-43.
3. Matsuo T, Yamasaki O. Vogt-Koyanagi-Harada disease-like posterior uveitis in the course of nivolumab (anti-PD-1 antibody), interposed by vemurafenib (BRAF inhibitor), for metastatic cutaneous malignant melanoma. *Clin Case Rep*. 2017;5:694-700.
4. Matsuo T, Itami M, Shiraga F. Choroidopathy in patients with sarcoidosis observed by simultaneous indocyanine green and fluorescein angiography. *Retina*. 2000;20:16-21.
5. Matsuo T, Fujiwara N, Nakata Y. First presenting signs or symptoms of sarcoidosis in a Japanese population. *Jpn J Ophthalmol*. 2005;49:149-152.
6. Matsuo T, Itami M, Nakagawa H, Nagayama M. The incidence and pathology of conjunctival ulceration in Behçet's syndrome. *Br J Ophthalmol*. 2002;86:140-143.
7. Matsuo T, Itami M. Recurrent versus non-recurrent or no eye involvement in Behcet's disease. *Ocul Immunol Inflamm*. 2005;13:73-77.
8. Matsuo T, Sato Y, Shiraga F, Shiragami C, Tsuchida Y. Choroidal abnormalities in Behcet disease observed by simultaneous indocyanine green and fluorescein angiography with scanning laser ophthalmoscopy. *Ophthalmology*. 1999;106:295-300.
9. Matsuo T. Fluorescein angiographic features of tubulointerstitial nephritis and uveitis syndrome. *Ophthalmology*. 2002;109:132-136.
10. Matsuo T, Yamaoka A. Retinal vasculitis revealed by fluorescein angiography in patients with inflammatory bowel disease. *Jpn J Ophthalmol*. 1998;42:398-400.
11. Accorinti M, Saturno MC, Iannetti L, Manni P, Mastromarino D, Pirraglia MP. Treatment and prognosis of Vogt-Koyanagi-Harada disease: real-life experience in long-term follow-up. *J Clin Med*. 2022;11:3632.
12. Snyder DA, Tessler HH. Vogt-Koyanagi-Harada syndrome. *Am J Ophthalmol*. 1980;90:69-75.
13. Rabiah PK, Vitale AT. Noninfectious uveitis and pregnancy. *Am J Ophthalmol*. 2003;136:91-98.
14. Alromaih AZ, Almater AI, Albloushi AF, Alkheraiji NF, El-Asrar AMA. Outcomes of initial-onset acute uveitis associated with Vogt-Koyanagi-Harada disease occurred during pregnancy. *Int Ophthalmol*. 2022;43(1):185-195.
15. Friedman Z, Granat M, Neumann E. The syndrome of Vogt-Koyanagi-Harada and pregnancy. *Metab Pediatr Ophthalmol*. 1980;4:147-149.
16. Satoh S, Koh M, Tamura H. Harada's disease in pregnancy: a case report [in Japanese]. *Nippon Ganka Kyo*. 1986;37:46-50.
17. Steahly LP. Vogt-Koyanagi-Harada syndrome and pregnancy. *Ann Ophthalmol*. 1990;22:59-62.
18. Yamagami S, Mochizuki M, Ando K. Systemic corticosteroid therapy for pregnant patients with Vogt-Koyanagi-Harada syndrome [in Japanese]. *Ganka Rinsho Iho*. 1991;85:52-55.
19. Watase M, Kawamura K, Nagano T, Yata K. A case of Harada disease during pregnancy treated with systemic corticosteroid drugs [in Japanese]. *Nippon Ganka Kyo*. 1995;46:1192-1195.
20. Nohara M, Norose K, Segawa K. Vogt-Koyanagi-Harada disease during pregnancy. *Br J Ophthalmol*. 1995;79:94-95.
21. Miyata N, Sugita M, Nakamura S, et al. Vogt-Koyanagi-Harada disease in two pregnant females [in Japanese]. *Rinsho Ganka*. 1997;51:755-759.
22. Taguchi C, Ikeda E, Hikita N, Mochizuki M. A report of two cases suggesting positive influence of pregnancy on uveitis activity [in Japanese]. *Nippon Ganka Gakkai Zasshi*. 1999;103:66-71.
23. Doi M, Matsubara H, Uji Y. Vogt-Koyanagi-Harada syndrome in a pregnant patient treated with high-dose systemic corticosteroids. *Acta Ophthalmol Scand*. 2000;78:93-96.
24. Miyata N, Sugita M, Nakamura S, et al. Treatment of Vogt-Koyanagi-Harada's disease during pregnancy. *Jpn J Ophthalmol*. 2001;45:177-180.

25. Kawano S, Fukada Y, Ito H, Hoshi K. A case of intrauterine growth restriction complicated by Vogt-Koyanagi-Harada disease at 11 weeks gestation [in Japanese]. *Nippon Sanka Fujinka Gakkai Kanto Rengo Chiho Bukai Kaiho*. 2005;42:421-425.
26. Aoki Y, Sone K, Nakazawa T, et al. A case of pregnancy induced hypertension complicated by detached retinas originated from the Harada disease [in Japanese]. *Nippon Sanka Fujinka Gakkai Tokyo Chiho Bukai Kaiho*. 2006;55:426-429.
27. Matsumoto M, Nakanishi H, Kita M. A case of Harada disease during pregnancy treated with sub-Tenon injection of triamcinolone acetonide [in Japanese]. *Nippon Ganka Kiyo*. 2006;57:614-617.
28. Ohta K, Gotoh N, Yonezawa H, Oka K, Ashida T. Fetal death following high-dose systemic steroid therapy in a pregnant patient with Vogt-Koyanagi-Harada disease [in Japanese]. *Nippon Ganka Gakkai Zasshi*. 2007;111:959-964.
29. Hashimoto Y, Kuwata T, Taneichi A, et al. Visual impairment during late pregnancy caused by Vogt-Koyanagi-Harada disease [in Japanese]. *Tochigiken Sanfujinka Iho*. 2008;35:18-19.
30. Ohkawara Y, Makino S. A case of Vogt-Koyanagi-Harada disease treated with systemic steroid administration after delivery in a patient at the 37th week of pregnancy [in Japanese]. *Ganka Rinsho Kiyo*. 2009;2:616-619.
31. Matsubara S, Kuwata T, Ohkawara Y, Makino S. Headache in late pregnancy: a symptom for Vogt-Koyanagi-Harada disease. *Arch Gynecol Obstet*. 2011;283:1423-1425.
32. Tien MCH, Teoh SCB. Treatment of Vogt-Koyanagi-Harada syndrome in pregnancy. *Can J Ophthalmol*. 2009;44:211-212.
33. Masaki N, Hayashi R, Liu M, Miyahara S. A case of Vogt-Koyanagi-Harada disease during pregnancy treated with sub-Tenon injection of triamcinolone acetonide [in Japanese]. *Atarashii Ganka*. 2011;28:711-714.
34. Tominaga A, Ochi R, Harino S, Takahashi T. Pulsed corticosteroid therapy for Vogt-Koyanagi-Harada disease in a case at fourteen weeks' gestation [in Japanese]. *Rinsho Ganka*. 2012;66:1229-1234.
35. Kasahara S, Ichibe Y, Shimizu K. A case of Vogt-Koyanagi-Harada disease that developed later in pregnancy and improved without treatment [in Japanese]. *Atarashii Ganka*. 2014;31:1407-1412.
36. Kobayashi T, Maruyama K, Shoda H, et al. A case of Vogt-Koyanagi-Harada disease during first trimester, treated with steroid pulse therapy [in Japanese]. *Atarashii Ganka*. 2015;32:1618-1621.
37. Sugita K, Mizumoto K, Kato N, Zako M. Early resolution of subretinal fluid without high-dose corticosteroids in a pregnant patient with Vogt-Koyanagi-Harada disease: a case report. *J Ophthalmic Inflamm Infect*. 2015;5:20.
38. Babu K, Parikh A. Reply to "Early resolution of subretinal fluid without high-dose corticosteroids in a pregnant patient with Vogt-Koyanagi-Harada disease" by Sugita et al. *J Ophthalmic Inflamm Infect*. 2016;6:13.
39. Saitoh A. High-dose systemic steroid therapy in case at twenty weeks gestation [in Japanese]. *Ganka Rinsho Kiyo*. 2017;10:200-202.
40. Nakamura T, Keino H, Okada AA. Sub-Tenon triamcinolone acetonide injection in a pregnant patient with Vogt-Koyanagi-Harada disease. *Retinal Cases Brief Rep*. 2018;12:375-378.
41. Ingolotti M, Schlaen BA, Melo-Granados EAR, Garcia HR, Partida JAA. Azathioprine during the first trimester of pregnancy in a patient with Vogt-Koyanagi-Harada disease: a multimodal imaging follow-up study. *Am J Case Rep*. 2019;20:300-305.
42. Okamoto N, Setoguchi Y, Kiryu J. A case of Vogt-Koyanagi-Harada disease in a pregnant woman at 37 weeks of gestation treated with steroid pulse therapy with a good course [in Japanese]. *Atarashii Ganka*. 2020;37:1022-1026.
43. Kokehara T, Fusa M, Miki R, et al. A case of Vogt-Koyanagi-Harada disease complicated with pregnancy-induced hypertensive nephropathy [in Japanese]. *Kakogawa Shimin Byoin Kiko Gakujuetsushi*. 2021;10:10-13.
44. Sanchez-Vicente JL, Moruno-Rodriguez A, De Las Morenas-Iglesias J, et al. Clinical manifestations and treatment of Vogt-Koyanagi-Harada disease during pregnancy and after birth: a case report. *Ocul Immunol Inflamm*. 2022;31:830-837.
45. Levy RA, de Jesus GR, de Jesus NR, Klumb EM. Critical review of the current recommendations for the treatment of systemic inflammatory rheumatic diseases during pregnancy and lactation. *Autoimmun Rev*. 2016;15:955-963.
46. Bandoli G, Palmsten K, Smith CJF, Chambers CD. A review of systemic corticosteroid use in pregnancy and the risk of select pregnancy and birth outcomes. *Rheum Dis Clin N Am*. 2017;43:489-502.
47. Matsuo T, Honda H, Tanaka T, Uruguchi K, Kawahara M, Hagiya H. COVID-19 mRNA vaccine-associated uveitis leading to diagnosis of sarcoidosis: case report and review of literature. *J Investig Med High Impact Case Rep*. 2022;10:23247096221086450.
48. Matsuo T, Noda H. Temporal association of vitreous hemorrhage and hypertension after COVID-19 mRNA vaccines. *Clin Case Rep*. 2022;10:e06657.
49. Matsuo T, Okubo K, Mifune H, Imao T. Bilateral optic neuritis and hypophysitis with diabetes insipidus one month after COVID-19 mRNA vaccine: case report and literature review. *J Investig Med High Impact Case Rep*. 2023;11:23247096231186046.
50. Matsuo T, Iguchi D. Rare combination of abducens nerve palsy and optic neuritis on the same side: case report and review of 8 patients in literature. *J Investig Med High Impact Case Rep*. 2024;12:23247096231225873.
51. Yasaka Y, Hasegawa E, Keino H, et al. A multicenter study of ocular inflammation after COVID-19 vaccination. *Jpn J Ophthalmol*. 2023;67:14-21.

**How to cite this article:** Matsuo T, Takahashi K, Kondo T. Vogt-Koyanagi-Harada disease in pregnancy: Case report and review of 32 patients in the literature. *Clin Case Rep*. 2024;12:e8643. doi:[10.1002/ccr3.8643](https://doi.org/10.1002/ccr3.8643)