

## Long-Term Follow-up Data of a Multi-Institutional Phase-2 Study of S-1/oxaliplatin and Bevacizumab Therapy in Patients with Advanced Colorectal Cancer: The HiSCO-02 Study

Manabu Shimomura<sup>a\*</sup>, Katsunori Shinozaki<sup>b</sup>, Takuya Yano<sup>a</sup>, Shintaro Akabane<sup>a</sup>, and Hideki Ohdan<sup>a</sup>;  
Hiroshima Surgical study group of Clinical Oncology (HiSCO)

<sup>a</sup>Department of Gastroenterological and Transplant Surgery, Graduate School of Biomedical and Health Sciences, Hiroshima University, Hiroshima 734-8553, Japan,

<sup>b</sup>Division of Clinical Oncology, Hiroshima Prefectural Hospital, Hiroshima 734-8530, Japan

Oral fluoropyrimidines (FUs) have certain advantages over intravenous FUs, such as longer intervals between outpatient visits, no requirement for central venous port (CVP) implantation, and lower incidence of neutropenia. We previously reported the efficacy of S-1/oxaliplatin (SOX) with bevacizumab therapy as a first-line treatment for advanced colorectal cancer (CRC) in a prospective phase-II multi-institutional clinical trial (HiSCO-02 study). However, our prognostic data at the time lacked a sufficient observation period. Herein, we analyze the longer-term follow-up data, focusing on the status of eventual CVP implantation via an open-label, non-randomized, multicenter study. This study enrolled 55 patients (mean age, 64 years), of whom 43 died (41 of primary cancer). The median overall survival was 22.7 months (95% CI: 20.1-34.7 months). Post-treatment regimens after failure of first-line treatment were initiated in 43 patients; CPT11-based regimens were selected in most cases, and other oral FU combinations in nine. CVP was implanted in 35 patients prior to first-line treatment; eleven of the remaining 20 patients did not require CVP implantation. In conclusion, we report here the final prognostic update of the Phase II clinical trial examining the efficacy of SOX plus bevacizumab therapy, the results of which confirm the clinical efficacy of this regimen.

**Key words:** metastatic colorectal cancer, chemotherapy, S-1, prospective phase II study

The development of novel therapeutic agents, including molecular targeted therapy and immunotherapy, for advanced colorectal cancer (CRC) has progressed in recent years, with the new agents reportedly prolonging survival times [1,2]. Combination chemotherapies, such as FOLFOX (5-fluorouracil, leucovorin, and oxaliplatin) and FOLFIRI (5-fluorouracil, leucovorin, and irinotecan), are still the most commonly used first-line treatments for metastatic CRC. However, these regimens require repeated infusions via

a central venous port (CVP) [3].

Oral fluoropyrimidines (FU) can be used in place of leucovorin and fluorouracil infusions [4]. Oral FU has certain advantages over intravenous FU, such as longer outpatient visits, no need for a CVP, and lower incidence of neutropenia [5]. A treatment regimen has been developed to replace intravenous FU with oral FU as the standard therapy for advanced CRC. We previously reported the efficacy of S-1 (an oral fluorouracil) combined with intravenous oxaliplatin and bevacizumab (SOX plus bevacizumab) as first-line therapy for

advanced CRC in a prospective phase II clinical trial (HiSCO-02 study) [6]. However, the prognostic data of the HiSCO-02 study were immature because of the lack of a sufficient observation period.

Although several clinical trials have reported the efficacy and favorable long-term survival of oral FU combination therapy [7], post-treatment details in a real-world clinical setting are scarce. In addition, clinical data on the eventual placement or not of a CVP (e.g., due to peripheral venous discomfort or for second-line treatments) are lacking. Thus, we aimed to determine the long-term prognosis of SOX with bevacizumab therapy in the HiSCO-02 study, with a focus on the eventual status of CVP implantation.

### Patients and Methods

We conducted an open-label, non-randomized, multicenter clinical phase II trial at 12 institutions in Hiroshima, Japan. We enrolled individuals aged 20-80 years who had metastatic CRC, an Eastern Cooperative Oncology Group performance status (PS) of 0 or 1, assessable lesions, and no prior history of chemotherapy. Eligible patients were administered SOX plus bevacizumab (oral S-1 80 mg/m<sup>2</sup>/day on days 1-14; intravenous oxaliplatin [130 mg/m<sup>2</sup>] and bevacizumab [7.5 mg/kg] on day 1 and then q3w). The primary endpoint was response rate (RR), and the secondary endpoints were progression-free survival (PFS), overall survival (OS), and safety. Details of the eligible cases, treatment protocols, and RR were previously reported [6]. Furthermore, the previous study showed data confirming its hypothesis and validating the efficacy of SOX plus bevacizumab therapy for advanced CRC [6]. Here, we present the latest long-term prognostic data, prognostic factors, and details of treatment regimens after patients become resistant to SOX plus bevacizumab therapy. In addition, we performed long-term observation of one of the initial advantages of this regimen: the lack of CVP implantation.

This study was conducted in accordance with the principles of the Declaration of Helsinki. All patients provided written informed consent after being informed of the purpose and investigational nature of the study. The institutional review boards and ethics committees of each participating center reviewed and approved the protocol. This study was registered in the UMIN Clinical Trial Registry (No: UMIN000004976).

**Statistical analysis.** All analyses were performed using an intention-to-treat dataset. Kaplan-Meier survival curves were plotted, and univariate analyses of the factors thought to influence OS were performed using a log-rank test. A Cox proportional hazards model was used for multivariate analyses. Statistical significance was set at  $p < 0.05$ . All statistical analyses were performed using JMP (version 16; SAS Institute Inc., Cary, NC, USA).

### Results

**Patient characteristics.** Between May 2011 and January 2014, 55 patients with CRC were enrolled from 12 institutions. The patient characteristics are listed in Table 1. The mean patient age was 64 years. Forty-nine patients had a PS of 0 (i.e., normal activity), and six had a PS of 1. There were 16 patients diagnosed with right-sided colon cancer and 39 patients with left-sided colon cancer. The median follow-up duration was 21.9 months (range 1.4-97.0 months), as compared to 22.5 months in the previous study.

**Long-term survival and prognostic factors.** Of the 55 patients enrolled, 43 died; of these 43 patients, 41 died of primary cancer. The median OS was 22.7

**Table 1** Baseline patient characteristics (n = 55)

Parameter	Number of patients
Sex	
Male	36
Female	19
Age, years (range)	64 (21-79)
Performance status	
0	49
1	6
Primary site	
Colon	33
Rectosigmoid	3
Rectum	19
Primary tumor resection (%)	37 (67.3%)
Metastatic sites	
Liver	32
Lung	23
Lymph node metastases	13
Peritoneal dissemination	4
other metastases	11
Number of metastatic sites	
1	29
2	17
≥3	9

months (95% confidence interval, 20.1-34.7 months) (Fig. 1).

Age and CEA cutoffs were classified as low or high based on the median values. In the univariate analysis, tumor histology, number of organs with metastatic lesions, and elevated pretreatment CEA level were identified as prognostic factors. In the multivariate analysis, only the number of organs with metastatic lesions was as an independent prognostic factor (Table 2). The median survival time for patients with right-sided colon cancer was 20.1 months, while that for patients with left-sided colon cancer was 24.7 months; however, this difference was not found to be statistically significant ( $p=0.99$ ).

**Post-treatment details after failure of SOX therapy.** SOX plus bevacizumab therapy failed as first-line treatment in 43 patients. Second-line regimens were initiated as follows: FOLFIRI plus anti-VEGF therapy in 17 patients, CPT-11-based regimen with oral FU and anti-VEGF in nine patients, FOLFIRI with anti-EGFR therapy in eight patients, oral FU monotherapy in three patients, radiotherapy in three patients, surgery in two patients, and FOLFOX with anti-VEGF in one patient. As late lines of treatment, trifluridine/tipiracil therapy was administered to 10 patients and regorafenib therapy

was administered to four patients. Metastases were resected in four patients during the treatment course.

**CVP placement.** Before the administration of SOX and bevacizumab therapy, a CVP had been

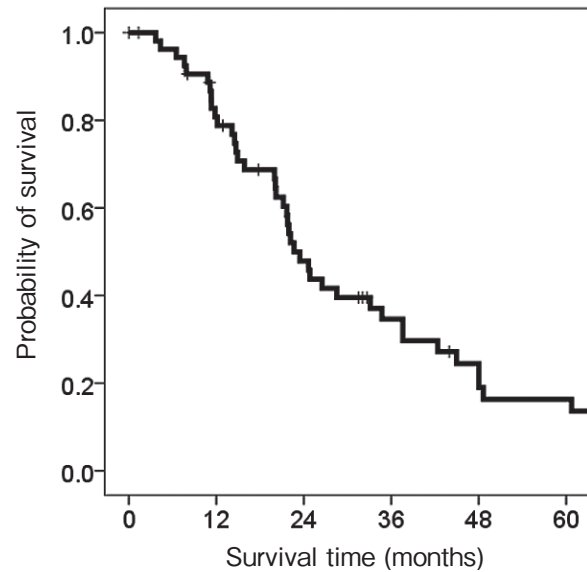


Fig. 1 The median OS was 22.7 months (95% Confidence interval: 20.1–34.7 months).

Table 2 Prognostic factor

		n	median OS	Univariate	Multivariate		
				P-value	P-value	Risk	95%CI
sex	male	36	24.9	0.48			
	female	18	20.0				
age	low	28	21.7	0.54			
	high	26	24.9				
PS	0	48	23.5	0.61			
	1	6	20.1				
Location	colon	32	22.2	0.68			
	rectum	22	23.5				
Histology	well or moderate differentiated type	48	24.7	0.02	0.06	2.84	0.96–8.47
	others	4	20.0				
History of surgery for CRC	no	19	24.7	0.99			
	yes	35	22.2				
History of adjuvant therapy	no	43	21.7	0.07			
	yes	12	44.0				
Number of metastatic organs	2 or less	28	42.4	0.0002	0.01	3.24	1.26–8.32
	3 or more	26	20.2				
CEA	low	27	34.7	0.007	0.48	1.35	0.58–3.14
	high	27	21.7				

PS, performance status; CEA, carcinoembryonic antigen; OS, overall survival; CI, confidence interval.

implanted in 35 patients to secure the route of intravenous administration of oxaliplatin and bevacizumab. The CVP was removed in three patients during the treatment course due to infections (two cases) and catheter injury (one case). Of the 20 patients who did not undergo CVP placement before the first-line treatment, nine underwent CVP placement later. Among these nine patients, CVP was implanted in three patients to secure a venous route during first-line treatment, and it was implanted in five other patients when selecting a second-line regimen that required a CVP, and the other one patient was not detailed. Eleven patients did not require a CVP at all (Fig. 2).

## Discussion

Herein, we report the final follow-up of the Phase II clinical trial that tested the efficacy of SOX with bevacizumab therapy. We also determined the status of CVP placement and post-treatment practice details.

Oral FU regimens have been reported as good treatment options for advanced CRC [5,8,9]. The SOFT trial, a large RCT conducted in Japan, demonstrated the non-inferiority of SOX with bevacizumab therapy to the standard of care (FOLFOX with bevacizumab therapy) [3]. The SOFT trial reported a median OS of 29.6 months (24.8-34.7 months), which is longer than that reported by us. We enrolled patients with peritoneal

dissemination in this study, who were excluded from the SOFT study; this inclusion may have influenced our long-term survival data. Previous reports have reported a median survival of approximately 24 months [9-11]. Thus, we believe that this study's median overall survival of 22.7 months corroborated previous studies and validated the efficacy of SOX with bevacizumab therapy for OS.

Several clinical trials have examined the OS of SOX plus bevacizumab; however, studies providing data on post-treatment details are limited. Unfortunately, the final OS follow-up of the SOFT trial did not provide such details [7]. In this study, we provide a detailed post-treatment data providing a real-world clinical perspective. Secondary treatment consists of irinotecan in most cases; however, several patients also receive oral FU as second-line therapy after SOX plus bevacizumab therapy.

The oral FU regimen has advantages such as requiring only one outpatient visit every three weeks and eliminating the need for CVP implantation [12]. However, information on how often CVPs are eventually implanted in those receiving oral FU regimens is lacking. This study shows that a CVP was required in 44 out of 55 patients (80%) who originally received an oral FU combination regimen as their primary treatment. However, considering that 11 patients (20%) did not require CVPs and three had catheter-related com-

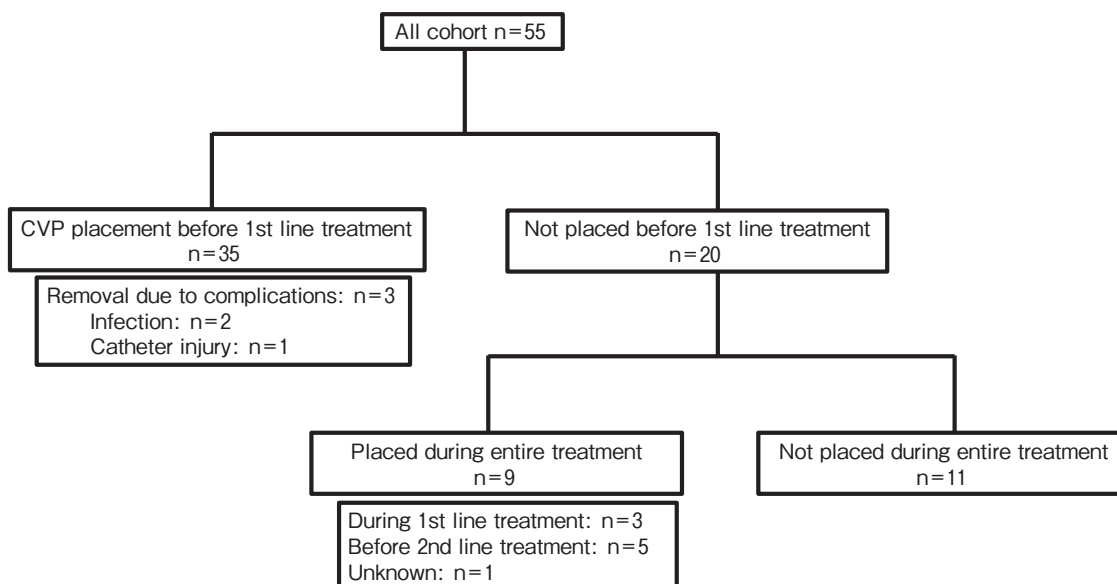


Fig. 2 Long-term observational information on CVP implantation is shown.

plications, treatment without indwelling CVP should be considered as an option for treatment of CRC.

This study supports other reports showing the anti-tumor efficacy of oral FU agents to be comparable to those of intravenous FU agents. Intravenous FU and oral FU regimens have different adverse event profiles, with more neutropenia with intravenous FU and more diarrhea with oral FU [5]. As noted earlier, oral FU drug regimens may eliminate the need for a CVP and have the advantage of fewer prolonged hospital visits, which is especially desired among patients who are not ready for major lifestyle changes. On the other hand, patients who are concerned about vascular pain or extravascular leakage of combinatory IV drugs may benefit from CVP implantation. While CVPs have an important role in cancer treatment in terms of ensuring a safe route of administration of therapeutic agents, the not-infrequent incidence of adverse events with long-term implantation should be noted. In a recent report of 253 cancer patients with implanted CVPs, 12% developed bloodstream infections and 14% required port removal due to complications [12]. As treatment options expand, there is an increasing need for physicians to choose a treatment method that matches each patient's pre-existing conditions and preferences. We believe that the information presented in this report on CVP implantation status and frequency of adverse events will be important information for patients and physicians when selecting treatment options.

One limitation of this study is that it reports a relatively small number of cases and lacks the genetic information that is now a routine part of treatment planning. Recently, the benefit of anti-EGFR antibody therapy over anti-VEGF antibody therapy for left-sided RAS wild-type CRC in OS was reported [13]. However, for right-sided or RAS-mutant CRC, which accounts for more than 50% of CRCs, anti-VEGF antibody therapy including SOX with bevacizumab therapy is still a standard option, making this study's results quite relevant despite expanded treatment paradigms. We believe that detailed post-treatment data and analysis of eventual CVP placement or not is useful in clinical decision-making.

In conclusion, we reported the final follow-up of the Phase II clinical trial begun in 2011, which tested the efficacy of SOX plus bevacizumab therapy. Not only was the clinical efficacy of this regimen confirmed, but data on the eventual necessity or not of CVP implantation

provides an important new clinical perspective on standard CRC treatment practices.

**Acknowledgments.** We thank all patients who participated in this trial and their families. The following departments and hospitals participated in the trial: Department of Gastroenterological and Transplant Surgery, Applied Life Sciences, Institute of Biomedical & Health Sciences, Hiroshima University, Division of Clinical Oncology, Hiroshima Prefectural Hospital, Department of Surgery, Hiroshima City Asa Hospital, Department of Surgery, National Hospital Organization Higashihiroshima Medical Center, Department of Surgery, Onomichi General Hospital, Department of Surgery, Chugoku Rosai Hospital, Department of Surgery, Hiroshima General Hospital of West Japan Railway Company, Department of Surgery, Yoshida General Hospital, Department of Surgery, National Hospital Organization Kure Medical Center, Department of Surgery, Chuden Hospital, Department of Surgery, Hiroshima-nishi Medical Center, Department of Surgery, and Kure City Medical Association Hospital.

## References

1. Grothey A, Sargent D, Goldberg RM and Schmoll HJ: Survival of patients with advanced colorectal cancer improves with the availability of fluorouracil-leucovorin, irinotecan, and oxaliplatin in the course of treatment. *J Clin Oncol* (2004) 22: 1209–1214.
2. Tournigand C, Andre T, Achille E, Lledo G, Flesh M, Mery-Mignard D, Quinaux E, Couteau C, Buyse M, Ganem G, Landi B, Colin P, Louvet C and de Gramont A: FOLFIRI followed by FOLFOX6 or the reverse sequence in advanced colorectal cancer: a randomized GERCOR study. *J Clin Oncol* (2004) 22: 229–237.
3. Yamada Y, Takahari D, Matsumoto H, Baba H, Nakamura M, Yoshida K, Yoshida M, Iwamoto S, Shimada K, Komatsu Y, Sasaki Y, Satoh T, Takahashi K, Mishima H, Muro K, Watanabe M, Sakata Y, Morita S, Shimada Y and Sugihara K: Leucovorin, fluorouracil, and oxaliplatin plus bevacizumab versus S-1 and oxaliplatin plus bevacizumab in patients with metastatic colorectal cancer (SOFT): an open-label, non-inferiority, randomized phase 3 trial. *Lancet Oncol* (2013) 14: 1278–1286.
4. Fuchs CS, Marshall J and Barrueco J: Randomized, controlled trial of irinotecan plus infusional, bolus, or oral fluoropyrimidines in first-line treatment of metastatic colorectal cancer: updated results from the BICC-C study. *J Clin Oncol* (2008) 26: 689–690.
5. Chionh F, Lau D, Yeung Y, Price T and Tebbutt N: Oral versus intravenous fluoropyrimidines for colorectal cancer, *Cochrane Database Syst Rev* (2017) 7: CD008398.
6. Shimomura M, Shinozaki K, Hinoi T, Yoshimitsu M, Kurayoshi M, Sumitani D, Ishizaki Y, Oshiro Y, Kodama S, Shimizu Y, Arita M, Tokunaga M, Yoshida M, Tanaka J and Ohdan H, Hiroshima Surgical study group of Clinical (HiSCO): A multi-institutional feasibility study of S-1/oxaliplatin plus bevacizumab in patients with advanced/metastatic colorectal cancer: the HiSCO-02 prospective phase II study. Springerplus (2016) e1800.
7. Baba H, Yamada Y, Takahari D, Matsumoto H, Yoshida K, Nakamura M, Yoshida M, Iwamoto S, Shimada K, Komatsu Y, Sasaki Y, Satoh T, Takahashi K, Mishima H, Muro K, Watanabe M, Sakata Y, Morita S, Shimada Y and Sugihara K: S-1 and oxaliplatin (SOX) plus bevacizumab versus mFOLFOX6 plus bevacizumab as first-line treatment for patients with metastatic colorectal cancer: updated overall survival analyses of the open-label,

- non-inferiority, randomised phase III: SOFT study. *ESMO Open* (2017) 2: e000135.
8. Cassidy J, Clarke S, Diaz-Rubio E, Scheithauer W, Figer A, Wong R, Koski S, Lichinitser M, Yang TS, Rivera F, Couture F, Sirzen F and Saltz L: Randomized phase III study of capecitabine plus oxaliplatin compared with fluorouracil/folinic acid plus oxaliplatin as first-line therapy for metastatic colorectal cancer. *J Clin Oncol* (2008) 26: 2006–2012.
  9. Saltz LB, Clarke S, Diaz-Rubio E, Scheithauer W, Figer A, Wong R, Koski S, Lichinitser M, Yang TS, Rivera F, Couture F, Sirzen F and Cassidy J: Bevacizumab in combination with oxaliplatin-based chemotherapy as first-line therapy in metastatic colorectal cancer: a randomized phase III study. *J Clin Oncol* (2008) 26: 2013–2019.
  10. Van Cutsem E, Kohne CH, Hitre E, Zaluski J, Chang Chien CR, Makhson A, D'Haens G, Pinter T, Lim R, Bodoky G, Roh JK, Folprecht G, Ruff P, Stroh C, Tejpar S, Schlichting M, Nippgen J and Rougier P: Cetuximab and chemotherapy as initial treatment for metastatic colorectal cancer. *N Engl J Med* (2009) 360: 1408–1417.
  11. Douillard JY, Siena S, Cassidy J, Tabernero J, Burkes R, Barugel M, Humblet Y, Bodoky G, Cunningham D, Jassem J, Rivera F, Kocakova I, Ruff P, Blasinska-Morawiec M, Smakal M, Canon JL, Rother M, Oliner KS, Wolf M and Gansert J: Randomized, phase III trial of panitumumab with infusional fluorouracil, leucovorin, and oxaliplatin (FOLFOX4) versus FOLFOX4 alone as first-line treatment in patients with previously untreated metastatic colorectal cancer: the PRIME study. *J Clin Oncol* (2010) 31: 4697–4705.
  12. Moss JG, Wu O, Bodenham AR, Agarwal R, Menne TF, Jones BL, Heggie R, Hill S, Dixon-Hughes J, Soulis E, Germini E, Dillon S and McCartney E: Central venous access devices for the delivery of systemic anticancer therapy (CAVA) a randomised controlled trial. *Lancet* (2021) 398: 403–415.
  13. Watanabe J, Muro K, Shitara K, Yamazaki K, Shiozawa M, Ohori H, Takashima A, Yokota M, Makiyama A, Akazawa N, Ojima H, Yuasa Y, Miwa K, Yasui H, Oki E, Sato T, Naitoh T, Komatsu Y, Kato T, Hihara M, Soeda J, Misumi T, Yamamoto K, Akagi K, Ochiai A, Uetake H, Tsuchihara K and Yoshino T: Panitumumab vs Bevacizumab Added to Standard First-line Chemotherapy and Overall Survival Among Patients With RAS Wild-type, Left-Sided Metastatic Colorectal Cancer: A Randomized Clinical Trial. *JAMA* (2023) 18: 329: 1271–1282.