



ARCHIVIO ISTITUZIONALE DELLA RICERCA

Alma Mater Studiorum Università di Bologna Archivio istituzionale della ricerca

Identification of Fetuses at Increased Risk of Trisomies in the First Trimester Using Axial Planes

This is the final peer-reviewed author's accepted manuscript (postprint) of the following publication:

Published Version:

Identification of Fetuses at Increased Risk of Trisomies in the First Trimester Using Axial Planes / Montaguti, Elisa; Diglio, Josefina; Petrachi, Benedetta; Arosio, Viola; Fiorentini, Marta; Cavalera, Marta; Pellegrino, Anita; Amodeo, Silvia; Lenzi, Jacopo; Pilu, Gianluigi. - In: FETAL DIAGNOSIS AND THERAPY. - ISSN 1015-3837. - ELETTRONICO. - 51:1(2024), pp. 1-6. [10.1159/000533879]

This version is available at: <https://hdl.handle.net/11585/955788> since: 2024-02-06

Published:

DOI: <http://doi.org/10.1159/000533879>

Terms of use:

Some rights reserved. The terms and conditions for the reuse of this version of the manuscript are specified in the publishing policy. For all terms of use and more information see the publisher's website.

(Article begins on next page)

This item was downloaded from IRIS Università di Bologna (<https://cris.unibo.it/>).
When citing, please refer to the published version.

This is the final peer-reviewed accepted manuscript of:

Montaguti E, Diglio J, Petrachi B, Arosio V, Fiorentini M, Cavalera M, Pellegrino A, Amodeo S, Lenzi J, Pilu G.

Identification of Fetuses at Increased Risk of Trisomies in the First Trimester Using Axial Planes.

Fetal Diagn Ther. 2024; 51(1): 1-6.

The final published version is available online at: [10.1159/000533879](https://doi.org/10.1159/000533879)

Terms of use:

Some rights reserved. The terms and conditions for the reuse of this version of the manuscript are specified in the publishing policy. For all terms of use and more information see the publisher's website.

This item was downloaded from IRIS Università di Bologna (<https://cris.unibo.it/>)

When citing, please refer to the published version.

1 **Identification of fetuses at increased risk of trisomies in the first trimester using axial planes**

2 Elisa MONTAGUTI¹, MD, PhD, Josefina DIGLIO¹, MD, Benedetta PETRACHI¹, MD, Viola
3 AROSIO¹, MD, Marta FIORENTINI¹, MD, Marta CAVALERA¹, MD, Anita PELLEGRINO¹,
4 MD, Silvia AMODEO¹, MD, Jacopo LENZI², PhD, Gianluigi PILU¹, Professor

5 *¹Obstetric Unit, IRCCS Azienda Ospedaliero-Universitaria di Bologna*

6 *²Department of Biomedical and Neuromotor Sciences, University of Bologna*

7

8 **Corresponding author:**

9 Elisa Montaguti

10 Obstetric Unit, IRCCS Azienda Ospedaliero-Universitaria di Bologna

11 Via Massarenti 13, 40138 Bologna, Italy

12 Tel + 39 051 214 4369

13 e-mail: elisa.montaguti87@gmail.com

14 Orcid: 0000-0002-3176-9184

15

16 **Short title:** detecting fetuses at increased risk of trisomies by transverse planes.

17

18 **Number of Tables:** 3

19 **Number of Figures:** 1

20 **Word count:** 1634 (abstract and main text)

21 **Keywords:** nuchal translucency, combined test, trisomy, first trimester.

22 **Mini - Summary**

- 23 • What does this study add to current knowledge? Increased nuchal translucency can be
24 accurately identified in the transverse plane, but the ability of axial measurements in the
25 identification of fetuses with increased risk during the first trimester has not been assessed
26 so far, especially in those with unfavorable position. The present study demonstrates that
27 fetuses at increased risk of trisomies can be reliably identified by axial views during first
28 trimester screening scan.
- 29 • What are the main clinical implications? Assessment of nuchal translucency in the axial
30 scan identified accurately fetuses at increased risk of trisomies during the first trimester
31 aneuploidies screening. This approach may be technically advantageous in those fetuses
32 with unfavorable position.

33 **Abstract**

34 **Introduction:** the measurement of nuchal translucency is crucial for the assessment risk of
35 aneuploidies in the first trimester. We investigate the ability of nuchal translucency (NT) assessed
36 by a transverse view of the fetal head to detect fetuses at increased risk of common aneuploidies at
37 11-13 weeks of gestation.

38 **Methods:** we enrolled a nonconsecutive series of women who attended our outpatient clinic from
39 January 2020 to April 2021 for aneuploidies screening by means of first trimester combined test.
40 All women were examined by operators certified by the Fetal Medicine Foundation. In each patient
41 NT measurements were obtained both from median sagittal view and transverse view. We
42 calculated the risk of aneuploidy using NT measurements obtained both with sagittal and axial
43 scans and then we compared the results.

44 **Results:** a total of 1023 women were enrolled. An excellent correlation was found between sagittal
45 and transverse NT measurements. The sensitivity and specificity of the axial scan to identify fetuses
46 that were deemed at risk of trisomy 21 using standard sagittal scans was $40/40 = 100.0\%$ (95% CI
47 $91.2-100.0$) and $977/983 = 99.4\%$ (95% CI $98.7-99.7$) respectively. The sensitivity and specificity
48 of the axial scan to identify fetuses at risk of trisomy 13 or 18 was $16/16 = 100.0\%$ (95% CI $80.6-$
49 100.0) and $1005/1007 = 99.8\%$ (95% CI $99.3-99.9$).

50 **Conclusions:** when the sonogram, a part of combined test screening, is performed by an expert
51 sonologist, axial views can reliably identify fetuses at increased risk of trisomies without an
52 increase of false negative results.

53 **Introduction**

54 The accurate measurement of nuchal translucency (NT) is a key part of the screening for
55 chromosomal abnormalities in the first trimester of pregnancy[1-5]. In the so-called “combined
56 test”, the assessment of the fluid space behind the fetal head in a sagittal scan is combined with
57 demographic and anthropometric characteristics of the patient and with biochemical parameters
58 (beta fraction of the chorionic gonadotropin and pregnancy-associated plasma protein A) to provide
59 a risk assessment of fetal aneuploidies[4, 6]. An invasive procedure for the assessment of fetal
60 karyotype is offered when the calculated risk of aneuploidies is increased as well as in case of a
61 large NT measurements, most frequently when the measurement is in excess of the 99th percentile,
62 i.e. greater than 3.5 mm[7-13].

63 At present the gold standard for NT sonographic measurement is the sagittal approach, that however
64 is extremely dependent on the fetal position and is time consuming when the fetus is not lying on
65 his back. We have recently demonstrated that NT measurement in the axial plane provides very
66 similar results and can be accomplished more rapidly[14, 15].

67 The aim of the present study was to evaluate whether the axial measurement of NT was equally
68 accurate in the calculation of the risk of common aneuploidies and in identifying fetuses at
69 increased risk, compared with sagittal assessment.

70

71 **Materials and methods**

72 This was a retrospective analysis of the obstetric population described in a previous study[14]. A
73 non-consecutive series of women were enrolled from a larger project promoted by the Health
74 Authorities of the Emilia-Romagna region, which aimed to compare the performance of the
75 combined test and Non Invasive Prenatal Testing (NIPT) in identifying fetuses at increased risk of
76 trisomies 21, 13 and 18. In accordance with the recommendations of the scientific literature and the
77 Italian Ministry of Health, the risk of trisomy 21 is defined as increased when it is equal to or
78 greater than 1 case in 300, while the risk of trisomy 13 and 18 is defined as increased when it is

79 equal to or greater than 1 case in 150. In these cases and in those with an NT equal or greater than
80 3.5 mm[10, 16] the determination of fetal karyotype by means of chorionic villous sampling
81 (usually between 11th and 14th weeks) or amniocentesis (between 16th and 18th weeks) is offered to
82 the patient.

83 For each woman enrolled, an operator certified by Fetal Medicine Foundation (FMF) measured the
84 NT by sagittal scan according to the FMF recommendations[4, 17]; this measurement was used as a
85 part of the combined test to estimate the risk of trisomies using the software of the First Trimester
86 Screening Program (version 2.8.1_4). The same operator then acquired an axial image of the fetal
87 head using a Voluson E8 or E10 machine (General Electric Kretz Ultrasound, Zipf, Austria) with a
88 3-7 MHz probe. As previously described[14], a view of fetal head was obtained at the level of the
89 suboccipitobregmatic plane that crosses the posterior cranial fossa, similarly to what is performed in
90 the second trimester for the measurement of the nuchal fold. The frontal horns, the thalamus and the
91 cerebellar peduncles are visualized. NT was then measured off-line by a second operator, blinded to
92 the sagittal measurement, the combined test and NIPT results. The calipers, as previously
93 described[14], were positioned from the external contour of the occipital bone to the external
94 contour of the skin. This axial measurement was then used to calculate the risks of aneuploidies
95 using the FMF software. In some cases, the skin is closely apposed to the occipital bone and no NT
96 is visible in the axial plane. We have previously demonstrated that in these cases the NT in the
97 sagittal plane is always within normal limits with a mean dimension of 1.26 ± 0.25 mm (range 0.50
98 to 2.10). In such cases, we used this value for the risk calculation.

99

100 *Statistics*

101 Mean and standard deviation were used as descriptive statistic for continuous variables, while
102 frequencies and percentages were computed for discrete or categorical variables.

103 The degree of agreement between axial and sagittal NT measures in identifying fetuses at high risk
104 of trisomies was measured by Cohen's kappa (κ). To assess the validity of the novel approach (axial

105 scan) to discriminate between the two outcomes as compared with the gold standard (sagittal scan),
106 two additional indices were evaluated: sensitivity (proportion of subjects with the condition who are
107 correctly identified by the novel test) and specificity (proportion of subjects without the condition
108 who are correctly identified by the novel test). The 95% confidence intervals (CIs) for Cohen's κ
109 were calculated by Fleiss method, while the 95% CIs for sensitivity and specificity were calculated
110 by Wilson score.

111 Moreover, the Bland–Altman plot was used to compare the two measurement techniques. More
112 specifically, as suggested by the literature [Krouwer 2008], the differences between the two
113 techniques were plotted against the reference method (i.e., the sagittal scan) instead of the averages
114 of the two. Horizontal lines were drawn at the mean difference and at the 95% limits of agreement,
115 which were defined as the mean difference \pm 1.96 times the standard deviation of the differences.
116 Ninety-five percent confidence intervals (CIs) for the mean difference and for both the upper and
117 lower limits of agreement were also provided [Bland & Altman, 1999].

118 All analyses were performed by means of Stata 15 software (StataCorp. 2017. Stata Statistical
119 Software: Release 15. College Station, TX: StataCorp LP).

120

121 **Results**

122 1023 women were enrolled for the purpose of the study, whose demographic and ultrasound
123 characteristics are shown in Table 1. Among those, 40 (3.9%) fetuses were found to be at high risk
124 for trisomy 21, 16 (1.6%) for trisomy 13 or 18 by means of the sagittal views using the Fetal
125 Medicine Foundation algorithm in the so-called combined test. Among these, 14 fetuses (1.4%)
126 were at risk for all the three aneuploidies evaluated and in 2 fetuses the risk during the combined
127 test was not computed due to an abnormally increased nuchal translucency both in the sagittal as
128 well as in axial scan.

129 Cohen's κ for the classification of fetuses at risk of trisomy 21 was 0.927 (95% CI 0.869 to 0.985),
130 suggesting an almost perfect agreement between axial and sagittal scans. In particular, as shown in

131 Table 2, the sensitivity of the axial compared with the sagittal scan was $40/40 = 100.0\%$ (95% CI
132 91.2 to 100.0), while the specificity was $977/983 = 99.4\%$ (95% CI 98.7 to 99.7). Cohen's κ for the
133 classification of fetuses at risk of trisomy 13 or 18 was 0.940 (95% CI 0.858 to 1.000), suggesting
134 an almost perfect agreement between axial and sagittal scans. As shown in Table 3, the sensitivity
135 of the axial scan to identify fetuses at risk of trisomy 13 or 18 compared with the sagittal scan was
136 $16/16 = 100.0\%$ (95% CI 80.6 to 100.0), and the specificity to identify fetuses not at risk was
137 $1005/1007 = 99.8\%$ (95% CI 99.3 to 99.9).

138 As shown in Figure 2, mean difference between the risk measures for trisomy 21 obtained with the
139 axial vs. sagittal scans was -25.97 (95% CI -98.07 to 46.13) and exhibited a 95% agreement
140 ranging from -2327.05 (95% CI -2450.25 to -2203.85) to 2275.10 (95% CI 2151.90 to 2398.30).
141 Lastly, as shown in Figure 3, mean difference between the risk measures for trisomy 13 or 18
142 obtained with the axial vs. sagittal scans was 227.07 (95% CI 64.00 , 390.14) and exhibited a 95%
143 agreement ranging from -4977.43 (95% CI -5256.08 to -4698.78) to 5431.57 (95% CI 5152.92 to
144 5710.22).

145

146 **Discussion**

147 *Principal findings of the study*

148 Our study indicates that as a part of the combined test axial NT measurements are as accurate as the
149 sagittal measurements in the identification of fetuses at risk for common aneuploidies. As already
150 demonstrated in a previous analysis of the same population, the axial measurement has excellent
151 intra- and inter-operator reproducibility and, compared to the sagittal scan used as a gold standard,
152 showed no systematic differences with an extremely low average difference in the
153 measurements[14, 15]. Particularly in our population, axial scanning did not miss any fetus
154 identified at increased risk for trisomy 21, 13, 18 on the basis of standard combined test.

155

156 *Results in the context of what is known, strengths and limitations*

157 This, to our knowledge, is the first study that compares the effectiveness of axial measurement of
158 nuchal translucency in identifying high-risk fetuses for aneuploidy in the first trimester of gestation.
159 Certainly, to confirm the usefulness of this method, a prospective validation is required. An
160 important limitation was the finding of some false positives; in particular 6 fetuses not at increased
161 risk for trisomy 21 with the standard sagittal scan were found to be at increased risk with the
162 transverse approach, as well as 2 fetuses for trisomy 13/18. The routine use of this axial technique
163 could lead to an increase, albeit slightly, in the use of invasive diagnosis, which is however been
164 demonstrated to be safe in expert hands[18].

165

166 *Clinical and research implications*

167 Additionally, all measurements and evaluations in our study were performed by experienced first
168 trimester ultrasound operators, certified by the Fetal Medicine Foundation. The usefulness of axial
169 scanning even in the hands of less experienced sonographers has yet to be demonstrated. Further
170 prospective studies are needed to propose this scan particularly in patients who undergo a NIPT test.
171 A sagittal view of fetal head in the first trimester of pregnancy is useful not only for the
172 measurement of nuchal translucency, but also for the evaluation of fetal brain and profile[19, 20]. In
173 particular, when an abnormal appearance of intracranial translucency or of brainstem-to-occipital
174 bone diameter is detected, a suspect of open spina bifida or of posterior fossa malformation can be
175 raised. However, these details can be evaluated by sagittal scans even when the fetus is not perfectly
176 oriented, i.e. lying on his back, not separated from the amnion or in case of hyperextension -
177 hyperflexion of the neck, all cases where the midsagittal scan specific for NT evaluation is not
178 feasible according to the standards of the Fetal Medicine Foundation; this obstacle could be
179 surmounted by an axial evaluation.

180

181 *Conclusions*

182 Obviously, the goal of our study is not to replace in the clinical practice during first trimester
183 screening the median sagittal scan, validated by a large variety of studies. However, we have shown
184 that even using an axial approach, which is less time-consuming and less dependent on fetal
185 position, the risk of fetal trisomies is not underestimated compared with a standard combined test.
186 We suggest that in cases in which a sagittal view of the fetal head is difficult or impossible to
187 obtain, an axial approach may be considered.

188

189 **Statements**

190 **Acknowledgements**

191 The authors report no acknowledgements.

192

193 **Statements of Ethics**

194 The study protocol was approved by the local Ethics Committee of Sant'Orsola-Malpighi Hospital
195 and a consent form signed at recruitment was obtained from each eligible patient
196 (203/2020/Oss/AOUBo). The study protocol conforms to the ethical guidelines of the “World
197 Medical Association (WMA) Declaration of Helsinki-Ethical Principles for Medical Research
198 Involving Human Subjects” adopted by the 18th WMA General Assembly, Helsinki, Finland, June
199 1964 and amended by the 59th WMA General Assembly, Seoul, South Korea, October 2008.

200

201 **Conflict of interest:** the Authors report no conflict of interest.

202

203 **Funding sources:** no funding was received for the purpose of this study.

204

205 **Authors contributions:**

206 EM contributed to the conception of the study, collected data and drafted the manuscript; JD, BP,
207 VA, MF, MC, AP and SA contributed to the conception of the study and collected data, JL
208 performed statistical analysis, GP contributed to the conception of the study and to data collection.
209 All Authors revised and approved the final version of the paper.

210

211 **Data Availability statement:**

212 The data that support the findings of this study are not publicly available due to privacy reason but
213 are available from the corresponding author upon reasonable request.

214

215 **References**

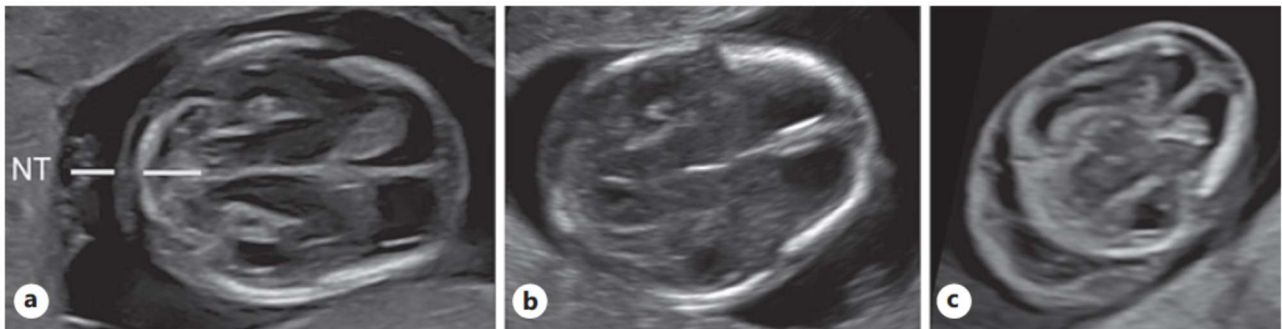
- 216 1. Nicolaides KH. Nuchal translucency and other first-trimester sonographic markers of
217 chromosomal abnormalities. *American journal of obstetrics and gynecology*. 2004;191(1):45-67.
- 218 2. Nicolaides KH, Azar G, Byrne D, Mansur C, Marks K. Fetal nuchal translucency:
219 ultrasound screening for chromosomal defects in first trimester of pregnancy. *Bmj*.
220 1992;304(6831):867-9.
- 221 3. Pandya PP, Snijders RJ, Johnson SP, De Lourdes Brizot M, Nicolaides KH. Screening for
222 fetal trisomies by maternal age and fetal nuchal translucency thickness at 10 to 14 weeks of
223 gestation. *Br J Obstet Gynaecol*. 1995;102(12):957-62.
- 224 4. Salomon LJ, Alfirevic Z, Bilardo CM, Chalouhi GE, Ghi T, Kagan KO, et al. ISUOG
225 practice guidelines: performance of first-trimester fetal ultrasound scan. *Ultrasound in obstetrics &*
226 *gynecology : the official journal of the International Society of Ultrasound in Obstetrics and*
227 *Gynecology*. 2013;41(1):102-13.
- 228 5. Bilardo CM, Chaoui R, Hyett JA, Kagan KO, Karim JN, Papageorghiou AT, et al. ISUOG
229 Practice Guidelines (updated): performance of 11-14-week ultrasound scan. *Ultrasound Obstet*
230 *Gynecol*. 2023;61(1):127-43.
- 231 6. Wright D, Syngelaki A, Bradbury I, Akolekar R, Nicolaides KH. First-trimester screening
232 for trisomies 21, 18 and 13 by ultrasound and biochemical testing. *Fetal Diagn Ther*.
233 2014;35(2):118-26.
- 234 7. Nicolaides KH, Heath V, Cicero S. Increased fetal nuchal translucency at 11-14 weeks.
235 *Prenat Diagn*. 2002;22(4):308-15.
- 236 8. Pandya PP, Brizot ML, Kuhn P, Snijders RJ, Nicolaides KH. First-trimester fetal nuchal
237 translucency thickness and risk for trisomies. *Obstet Gynecol*. 1994;84(3):420-3.
- 238 9. Pandya PP, Kondylis A, Hilbert L, Snijders RJ, Nicolaides KH. Chromosomal defects and
239 outcome in 1015 fetuses with increased nuchal translucency. *Ultrasound Obstet Gynecol*.
240 1995;5(1):15-9.

- 241 10. Petersen OB, Smith E, Van Opstal D, Polak M, Knapen M, Diderich KEM, et al. Nuchal
242 translucency of 3.0-3.4 mm an indication for NIPT or microarray? Cohort analysis and literature
243 review. *Acta Obstet Gynecol Scand.* 2020;99(6):765-74.
- 244 11. Rao RR, Valderramos SG, Silverman NS, Han CS, Platt LD. The value of the first trimester
245 ultrasound in the era of cell free DNA screening. *Prenat Diagn.* 2016;36(13):1192-8.
- 246 12. Srebniak MI, de Wit MC, Diderich KE, Govaerts LC, Joosten M, Knapen MF, et al.
247 Enlarged NT (≥ 3.5 mm) in the first trimester - not all chromosome aberrations can be detected by
248 NIPT. *Mol Cytogenet.* 2016;9(1):69.
- 249 13. Vora NL, Robinson S, Hardisty EE, Stamilio DM. Utility of ultrasound examination at 10-
250 14 weeks prior to cell-free DNA screening for fetal aneuploidy. *Ultrasound Obstet Gynecol.*
251 2017;49(4):465-9.
- 252 14. Montaguti E, Rizzo R, Diglio J, Di Donna G, Brunelli E, Cofano M, et al. Increased nuchal
253 translucency can be ascertained using transverse planes. *Am J Obstet Gynecol.* 2022.
- 254 15. Montaguti E, Pilu G. Invasive diagnosis after first-trimester aneuploidy screening. *American*
255 *journal of obstetrics and gynecology.* 2022.
- 256 16. Maya I, Yacobson S, Kahana S, Yeshaya J, Tenne T, Agmon-Fishman I, et al. Cut-off value
257 of nuchal translucency as indication for chromosomal microarray analysis. *Ultrasound Obstet*
258 *Gynecol.* 2017;50(3):332-5.
- 259 17. Nicolaides KH. Screening for fetal aneuploidies at 11 to 13 weeks. *Prenat Diagn.*
260 2011;31(1):7-15.
- 261 18. Salomon LJ, Sotiriadis A, Wulff CB, Odibo A, Akolekar R. Risk of miscarriage following
262 amniocentesis or chorionic villus sampling: systematic review of literature and updated meta-
263 analysis. *Ultrasound Obstet Gynecol.* 2019;54(4):442-51.
- 264 19. Volpe P, Contro E, Fanelli T, Muto B, Pilu G, Gentile M. Appearance of fetal posterior
265 fossa at 11-14 weeks in fetuses with Dandy-Walker malformation or chromosomal anomalies.
266 *Ultrasound Obstet Gynecol.* 2016;47(6):720-5.

267 20. Chaoui R, Benoit B, Mitkowska-Wozniak H, Heling KS, Nicolaides KH. Assessment of
268 intracranial translucency (IT) in the detection of spina bifida at the 11-13-week scan. *Ultrasound*
269 *Obstet Gynecol.* 2009;34(3):249-52.
270

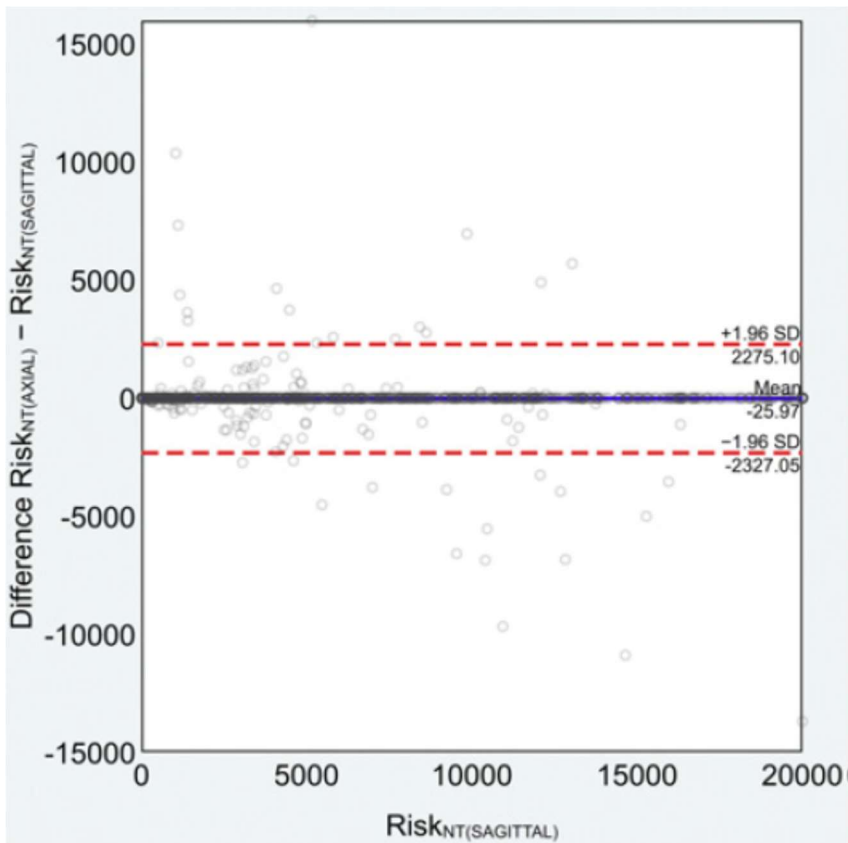
271 **Figure legends**

272 **Fig. 1.** Axial scan of the fetal head, passing through the frontal horns, the thalamus and the
273 cerebellar peduncles. Axial nuchal translucency is measured from the external contour of the
274 occipital bone and that of the skin (a). Example of a scan in which the translucency is not
275 measurable because there is no accumulation of fluid between the occipital bone and the skin (b). A
276 fetus with increased axial nuchal translucency (c).



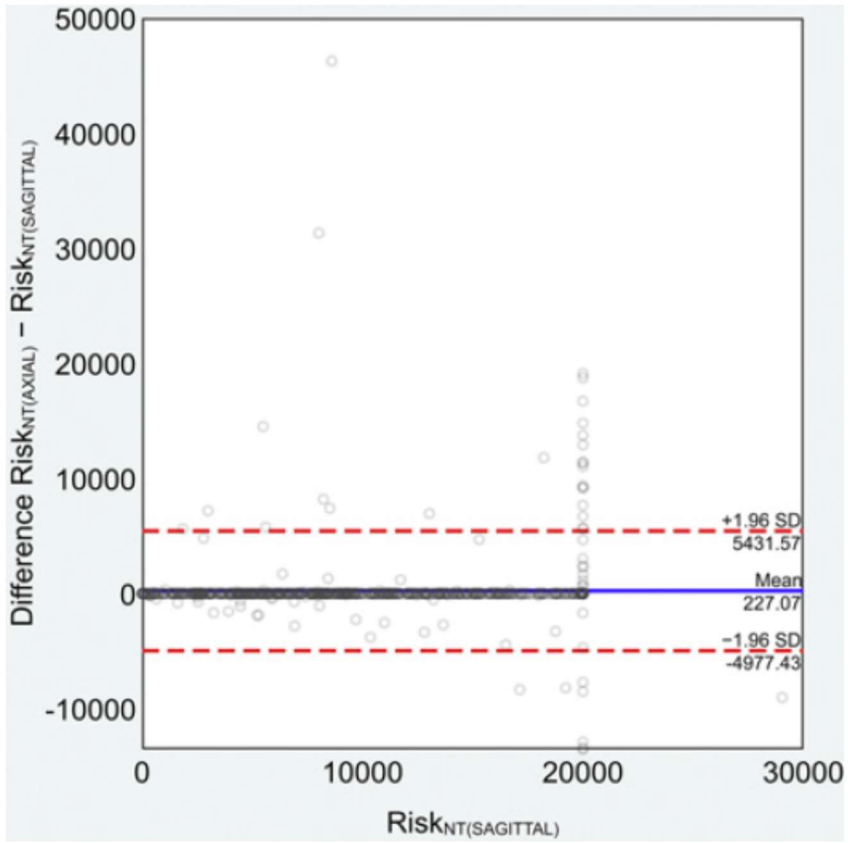
277

278 **Fig. 2.** Bland–Altman plot of risk measures for trisomy 21 obtained with axial vs. sagittal views.
279 Dashed lines indicate the 95% limits of agreement of the differences between the two techniques.



280

281 **Fig. 3.** Bland–Altman plot of risk measures for trisomy 13 or 18 obtained with axial vs. sagittal
282 views. Dashed lines indicate the 95% limits of agreement of the differences between the two
283 techniques.



284