




Marginal versus Segmental Mandibulectomy in the Treatment of Oral Cavity Cancer: A Systematic Review and Meta-analysis

Carlos Miguel Chiesa-Estomba¹ Miguel Mayo-Yanez² Giuditta Manelli³ Gabriele Molteni⁴
Jerome Lechien⁵ Nicolas Fakhry⁶ Antoine Melkane⁷ Christian Calvo-Henriquez⁸ David Kalfert⁹
Tareck Ayad¹⁰

¹ Department of Otorhinolaryngology - Head and Neck Surgery, Hospital Universitario de Donostia, San Sebastian, Guipuzcoa, Spain

² Department of ENT, Hospital Juan Canalejo de La Coruña, A Coruna, Galicia, Spain

³ Department of ENT, Azienda Ospedaliero Universitaria Careggi, Firenze, Toscana, Italy

⁴ Department of ENT, Università degli Studi di Verona, Verona, Veneto, Italy

⁵ Department of ENT, Hôpital Foch, Suresnes, Île-de-France, France

⁶ Department of ENT, Assistance Publique Hôpitaux de Marseille, Marseille, Provence-Alpes-Côte d'Azur, France

⁷ Department of ENT, Hôpital Hôtel Dieu de France, Beirut, Lebanon

Address for correspondence Carlos Miguel Chiesa-Estomba, MD, MSc, PhD, FEBEORL-HNS, Department of Otorhinolaryngology - Head and Neck Surgery, Hospital Universitario de Donostia, Dr. Begiristain Dr. Begiristain Pasealekua 1, San Sebastian, Guipuzcoa 20014, Spain (e-mail: chiesaestomba86@gmail.com).

⁸ Department of ENT, Hospital Universitario de Santiago de Compostela, Santiago de Compostela, Galicia, Spain

⁹ Department of ENT, Charles University, Praha, Czech Republic

¹⁰ Department of ENT, University of Montreal Hospital Centre, Montreal, Quebec, Canada

Int Arch Otorhinolaryngol 2023;27(4):e733–e743.

Abstract

Introduction Oral cavity squamous cell carcinoma (OCSCC) is the most common malignancy in the oral cavity. Two types of mandibular resections have been described: the segmental mandibulectomy and the marginal mandibulectomy. Both may have a different impact over the quality of life, oncological prognosis, and functional or aesthetic result.

Objectives The aim of this study was to systematically explore the literature to determine the survival outcomes and disease control rates in patients who underwent segmental or marginal mandibulectomy for OCSCC with histological evidence of cortical and medullary bone invasion.

Data Synthesis This review involved a systematic search of the electronic databases MEDLINE/PUBMED, Google Scholar, Ovid Medline, Embase, and Scopus including articles from 1985 to 2019. Fifteen articles were included for qualitative analysis and 11 articles were considered for meta-analysis calculations. All of them correspond to retrospective cohort studies.

Conclusion This systematic review reveals the low-level evidence regarding the impact over local control or survival according to the type of mandibulectomy. Our results need to be considered with precaution according to the limited evidence available. We just found difference regarding the 5-year disease-free survival, and a tendency in favor of segmental mandibulectomy was confirmed when medullary invasion was evident.

Keywords

- ▶ oral cancer
- ▶ oral cavity
- ▶ mandible
- ▶ mandibulectomy
- ▶ survival

received
February 24, 2022
accepted after revision
May 15, 2022
article published online
April 11, 2023

DOI <https://doi.org/10.1055/s-0042-1750764>.
ISSN 1809-9777.

© 2023. Fundação Otorrinolaringologia. All rights reserved.
This is an open access article published by Thieme under the terms of the Creative Commons Attribution-NonDerivative-NonCommercial-License, permitting copying and reproduction so long as the original work is given appropriate credit. Contents may not be used for commercial purposes, or adapted, remixed, transformed or built upon. (<https://creativecommons.org/licenses/by-nc-nd/4.0/>)
Thieme Revinter Publicações Ltda., Rua do Matoso 170, Rio de Janeiro, RJ, CEP 20270-135, Brazil

Introduction

Oral cavity squamous cell carcinoma (OCSCC) is the most common malignancy in the oral cavity.¹ It affects ~ 300,000 patients worldwide each year and represents the 6th most common global malignancy and 30% of cancers affecting the head and neck region.¹⁻³ Regarding the treatment strategy, surgery is still considered the first choice of treatment of OCSCC, although multimodal therapy, including adjuvant radiation therapy (RT) with or without chemotherapy (CT) can be used in advanced stages.

According to previous studies, mandibular involvement rates range between 12 and 56%, and when the tumor clearly invades the mandible, the affected bone needs to be resected in continuity with the soft tissues. However, when the invasion is not clear or significant, there is no guideline based on evidence that could assist in the decision on mandibular management.⁴⁻⁸

Two types of mandibular resections have been described: the segmental mandibulectomy (SM), in which the resection involves the entire vertical height of the mandible with interruption of the continuity of the mandible, and the marginal mandibulectomy (MM), in which the resection just involves a part of the height of the mandible with preservation of the continuity of the mandible. Both may have a different impact over the quality of life, oncological prognosis and functional or aesthetic result when the surgeons fail in their decision process.⁴

The type of mandibulectomy may be controversial, and some surgeons consider a marginal resection as a reasonable option for cancers adherent to the periosteum or superficially eroding the mandibular cortex without invasion of the medullary portion.^{9,10} The aim of this study was to systematically explore the literature to determine the survival outcomes and disease control rates in patients who underwent MM or SM for OCSCC with histological evidence of cortical and medullary bone invasion.

Review of the Literature

This meta-analysis involved a systematic review using the Population Intervention Comparison and Outcome (PICO)¹¹ modeling and following the guidelines proposed by the preferred reporting items for systematic reviews and meta-analyses (PRISMA) statement.¹² The project is an initiative of the Young Otolaryngologist Group of the International Federation of Otolaryngologic Societies (YO-IFOS).

Population and Inclusion/Exclusion Criteria

The inclusion criteria considered for this meta-analysis were randomized clinical trials and prospective or retrospective cohort studies investigating the differences among marginal and segmental mandibulectomy in patients operated on for an OCSCC reporting at least 5 years of follow-up. T (Tumor) and N (Node) stages as well as radiological preoperative assessment were investigated. The exclusion criteria were single-arm studies (without MM or SM subjects' groups), studies including pediatric cases, salvage surgery, and stud-

ies with less than 20 patients treated in each group or not matching the inclusion criteria. The need for neck dissection or mandibular reconstruction was not considered an exclusion criterion.

Intervention and Comparison

In the intervention group were included patients who underwent MM; while the comparison group was established with patients who underwent SM, hemi-mandibulectomy, and subtotal or total mandibulectomy, according to the extent of mandibular invasion (no invasion, cortical invasion, or medullary invasion).

Outcomes

The primary outcome evaluated was disease-free survival (DFS), and the secondary outcomes were overall survival (OS) and local control (LC), all of them after at least 5 years of follow-up.

Search Strategy

The search was performed from December 1985 to December 2020. Manuscripts in English, Spanish, Italian, Chinese, and French were considered. The search was based on a combination of medical subject heading (MeSH) terms and free text words: (1) *oral cavity cancer*, (2) *marginal mandibulectomy*, (3) *segmental mandibulectomy*, (4) *squamous cell carcinoma*, (5) *bone invasion*, and (6) *mandibular osteotomy*. This resulted in a total of 171 manuscripts that were subjected to our inclusion and exclusion criteria. The titles and abstracts were screened by two investigators (C. M. C. E. and M. M. Y.) to discard irrelevant publications. The information extracted from each study included the following: author, year of publication, number of patients treated, type of mandibulectomy, bone invasion, DFS, OS, 5-year survival rate and LC. Tumor stage or complementary treatment data could not be included in the final analysis due to the variabilities among time periods and treatment strategies or the lack of information in the studies included.

Assessment of Quality

Two authors evaluated the methodological quality of the identified studies using the Oxford Center for Evidence-Based Medicine (OCEBM) levels of evidence.¹³ Bias analysis was performed using the quality assessment tool of the *National Institutes of Health* for each type of study.¹⁴

Statistical Analysis

A meta-analysis of selected studies with an odds ratio (OR) comparing patients who underwent MM (experimental group) and patients who underwent SM (control group) was performed with the Cochrane Review Manager 5.4 (Nordic Cochrane Centre, Cochrane Collaboration, 2020, Copenhagen, Denmark). A fixed-effects model was used in this study. The heterogeneity assumption was checked using the Q-test and the I² test.

The Cochrane Review Manager uses the Mantel-Haenszel method for calculating the weighted summary OR under the fixed-effects model, and the heterogeneity statistic is

incorporated to calculate the summary OR under the random-effects model. The pooled OR with 95% confidence interval (CI) is given for both fixed-effects model and random-effects model.

Regarding the meta-analysis, dichotomous data and time-to-event data were considered. The dichotomous data were measured by relative risk (RR) with 95% of confidence interval and by hazard ratio (HR) for time-to-event data. The statistical significance for the hypothesis test was set at $p < 0.05$. The subgroup analysis was based on different types of mandibular invasion and different types of data.

Besides, a chi-squared test with Yates correction for continuity was applied with a 2-tailed p -value for the comparison according to sex, histology, and type of procedure from independent samples. A p -value < 0.05 was considered statistically significant. A number-needed-to-treat (NNT) analysis was adopted as a method of sensitivity analysis, when possible.

A total of 201 manuscripts were revised, 107 were excluded due to duplication and 97 studies met our inclusion criteria. From those, 51 were excluded due to the absence of randomization, 37 due to inclusion of oropharyngeal tumors, 3 due to the inclusion of parapharyngeal tumors, and 3 because they reported less than 5 years of follow-up. (► Fig. 1) Five-year LC, DFS, and OS data were included in ►Supplementary Table S1 and tumor, node, metastasis (TNM) stage and radiological data were included in ►Supplementary Table S2.

Fifteen articles were included for qualitative analysis,^{15–29} and 11 articles were considered for meta-analysis calculations.^{2,6,16–21,23,28,29} All of them correspond to retrospective cohort studies comparing the effectiveness of horizontal marginal and segmental mandibulectomy. Two-thousand and twenty-three patients were included; 857

patients in the MM group, and 1,166 patients in the SM group. Variables like age, sex, histology, type of surgery, and maximum time to follow-up were compared between both groups (► Table 1). The demographic data between the MM and SM groups were similar. The rate of patients who underwent MM and SM was comparable (42.4% and 57.6%, respectively). The most common tumor locations were the gingiva, floor of the mouth, tongue, cheek, and retromolar trigone. The postoperative pathological reports showed that the frequency of mandibular invasion was between 21 and 71.4% among the patients included. The risks of bias are included in ►Table 2.

Six studies reported LC according to both techniques.^{16,19,20,23,25,26} The results of the meta-analysis revealed no statistical significance in the 5-year LC rate between MM or SM methods among all patients (RR = 0.98, 95% CI 0.92–1.05, $p = 0.58$). However, for patients with pathologically confirmed mandibular invasion, weak evidence indicated that the LC rate decreased by 9.9% for marginal resection compared with segmental resection (RR = 1.13, 95% CI 0.85–1.52, $p = 0.40$) (► Fig. 2).^{19,26} The LC rate was further evaluated using the Kaplan-Meier survival curve according to the time-to-event analysis, and the results from the limited data showed no difference between both techniques in patients with mandibular invasion (HR = 1.71, 95% CI 0.82–3.55, $p = 0.54$) (► Fig. 2, ► Figure 3).^{20,29}

Five studies reported DFS data.^{17,21,25,26,29} When all patients were considered, the 5-year DFS rate meta-analysis indicated a non-significant tendency in favor of SM in oral cancer patients (RR = 1.11, 95% CI 0.98–1.25, $p = 0.09$). However, when medullary invasion was considered, the limited evidence obtained in this comparison indicates that MM

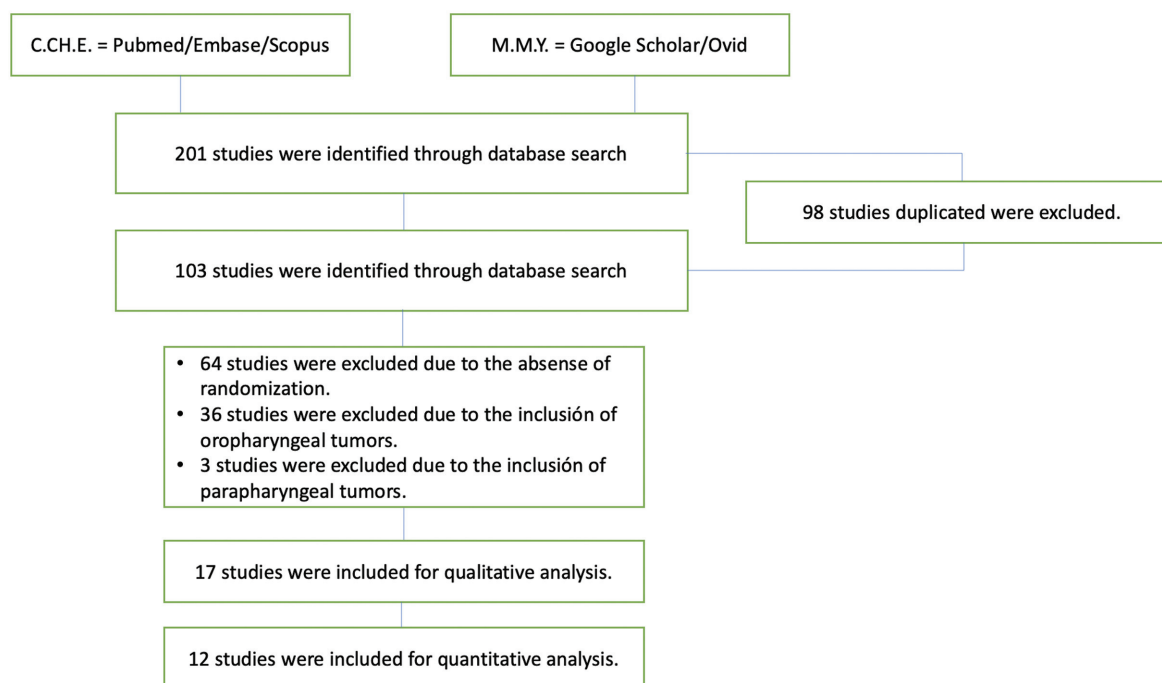


Fig. 1 Prisma Flowchart.

Table 1 Demographic data

Author/Year/ Country	Type of study	Number of patients	Sex	Mean age	Tumor location	Marginal mandibulectomy	Segmental mandibulectomy	Bone invasion MM/SM	Complementary treatment
Wald – 1983, USA ¹⁵	R	47	Male: 33/Female: 32	ND	Oral cavity	21	26	ND	18 patients receive a segmental mandibulectomy + RT. 16 patients receive a marginal mandibulectomy + RT.
Barttelbort – 1987, USA ¹⁶	R	38	Male: 34/Female: 4	59	Oral cavity	21	17	3/5	ND
Soo – 1988, USA ¹⁷	R	241	ND	ND	Gingiva	81	160	16/64	ND
Totsuka – 1991, Japan. ¹⁸	R	53	Male: 34/Female: 19	65 (min: 42/max: 84)	Gingiva	23	30	ND	ND
Dubner – 1993, USA ¹⁹	R	130	ND	ND	FOM, gingiva, RMT, tongue, cheek	79	51	9/33	ND
Overholt – 1996, USA ²⁰	R	129	ND	ND	Gingiva	59	70	ND	ND
Ord – 1997, USA ²¹	R	46	Male: 26/Female: 20	63 (min: 38/max: 89)	FOM, RMT, cheek, gingiva	26	20	2/13	ND
Ash – 2000, Canada ²²	R	107	Male: 71/Female: 36	62 (28–65)	FOM, gingiva, RMT	37	70	10/38	ND
Nie – 2000, China ²³	R	248	Male: 167/Female: 81	42 (min: 21/max: 78)	Tongue, cheek, gingiva, FOM, RMT	82	166	ND	ND
Wearning – 2001, USA ²⁴	R	222	Male: 146/Female: 76	63 (min: 33/max: 93)	Cheek, gingiva, RMT, FOM, tongue	182	40	ND	ND
Shaw – 2004, UK ²⁵	R	100	Male: 56/Female: 40	63 (min 32/max: 89)	FOM, RMT, gingiva, tongue, cheek	35	65	8/54	ND
Patel – 2008, Australia ²⁶	R	111	Male: 81/Female: 30	63 (min: 30/max: 85)	FOM, gingiva, RT, cheek	78	33	36/31	ND
Qiu – 2017, China ²⁷	R	82	Male: 61/Female: 21	52 (min: 27/max: 77)	FOM, RT, gingiva, tongue	39	43	29/23	ND
Sproll – 2019, Germany ²⁸	R	259	Male: 178/Female: 83	62 (min: 32/max: 91)	FOM, alveolar process, tongue, cheek	35	224	5/105	2 Patients received NA-RT and 77 received A-RT; 9 patients received NA-CRT and 47 received A-CRT
Stoop -2020, The Netherlands ²⁹	R	210	Male: 127/Female: 83	67	Oral cavity	59	151	ND	ND
Total	NA	2.023	Male: 1,004/ Female: 525	59 (min: 21/max: 93)		857	1,166	118/366	ND

Abbreviations: NA, not apply; ND, not described; R, retrospective; A-RT, adjuvant radio therapy; NA-RT, neoadjuvant radio therapy.
*In the study published by Wald et al. 6 patients were excluded because of a mandibulectomy was not performed.

Table 2 Bias analysis performed with the quality assessment tool of the *National Institutes of Health* for each type of study

REFERENCE	STUDY TYPE	LIMITATIONS	#1	#2	#3	#4	#5	#6	#7	#8	#9	Quality rating (Good, fair, or poor)
Wald – 1983, USA ¹⁵	Retrospective case series	Heterogeneous and small sample No inference	Yes	Yes	CD	No	Yes	Yes	Yes	No	No	Poor
Barttelbort – 1987, USA ¹⁶	Retrospective case series	No inference	No	No	Yes	Yes	Yes	No	Yes	No	No	Poor
Soo – 1988, USA ¹⁷	Retrospective case series	–	Yes	Yes	Yes	Yes	Yes	Yes	Yes	Yes	Yes	Good
Totsuka – 1991, Japan. ¹⁸	Retrospective case series	Heterogeneous and small sample No inference	Yes	Yes	CD	No	Yes	Yes	Yes	No	Yes	Poor
Dubner – 1993, USA ¹⁹	Retrospective case series	Heterogeneous and small sample No inference	Yes	Yes	CD	No	Yes	Yes	Yes	No	Yes	Poor
Overholt – 1996, USA ²⁰	Retrospective case series	No inference	Yes	Yes	Yes	Yes	Yes	Yes	Yes	No	Yes	Fair
Ord – 1997, USA ²¹	Retrospective case series	No inference	Yes	Yes	Yes	Yes	Yes	Yes	Yes	No	Yes	Fair
Ash – 2000, Canada ²²	Retrospective case series	–	Yes	Yes	Yes	Yes	Yes	Yes	Yes	Yes	Yes	Good
Nie – 2000, China ²³	Retrospective case series	–	Yes	Yes	Yes	Yes	Yes	Yes	Yes	Yes	Yes	Good
Wearning – 2001, USA ²⁴	Retrospective case series	–	Yes	Yes	Yes	Yes	Yes	Yes	Yes	Yes	Yes	Good
Shaw – 2004, UK ²⁵	Retrospective Case Series	–	Yes	Yes	Yes	Yes	Yes	Yes	Yes	Yes	Yes	Good
Patel – 2008, Australia ²⁶	Retrospective case series	–	Yes	Yes	Yes	Yes	Yes	Yes	Yes	Yes	Yes	Good
Qiu – 2017, China ²⁷	Retrospective case series	–	Yes	Yes	Yes	Yes	Yes	Yes	Yes	Yes	Yes	Good
Sproll – 2019, Germany ²⁸	Retrospective case series	Heterogeneous and small sample	Yes	Yes	Yes	No	Yes	Yes	Yes	Yes	Yes	Fair
Stoop – 2020, The Netherlands ²⁹	Retrospective case series	–	Yes	Yes	Yes	Yes	Yes	Yes	Yes	Yes	Yes	Good

Abbreviations: CD, cannot determine; NA, not applicable; NR, not reported.

- #1. Was the study question or objective clearly stated?
- #2. Was the study population clearly and fully described, including a case definition?
- #3. Were the cases consecutive?
- #4. Were the subjects comparable?
- #5. Was the intervention clearly described?
- #6. Were the outcome measures clearly defined, valid, reliable, and implemented consistently across all study participants?
- #7. Was the length of follow-up adequate?
- #8. Were the statistical methods well described?
- #9. Were the results well described?

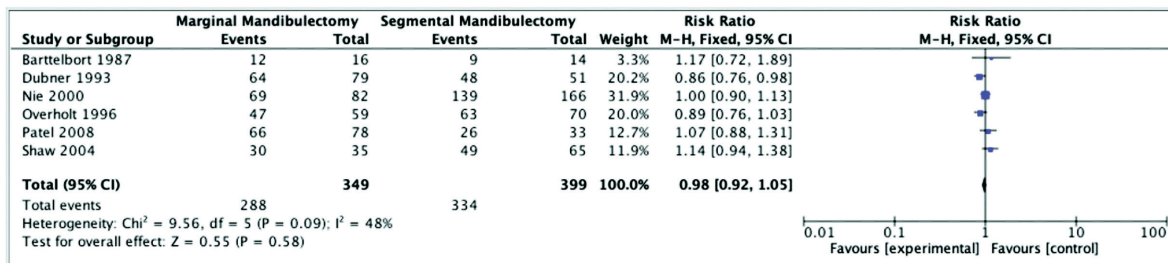


Fig. 2a. 5-years local control.

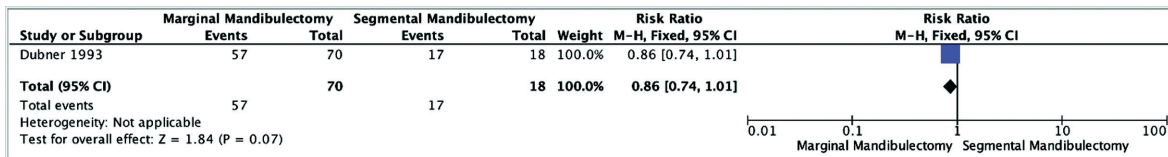


Fig. 2b. 5-years local control among patients without bone invasion.

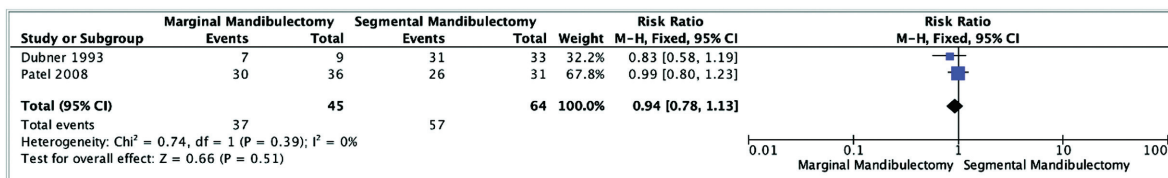


Fig. 2c. 5-years local control among patients with bone invasion.

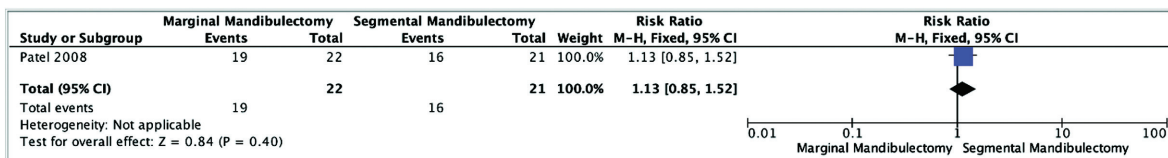


Fig. 2d. 5-years local control among patients with medullary invasion.

Fig. 2 Local Control Data. 2a. 5-years local control; 2b. 5-years local control among patients without bone invasion; 2c. 5-years local control among patients with bone invasion. 2d. 5-years local control among patients with medullary invasion.

could reduce the 5-year DFS by 14% compared with SM (RR= 0.88, 95% CI 0.50–1.53, $p = 0.64$) (► Fig. 4).²⁶ When we evaluated the effect of both types of mandibulectomy in those patients with cortical invasion, we didn't find differences between the techniques (HR = 1.59, 95% CI 0.73–3.45, $p = 0.79$). However, in those patients with mandibular medullary invasion, applying the Kaplan-Meier method, patients who underwent SM had an increased DFS of 73% compared with MM (HR= 0.27, 95% CI 0.08–0.93, $p = 0.04$) (► Fig. 4, ► Figure 3).²⁶

Four studies reported OS rates. The 5-year OS rate showed no significant difference between the patients who underwent MM and the patients who underwent SM (RR= 0.91, 95% CI 0.77–1.08, $p = 0.28$) (► Fig. 4).^{18,23,28} The OS rate was further evaluated with the Kaplan-Meier survival curve

analysis; Probably due to the limited data, no statistically significant difference was found between the two types of mandibulectomy, although the SM could increase the OS by 79% (HR = 0.21, 95% CI 0.01–3.97, $p = 0.30$) (► Fig. 3 and 5).¹⁸

Discussion

Despite the multiple options available for oral cancer treatment, surgery is still considered the treatment of choice. When the bone invasion is clear, bone resection is considered the standard of care. However, due to the significant functional and cosmetic implications when the tumor is adjacent to the jaw or the latter is potentially involved, the most important oncological decision is the management of the mandible looking to obtain free margins.

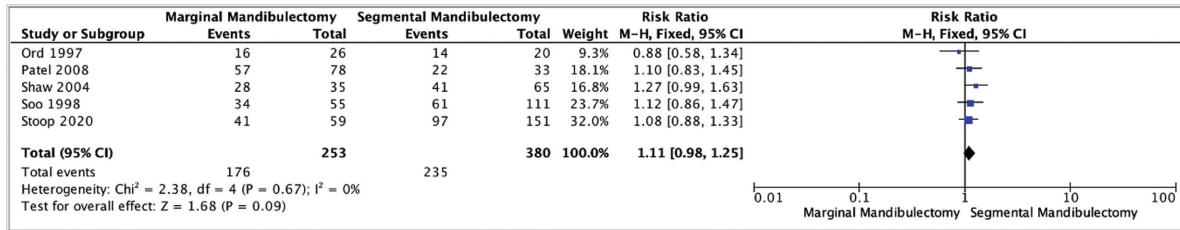


Fig. 3a. 5-years disease free survival.

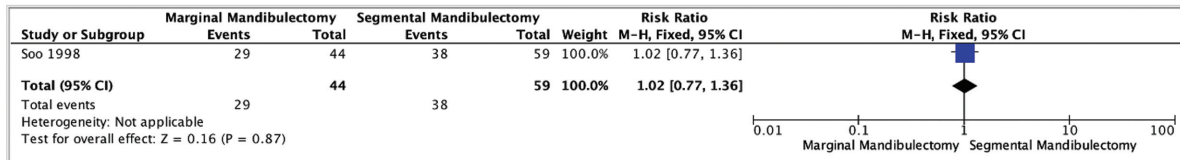


Fig. 3b. 5-years disease free survival among patients without bone invasion.

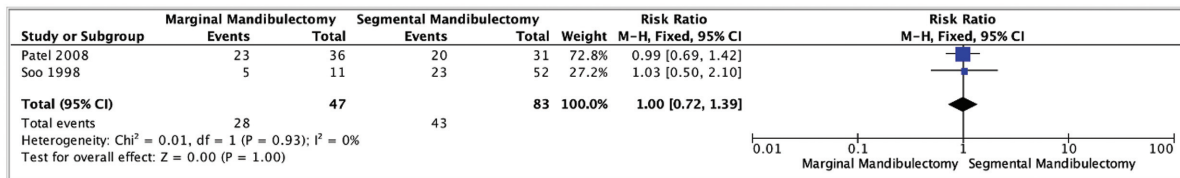


Fig. 3c. 5-years disease free survival among patients with bone invasion.

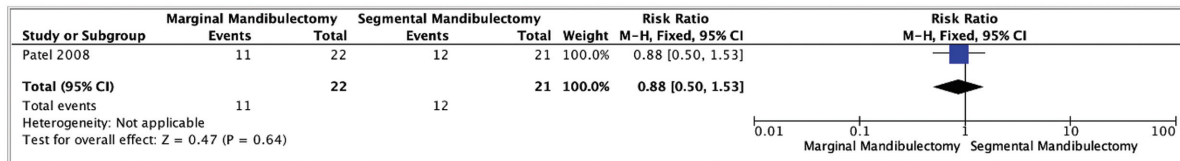


Fig. 3d. 5-years disease free survival among patients with medullary invasion.

Fig. 3 Disease Free Survival Data. 3a. 5-years disease free survival; 3b. 5-years disease free survival among patients without bone invasion; 3c. 5-years disease free survival among patients with bone invasion; 3d. 5-years disease free survival among patients with medullary invasion.

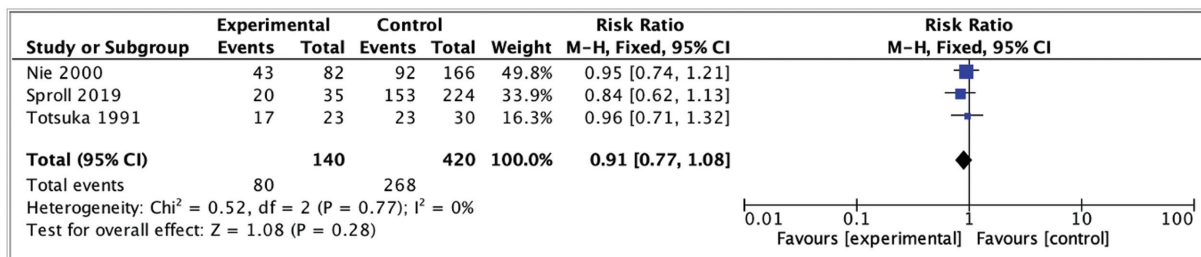


Fig. 4 5-years overall survival.

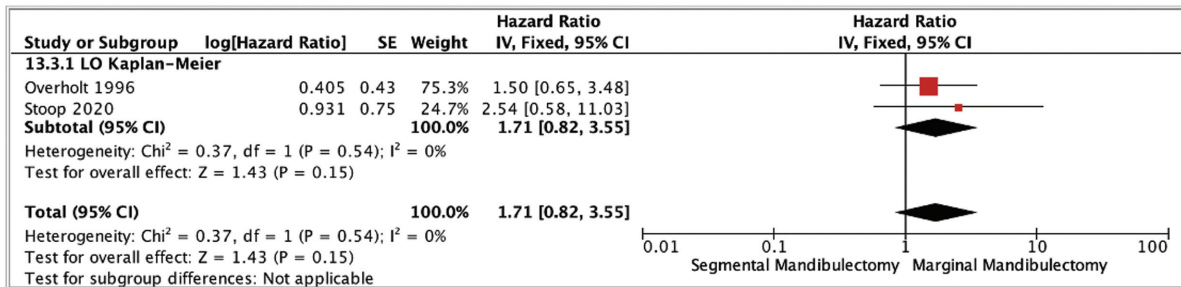


Figure 5a. 5-years local control.

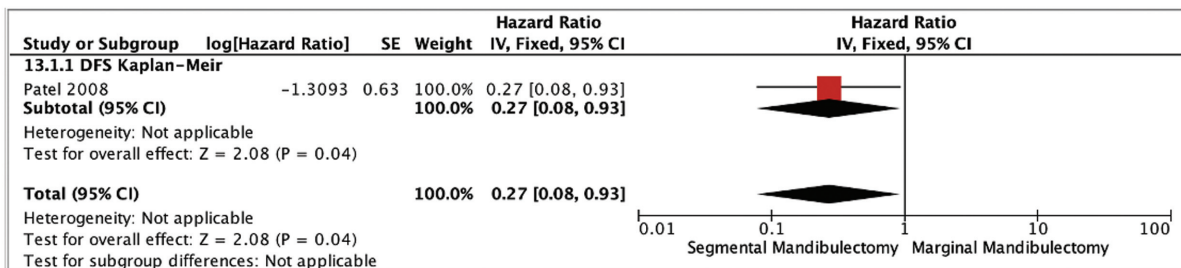


Figure 5b. 5-years DFS in patients with medullary invasion.

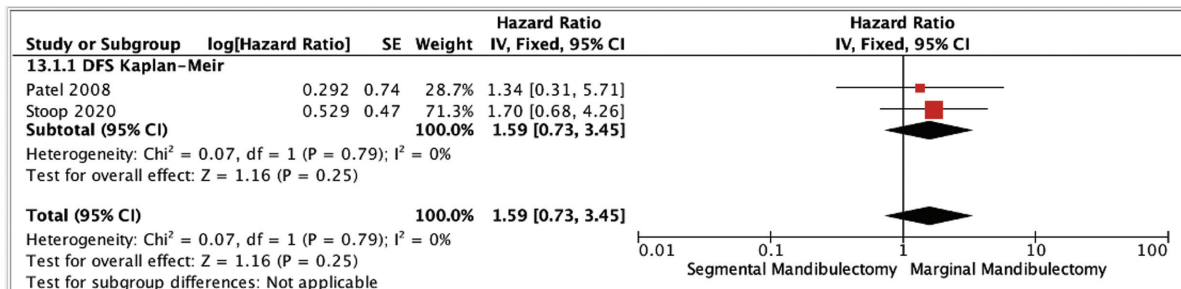


Figure 5c. 5-years DFS in patients with cortical bone invasion.

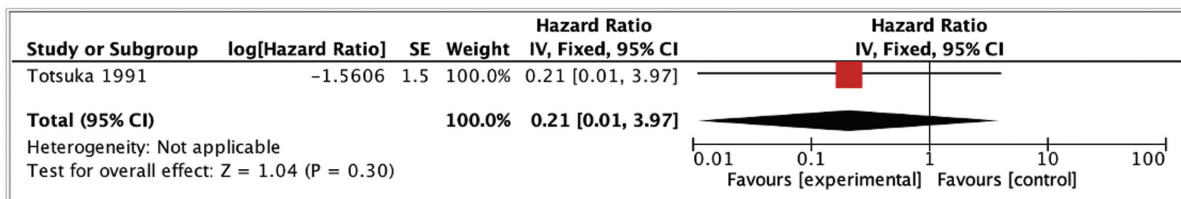


Figure 5d. 5-years OS in patients with medullary invasion.

Fig. 5 Time to event data analysis. 5a. 5-years local control; 5b. 5-years DFS in patients with medullary invasion; 5c. 5-years DFS in patients with cortical bone invasion, 5d. 5-years OS in patients with medullary invasion.

According to our results, and assuming the risk of bias related to the studies included and the lack of data related to the surgical decision-making, when free margins were obtained, no statistically significant difference in the 5-year LC rate was observed between both types of mandibulectomy or different degrees of infiltration. However, regarding the 5-year DFS, despite the limited amount of data, a tendency in

favor of SM was observed when bone invasion was not considered and confirmed when medullary invasion was evident. Regarding OS, when free margins were achieved, non-significant differences were observed between both techniques, irrespective of the type of mandibular involvement.

In a previous meta-analysis published by Gou et al.,³⁰ the authors concluded that, under the assumption that a safety

margin had been obtained, the type of mandibulectomy did not affect LC, DFS, or OS in patients with OCSCC. Subsequently, a MM may be considered in cases of superficial mandibular cortical invasion, while a SM may represent a more reasonable choice for patients with extensive mandibular cortical or medullary invasion.³⁰ However, this study combined data from OCSCC and oropharyngeal squamous cell carcinoma (OPSCC). A potentially increased rate of p16-positive OPSCC and a different biological behavior between OCSCC and OPSCC might limit the conclusions drawn from this meta-analysis.

When a MM is feasible and the lower border of the mandible is preserved, the functional result is probably better, and reconstruction is made easier. However, if a segmental resection is needed, a composite reconstruction using a free flap is usually required with an increased morbidity. Therefore, some surgeons hypothesized that the compact cortex of the mandibular bone may serve as a barrier or a defensive line to prevent cancer spread. Thus, a MM resection could be the treatment selected for oral cancer patients without mandibular medullary invasion to minimize the functional and aesthetic impact.³⁰⁻³²

According to Yue et al., the pattern of soft-tissue invasion has become a useful tool that further characterizes the biologic behavior of OCSCC.³³ The authors concluded that an aggressive histologic worst pattern of invasion in OCSCC tumors exhibited an infiltrative pattern of mandibular invasion too.³³ In the same vein, researchers have shown that, at the beginning, bone erosion occurs as a result of osteoclast cell activity at the frontline of tumor infiltration, probably related to the inflammation process and before bone invasion by tumor cells.³⁴ Moreover, according to Brown et al., the tumors enter the mandible at the point of abutment rather than the occlusal surface, neural foramina, or the periodontal membrane, as previously considered.³⁵⁻³⁷ However, it is accepted that once the inferior alveolar nerve canal is breached by advanced lesions, anterior and posterior perineural extension take place in both the edentulous and dentate mandible. Thus, a SM would be the appropriate option for these patients.

A careful preoperative (clinical and radiological) and intraoperative evaluation should be performed, before any surgical attempt in any OCSCC patients to propose the best surgical approach.^{35,36,38} In these patients, the sensitivity of computerized tomography (CT) scan compared with histology is 40 to 60%, with 89 to 100% specificity,^{7,39,40} while magnetic resonance imaging (MRI) shows 56 to 94% sensitivity and 73 to 100% specificity.^{41,42} Medullary edema is the most common cause of false positives described in the MRI group, which may be difficult to distinguish from tumoral infiltration.⁴³ However, in a recent study by Bouhir et al., the authors recommend the use of CT scan and MRI combined to improve preoperative mandibular invasion assessment in oral cavity and oropharyngeal cancer.⁴³

Some authors advocate that a MM may also be useful for patients with a clear cortical invasion, when a safety margin of at least 1 cm can be obtained in the lower contour of the remaining mandible.⁴⁴ According to our results, in cases in which the tumor is close to the alveolar crest, a MM may be

an appropriate choice, since no statistically significant difference was found regarding the 5-year LC rates between both surgical methods. However, a SM seems to be the most appropriate treatment for patients with medullary invasion even if our meta-analysis failed to show an improvement in OS.

Previous studies regarding OCSCC demonstrated that positive soft-tissue margins was the most relevant factor regarding LC and not the bone invasion pattern, type of resection,⁴⁵ or the depth of mandibular bone invasion.^{46,47} We did not find any difference in terms of the 5-year DFS between both techniques, a factor that can be related to the soft-tissue margins affected in the smaller cases treated with a MM and the advanced stage in patients treated with a SM. However, performing a SM increases the 5-year DFS by 73% compared with MM in patients with medullary invasion.

In the clinical decision-making process, other factors need to be considered to estimate the prognosis of OCSCC patients. The depth of infiltration or tumor thickness, pattern of spread, nerve invasion, and cervical lymph node status, are considered independent factors regarding OS, irrespective of the type of mandibulectomy performed.⁴⁸ Moreover, at least 50% of patients with OCSCC have positive lymph node metastases, which is considered the most important prognostic factor.⁴⁹ Moreover, in the 8th edition of the American Joint Committee on Cancer (AJCC) cancer staging manual, the incorporation of depth of invasion in the T staging as a prognostic factor supports the importance of the tumor growth pattern, as well as overall tumor dimension, as features critical to assessing tumor behavior and to determining the most optimal locoregional management.⁵⁰⁻⁵⁴

As highlighted recently by Manelli et al., intraoperative frozen section, spectroscopy, narrow band imaging, and optical coherence tomography are useful tools to evaluate soft-tissue margins during OCSCC surgery. However, in case of tumor bone involvement in advanced OCSCC, a frozen section evaluation of decalcified cortical bone is not practical and does not add any improvement to margins assessment accuracy.⁵⁵

In previously irradiated patients, bone resistance to tumor spread may be altered. In those patients, a SM would be indicated when the tumor abuts the mandible. Moreover, bone fracture or osteoradionecrosis could be more frequent if a MM is performed in the edentulous mandible or in irradiated patients.¹⁵

Finally, we need to highlight the limitations of this study such as the retrospective nature of all the studies available across the indexed literature and also the risk of bias related to the mandibulectomy technique selection, due to the lack of radiological data, description about cases included, and the lack of data about postoperative radiation or chemoradiation therapy among most studies included. There is also mixed data in most of the studies regarding T and N stages, and, finally, a limited number of patients that precludes proper subgroup analysis. These inconsistencies limited our ability to perform an analysis with unbiased objective results. Other factors that can contribute to the heterogeneity are the differences among mandibulectomy techniques among surgical teams.

As a future perspective, well-designed prospective randomized studies or also retrospective well-designed studies are required to understand the potential benefit over OS, DFS, and LC of both techniques in patients undergoing OCSCC resection. These studies should include surgeons with a homogeneous surgical technique, provide radiological data, include histological data regarding cortical and medullary bone invasion in surgical specimen, describing previous treatment received and at least 5-years of follow-up. Analyzing also factors like depth of infiltration according to the 8th edition of the AJCC, T and N staging, perineural invasion, etc.

Final Comments

The results obtained in this systematic review need to be considered with precaution, because they reveal the low-level evidence regarding the impact over LC or survival according to the type of mandibulectomy. Our results suggest that when free margins were obtained, no statistically significant difference was observed between both types of mandibulectomy or bone infiltration patterns, regarding the 5-year LC and OS. However, regarding 5-year DFS, a tendency in favor of SM was confirmed when medullary invasion was evident.

Conflict of Interests

The authors have no conflict of interests to declare.

References

- 1 Ferlay J, Colombet M, Soerjomataram I, et al. Estimating the global cancer incidence and mortality in 2018: GLOBOCAN sources and methods. *Int J Cancer* 2019;144(08):1941–1953
- 2 Siegel RL, Miller KD, Jemal A. Cancer statistics, 2016. *CA Cancer J Clin* 2016;66(01):7–30
- 3 Weatherspoon DJ, Chattopadhyay A, Boroumand S, Garcia I. Oral cavity and oropharyngeal cancer incidence trends and disparities in the United States: 2000–2010. *Cancer Epidemiol* 2015;39(04):497–504
- 4 Van Cann EM, Dom M, Koole R, Merckx MAW, Stoelinga PJW. Health related quality of life after mandibular resection for oral and oropharyngeal squamous cell carcinoma. *Oral Oncol* 2005;41(07):687–693
- 5 Van Cann EM, Oyen WJ, Koole R, Stoelinga PJ. Bone SPECT reduces the number of unnecessary mandibular resections in patients with squamous cell carcinoma. *Oral Oncol* 2006;42(04):409–414
- 6 Van Cann EM, Koole R, Oyen WJG, et al. Assessment of mandibular invasion of squamous cell carcinoma by various modes of imaging: constructing a diagnostic algorithm. *Int J Oral Maxillofac Surg* 2008;37(06):535–541
- 7 Hendrikx AWF, Maal T, Dieleman F, Van Cann EM, Merckx MAW. Cone-beam CT in the assessment of mandibular invasion by oral squamous cell carcinoma: results of the preliminary study. *Int J Oral Maxillofac Surg* 2010;39(05):436–439
- 8 Kansy K, Mueller AA, Mücke T, et al. A worldwide comparison of the management of surgical treatment of advanced oral cancer. *J Craniomaxillofac Surg* 2018;46(03):511–520
- 9 O'Brien CJ, Lee KK, Castle GK, Hughes CJ. Comprehensive treatment strategy for oral and oropharyngeal cancer. *Am J Surg* 1992;164(06):582–586
- 10 McGregor IA, MacDonald DG. Mandibular osteotomy in the surgical approach to the oral cavity. *Head Neck Surg* 1983;5(05):457–462
- 11 Systematic and literature review resources. 2011 <http://distillercer.com/resources>. Accessed January 2019.
- 12 Moher D, Liberati A, Tetzlaff J, Altman DGPRISMA Group. Preferred reporting items for systematic reviews and meta-analyses: the PRISMA statement. *PLoS Med* 2009;6(07):e1000097
- 13 Howick J, Chalmers I, Glasziou P, et al. The 2011 Oxford CEBM levels of evidence (introductory document). <http://www.cebm.net/index.aspx?o=5653>. Published 2011. Accessed May 12, 2019.
- 14 Study Quality Assessment Tools [Internet]. NHLBI, NIH Available from: <https://www.nlm.nih.gov/health-topics/study-quality-assessment-tools>.
- 15 Wald RM Jr, Calcaterra TC. Lower alveolar carcinoma. Segmental vs marginal resection. *Arch Otolaryngol* 1983;109(09):578–582
- 16 Barttelbort SW, Bahn SL, Ariyan SA. Rim mandibulectomy for cancer of the oral cavity. *Am J Surg* 1987;154(04):423–428
- 17 Soo KC, Spiro RH, King W, Harvey W, Strong EW. Squamous carcinoma of the gums. *Am J Surg* 1988;156(04):281–285
- 18 Totsuka Y, Usui Y, Tei K, et al. Results of surgical treatment for squamous carcinoma of the lower alveolus: segmental vs. marginal resection. *Head Neck* 1991;13(02):114–120
- 19 Dubner S, Heller KS. Local control of squamous cell carcinoma following marginal and segmental mandibulectomy. *Head Neck* 1993;15(01):29–32
- 20 Overholt SM, Eicher SA, Wolf P, Weber RS. Prognostic factors affecting outcome in lower gingival carcinoma. *Laryngoscope* 1996;106(11):1335–1339
- 21 Ord RA, Sarmadi M, Papadimitrou J. A comparison of segmental and marginal bony resection for oral squamous cell carcinoma involving the mandible. *J Oral Maxillofac Surg* 1997;55(05):470–477, discussion 477–478
- 22 Ash CS, Nason RW, Abdoh AA, Cohen MA. Prognostic implications of mandibular invasion in oral cancer. *Head Neck* 2000;22(08):794–798
- 23 Nie X, Wei F. Marginal resection for the mandible management of oral squamous cell carcinoma. *J Chin Oncol* 2000;6:156–157
- 24 Werning JW, Byers RM, Novas MA, Roberts D. Preoperative assessment for and outcomes of mandibular conservation surgery. *Head Neck* 2001;23(12):1024–1030
- 25 Shaw RJ, Brown JS, Woolgar JA, Lowe D, Rogers SN, Vaughan ED. The influence of the pattern of mandibular invasion on recurrence and survival in oral squamous cell carcinoma. *Head Neck* 2004;26(10):861–869
- 26 Patel RS, Dirven R, Clark JR, Swinson BD, Gao K, O'Brien CJ. The prognostic impact of extent of bone invasion and extent of bone resection in oral carcinoma. *Laryngoscope* 2008;118(05):780–785
- 27 Qiu Y, Lin L, Shi B, Zhu X. Does Different Mandibulectomy (Marginal vs Segmental) Affect the Prognosis in Patients With Oral Squamous Cell Carcinoma? *J Oral Maxillofac Surg* 2018;76(05):1117–1122
- 28 Sproll CK, Holtmann H, Schorn LK, et al. Mandible handling in the surgical treatment of oral squamous cell carcinoma: lessons from clinical results after marginal and segmental mandibulectomy. *Oral Surg Oral Med Oral Pathol Oral Radiol* 2020;129(06):556–564
- 29 Stoop CC, de Bree R, Rosenberg AJWP, van Gemert JTM, Forouzanfar T, Van Cann EM. Locoregional recurrence rate and disease-specific survival following marginal vs segmental resection for oral squamous cell carcinoma with mandibular bone invasion. *J Surg Oncol* 2020;122:646–652
- 30 Gou L, Yang W, Qiao X, et al. Marginal or segmental mandibulectomy: treatment modality selection for oral cancer: a systematic review and meta-analysis. *Int J Oral Maxillofac Surg* 2018;47(01):1–10. Doi: 10.1016/j.ijom.2017.07.019
- 31 Marchetta FC, Sako K, Murphy JB. The periosteum of the mandible and intraoral carcinoma. *Am J Surg* 1971;122(06):711–713

- 32 Carter RL, Tsao SW, Burman JF, Pittam MR, Clifford P, Shaw HJ. Patterns and mechanisms of bone invasion by squamous carcinomas of the head and neck. *Am J Surg* 1983;146(04):451–455
- 33 Yue LE, Sharif KF, Sims JR, et al. Oral squamous carcinoma: Aggressive tumor pattern of invasion predicts direct mandible invasion. *Head Neck* 2020;42(11):3171–3178. Doi: 10.1002/hed.26360
- 34 O'Brien CJ, Carter RL, Soo KC, Barr LC, Hamlyn PJ, Shaw HJ. Invasion of the mandible by squamous carcinomas of the oral cavity and oropharynx. *Head Neck Surg* 1986;8(04):247–256
- 35 Brown JS, Browne RM. Factors influencing the patterns of invasion of the mandible by oral squamous cell carcinoma. *Int J Oral Maxillofac Surg* 1995;24(06):417–426
- 36 Brown JS, Kalavrezos N, D'Souza J, Lowe D, Magennis P, Woolgar JA. Factors that influence the method of mandibular resection in the management of oral squamous cell carcinoma. *Br J Oral Maxillofac Surg* 2002;40(04):275–284
- 37 Brown JS, Lowe D, Kalavrezos N, D'Souza J, Magennis P, Woolgar J. Patterns of invasion and routes of tumor entry into the mandible by oral squamous cell carcinoma. *Head Neck* 2002;24(04):370–383
- 38 Brown JS, Griffith JF, Phelps PD, Browne RM. A comparison of different imaging modalities and direct inspection after periosteal stripping in predicting the invasion of the mandible by oral squamous cell carcinoma. *Br J Oral Maxillofac Surg* 1994;32(06):347–359
- 39 Gu DH, Yoon DY, Park CH, et al. CT, MR, (18)F-FDG PET/CT, and their combined use for the assessment of mandibular invasion by squamous cell carcinomas of the oral cavity. *Acta Radiol* 2010;51(10):1111–1119
- 40 van den Brekel MW, Runne RW, Smeele LE, Tiwari RM, Snow GB, Castelijns JA. Assessment of tumour invasion into the mandible: the value of different imaging techniques. *Eur Radiol* 1998;8(09):1552–1557
- 41 Uribe S, Rojas LA, Rosas CF. Accuracy of imaging methods for detection of bone tissue invasion in patients with oral squamous cell carcinoma. *Dentomaxillofac Radiol* 2013;42(06):20120346
- 42 Li C, Yang W, Men Y, Wu F, Pan J, Li L. Magnetic resonance imaging for diagnosis of mandibular involvement from head and neck cancers: a systematic review and meta-analysis. *PLoS One* 2014;9(11):e112267
- 43 Bouhir S, Mortuaire G, Dubrulle-Berthelot F, et al. Radiological assessment of mandibular invasion in squamous cell carcinoma of the oral cavity and oropharynx. *Eur Ann Otorhinolaryngol Head Neck Dis* 2019;136(05):361–366
- 44 Chen YL, Kuo SW, Fang KH, Hao SP. Prognostic impact of marginal mandibulectomy in the presence of superficial bone invasion and the nononcologic outcome. *Head Neck* 2011;33(05):708–713
- 45 O'Brien CJ, Adams JR, McNeil EB, et al. Influence of bone invasion and extent of mandibular resection on local control of cancers of the oral cavity and oropharynx. *Int J Oral Maxillofac Surg* 2003;32(05):492–497
- 46 De Vicente JC, Recio OR, Pendás SL, López-Arranz JS. Oral squamous cell carcinoma of the mandibular region: A survival study. *Head Neck* 2001;23(07):536–543
- 47 Spiro RH, Guillaumondegui O Jr, Paulino AF, Huvos AG. Pattern of invasion and margin assessment in patients with oral tongue cancer. *Head Neck* 1999;21(05):408–413
- 48 O'Brien CJ, Lauer CS, Fredricks S, et al. Tumor thickness influences prognosis of T1 and T2 oral cavity cancer—but what thickness? *Head Neck* 2003;25(11):937–945
- 49 Kowalski LP, Sanabria A. Elective neck dissection in oral carcinoma: a critical review of the evidence. *Acta Otorhinolaryngol Ital* 2007;27(03):113–117
- 50 Brockhoff HC II, Kim RY, Braun TM, Skouteris C, Helman JI, Ward BB. Correlating the depth of invasion at specific anatomic locations with the risk for regional metastatic disease to lymph nodes in the neck for oral squamous cell carcinoma. *Head Neck* 2017;39(05):974–979
- 51 Fukano H, Matsuura H, Hasegawa Y, Nakamura S. Depth of invasion as a predictive factor for cervical lymph node metastasis in tongue carcinoma. *Head Neck* 1997;19(03):205–210
- 52 Kane SV, Gupta M, Kakade AC, D' Cruz A. Depth of invasion is the most significant histological predictor of subclinical cervical lymph node metastasis in early squamous carcinomas of the oral cavity. *Eur J Surg Oncol* 2006;32(07):795–803
- 53 Melchers LJ, Schuurin E, van Dijk BA, et al. Tumour infiltration depth ≥ 4 mm is an indication for an elective neck dissection in pT1cN0 oral squamous cell carcinoma. *Oral Oncol* 2012;48(04):337–342
- 54 Tan WJ, Chia CS, Tan HK, Soo KC, Iyer NG. Prognostic significance of invasion depth in oral tongue squamous cell carcinoma. *ORL J Otorhinolaryngol Relat Spec* 2012;74(05):264–270
- 55 Mannelli G, Comini LV, Piazza C. Surgical margins in oral squamous cell cancer: intraoperative evaluation and prognostic impact. *Curr Opin Otolaryngol Head Neck Surg* 2019;27(02):98–103