

Orbital/ocular inflammatory involvement in VEXAS syndrome: Data from the international AIDA network VEXAS registry

Antonio Vitale^{a,b}, Valeria Caggiano^{a,b}, Eduardo Martin-Nares^c, Micol Frassi^d, Lorenzo Dagna^{e,f}, Pravin Hissaria^{g,h}, Paolo Sfrisoⁱ, José Hernández-Rodríguez^j, Guillermo Ruiz-Irastorza^{k,ao}, Sara Monti^{l,m}, Abdurrahman Tufanⁿ, Matteo Piga^o, Henrique A Mayrink Giardini^p, Giuseppe Lopalco^q, Ombretta Viapiana^r, Amato De Paulis^{s,t}, Paola Triggianese^{u,v}, Rosetta Vitetta^w, Alejandra de-la-Torre^x, Alex Fonollosa^y, Federico Caroni^{z,b}, Jurgen Sota^{a,b}, Edoardo Conticini^{a,b}, Jessica Sbalchiero^{a,b}, Alessandra Renieri^{aa,ab,ac,b}, Giulia Casamassima^{aa,ab,ac,b}, Ewa Wiesik-Szewczyk^{ad}, Derya Yildirimⁿ, Andrea Hinojosa-Azaola^c, Francesca Crisafulli^d, Franco Franceschini^d, Corrado Campochiaro^{e,f}, Alessandro Tomelleri^{e,f}, Alicia Callisto^g, Mark Beecher^g, Sara Bindoliⁱ, Chiara Baggioⁱ, Verónica Gómez-Caverzaschi^j, Laura Pelegrín^{ae}, Adriana Soto-Peleteiro^{k,ao}, Alessandra Milanese^{l,m}, Ibrahim Vasiⁿ, Alberto Cauli^o, Isabele Parente de Brito Antonelli^p, Florenzo Iannone^q, Riccardo Bixio^r, Francesca Della Casa^s, Ilaria Mormile^s, Carmelo Gurnari^{af,ag}, Alessia Fiorenza^w, Germán Mejia-Salgado^x, Perla Ayumi Kawakami-Campos^{ah}, Gaafar Ragab^{ai,aj}, Francesco Ciccia^{ak}, Piero Ruscitti^{al}, Monica Bocchia^{z,b}, Alberto Balistreri^{am,b}, Gian Marco Tosi^{an,b}, Bruno Frediani^{a,b}, Luca Cantarini^{a,b,*}, Claudia Fabiani^{am,b,*}

^a Department of Medical Sciences, Surgery and Neurosciences, Research Center of Systemic Autoinflammatory Diseases and Behçet's Disease Clinic, University of Siena, Siena, Italy

^b Rheumatology Unit, Policlinico "Le Scotte", Azienda Ospedaliero-Universitaria Senese [European Reference Network (ERN) for Rare Immunodeficiency, Autoinflammatory and Autoimmune Diseases (RITA) Center] Siena, viale Bracci 16, Siena 53100, Italy

^c Department of Immunology and Rheumatology, Instituto Nacional de Ciencias Médicas y Nutrición Salvador Zubirán, Mexico City, Mexico

^d Rheumatology and Clinical Immunology, Spedali Civili and Department of Clinical and Experimental Sciences, University of Brescia, [European Reference Network (ERN) for Rare Immunodeficiency, Autoinflammatory and Autoimmune Diseases (RITA) Center], Brescia, Italy

^e Division of Immunology, Transplants and Infectious Diseases, Università Vita-Salute San Raffaele, Milan, Italy

^f Unit of Immunology, Rheumatology, Allergy and Rare Diseases, IRCCS Ospedale San Raffaele, [European Reference Network (ERN) for Rare Immunodeficiency, Autoinflammatory and Autoimmune Diseases (RITA) Center], Milan, Italy

^g Department of Clinical Immunology and Allergy, Royal Adelaide Hospital, Adelaide, Australia

^h Department of Immunopathology, SA Pathology, Adelaide, Australia

ⁱ Rheumatology Unit, Department of Medicine, University of Padua, [European Reference Network (ERN) for Rare Immunodeficiency, Autoinflammatory and Autoimmune Diseases (RITA) Center], Padua, Italy

^j Clinical Unit of Autoinflammatory Diseases, Department of Autoimmune Diseases, Institut d'Investigacions Biomèdiques August Pi I Sunyer (IDIBAPS), Hospital Clínic de Barcelona [European Reference Network (ERN) for Rare Immunodeficiency, Autoinflammatory and Autoimmune Diseases (RITA) Center], University of Barcelona, Barcelona, Spain

^k Faculty of Medicine and Nursery, University of the Basque Country, UPV/EHU, Leioa, Biscay, Spain

^l Division of Rheumatology, Fondazione IRCCS Policlinico San Matteo, [European Reference Network (ERN) for Rare Immunodeficiency, Autoinflammatory and Autoimmune Diseases (RITA) Center], Pavia, Italy

^m Department of Internal Medicine and Therapeutics, Università di Pavia, Italy

ⁿ Department of Internal Medicine, Division of Rheumatology, Gazi University Hospital, Ankara, Türkiye

^o Rheumatology Unit, Department of Medical Sciences, University and AOU of Cagliari, Cagliari, Italy

From the International AIDA (AutoInflammatory Diseases Alliance) Network and from the Autoinflammatory Diseases Working Group of the Italian Society of Rheumatology (SIR).

* Corresponding author at: Rheumatology Unit, Policlinico "Le Scotte", Azienda Ospedaliero-Universitaria Senese [European Reference Network (ERN) for Rare Immunodeficiency, Autoinflammatory and Autoimmune Diseases (RITA) Center] Siena, viale Bracci 16, Siena 53100, Italy.

E-mail addresses: cantariniluca@hotmail.com (L. Cantarini), claudia.fabiani@aidanetwork.org (C. Fabiani).

<https://doi.org/10.1016/j.semarthrit.2024.152430>

Available online 18 March 2024

0049-0172/© 2024 The Authors. Published by Elsevier Inc. This is an open access article under the CC BY license (<http://creativecommons.org/licenses/by/4.0/>).

- ^p Rheumatology Division, Faculdade de Medicina, Hospital das Clínicas, Universidade de São Paulo, São Paulo, Brazil
- ^q Department of Precision and Regenerative Medicine and Ionian Area (DiMePre-J) Policlinic Hospital, University of Bari, Bari, Italy
- ^r Rheumatology Unit, Department of Medicine, University and Azienda Ospedaliera Universitaria Integrata of Verona, Italy
- ^s Department of Translational Medical Sciences, Section of Clinical Immunology, University of Naples Federico II, Naples, Italy
- ^t Center for Basic and Clinical Immunology Research (CISI), WAO Center of Excellence, University of Naples Federico II, Naples, Italy
- ^u Rheumatology, Allergy and Clinical Immunology, Department of Systems Medicine, University of Rome Tor Vergata, Rome, Italy
- ^v Molecular Medicine and Applied Biotechnology, University of Rome Tor Vergata, Rome, Italy
- ^w Unit of Rheumatology, ASL VC Sant' Andrea Hospital, Vercelli 13100, Italy
- ^x Neuroscience Research Group (NEUROS), NeuroVitae Center, Escuela de Medicina y Ciencias de la Salud, Universidad del Rosario, Bogotá, Colombia
- ^y Department of Ophthalmology, Biocruces Bizkaia Health Research Institute, Cruces University Hospital, University of the Basque Country, Barakaldo, Spain
- ^z Hematology Unit, Azienda Ospedaliera Universitaria Senese, University of Siena, Siena 53100, Italy
- ^{aa} Medical Genetics, Department of Medical Biotechnologies, University of Siena, Siena, Italy
- ^{ab} Department of Medical Biotechnologies, Med Biotech Hub and Competence Center, University of Siena, Siena, Italy
- ^{ac} Genetica Medica, Azienda Ospedaliero-Universitaria Senese, Siena, Italy
- ^{ad} Department of Internal Medicine, Pneumology, Allergy and Clinical Immunology, Central Clinical Hospital of the Ministry of National Defense, Military Institute of Medicine, National Research Institute, Warsaw, Poland
- ^{ae} Department of Ophthalmology, Institut Clínic d'Ofthalmologia (ICOF), Hospital Clinic de Barcelona, University of Barcelona, Institut de Investigacions Biomediques August Pi i Sunyer (IDIBAPS), Barcelona, Spain
- ^{af} Department of Biomedicine and Prevention, University of Rome Tor Vergata, Rome, Italy
- ^{ag} Department of Translational Hematology and Oncology Research, Taussig Cancer Institute, Cleveland Clinic, Cleveland, OH, USA
- ^{ah} Department of Ophthalmology, Instituto Nacional de Ciencias Médicas y Nutrición Salvador Zubirán, Mexico City, Mexico
- ^{ai} Internal Medicine Department, Rheumatology and Clinical Immunology Unit, Faculty of Medicine, Cairo University, Giza, Egypt
- ^{aj} Faculty of Medicine, Newgiza University, 6th of October City, Egypt
- ^{ak} Department of Precision Medicine, University of Campania "Luigi Vanvitelli", Naples, Italy
- ^{al} Rheumatology Unit, Department of Biotechnological and Applied Clinical Sciences, University of L'Aquila, L'Aquila, Italy
- ^{am} Bioengineering and Biomedical Data Science Lab, Department of Medical Biotechnologies, University of Siena, Siena, Italy
- ^{an} Ophthalmology Unit, Department of Medicine, Surgery and Neurosciences, University of Siena, Siena, Italy
- ^{ao} Autoimmune Diseases Unit, Biocruces Bizkaia Health Research Institute, Barakaldo, Biscay, Spain

ARTICLE INFO

Keywords:

Autoinflammatory diseases
 Myelodysplastic syndrome
 Relapsing polychondritis
 Scleritis
 Uveitis
 AIDA network VEXAS registry

ABSTRACT

VEXAS syndrome is a recently described monogenic autoinflammatory disease capable of manifesting itself with a wide array of organs and tissues involvement. Orbital/ocular inflammatory manifestations are frequently described in VEXAS patients. The objective of this study is to further describe orbital/ocular conditions in VEXAS syndrome while investigating potential associations with other disease manifestations. In the present study, twenty-seven out of 59 (45.8 %) VEXAS patients showed an inflammatory orbital/ocular involvement during their clinical history. The most frequent orbital/ocular affections were represented by periorbital edema in 8 (13.6 %) cases, episcleritis in 5 (8.5 %) patients, scleritis in 5 (8.5 %) cases, uveitis in 4 (6.8 %) cases, conjunctivitis in 4 (6.8 %) cases, blepharitis in 3 (5.1 %) cases, orbital myositis in 2 (3.4 %) cases. A diagnosis of systemic immune-mediated disease was observed in 15 (55.6 %) cases, with relapsing polychondritis diagnosed in 12 patients. A significant association was observed between relapsing polychondritis and orbital/ocular involvement in VEXAS syndrome (Relative Risk: 2.37, 95 % C.I. 1.03–5.46, $p = 0.048$). Six deaths were observed in the whole cohort of patients after a median disease duration of 1.2 (IQR=5.35) years, 5 (83.3 %) of which showed orbital/ocular inflammatory involvement. In conclusion, this study confirms that orbital/ocular inflammatory involvement is a common finding in VEXAS patients, especially when relapsing polychondritis is diagnosed. This makes ophthalmologists a key figure in the diagnostic process of VEXAS syndrome. The high frequency of deaths observed in this study seems to suggest that patients with orbital/ocular involvement may require increased attention and more careful follow-up.

Introduction

VEXAS (Vacuoles, E1 enzyme, X-linked, Autoinflammatory, Somatic) syndrome is a new autoinflammatory condition caused by acquired *UBA1* gene mutations affecting bone marrow cell precursors. It represents a monogenic autoinflammatory disease involving selectively adults with a marked male predominance due to the X-chromosome localization of *UBA1* gene [1].

The disease is clinically characterized by a prominent systemic inflammation with frequent identification of hematological disorders, especially myelodysplastic syndrome and monoclonal gammopathy of unknown significance [2]. Although much is still to be studied about this recently discovered disease, it is well known that systemic inflammation may manifest with a wide range of organs involvement, where skin, lungs, joints, cartilage, and vessels are particularly involved [3]. In this context, the eye seems to be highly involved in VEXAS syndrome, accounting for one of the most targeted organs by inflammation. Therefore, this study was conducted to better characterize orbital/ocular involvement in VEXAS syndrome, describing the whole plethora of manifestations that occurred in a relatively large group of VEXAS

patients and looking for associations with other disease features.

Material and methods

This study is based on the AutoInflammatory Disease Alliance (AIDA) international cohort of VEXAS patients; an on-line data collection was conducted through both retrospective and prospective methods using the Research Electronic Data Capture (REDCap) instrument, as previously described [4,5]. Patients developing orbital inflammatory involvement were selected and later compared to patients without ocular or orbital inflammatory affections. The follow-up period ranged between the first symptoms occurrence of VEXAS syndrome and the last assessment; the enrollment period in the AIDA Registry ranged between November 2022 and October 2023. The patient's clinical data were updated as of the time of statistical analysis in October 2023.

The aim of the study was to describe ocular and orbital inflammation in VEXAS syndrome, thus looking for any association with other VEXAS-related manifestations.

Orbital inflammatory involvement was meant as the abrupt occurrence of ocular inflammatory affections and inflammation of intraorbital

tissues starting from the onset of other VEXAS-related manifestations (disease onset) until the last follow-up assessment. Periorbital edema is defined as swelling in the tissues around the eye due to inflammation of intraorbital structures, with at least one episode responsive to glucocorticoid administration. Regarding laboratory assessment, anemia was defined as Hb \leq 12 g/dl; platelets count \leq 150,000/mm³ was defined thrombocytopenia; leukocyte count $<$ 4000/mm³ was defined leukopenia, while leukocyte count $>$ 10,000/mm³ was classified as leukocytosis. Erythrocyte sedimentation rate (ESR), C reactive protein (CRP), and mean corpuscular value (MCV) were considered increased in accordance with each laboratory reference limit. Dacryoadenitis, orbital myositis, and orbital cellulitis were assessed with orbital ultrasound and magnetic resonance imaging; xerophthalmia was ascertain at Schirmer test and break-up time. Orbital involvement was distinguished between patients with potentially sight threatening conditions (scleritis, uveitis, orbital cellulitis, diplopia) and patients with less severe manifestations (episcleritis, conjunctivitis, blepharitis, dacryoadenitis, xerophthalmia).

Infectious, autoimmune, neoplastic diseases and ocular-specific conditions capable to explaining the eye involvement were ruled out with adequate, clinically oriented laboratory and instrumental examinations. All patients, even those without any eye-related symptoms, were examined by an experienced ophthalmologist.

Inclusion criteria consisted of the identification of a pathogenic or likely pathogenic mutation in the *UBA1* gene. Pathogenicity of *UBA1* variants was derived from Infervers, an online database for auto-inflammatory mutations. Copyright. Available at <https://infervers.umai-montpellier.fr/> [6–9]. Patients enrolled provided their signed informed consent for the use of clinical, laboratory, and genetic data in the context of the AIDA network [4]. The AIDA Network project was approved by the Ethics Committee of the Azienda Ospedaliero-Universitaria Senese, Siena, Italy in June 2019, with later updates including the development of the international AIDA registry dedicated to VEXAS syndrome (Ref. N. 14951).

Statistical analysis included descriptive statistics including sample sizes, percentages, frequency counts, mean, median, standard deviations and interquartile range calculations. Pairwise comparisons for quantitative data were performed by using the Student-*t* test or the Mann-Whitney U test according to data distribution assessed with the Shapiro-Wilk test. Pairwise comparisons for qualitative data were performed using the χ^2 test or the Fisher exact test according to frequency counts and expected frequencies. The risk ratio, the corresponding 95 % confidence intervals (95 % C.I.) and the *p*-value obtained through the Mantel-Haenszel χ^2 test were calculated with the Episheet software [10]. All statistical computations were two-tailed statistical analyses, with a type I error set at 0.05 ($p < 0.05$), using RStudio software version 4.3.0.

Results

A total of 59 patients were enrolled in study; all but one patient (1.7 %) was female. Patients derived from Brazil ($n = 1$), Spain ($n = 8$), Italy ($n = 37$), Turkey ($n = 2$), Mexico ($n = 6$) and Australia ($n = 5$). The mean age of disease onset was 66.3 ± 11.9 years and the mean age at diagnosis of VEXAS syndrome was 70.2 ± 11.5 years. The majority of patients were Caucasian ($n = 47$, 80 %), while 9 patients (15 %) were Hispanic; the ethnic origin was unknown in 3 patients (5 %).

Twenty-seven out of 59 (45.8 %) VEXAS patients showed an inflammatory orbital/ocular involvement during their clinical history; 25/27 (92.6 %) patients presented an orbital/ocular involvement as early as the disease onset.

Orbital/ocular involvement was represented by: periorbital edema in 8 (13.6 %) cases (11 eyes), episcleritis in 5 (8.5 %) patients (9 eyes), scleritis in 5 (8.5 %) cases (6 eyes), uveitis in 4 (6.8 %) cases (4 eyes), conjunctivitis in 4 (6.8 %) cases, blepharitis in 3 (5.1 %) cases, orbital myositis in 2 (3.4 %) cases, orbital cellulitis in 2 cases (3.4 %). In addition, dacryoadenitis, diplopia, and xerophthalmia with

photophobia were each observed in 1 (1.7 %) patient. Patients with periorbital edema also suffered from the following orbital affections: episcleritis in 2 cases, orbital cellulitis in 2 cases, and scleritis, uveitis, orbital myositis, and dacryoadenitis, each in one case. In total, 14 patients suffered from potentially sight threatening conditions and 13 from less severe orbital conditions. In 8 (29.6 %) patients multiple orbital/ocular involvement was recorded, with no trend towards an association between specific ocular or orbital affection. Fig. 1 represents a case of orbital myositis in a VEXAS patient assessed by computed tomography (CT).

Genetic testing comprised the Sanger test in 15 (25.4 %) patients and next-generation sequencing in 44 (74.6 %) patients, based on peripheral blood in 17 (28.8 %) patients and bone marrow in 42 (71.2 %) patients. The following genetic variants were identified among patients with eye involvement: p.Met41Thr in 12 (44.4 %) cases, p.Met41Val in 7 (25.9 %) cases, p.Met41Leu in 5 (18.5 %) cases, the p.Gly477Ala (likely pathogenic) mutation in 1 (3.7 %) case, the p.Gly40_Lys43del (pathogenic) mutation in 1 (3.7 %) case, and the p.(Ser56Phe) (likely pathogenic) mutation in 1 (3.7 %) case. Mutations observed among patients with no orbital inflammation were: p.Met41Thr in 13 (40.6 %) cases, p.Met41Val in 9 (28.1 %) cases, p.Met41Leu in 4 (12.5 %) cases, the p.Gly477Ala (likely pathogenic) mutation in 2 cases (6.3 %), the c.118-2A>G mutation (pathogenic, Human Genome Variation Society not available) in 2 (6.3 %) cases, p.Gly40_Lys43del mutation in 2 (6.3 %) cases. No statistically significant differences were observed between patients with and without orbital/ocular involvement in the frequency of the p.Met41Thr mutation ($p = 0.797$), the p.Met41Val mutation ($p = 1.00$), the p.Met41Leu mutation ($p = 0.718$), and of the other rare mutations taken as a whole ($p = 0.19$). Table 1 summarizes clinical data of patients with and without orbital/ocular manifestations; Table 2 describes laboratory data from patients with and without orbital/ocular affections.

Fifteen of the patients (55.6 %) with orbital/ocular involvement had a diagnosis of systemic disease as follows: relapsing polychondritis in 12 patients, two of which also suffered from Sweet syndrome; spondyloarthritis in 2 cases; polyarteritis nodosa in one case. The frequency of systemic disorders in VEXAS patients without orbital/ocular involvement was 12/32 (37.5 %), with no statistically significant differences compared to patients with orbital/ocular involvement ($p = 0.26$). No statistically significant differences were observed comparing patients with no orbital/ocular involvement, patients with potentially sight threatening manifestations and patients with less severe orbital/ocular involvement (7/14 cases and 8/13 cases, respectively, $p = 0.83$).

Relapsing polychondritis was observed in 12/27 (44.4 %) patients with orbital involvement and in 6/32 (18.8 %) patients without orbital involvement (Relative Risk: 2.37, 95 % C.I. 1.03–5.46, $p = 0.048$). In particular, relapsing polychondritis coexisted with the specific orbital/ocular manifestations reported in Fig. 2. All patients with episcleritis and 3 out of 4 patients with uveitis also suffered from relapsing polychondritis. All cases of episcleritis also suffered from relapsing polychondritis.

Comorbidities reported among patients with orbital/ocular involvement included essential systemic hypertension ($n = 8$); type 2 diabetes mellitus ($n = 8$), dyslipidemia ($n = 3$), atrial fibrillation ($n = 2$), stroke ($n = 2$), hyperplasia of prostate ($n = 2$), osteoporosis ($n = 2$). Each of the following comorbidities was found in one patient: cardiomegaly, gynecomastia, uncomplicated cholelithiasis, diffuse idiopathic skeletal hyperostosis, autoimmune pancreatitis, ischemic heart disease, aortic (valve) stenosis, carcinoma *in situ* of prostate, diverticulosis, ulcerative colitis, Grave's disease, and Hashimoto thyroiditis.

Bone marrow evaluation and search for vacuoles in hematological precursors were performed in all but 4 patients (two with orbital/ocular involvement and two without orbital/ocular involvement). Hematological disorders were observed in 10 patients with orbital/ocular involvement and 15 patients without orbital/ocular involvement ($p = 0.62$). Among patients with orbital/ocular inflammatory affections, the

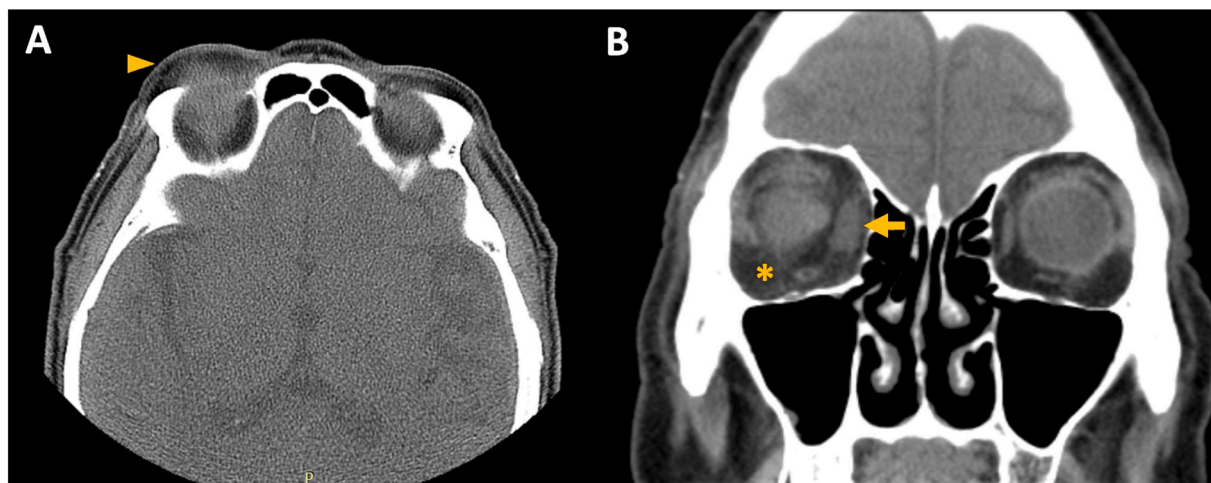


Fig. 1. Shows an orbital computed tomography (CT) in the axial (A) and coronal (B) planes showing palpebral/periorbital edema (arrowhead), intraconal fat stranding (orbital cellulitis) (asterisk) and medial rectus enlargement (orbital myositis) (arrow) in the right eye of a 77-year-old male patient with VEXAS syndrome.

Table 1
Clinical and laboratory VEXAS-related manifestations among patients with and without orbital/ocular involvement. Abbreviations: SD, standard deviation.

	Orbital/ocular involvement (n = 27)	No orbital/ocular involvement (n = 32)	p-value
Age disease onset, years (mean±SD)	65.19±11.75	65.44 ± 10.56	0.72
Age at diagnosis, years (mean±SD)	67.16±13.59	69.7 ± 8.37	0.47
Skin manifestations, n (%)	22 (81.5)	22 (68.8)	0.41
Fever episodes	20 (74)	23 (71.9)	0.85
Arthralgia	21 (70.4)	19 (65.6)	0.91
Arthritis	9 (33.3)	8 (25)	0.68
Myositis	1 (3.7)	0 (0)	1.00
Gut involvement	3 (11.1)	3 (9.4)	1.00
Abdominal pain	2 (7.4)	5 (15.6)	0.44
Splenomegaly	6 (22.2)	6 (18.8)	1.00
Lymphadenopathy	8 (29.6)	4 (12.5)	0.19
Hepatomegaly	1 (3.7)	0 (0)	1.00
Neurological involvement	4 (14.8)	4 (12.5)	1.00
Vessel involvement	13 (48.1)	10 (31.3)	0.29
Cardiac involvement	5 (18.5)	3 (9.4)	0.45
Thoracic pain	6 (22.2)	5 (15.6)	0.75
Pleuritis	2 (7.4)	5 (15.6)	0.44
Pericarditis	1 (3.7)	0 (0)	1.00
Lung involvement	9 (33.3)	4 (12.5)	0.11
Kidney involvement	2 (7.4)	1 (3.1)	0.59
Orchitis	4 (14.8)	3 (9.4)	0.69
Epididymitis	2 (7.4)	4 (12.5)	0.68

hematological disorders accounted for myelodysplastic syndrome in all cases.

Six deaths were observed in the whole cohort of patients after a median disease duration of 1.2 (IQR=5.35) years, 5 (83.3 %) of which showed orbital/ocular inflammatory involvement, as follows: scleritis in 2 cases, at the age of 59.5 years and 75 years, respectively; orbital myositis and cellulitis in the third case, at the age of 80.4 years; episcleritis and diplopia in the fourth case at the age of 72.8 years; and episcleritis in the fifth case at the age of 87.5 years. The causes of death were intestinal perforation in one case (related to VEXAS syndrome) at the age of 87.5 years, acute respiratory failure in 2 cases (both related to VEXAS syndrome), infectious complications in one case at the age of 59.5 years; the reason was not reported in 2 cases. No statistically significant difference was observed in the frequency of death according to

Table 2
Major laboratory features in VEXAS patients according to the occurrence of orbital/ocular inflammatory manifestations. Vacuole presence in hematological precursors was not investigated in four patients, two with orbital inflammatory involvement and two without. Abbreviations: IQ, interquartile range; SD, standard deviation.

Laboratory manifestations	Orbital/ocular involvement (n = 27)	No orbital/ocular involvement (n = 32)	p-value
ESR mm/h mean±SD	99.7 ± 36.3	80.7 ± 40.6	0.16
CRP mg/dL median (IQ)	62.17 (37.8)	22.6 (12.5)	0.21
Anemia, n (%)	24 (88.9)	25 (78.1)	0.49
MCV fl mean±SD	104.1 ± 11	103.6 ± 12.3	0.91
Leukocytosis, n (%)	1 (3.7)	2 (6.3)	1.00
Leukopenia, n (%)	12 (44.4)	15 (46.9)	1.00
Thrombocytopenia, n (%)	13 (48.1)	27 (84.4)	0.005
Paraproteinemia, n (%)	3 (11.1)	4 (12.5)	1.00
Vacuoles in myeloid/erythroid precursors, n (%)	13/25 (52)	6/30 (20)	0.028

the presence or absence of orbital/ocular involvement (p = 0.08); 3 out of 5 deaths occurred in patients with orbital/ocular involvement and concomitant relapsing polychondritis.

Discussion

Ocular symptoms account for one of the most frequent manifestations of VEXAS syndrome [11]. Geogin-Lavialle and colleagues described ocular symptoms in about 40 % of VEXAS patients, with uveitis, scleritis, episcleritis, and periorbital oedema, involving 9.5 %, 8.6 %, 12.1 % and 8.6 % of cases, respectively. The percentage of ocular inflammation was reported in 64 % of 25 VEXAS cases. Also in this case, inflammatory ocular involvement included conjunctivitis, episcleritis, scleritis, uveitis and orbital inflammation [12]. However, the list of possible VEXAS ocular manifestations is expanding along with the identification of new cases and the better definition of the disease. In fact, superior orbital fissure syndrome, dacryoadenitis, retinal vasculitis, and orbital myositis have also been included in the plethora of possible ocular involvement [13]. Ocular inflammation may also represent the clinical clue leading to the suspicion and diagnosis of VEXAS syndrome, rendering ophthalmologists a central figure in the recognition of this new clinical entity [14,15].

The present study confirms that a remarkable number of VEXAS patients suffers from eye inflammation with a protean range of

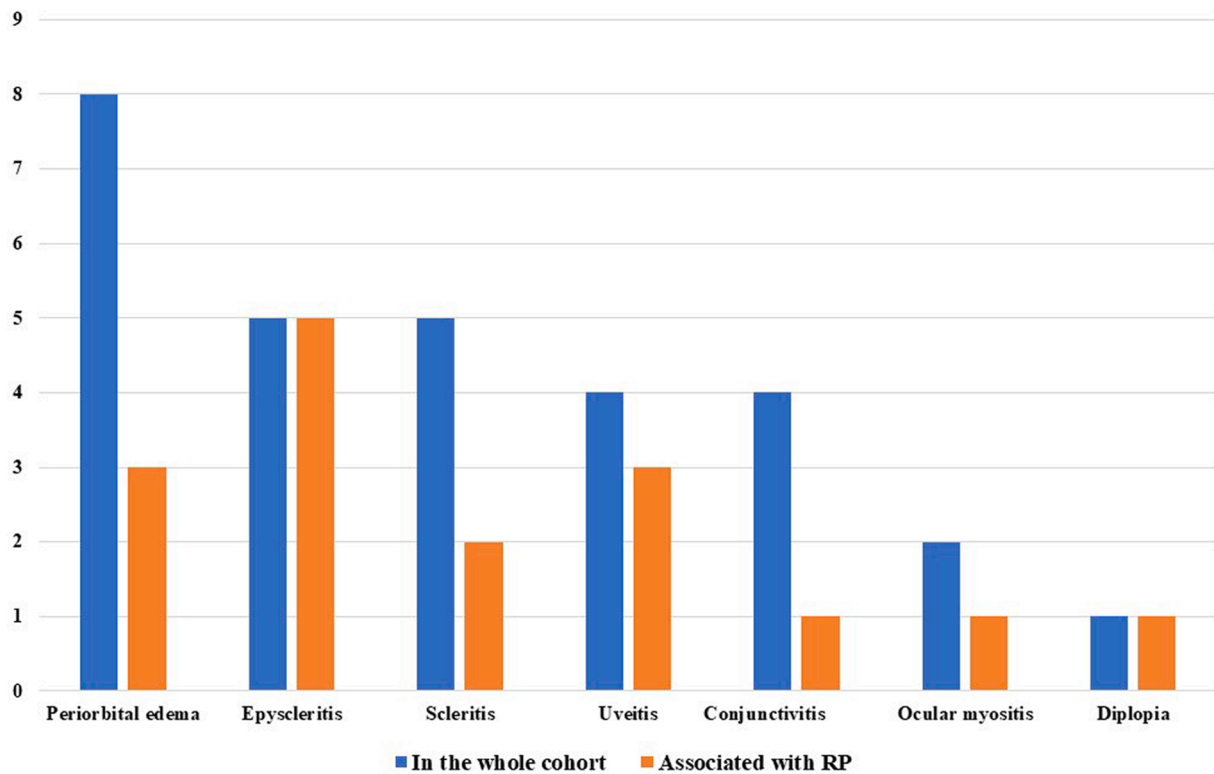


Fig. 2. Describes the frequency of specific orbital/ocular manifestations in the whole cohort and among patients with relapsing polychondritis.

manifestations. More specifically, periorbital edema, episcleritis, scleritis, uveitis, conjunctivitis, and blepharitis account for the most frequent inflammatory orbital/ocular features of VEXAS syndrome; other less frequent orbital/ocular affections are also identified, including eye muscles myositis, orbital cellulitis, and dacryoadenitis. The ophthalmological manifestations were non-mutually exclusive, as one patient may have presented with more than one manifestation.

Orbital/ocular involvement in the two patients with Grave's disease and Hashimoto thyroiditis started at the onset of the other VEXAS symptoms rather than with the concomitant thyroidal autoimmune disease, thus suggesting an association with VEXAS syndrome rather than to the endocrinological condition.

None of the other VEXAS-related signs were found to be significantly associated with orbital/ocular involvement. Conversely, orbital/ocular involvement was significantly associated with the diagnosis of relapsing polychondritis, with the frequency more than doubling among patients with orbital/ocular inflammatory manifestations. The role of chondritis and relapsing polychondritis on the prognosis of VEXAS patients is a matter of controversy. In particular, based on 40 patients suffering from idiopathic relapsing polychondritis and 55 patients with VEXAS-related relapsing polychondritis, Khitri et al. found a worse prognosis with more refractory disease and higher mortality in the latter group [16]. In the same way, a large-scale analysis of 116 French patients described 3 clusters of VEXAS syndrome, with the second burdened by the worst prognosis. This second cluster was also characterized by a high frequency of relapsing chondritis [17]. On the contrary, a further study based on 83 VEXAS patients disclosed that the occurrence of ear chondritis was associated with a better prognosis [18]. In the scenario, the data from the present study supports an association between ocular involvement and relapsing polychondritis. In particular, all patients with episcleritis also suffered from relapsing polychondritis and most of the VEXAS patients with scleritis, uveitis and orbital myositis presented a clinical picture consistent with relapsing polychondritis. Although no statistical significance was reached, mortality was more frequent among patients with ocular involvement. This seems to support the previous

studies suggesting a negative role for relapsing polychondritis.

No statistically significant differences were observed in the frequency of MSD and paraproteinemia between patients with and without orbital/ocular involvement. Noteworthy, in this study vacuoles in myeloid and erythroid precursors were significantly more frequent among patients with orbital/ocular involvement, while the frequency of thrombocytopenia was significantly higher among patients without orbital/ocular involvement. The result about thrombocytopenia appears to contravene previous findings suggesting that chondritis and thrombocytopenia are both frequently identified in the same subgroup of patients [19]. In addition, thrombocytopenia has been found to represent a risk factor for mortality [19], crawling with the lower frequency of thrombocytopenia observed in the present study in the group of patients with the higher mortality frequency. However, studies are still based on a limited number of patient at present, and the evidence currently available need to be verified in progressively larger cohorts. Whether or how thrombocytopenia may associate with orbital involvement will have to be the objective of future studies. Similarly, explaining the higher frequency of patients with vacuoles in the bone marrow hematological precursors among those with orbital inflammatory manifestations is currently challenging. Further evidence is needed to determine whether this finding is meaningful or merely coincidental.

Most of the patients that died in this cohort also suffered from orbital/ocular inflammatory manifestations, thus suggesting that patients with ocular features may be at higher risk of death in the short term. This finding requires further confirmation in larger cohorts, both due to the limited number of patients observed in the present study and to the highly varied nature of orbital/ocular inflammatory manifestations observed in deceased patients, ranging from scleritis to episcleritis. However, based on the observations in the current study, orbital involvement may require increased attention and more careful follow-up in VEXAS patients.

The main limitation of this study consists in the limited number of patients enrolled, which nonetheless would have to be considered a remarkable number for a recently discovered disease.

In conclusion, the present study confirms that orbital/ocular inflammatory involvement is a common finding in VEXAS patients, especially those resembling relapsing polychondritis. This makes ophthalmologists a key figure in the diagnostic process of VEXAS syndrome. The high frequency of deaths observed in this study seems to suggest that orbital/ocular inflammation could potentially serve as an indicator for identifying patients requiring more careful monitoring.

CRedit authorship contribution statement

Antonio Vitale: Writing – original draft, Data curation. **Valeria Caggiano:** Writing – original draft, Data curation, Conceptualization. **Eduardo Martin-Nares:** Supervision, Data curation. **Micol Frassi:** Supervision, Data curation. **Lorenzo Dagna:** Supervision, Data curation. **Pravin Hissaria:** Supervision, Investigation, Data curation. **Paolo Sfriso:** Supervision, Investigation. **José Hernández-Rodríguez:** Supervision, Investigation. **Guillermo Ruiz-Irastorza:** Supervision, Investigation. **Sara Monti:** Supervision, Investigation. **Abdurrahman Tufan:** Supervision, Investigation. **Matteo Piga:** Supervision, Investigation. **Henrique A Mayrink Giardini:** Supervision, Investigation. **Giuseppe Lopalco:** Supervision, Investigation. **Ombretta Viapiana:** Supervision, Investigation. **Amato De Paulis:** Supervision, Investigation. **Paola Triggianese:** Supervision, Investigation. **Rosetta Vitetta:** Supervision, Investigation. **Alejandra de-la-Torre:** Supervision, Investigation. **Alex Fonollosa:** Supervision, Investigation. **Federico Caroni:** Supervision, Investigation. **Jurgen Sota:** Supervision, Investigation. **Edoardo Conticini:** Supervision, Investigation. **Jessica Sbalchiero:** Supervision, Investigation, Conceptualization. **Alessandra Renieri:** Supervision, Investigation. **Giulia Casamassima:** Supervision, Investigation. **Ewa Wiesik-Szewczyk:** Validation, Investigation. **Derya Yildirim:** Supervision, Investigation. **Andrea Hinojosa-Azaola:** Supervision, Investigation. **Francesca Crisafulli:** Supervision, Investigation. **Franco Franceschini:** Supervision, Investigation. **Corrado Campochiaro:** Supervision, Investigation. **Alessandro Tomelleri:** Supervision, Investigation. **Alicia Callisto:** Supervision, Investigation. **Mark Beecher:** Supervision, Investigation. **Sara Bindoli:** Supervision, Investigation. **Chiara Baggio:** Supervision, Investigation. **Verónica Gómez-Caverzaschi:** Supervision, Investigation. **Laura Pelegrín:** Supervision, Investigation. **Adriana Soto-Peleteiro:** Supervision, Investigation. **Alessandra Milanesi:** Supervision, Investigation. **Ibrahim Vasi:** Supervision, Investigation. **Alberto Cauli:** Supervision, Investigation. **Isabele Parente de Brito Antonelli:** Supervision, Investigation. **Floranzo Iannone:** Supervision, Investigation. **Riccardo Bixio:** Supervision, Investigation. **Francesca Della Casa:** Supervision, Investigation. **Ilaria Mormile:** Supervision, Investigation. **Carmelo Gurnari:** Supervision, Investigation. **Alessia Fiorenza:** Validation, Investigation. **Germán Mejía-Salgado:** Supervision, Investigation. **Perla Ayumi Kawakami-Campos:** Supervision, Investigation. **Gaafar Ragab:** Supervision, Investigation. **Francesco Ciccia:** Supervision, Investigation. **Piero Ruscitti:** Supervision, Investigation. **Monica Bocchia:** Supervision, Investigation. **Alberto Balistreri:** Supervision, Investigation. **Gian Marco Tosi:** Supervision, Investigation. **Bruno Frediani:** Supervision, Investigation. **Luca Cantarini:** Supervision, Data curation, Conceptualization. **Claudia Fabiani:** Validation, Supervision, Data curation, Conceptualization.

Declaration of competing interest

The authors declare that they have no conflicts of interest for this work.

Declarations

Ethics approval and consent to participate: The Ethics Committee of Azienda Ospedaliero-Universitaria Senese, Siena, Italy (Ref. N. 14951; NCT05200715) approved the study, which was performed according to

the Good Clinical Practice guidelines and the latest Declaration of Helsinki. Written informed consents for involved patients were collected. Clinical data are kept in accordance with the EU General Data Protection Regulations (GDPR), or other counterparts, on the processing of personal data and the protection of privacy (2016/679/EU).

Funding

No funding for this study.

Acknowledgments

This research is supported (not financially) by the European Reference Network (ERN) for Rare Immunodeficiency, Autoinflammatory and Autoimmune Diseases (RITA). Thirteen of the authors of this publication [Antonio Vitale, Valeria Caggiano, Micol Frassi, Jurgen Sota, Lorenzo Dagna, Paolo Sfriso, Sara Monti, Edoardo Conticini, Federico Caroni, Alessandra Renieri, Giulia Casamassima, Jurgen Sota, Jessica Sbalchiero, José Hernández-Rodríguez, Monica Bocchia, Frediani Bruno, Alberto Balistreri, Gian Marco Tosi, Claudia Fabiani, and Luca Cantarini] belong to institutes that are members of the ERN RITA [Azienda Ospedaliero-Universitaria Senese of Siena; University of Brescia and Spedali Civili of Brescia; University of Padua; Università Vita-Salute San Raffaele, Milan; Hospital Clínic of Barcelona; Fondazione IRCCS Policlinico San Matteo]

References

- [1] Beck DB, Ferrada MA, Sikora KA, Ombrello AK, Collins JC, Pei W, et al. Somatic mutations in *UBA1* and severe adult-onset autoinflammatory disease. *N Engl J Med* 2020;383:2628–38.
- [2] Obiorah IE, Patel BA, Groarke EM, Wang W, Trick M, Ombrello AK, et al. Benign and malignant hematologic manifestations in patients with VEXAS syndrome due to somatic mutations in *UBA1*. *Blood Adv* 2021;5:3203–15.
- [3] Vitale A, Caggiano V, Bimonte A, Caroni F, Tosi GM, Fabbiani A, et al. VEXAS syndrome: a new paradigm for adult-onset monogenic autoinflammatory diseases. *Intern Emerg Med* 2023;18(3):711–22.
- [4] Vitale A, Caggiano V, Della Casa F, Hernández-Rodríguez J, Frassi M, Monti S, et al. Development and Implementation of the AIDA International Registry for Patients With VEXAS Syndrome. *Front Med* 2022;9:926500 (Lausanne).
- [5] Harris PA, Taylor R, Thielke R, Payne J, Gonzalez N, Conde JG. Research electronic data capture (REDCap)—a metadata-driven methodology and workflow process for providing translational research informatics support. *J Biomed Inform* 2009;42(2):377–81.
- [6] Van Gijn ME, Ceccherini I, Shinar Y, Carbo EC, Slofstra M, Arostegui JI, et al. New workflow for classification of genetic variants' pathogenicity applied to hereditary recurrent fevers by the International Study Group for Systemic Autoinflammatory Diseases (INSAID). *J Med Genet* 2018;55(8):530–7.
- [7] Milhavel F, Cuisset L, Hoffman HM, Slim R, El-Shanti H, Aksentijevich I, et al. The infivers autoinflammatory mutation online registry: update with new genes and functions. *Hum Mutat* 2008;29(6):803–8.
- [8] Touitou I, Lesage S, McDermott M, Cuisset L, Hoffman H, Dode C, et al. Infervers: an evolving mutation database for auto-inflammatory syndromes. *Hum Mutat* 2004;24(3):194–8.
- [9] Sarrauste de Menthère C, Terrière S, Pugnère D, Ruiz M, Demaille J, Touitou I. INFEVERS: the registry for FMF and hereditary inflammatory disorders mutations. *Nucleic Acids Res* 2003;31(1):282–5.
- [10] Rothman K. Episheet. 2015. Available: <https://www.rtihs.org/sites/default/files/2022-04/Episheet.xls>.
- [11] Geogin-Lavialle S, Terrier B, Guedon AF, Heiblig M, Comont T, Lazaro E, et al. Further characterization of clinical and laboratory features in VEXAS syndrome: large-scale analysis of a multicentre case series of 116 French patients. *Br J Dermatol* 2022;186:564–74.
- [12] Hines AS, Mohandes NA, Lehman JS, Koster MJ, Cantwell HM, Alavi A, et al. Cutaneous involvement in VEXAS syndrome: clinical and histopathologic findings. *Int J Dermatol* 2023;62:938–45.
- [13] Myint K, Patrao N, Vonica O, Vahdani K. Recurrent superior orbital fissure syndrome associated with VEXAS syndrome. *J Ophthalmic Inflamm Infect* 2023;13:39.
- [14] Lokhande A, Jarmale S, Vaishnav YJ, Schaefer J. An Orbital Manifestation of VEXAS Syndrome. *Ophthalmic Plast Reconstr Surg* 2023;39:e194–7.
- [15] Fanlo P, Román MLS, Fonollosa A, Ilarramendi J, Heras H, Grayson P. Episcleritis and periorbital edema secondary to VEXAS syndrome. *Arch Soc Esp Oftalmol* 2023;98:607–10 (Engl Ed).
- [16] Khitri MY, Guedon AF, Geogin-Lavialle S, Terrier B, Saadoun D, Seguier J, le Besnerais M, et al. Comparison between idiopathic and VEXAS-relapsing

- polychondritis: analysis of a French case series of 95 patients. *RMD Open* 2022;8:e002255.
- [17] Georjin-Lavialle S, Terrier B, Guedon AF, Heiblig M, Comont T, Lazaro E. Further characterization of clinical and laboratory features in VEXAS syndrome: large-scale analysis of a multicentre case series of 116 French patients. *Br J Dermatol* 2022; 186(3):564–74.
- [18] Ferrada MA, Savic S, Cardona DO, Collins JC, Alessi H, Gutierrez-Rodrigues F, et al. Translation of cytoplasmic UBA1 contributes to VEXAS syndrome pathogenesis. *Blood* 2022;140(13):1496–506.
- [19] Gutierrez-Rodrigues F, Kusne Y, Fernandez J, Lasho T, Shalhoub R, Ma X, et al. Spectrum of clonal hematopoiesis in VEXAS syndrome. *Blood* 2023;142(3):244–59.