

## RESEARCH ARTICLE

# NUT carcinoma in pediatric patients: Characteristics, therapeutic regimens, and outcomes of 11 cases registered with the German Registry for Rare Pediatric Tumors (STEP)

Tim Flaadt<sup>1</sup>  | Hannah Wild<sup>1</sup> | Michael Abele<sup>1</sup>  | Michael Frühwald<sup>2</sup> |  
Uta Dirksen<sup>3</sup>  | Carl F. Classen<sup>4</sup> | Christian Seitz<sup>1</sup> | Antje Redlich<sup>5</sup>  |  
Ulrich M. Lauer<sup>6,7</sup> | Linus Kloker<sup>6,7</sup> | Christian Kratz<sup>8</sup> | Dominik T. Schneider<sup>9</sup>  |  
Ines B. Brecht<sup>1</sup>

<sup>1</sup>Pediatric Hematology/Oncology, Department of Pediatrics, University Hospital Tuebingen, Tuebingen, Germany

<sup>2</sup>Swabian Children's Cancer Center, Children's Hospital, Klinikum Augsburg, Augsburg, Germany

<sup>3</sup>Pediatrics III, West German Cancer Centre Essen, German Cancer Consortium (DKTK) site Essen, National Center for Tumordiseases (NCT) site Essen, University Hospital Essen, Essen, Germany

<sup>4</sup>Pediatric Haematology/Oncology/Immunology, Department of Pediatrics, University Hospital Rostock, Rostock, Germany

<sup>5</sup>Pediatric Oncology, Otto-von-Guericke-University, Magdeburg, Germany

<sup>6</sup>Department of Internal Medicine VIII, Medical Oncology and Pneumology, University of Tuebingen, Tuebingen, Germany

<sup>7</sup>German Cancer Consortium (DKTK), German Cancer Research Center (DKFZ), Partner Site Tuebingen, Tuebingen, Germany

<sup>8</sup>Department of Pediatric Hematology and Oncology, Hannover Medical School, Hannover, Germany

<sup>9</sup>Clinic of Pediatrics, Dortmund Municipal Hospital, Dortmund, Germany

## Correspondence

Tim Flaadt, Department of Hematology and Oncology, University Children's Hospital Tuebingen, Hoppe-Seyler-Str. 1, Tuebingen 72070, Germany.  
Email: [tim.flaadt@med.uni-tuebingen.de](mailto:tim.flaadt@med.uni-tuebingen.de)

## Funding information

German Childhood Cancer Foundation, Grant/Award Numbers: DKS 2013.18 A/B, DKS 2018.18 A/B, DKS 2021.05 A/B

## Abstract

**Background and aims:** Nuclear protein of the testis (NUT) carcinoma (NC) is a rare and highly aggressive tumor defined by the presence of a somatic NUTM1 rearrangement, occurring mainly in adolescents and young adults. We analyzed the clinical and biological features of German pediatric patients ( $\leq 18$  years) with NC.

**Methods:** This study describes the characteristics and outcome of 11 children with NC registered in the German Registry for Rare Pediatric Tumors (STEP).

**Results:** Eleven patients with a median age of 13.2 years (range 6.6–17.8) were analyzed. Malignant misdiagnoses were made in three patients. Thoracic/mediastinal tumors were found to be the primary in six patients, head/neck in four cases; one patient had multifocal tumor with an unknown primary. All patients presented with regional lymph node involvement, eight patients (72.7%) with distant metastases. Seven patients underwent surgery, eight radiotherapy with curative intent; poly-

**Abbreviations:** AURK, aurora kinase; BETis, inhibitors of BET proteins; EFS, event-free survival; ESCP, European Standard Clinical Practice; EXPeRT, European Cooperative Study Group for Paediatric Rare Tumors; FISH, fluorescence in situ hybridization; Gy, Gray; HDAC, histone deacetylase; IHC, immunohistochemical; NC, NUT carcinoma; NUT, nuclear protein of the testis; OS, overall survival; PFS, progression-free survival; SSG, Scandinavian Sarcoma Group; STEP, Seltene Tumor-Erkrankungen in der Pädiatrie; T-VEC, talimogene laherparepvec; VIDE, vincristine, ifosfamide, doxorubicin and etoposide.

This is an open access article under the terms of the [Creative Commons Attribution-NonCommercial-NoDerivs](https://creativecommons.org/licenses/by-nc-nd/4.0/) License, which permits use and distribution in any medium, provided the original work is properly cited, the use is non-commercial and no modifications or adaptations are made.

© 2023 The Authors. *Pediatric Blood & Cancer* published by Wiley Periodicals LLC.

chemotherapy was administered in all patients. Novel treatment strategies including immunotherapy, targeted therapies, and virotherapy were applied in three patients. Median event-free survival and overall survival were 1.5 and 6.5 months, respectively.

**Conclusions:** Every undifferentiated or poorly differentiated carcinoma should undergo testing for the specific rearrangement of *NUTM1*, in order to initiate an intense therapeutic regimen as early as possible. As in adults, only few pediatric patients with NC achieve prolonged survival. Thus, novel therapeutic strategies should be included and tested in clinical trials.

#### KEYWORDS

immunotherapy, lung carcinoma, NUT carcinoma, rare tumors

## 1 | INTRODUCTION

Nuclear protein of the testis (NUT) carcinoma (NC) is a poorly differentiated squamous cell tumor defined by the presence of specific somatic translocations, which are rare and highly aggressive.<sup>1–3</sup> *NUTM1* rearrangements result in the fusion of the *NUTM1* gene with a couple of other genes.<sup>1–3</sup> In most NC cases, this “target” gene is *BRD4* (19p13); other known translocation partners are *BRD3* (9q34), *ZNF539* (19p12), or *NSD3* (8p12).<sup>4–6</sup> These aberrant gene fusions lead to the formation of oncogenic complexes that disrupt histone acetylation followed by massive alterations in the respective transcriptomes, which amongst other events lead to the activation of oncogenes and disruption of an orderly cell differentiation.<sup>7,8</sup>

Initially, NC is very often misdiagnosed. This is likely due to its rarity, lack of specific clinical, imaging, and histological features, and the fact that the tumors are not restricted to a particular organ.<sup>9–11</sup>

However, using a simple immunohistochemistry employing a highly specific anti-*NUTM1*-antibody makes the diagnosis quite easy and straightforward.<sup>12</sup>

NC can occur at any age, from infants (even neonates) to elderly people; however, most cases are found in adolescents and young adults.<sup>1,2</sup>

Cure or long-term survival is rare and mostly associated with the onset of tumor resections at localized disease stages; in adults, non-*BRD4*-fusions are also reported to be associated with better outcomes.<sup>1,8,13</sup> NCs are mostly refractory to conventional poly-chemotherapy; median overall survival (OS) is found to be very low, ranging from 6.7 to 9.5 months.<sup>1,8</sup>

Survival and response to treatment seem comparable between children/adolescents and adult patients. In a retrospective analysis of 63 patients by Bauer et al.<sup>14</sup> with NC, including 29 patients under the age of 18 years, progression-free survival (PFS) and OS did not differ significantly between the age groups over 18 years of age or below 18 years: for pediatric patients, PFS was 24% at 1 year and 14% at 2 years, and OS was 41% at 1 year and 30% at 2 years, respectively. For adult patients, they reported a PFS of 4% at 1 year and 4% at 2 years, respectively; OS was 16% at 1 year and 5% at 2 years, respectively.<sup>14</sup>

The current treatment approach for all patients is surgical resection before or after chemotherapy and radiation.<sup>15,16</sup> Novel treatment options, among them inhibitors of BET proteins (BETis),<sup>17</sup> histone deacetylase (HDAC) inhibitors,<sup>7</sup> and immunotherapeutic approaches with PD1/PD-L1 inhibition and oncolytic virotherapy are currently explored.<sup>18–20</sup> Currently three clinical trials currently evaluate targeted therapies in pediatric patients with NC, among them BET bromodomain inhibitors in combination with chemotherapy (NCT05019716) or the cyclin-dependent kinase inhibitor adamaciclib (NCT05372640).

Spreading the knowledge and a straightforward establishment of the diagnosis of NC are both essential to enable better management and counseling. To help to achieve these aims, a European Standard Clinical Practice (ESCP) on NC in children and adolescents has recently been published.<sup>16</sup>

Here, we report the characteristics, treatment, and outcomes of 11 pediatric patients (diagnosed  $\leq 18$  years), with NCs diagnosed between years 2011 and 2021 and being recorded in the German Registry for Rare Pediatric Tumors (STEP—“*Seltene Tumor-Erkrankungen in der Pädiatrie*”).

## 2 | METHODS

### 2.1 | Patients

Children and adolescents with NC were identified in the prospective STEP. Inclusion criteria were diagnosis of NC between 2011 and 2021 and age at diagnosis  $\leq 18$  years. Informed consent was obtained from the legal guardians and/or patients. The STEP registry has been approved by the institutional review boards of Erlangen, Germany, and the participating hospitals.

### 2.2 | Database

The database of the STEP registry contains patient and tumor characteristics such as gender, age at diagnosis, histology, symptoms,

localization, staging, tumor differentiation, molecular genetics, therapy modalities, events, outcomes, last follow-up, pre-existing diseases, family history, and germline genetic evaluation (if performed). Distinct treatment modalities were surgery, chemotherapy, radiotherapy, targeted therapy, immunotherapy, and oncolytic virotherapy. The quality of the data was verified by comparison with physicians' letters and with reports on surgery, radiology, and pathology kept at the study center or requested from the treating hospitals.

## 2.3 | Diagnosis

Because there are no morphological features unique to NC, it is diagnosed on the basis of its pathognomonic genetic characteristic, the NUTM1 rearrangement, that results in the expression of an aberrant NUTM1 fusion protein. Diagnosis of NC can be achieved using immunohistochemical (IHC) staining with a specific monoclonal antibody, which specifically recognizes the NUTM1 protein.<sup>21,22</sup>

Additional tests helping to identify the fusion partner of NUTM1 are in situ hybridization (fluorescence in situ hybridization; FISH) with split-apart probes or next-generation sequencing-based assays.<sup>23</sup> Following international and ESCP recommendations, evidence of positive IHC staining was defined as being necessary for inclusion in this analysis.<sup>16</sup> The histological specimen were reviewed by experts in pediatric pathology in order to confirm the diagnosis.

## 2.4 | Statistical methods

A descriptive analysis was done. Event-free survival (events defined as relapse, progressive disease, or death) and OS were calculated using the Kaplan–Meier method, starting from the date of the first diagnosis.

## 3 | RESULTS

The characteristics of the eleven patients with NC are shown in Table 1. The mean age at diagnosis was 13.2 years (range 6.6–17.8 years), with a predominance of male patients ( $n = 8$ ; 72.7%). For all patients, the family history was unremarkable with regard to tumor predisposition. Testing for germline mutations was done in none of the patients.

Primary sites were lung and mediastinum ( $n = 6$ ; 55%), cervical lymph nodes ( $n = 1$ ; 9%), paranasal sinuses ( $n = 1$ ; 9%), sublingual gland ( $n = 1$ ; 9%), and mandibula ( $n = 1$ ; 9%). One patient had widespread disease at diagnosis, with an unknown primary ( $n = 1$ ; 9%).

Presenting symptoms were nonspecific, with pain, local swelling, cough, and weight loss, in most patients with a duration of about 1–2 months (range 1 week to 6 months). Because of the nonspecific pattern of the symptoms, infectious causes were suspected initially in five patients (45.5%). In three patients, other malignant (mis)diagnoses were made in the beginning. In one patient, the diagnosis of NC was

made retrospectively, 5 five years after the initial diagnosis. In six patients (54.5%), NC was confirmed by reverse transcription polymerase chain reaction (RT-PCR), identifying *BRD4* as the fusion partner to *NUTM1* in four patients (36.4%), *BRD3-NUTM1* and *ZNF539-NUTM1* in one patient each (9%). In the other patients ( $n = 5$ , 45.5%), diagnosis was confirmed by IHC with anti-NUTM1 antibody immunostaining or FISH, thus without an explicit identification of the respective fusion partner.

Except for lactate dehydrogenase, none of the known tumor markers was found to be elevated (data supplement). IHC and molecular data of the NC samples are summarized in the data supplement. Focal expression of neuroendocrine markers was rarely seen. TTF1 and synaptophysin expression were always negative. Lymphoid markers were rarely positive. P63 was positive in six out of six patients tested. Ki67 was >30% in all tested tumor samples (range >30–>90%).

Maximum tumor sizes were between 2.5 and 11.5 cm. All patients ( $n = 11$ ) had local lymph node involvement, eight patients (72.7%) had distant metastasis. The most frequent sites of metastasis were lung/mediastinum and bones in four patients each (36.4%); cerebral and peritoneal metastasis was reported in one patient, and bone marrow infiltration in another patient (9%) (Table 1).

## 3.1 | Therapy

### 3.1.1 | First line therapy

Six of the 11 patients (54.5%) received conventional chemotherapy due to initial tumor extension and/or rapid progression. Chemotherapeutic agents included alkylating agents, platin compounds, and anthracyclines, mostly used in combination in the sense of polychemotherapeutic regimens (Table 2), often according to sarcoma treatment protocols (Scandinavian Sarcoma Group's [SSG] IX and Ewing). In one patient, a complete surgical resection was achieved initially; four other patients only achieved incomplete surgical resections initially; in one patient, incomplete resection was achieved following neoadjuvant chemotherapy.

All except one of the eleven patients rapidly experienced relapse or progressive disease (Table 2) after initial chemotherapy. The median number of cycles to progressive disease was two, with a range of one to five.

### 3.1.2 | Local therapy and radiotherapy

Eight patients received local radiotherapy with curative intent with a median dose of 54 Gray (Gy; range: 24–66.6). Subtotal (R2) resections or biopsies were performed in nine patients. Only in patient #11, prolonged survival was observed with R2 resection, in all other subtotally resected patients, rapid progression occurred despite radio- and chemotherapy. In the other long-term survivors (patients #11 and #7), R0 or R1 resections were possible.

**TABLE 1** Characteristics, therapy, and outcome of 11 nuclear protein of the testis (NUT) carcinoma (NC) patients.

Patient	Sex	Age at ID (y)	Symptoms (duration)	Primary site	Max. tumor size (cm)	Lymph nodes	Distant metastasis	Initially diagnosed as (duration to final diagnosis)	Diagnosis confirmed by <sup>1</sup>	Local therapy	First-line chemotherapy	Pattern of treatment failure at first relapse or progression	EFS (m)	OS (m)	Outcome
#1	f	14	Pain in shoulder, hip, back (2 m)	Unknown	7.7	Mediastinal	Lung, mediastinum, peritoneal, cerebral, bones (multiple)	CUP (1 m)	FISH	R2-resection, RTx 30 Gy (start after 2 <sup>nd</sup> cycle CTx)	VAI/PAI	Metastatic	3.7	4.1	DOD (4 m)
#2	m	9	Weight loss, malaise, food intolerance (6 m)	Lung, mediastinum	5.4	Mediastinal	Bones (multiple)	-	IHC	Biopsy only, RTx (start after 1 <sup>st</sup> cycle CTx)	VAI/PAI	Metastatic + local	2.7	10	DOD (10 m)
#3	m	17	Cough, pain (2 w)	Lung (right)	3.4	Mediastinal	Lung (bilateral)	Pneumonia (1 m)	IHC	Biopsy only, palliative RTx	VIDE	Metastatic	1.4	4.0	DOD (4 m)
#4	m	10	Pain in face (2 m)	Paranasal sinuses (right)	3.5	Jugular	Bones (multiple)	Sinusitis (2 m)	IHC	R2-resection, Re-excision, RTx after 2 <sup>nd</sup> cycle CTx 54 Gy	VAI/PAI	Metastatic	6.4	9.4	DOD (9 m)

(Continues)

TABLE 1 (Continued)

Patient	Sex	Age at ID (y)	Symptoms (duration)	Primary site	Max. tumor size (cm)	Lymph nodes	Distant metastasis	Initially diagnosed as (duration to final diagnosis)	Diagnosis confirmed by <sup>1</sup>	Local therapy	First-line chemotherapy	Pattern of treatment failure at first relapse or progression	EFS (m)	OS (m)	Outcome
#5	m	6	Thoracic pain, cough (2 m)	Lung (right)	6	Mediastinal	-	Pneumonia (2.5 m)	RT-PCR: BRD4-NUTM1	Biopsy only, RTx after end of CTx	PEI	Metastatic + local	0.6	3.3	DOD (3 m)
#6	m	17	Thoracic pain, cough, weight loss, fever (5 w)	Lung (right)	unknown	Mediastinal	-	Squamous cell carcinoma (2 w)	IHC	Biopsy only, no RTx	VIDE	Local	0.7	4.2	TRM (4 m)
#7	m	9	Local swelling, fever, vomiting, stomach pain (7 d)	Sublingual gland (right)	5	Cervical, mediastinal	-	Lymphadenitis (3 m)	RT-PCR: BRD4-NUTM1	R0-resection, RTx after 3rd cycle of CTx 54 Gy	VAI/PAI	Local	1.1	118.2	alive (9 y, 10 m)
#8	m	17	Mandibular swelling (1 m)	Mandibula (right)	11	Cervical	Lung (multiple)	-	RT-PCR: BRD4-NUTM1	R2-resection, RTx within 2nd cycle of CTx 66 Gy	CED	Metastatic + local	1.8	3.9	DOD (4 m)

(Continues)

TABLE 1 (Continued)

Patient	Sex	Age at ID (y)	Symptoms (duration)	Primary site	Max. tumor size (cm)	Lymph nodes	Distant metastasis	Initially diagnosed as (duration to final diagnosis)	Diagnosis confirmed by <sup>1</sup>	Local therapy	First-line chemotherapy	Pattern of treatment failure at first relapse or progression	EFS (m)	OS (m)	Outcome
#9	m	16	Cough, dyspnea, weight loss (2 m)	Lung (right)	11.5	Lung, mediastinal	Lung (multiple), bone marrow	Pneumonia (1 m)	RT-PCR: BRD4-NUTM1	biopsy only, palliative RTX	ICE; VDC	Local	0.6	7.8	DOD (8 m)
#10	f	17	Thoracic pain, cough (3 m)	Lung (right)	7	Lung, mediastinal	Pleura, mediastinum	Thymic carcinoma (5 y 2 m)	RT-PCR: BRD3-NUTM1	R2-resection after 1st cycle of CTx, RTX after 3rd cycle of CTx	PAC	Local	8.3	107.5	DOD (8 y, 11 m)
#11	f	7	Local swelling (3 m)	Cervical lymph nodes (left)	2.5	Cervical	Bones	-	RT-PCR: ZNF539-NUTM1	R1-resection, 4 cycles CTx, RTX within 2nd cycle	VAI/PAI	Metastatic	20.6	30.6	MR(3y, 5 m)

Abbreviations: CED, cisplatin; etoposide, doxorubicin; CTx, chemotherapy; CUP, cancer of unknown primary; DOD, died of disease; EFS, event-free survival; FISH, fluorescence in situ hybridization; ID, initial diagnosis; ICE/VDC, etoposide, ifosfamide, cisplatin/vincristine, doxorubicin, cyclophosphamide; IHC, immunohistochemistry; m, months; MR, mixed response OS, overall survival; PAC, doxorubicin, cisplatin, cyclophosphamide; PEI, etoposide, ifosfamide, cisplatin; PR, partial response; RT-PCR, reverse transcription polymerase chain reaction; RTX, radiotherapy; TRM, therapy related mortality; VAI/PAI, vincristine/cisplatin, adriamycin, ifosfamide; VIDE, vincristine, etoposide, doxorubicin, ifosfamide; w, weeks; y, years.

**TABLE 2** Details of systemic therapy in the 11 pediatric patients with nuclear protein of the testis (NUT) carcinoma (NC).

Patient	Line of therapy	Number of cycles	Therapy according to protocol	Chemotherapeutic agents	Targeted therapy	Best observed response	Outcome
#1	First line	1		Carboplatin; etoposide cyclophosphamide		-	PD (after 1 cycle)
	Second line	3	SSG IX Protocol; VAI/PAI <sup>1</sup>	Ifosfamide, adriamycin, vincristine/cisplatinium		-	PD (after 3 cycles)
#2	First line	4	SSG IX Protocol; VAI/PAI	Vincristine/cisplatinium, adriamycin, ifosfamide		PR (after 2 cycles)	PD (after 4 cycles)
	Second line	2	Adapted treatment protocol for bronchial carcinoma	Carboplatinium, paclitaxel, etoposide	BETI <sup>2</sup> (PD)		PD (after 1 cycle)
#3	First line	1	Adapted treatment protocol for bronchial carcinoma	Carboplatinium, paclitaxel, etoposide			PD (after 1 cycle)
	Second line	2	EWING 2008; VIDE	Vincristin, etoposide, doxorubicin, ifosfamide			PD (after first and second cycle)
#4	First line	8	SSG IX Protocol; VAI/PAI	Vincristine/cisplatinium, adriamycin, ifosfamide		CR (after 3 cycles)	Relapse 5 months after last cycle
#5	First line	1	-	Cyclophosphamide, dexamehasone (suspected lymphoma)			PD
#6	Second line	2	PEI (according to germ cell tumor protocol)	Etoposide, ifosfamide, cisplatinium			PD (after 2 cycles)
	Third line	1		Docetaxel			PD (after 1 cycle)
	First line	1	Adapted treatment protocol for bronchial carcinoma	Cisplatinium, etoposide			PD (after 1 cycle)
#7	Second line	4	EWING 2008; VIDE	Vincristine, etoposide, doxorubicin, ifosfamide/cyclophosphamide		PR (after 3 cycles)	PD (after 4 cycles)
	First line	9	SSG IX Protocol; VAI/PAI	Ifosfamide, adriamycin, vincristine/cisplatinium		CR	CR (after surgery and radiotherapy)
#8	First line	4		Cisplatinium, etoposide, doxorubicin		PR	PD (after cycle 2)

(Continues)

TABLE 2 (Continued)

Patient	Line of therapy	Number of cycles	Therapy according to protocol	Chemotherapeutic agents	Targeted therapy	Best observed response	Outcome
#9	First line	5	Ewing's sarcoma protocol	Etoposide, ifosfamide, cisplatinum (IEC) AND vincristine, doxorubicin, cyclophosphamide, ifosfamide, etoposide (VDCy-IE)		PD after IEC, PR after first and second cycle of VDCy-IE	PD after cycle 4 of VDCy-IE
	Second line	1		Cisplatinum, gemcitabine			PD (after 1 cycle)
	First line	8	PAC	Doxorubicin, cisplatinum, cyclophosphamide		PR (after 5 cycles)	PD
	Second line	6		Gemcitabine, carboplatinum			PD
	Third line	10		Gemcitabine, capecitabine		PR after first, fifth and 8th cycle	PD (after cycle 10)
#11	Fourth fifth and sixth line	9			octreotide <sup>3</sup> ; pembrolizumab; alisertib; vorinostat; navitoclax; BETi <sup>2</sup>		PD
	First line	12	SSG IX Protocol; VAI/PAI	Ifosfamide, adriamycin, vincristine/cisplatinum		CR (after 4 cycles)	CR, relapse after end of therapy
	Second line	3		Pembrolizumab		SD (after 1 cycle)	PD
	Third line	2		Pembrolizumab + Imlygic <sup>4</sup> + carboplatin / etoposide		PR (after 1 cycle)	MR (after 2 cycles)

Abbreviations: CR, complete response; MR, mixed response; PD, progressive disease; PR, partial response.

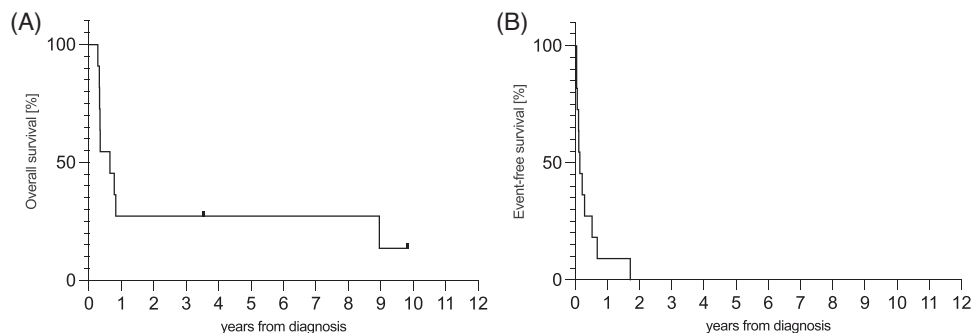
<sup>1</sup>Scandinavian Sarcoma Group's SSG IX protocol.

<sup>2</sup>inhibitor of BET proteins (patient #10 received 2 BETis, a first-generation (Molibresib (GSK525762)) and later a second-generation BETi (BI 89499) as compassionate use.

<sup>3</sup>octreotide was applied before the correct diagnosis of NC was made.

<sup>4</sup>recombinant oncolytic herpes simplex virus talimogene laherparepvec (T-VEC; Imlygic<sup>®</sup>).





**FIGURE 1** Overall survival (OS) and event-free survival (EFS) of the whole cohort. (A) Overall survival (OS). Median OS was calculated as 7.8 months; 2-year OS was 27.2% (with three long-term survivors; data of these patients are depicted in detail in Figure S1). (B) Event-free survival (EFS). Median EFS was calculated as 1.8 months. 2-year EFS was 0%.

### 3.1.3 | Targeted therapy and new agents

Three out of 11 patients (27.3 %) received targeted therapy at later stages, including BETi compounds in two patients; two patients received immunotherapy with the PD-1 inhibitor pembrolizumab; in one patient, pembrolizumab was combined with an Off-label use of the oncolytic herpes simplex virus talimogene laherparepvec (T-VEC; Imlygic®). No response was observed in the patients treated with BETi compounds. After PD with pembrolizumab monotherapy, a combinational treatment of T-VEC, chemotherapy and pembrolizumab resulted in PR after one cycle and mixed response (MR) after two cycles in patient #11. (For details, see supplemental material.)

## 3.2 | Outcome

Patients experienced early tumor recurrence/progression within a median of 1.8 months (range 0.6–20.6) after diagnosis. All patients had progressive disease or relapses after first-line therapy; the pattern of treatment failure at first relapse or progression was evaluable for all cases: four out of 11 (36.4%) showed isolated locoregional disease, four out of 11 (36.4%) had isolated distant disease, and three out of 11 (27.3%) combined locoregional and distant progression or relapse.

Median EFS was 1.8 months, 1-year EFS was 9.1% (95% CI: 0.5–33.3%) and 2-year EFS was 0% (Figure 1). The overall median survival time of the entire cohort was 7.8 months. One-year OS and 2-year OS were 27.2% (95% CI: 6.5–53.9%) (Figure 1).

At the end of follow-up, nine patients (81.8%) had died (eight patients (72.7%) from tumor progression and one patient from a bacterial infection associated with intense chemotherapy (stable disease at the time point of death)).

### 3.2.1 | Long-term survivors

Two patients are still alive (June 2023); one patient 9 years and 10 months after diagnosis without signs of recurrence, this patient had a localized tumor, which was completely resected; a local lymph node

relapse was successfully treated with radiotherapy and chemotherapy. Another patient currently receives therapy for a subsequent relapse (3 years, 5 months after diagnosis). Three patients (27.3%) experienced prolonged survival of over 2 years after combinational treatments (detailed information on the treatment of these patients in the data supplement; Figure 1). These patients experienced relapses or progressive disease during therapy. In one of these patients, a complete resection of the tumor was possible, a subsequent localized lymph node relapse/progression was successfully treated with radiotherapy and chemotherapy.

Despite several relapses and progressions another patient survived for 8 years and 11 months after diagnosis, this patient was diagnosed at the age of 17 years. This patient received targeted therapies and immunotherapy (including BETi compounds, BCL2-inhibitors and PD-1 inhibitor therapy) in combination with chemotherapy (including doxorubicin, cisplatin, cyclophosphamide, gemcitabine, carboplatin, and capecitabine) and radiotherapy, the tumor harbored a *BRD3-NUTM1* fusion, which is associated with better EFS and OS in adult patients.<sup>1,8,15</sup>

In another patient with prolonged survival, the *ZNF539-NUTM1* fusion was found. After an initial response, this patient experienced a relapse, which was treated with pembrolizumab monotherapy. After further progression, a combinational treatment consisting of pembrolizumab, chemotherapy (caboplatin and etoposide), and oncolytic virotherapy (Imlygic®; T-VEC) resulted in a MR.

## 4 | DISCUSSION

NC is a very rare tumor, genetically defined by a translocation involving the *NUTM1* gene. It represents an exceptionally aggressive tumor, clinically demonstrated with lymph node involvement in all patients in the present pediatric cohort and/or metastatic disease in 72.7% of the patients as well as rapid progression despite initial response to chemotherapy, corresponding to a median survival of less than 8 months. This observation is similar to previous reports from both pediatric and adolescent patients with NC. In a previously reported French cohort ( $n = 12$ ) consisting of adult and pediatric patients,

metastatic disease was seen in 8 patients (66.7%), corresponding in a 1-year EFS and OS of 8 and 17%, respectively.<sup>10</sup> The international NC registry reported PFS of 24% at 1 year and 14% at 2 years and an OS of 41% at 1 year and 30% at 2 years for a cohort of 29 pediatric patients, with a lower number of patients with metastatic disease than in our series and therefore probably slightly better overall- and event-free survivals.<sup>14</sup>

Due to its rarity and nonspecific presentation, for a long time, the diagnosis of NC was underestimated and often delayed. In our experience, an initial diagnosis of NC was proposed more frequently in recent times, which corresponds to the increasing number of patients diagnosed each year with NC and the increasing proportion of adult cases compared with pediatric cases.<sup>8,14</sup>

Like the reports on adult patients, this series of pediatric-only patients demonstrates the decent transient but then poor long-term response to chemotherapy, which is often rapidly followed by massive tumor progression.<sup>10,23</sup> Nevertheless, in some of our patients, further responses to second-line or subsequent chemotherapy and/or immunotherapy were seen, and prolonged survival was possible with multimodal treatment regimens. Because those patients received a combination of several different therapies not in a consecutive, but rather in an overlapping manner, and with low patient numbers, we were unable to conduct an analysis that identified elements of therapy or chemotherapeutic agents with improved outcomes. So far, no consensus has been reached about the optimal chemotherapy regimens. According to the recent ESCP, a multimodal and aggressive approach is highly recommended, as used in clinical practice in all of our patients.<sup>16</sup> The best responses on chemotherapy were observed for anthracycline-, an alkylating agent, and cisplatin-based regimens. Five patients received therapy according to the SSG IX protocol developed for unresectable Ewing's sarcoma consisting of vincristine/cisplatin, doxorubicin and ifosfamide. In four of these patients, significant responses were seen. Favorable responses with this sarcoma-like approach have previously been reported.<sup>13,24</sup> It has also been suggested that applying multimodal Ewing's sarcoma protocols, combining vincristine, ifosfamide, doxorubicin, and etoposide (VIDE) or vincristine, doxorubicin, cyclophosphamide, ifosfamide, etoposide (VDCy-IE) or etoposide, cisplatin (PE) could also be a favorable treatment options. VIDE has been applied in two of our patients, resulting in partial response and stable disease in one patient each.

Local treatment appears to play an important role in disease control, as the extent of surgical resection and initial radiotherapy have been reported as predictive of OS and EFS.<sup>14,25,26</sup> In our cohort, complete resection with adjuvant chemoradiotherapy resulted in long-term survival without recurrence in one patient.<sup>13</sup> In two other long-term survivors, subtotal resections (R1/R2) became possible. Radiotherapy was applied in all patients, with curative intent in eight patients. Radiotherapy doses were adapted upon the extent of local tumor burden as in adult patients with epithelial carcinomas. Consequently, high doses between 40 and 66 Gy have been applied, following previous reports.<sup>15</sup>

With the discovery of the oncogenic mechanism, NC has become a promising candidate for targeted therapeutic strategies. Three patients in the present cohort received various targeted therapies,

among them, treatment with the aurora kinase (AURK) inhibitor alisertib, the HDAC inhibitor vorinostat, BETi compounds (Molibresib (GSK525762)) and BI 89499), and the PD-1 inhibitor pembrolizumab. Several clinical trials evaluated different generations of BETi compounds in NC; however, currently without the hoped-for clinical efficacy—at least in monotherapy.<sup>27,28</sup> One patient received therapy with two different BETis: monotherapy with a first-generation BETi (Molibresib (GSK525762)), resulted in PD. Later, based on preclinical data, a dual BRD- and aurora-kinase inhibition (with BI 894999 and the AURK-inhibitor alisertib) was applied with good clinical tolerability, nevertheless resulting also in progressive disease.<sup>29</sup> Responses to HDAC inhibitors were also observed in some NC cases; one of our patients received vorinostat at a very late point in therapy, over 8 years after diagnosis. Despite the small number of published patients and the transient responses, there is a rationale supporting further clinical development of combinational treatments with HDAC inhibitors in pediatric NCs.<sup>30</sup>

In recent years, several cases of NCs receiving PD-1/PD-L1 inhibitor therapy have been reported, and PD-1 inhibitor therapy has been proven to be effective and safe in several other pediatric malignancies.<sup>31–33</sup> Reports of adult patients with unresectable NCs suggested that these patients might benefit more from pembrolizumab than nivolumab, especially with prior chemoradiotherapy or radiotherapy, which follows treatment strategies in lung cancer patients.<sup>32,34</sup> In two of our patients, pembrolizumab was given after chemotherapy and radiotherapy for the treatment of unresectable progressive disease or relapse.

After progressive disease with pembrolizumab monotherapy, one patient received a novel treatment strategy with pembrolizumab, conventional chemotherapy, and virotherapy with the oncolytic herpes simplex virus T-VEC (Imlygic®). This treatment follows preclinical data and a case report of an adult patient, resulting in an OS of 3.5 years after diagnosis and a MR at last follow up (June 2023).<sup>18,19</sup> This patient demonstrated response of nonirradiated tumor sites to chemioimmunovirotherapy, although it is not possible to distinguish which therapy element was responsible for the response. Details of therapy and the outcome will be reported separately.

As previously reported for adult patients, long-term survivors had either localized, nonthoracic disease with sufficient local tumor control (patient #7), or non-BRD4-fusions (patients #10 and #11, with BRD3–NUTM1 and ZNF539–NUTM1 fusion, respectively). Interestingly, in all long-term survivors, after disease progression or relapse, subsequent multimodal treatment approaches resulted in disease stabilization and prolonged survival. Patient #10 was correctly diagnosed with NC remarkable 5 years after initial presentation. In addition to the prognostically more favorable BRD3–NUTM1 fusion, an overall more indolent course of disease can be discussed here, therefore interpretations about therapy response should be interpreted cautiously here.

Currently, front-line immunotherapeutic approaches have not been evaluated systematically in patients with NC. In later-line settings, immunotherapy might be less effective due to the low immunogenicity of advanced tumors demonstrated in the low number of TILs in the

tumor specimen of our patients as well as the immunosuppressive effects of prior chemotherapy. In the authors' opinion, due to the rarity and the exceptional aggressiveness of this entity, all patients with newly diagnosed NCs should be treated in a clinical trial setting with combinational approaches of conventional therapy and immunotherapy, and/or targeted therapy (for example: NCT05019716).<sup>16,32</sup> If participation in a clinical trial is not possible for individual patients, international specialists should be contacted to discuss treatment options as published recommendations may not be up-to-date, especially with regard to the rapidly evolving field of targeted therapies and immunotherapy.<sup>16</sup>

Due to the retrospective nature, several treatment modalities, and, the small sample size, the results of this study must be interpreted cautiously. Over recent years, several groups have been formed to more clearly understand the characteristics and the outcome of rare tumors in children and adolescents (incidence < 2/million children/year), among them the European Cooperative Study for Pediatric Rare Tumors (EXPeRT), which has previously published a ESCP on NC in children and adolescents and currently collects data on all diagnosed European NC cases.<sup>16,35,36</sup>

As in adult patients, despite potential temporary response to chemotherapy, only a minority of pediatric patients with NC achieves long-term survival in the course of multimodal treatment regimens. Early diagnosis of undifferentiated or poorly differentiated carcinomas to identify the specific rearrangement of the *NUTM1* gene is necessary to initiate the optimal diagnostic and therapeutic strategy.

All pediatric patients with NC should be registered systematically into pediatric rare tumor registries in order to get a better insight into the characteristics and outcome of this very rare tumor entity and to further develop treatment recommendations. Molecular profiling should be performed systematically to better understand the molecular pathogenesis, the outcome of the molecular subgroups and hence to provide a sound basis for the evaluation of targeted therapies.

Further analyses in international collaborations like the EXPeRT are the next steps to improve knowledge on NC in childhood, hopefully helping to optimize treatment and outcomes. Besides the ongoing clinical trials, novel therapeutic approaches, including immunovirotherapy, are currently being explored in an upcoming phase I trial, which initially will be undertaken in a monocentric setting at University Hospital Tuebingen (including pediatric patients aged 6 years or more) only.

In future, great efforts should be made to set up clinical trials in order to be able to investigate therapy strategies in an evidence-based manner. Not only international cooperation, but also cooperation between pediatrics and adult medicine is necessary to achieve sufficient patient numbers.

## ACKNOWLEDGMENTS

The authors thank their colleagues at the STEP registry and the colleagues of the reporting hospitals, and all patients and their guardians who agreed to share their data.

Open access funding enabled and organized by Projekt DEAL.

## CONFLICT OF INTEREST STATEMENT

The authors report no conflict of interest.

## DATA AVAILABILITY STATEMENT

The data that support the findings of this study are available on request from the corresponding author. The data are not publicly available due to privacy restrictions.

## ORCID

Tim Flaadt  <https://orcid.org/0000-0002-2729-9941>

Michael Abele  <https://orcid.org/0000-0002-9780-603X>

Uta Dirksen  <https://orcid.org/0000-0002-5435-7860>

Antje Redlich  <https://orcid.org/0000-0002-1732-1869>

Dominik T. Schneider  <https://orcid.org/0000-0001-8153-1601>

## REFERENCES

- French CA. NUT carcinoma: clinicopathologic features, pathogenesis, and treatment. *Pathol Int*. 2018;68(11):583-595.
- Shehata BM, Steelman CK, Abramowsky CR, et al. NUT midline carcinoma in a newborn with multiorgan disseminated tumor and a 2-year-old with a pancreatic/hepatic primary. *Pediatr Dev Pathol*. 2010;13(6):481-485.
- Thompson-Wicking K, Francis RW, Stirnweiss A, et al. Novel BRD4-NUT fusion isoforms increase the pathogenic complexity in NUT midline carcinoma. *Oncogene*. 2013;32(39):4664-4674.
- Stevens TM, Morlote D, Xiu J, et al. NUTM1-rearranged neoplasia: a multi-institution experience yields novel fusion partners and expands the histologic spectrum. *Mod Pathol*. 2019;32(6):764-773.
- French CA, Ramirez CL, Kolmakova J, et al. BRD-NUT oncoproteins: a family of closely related nuclear proteins that block epithelial differentiation and maintain the growth of carcinoma cells. *Oncogene*. 2008;27(15):2237-2242.
- French CA, Rahman S, Walsh EM, et al. NSD3-NUT fusion oncoprotein in NUT midline carcinoma: implications for a novel oncogenic mechanism. *Cancer Discov*. 2014;4(8):928-941.
- Schwartz BE, Hofer MD, Lemieux ME, et al. Differentiation of NUT midline carcinoma by epigenomic reprogramming. *Cancer Res*. 2011;71(7):2686-2696.
- French CA. Pathogenesis of NUT midline carcinoma. *Annu Rev Pathol*. 2012;7:247-265.
- Huang QW, He LiJ, Zheng S, Liu T, Peng BN. An overview of molecular mechanism, clinicopathological factors, and treatment in NUT carcinoma. *Biomed Res Int*. 2019;2019:1.
- Lemelle L, Pierron G, Fréneaux P, et al. NUT carcinoma in children and adults: a multicenter retrospective study. *Pediatr Blood Cancer*. 2017;64(12).
- Baumgartner K, Lauer U, Horger M, et al. Nuclear protein in testis (NUT) midline carcinoma. *Rofo*. 2020;192(4):303-306.
- Lauer UM, Hinterleitner M, Horger M, Ohnesorge PV, Zender L. NUT carcinoma—an underdiagnosed malignancy. *Front Oncol*. 2022;12:914031.
- Storck S, Kennedy AL, Marcus KJ, et al. Pediatric NUT-midline carcinoma: therapeutic success employing a sarcoma based multimodal approach. *Pediatr Hematol Oncol*. 2017;34(4):231-237.
- Bauer DE, Mitchell CM, Strait KM, et al. Clinicopathologic features and long-term outcomes of NUT midline carcinoma. *Clin Cancer Res*. 2012;18(20):5773-5779.
- Giridhar P, Mallick S, Kashyap L, Rath GK. Patterns of care and impact of prognostic factors in the outcome of NUT midline carcinoma: a systematic review and individual patient data analysis of 119 cases. *Eur Arch Otorhinolaryngol*. 2018;275(3):815-821.

16. Lemelle L, Flaadt T, Fresneau B, et al. NUT carcinoma in children and adolescents: the Expert European Standard Clinical Practice Harmonized Recommendations. *J Pediatr Hematol Oncol*. 2023;45(4):165-173.
17. Filippakopoulos P, Qi J, Picaud S, et al. Selective inhibition of BET bromodomains. *Nature*. 2010;468(7327):1067-1073.
18. Ohnesorge P, Berchtold S, Beil J, et al. Efficacy of oncolytic herpes simplex virus T-VEC combined with BET inhibitors as an innovative therapy approach for NUT carcinoma. *Cancers (Basel)*. 2022;14(11):2761.
19. Kloker LD, Calukovic B, Benzler K, et al. Case report: immunovirotherapy as a novel add-on treatment in a patient with thoracic NUT carcinoma. *Front Oncol*. 2022;12:995744.
20. French CA, Cheng ML, Hanna GJ, et al. Report of the first international symposium on NUT carcinoma. *Clin Cancer Res*. 2022;28(12):2493-2505.
21. Haack H, Johnson LA, Fry CJ, et al. Diagnosis of NUT midline carcinoma using a NUT-specific monoclonal antibody. *Am J Surg Pathol*. 2009;33(7):984-991.
22. Tsao M-S, Nicholson AG, Maleszewski JJ, Marx A, Travis WD. Introduction to 2021 WHO classification of thoracic tumors. *J Thorac Oncol*. 2022;17(1):e1-e4.
23. French CA, Kutok JL, Faquin WC, et al. Midline carcinoma of children and young adults with NUT rearrangement. *J Clin Oncol*. 2004;22(20):4135-4139.
24. Mertens F, Wiebe T, Adlercreutz C, Mandahl N, French CA. Successful treatment of a child with t(15;19)-positive tumor. *Pediatr Blood Cancer*. 2007;49(7):1015-1017.
25. Chau NG, Ma C, Danga K, et al. An anatomical site and genetic-based prognostic model for patients with nuclear protein in testis (NUT) midline carcinoma: analysis of 124 patients. *JNCI Cancer Spectr*. 2020;4(2):pkz094.
26. Chau NG, Hurwitz S, Mitchell CM, et al. Intensive treatment and survival outcomes in NUT midline carcinoma of the head and neck. *Cancer*. 2016;122(23):3632-3640.
27. Cousin S, Blay J-Y, Garcia IB, et al. Safety, pharmacokinetic, pharmacodynamic and clinical activity of molibresib for the treatment of nuclear protein in testis carcinoma and other cancers: results of a Phase I/II open-label, dose escalation study. *Int J Cancer*. 2022;150(6):993-1006.
28. Shapiro GI, Lorusso P, Dowlati A, et al. A Phase 1 study of RO6870810, a novel bromodomain and extra-terminal protein inhibitor, in patients with NUT carcinoma, other solid tumours, or diffuse large B-cell lymphoma. *Br J Cancer*. 2021;124(4):744-753.
29. Felgenhauer J, Tomino L, Selich-Anderson J, Bopp E, Shah N. Dual BRD4 and AURKA inhibition is synergistic against MYCN-amplified and nonamplified neuroblastoma. *Neoplasia*. 2018;20(10):965-974.
30. French CA. Small-molecule targeting of BET proteins in cancer. *Adv Cancer Res*. 2016;131:21-58.
31. Xie X-H, Wang Li-Q, Qin Y-Y, et al. Clinical features, treatment, and survival outcome of primary pulmonary NUT midline carcinoma. *Orphanet J Rare Dis*. 2020;15(1):183.
32. Li X, Shi H, Zhang W, et al. Immunotherapy and targeting the tumor microenvironment: current place and new insights in primary pulmonary NUT carcinoma. *Front Oncol*. 2021;11:690115.
33. Marcus L, Fashoyin-Aje LA, Donoghue M, et al. FDA approval summary: pembrolizumab for the treatment of tumor mutational burden-high solid tumors. *Clin Cancer Res*. 2021;27(17):4685-4689.
34. Fiorica F, Belluomini L, Stefanelli A, et al. Immune checkpoint inhibitor nivolumab and radiotherapy in pretreated lung cancer patients: efficacy and safety of combination. *Am J Clin Oncol*. 2018;41(11):1101-1105.
35. Ferrari A, Schneider DT, Bisogno G. The founding of the European Cooperative Study Group on Pediatric Rare Tumors-EXPeRT. *Expert Rev Anticancer Ther*. 2013;13(1):1-3.
36. Bisogno G, Ferrari A, Bien E, et al. Rare cancers in children—The EXPeRT initiative: a report from the European Cooperative Study Group on Pediatric Rare Tumors. *Klin Padiatr*. 2012;224(6):416-420.

#### SUPPORTING INFORMATION

Additional supporting information can be found online in the Supporting Information section at the end of this article.

**How to cite this article:** Flaadt T, Wild H, Abele M, et al. NUT carcinoma in pediatric patients: Characteristics, therapeutic regimens, and outcomes of 11 cases registered with the German Registry for Rare Pediatric Tumors (STEP). *Pediatr Blood Cancer*. 2024;71:e30821.  
<https://doi.org/10.1002/pbc.30821>