

# Diagnosis and therapy of actinic keratosis

Janis Raphael Thamm  | Julia Welzel  | Sandra Schuh 

Department of Dermatology and Allergology,  
University Hospital Augsburg, Augsburg,  
Germany

## Correspondence

Janis Raphael Thamm, Department of  
Dermatology and Allergology, University  
Hospital Augsburg, Sauerbruchstraße 6, 86179  
Augsburg, Germany.  
Email: [janis.thamm@uk-augsburg.de](mailto:janis.thamm@uk-augsburg.de)

Janis Raphael Thamm  
Finanzielle Interessen: Ja  
Erklärung zu nicht-finanziellen  
Interessen: Keine

Julia Welzel  
Finanzielle Interessen: Ja  
Erklärung zu nicht-finanziellen  
Interessen: DDG

Sandra Schuh  
Finanzielle Interessen: Ja  
Erklärung zu nicht-finanziellen  
Interessen: Keine

## Summary

Actinic keratosis (AK) is considered a chronic and recurring in situ skin neoplasia, with a possible transformation into invasive squamous cell carcinoma (SCC). Among others, predominant risk factors for development of AK are UV-light exposure and immunosuppression. Basal epidermal keratinocyte atypia (AK I) and proliferation (PRO score) seem to drive malignant transformation, rather than clinical appearance of AK (Olsen I–III). Due to the invasiveness of punch biopsy, those histological criteria are not regularly assessed. Non-invasive imaging techniques, such as optical coherence tomography (OCT), reflectance confocal microscopy (RCM) and line-field confocal OCT (LC-OCT) are helpful to distinguish complex cases of AK, Bowen's disease, and SCC. Moreover, LC-OCT can visualize the epidermis and the papillary dermis at cellular resolution, allowing real-time PRO score assessment. The decision-making for implementation of therapy is still based on clinical risk factors, ranging from lesion- to field-targeted and ablative to non-ablative regimens, but in approximately 85% of the cases a recurrence of AK can be observed after a 1-year follow-up. The possible beneficial use of imaging techniques for a non-invasive follow-up of AK to detect recurrence or invasive progression early on should be subject to critical evaluation in further studies.

## KEYWORDS

Actinic keratosis, line-field confocal optical coherence tomography, confocal laser microscopy, non-invasive imaging, PRO score, topical therapy, photodynamic therapy

## EPIDEMIOLOGY AND ETIOLOGY OF ACTINIC KERATOSIS

Actinic keratoses (AKs) are precancerous epidermal skin lesions considered to be precursors of invasive squamous cell carcinomas (SCCs) developing from atypical keratinocytes. Accordingly, actinic keratosis is also referred to as in situ neoplasia. It has been suggested that approximately 60% of SCCs arise from AKs.<sup>1</sup> SCC accounts for approximately 20% of nonmelanoma skin cancer (NMSC) or *keratinocyte cancer* (KC) and is, therefore, the second most common form of nonmelanoma skin cancer in immunocompetent patients after basal cell carcinoma (BCC).<sup>2</sup> Usually, AKs manifest on sun-exposed sites, such as scalp, dorsal aspect of the hands, or forearms. Accordingly, the cumulative amount of UV-light exposure during life is considered

the most important cause for AK manifestation. In addition, other factors like age, gender, skin type (Fitzpatrick I and II), and immunosuppression contribute to the risk of developing AK.<sup>3</sup> It has been estimated that the prevalence of AK in the age group of 60–69 years is 4.6%, while the prevalence has almost tripled to 14.57% in the group older than 80 years.<sup>4</sup> In the German population, the examination of 90,800 individuals resulted in an estimated AK prevalence of 2.7% in all age groups, while in the older population, 11.5% of patients aged 60 to 70 years suffer from AK.<sup>5</sup> In addition, it was found that the male population is affected to a greater extent (3.5%) by AK than the female population (1.5%).<sup>3</sup>

While the life-time risk of malignant transformation to SCC is 6%–10% for patients with multiple AKs, the annual risk of malignant degeneration of individual actinic ker-

This is an open access article under the terms of the [Creative Commons Attribution-NonCommercial-NoDerivs](https://creativecommons.org/licenses/by-nc-nd/4.0/) License, which permits use and distribution in any medium, provided the original work is properly cited, the use is non-commercial and no modifications or adaptations are made.

© 2024 The Authors. *Journal der Deutschen Dermatologischen Gesellschaft* published by John Wiley & Sons Ltd on behalf of Deutsche Dermatologische Gesellschaft.

atoses ranges from 0.03%–20%.<sup>1,5,6</sup> Moreover, AK is considered a chronic recurrent disease, given that recurrence is observed in more than 85% of the treated AK cases after one year of follow-up.<sup>7</sup> The aging society and the high recurrence rate may partly explain why treatment of AK is a complex and expensive task presenting an estimated annual financial burden of nearly 1 to 1.68 billion US dollars for the American healthcare system.<sup>8,9</sup> These expenses include the examination of almost ten million patients with actinic skin damage per year.<sup>8</sup> The burden may further increase in an aging society and is supported by the fact that the incidence of SCC has even quadrupled in parts of the German population in the last 30 years.<sup>3</sup> Moreover, Leiter et al. predict for the year 2030 that the incidence of nonmelanoma skin cancer will double again, with a continuously increasing incidence in the long term.<sup>2</sup> The development of AK and the progression to invasive SCC is a multifactorial process driven by numerous endogenous and exogenous factors. On the genetic level, *TP53* acts as tumor suppressor gene in the human genome controlling numerous cell cycle mechanisms and playing a central role in the regulation of cell proliferation and induction of apoptosis in mutated cells. Mutations of *TP53* are predominantly found in human tumor tissue including SCC, where mutations of *TP53* are found in approximately 50% of the cases.<sup>10–12</sup> Sunlight, and UVB radiation in particular, has been identified as carcinogen with the ability of changing *TP53*.<sup>13</sup> *TP53* mutations identified in UVB-induced skin areas of mice resemble mutations in SCC, suggesting that these lesions are SCC precursors.<sup>14</sup> A characteristic UVB-induced mutation in the *TP53* gene is the conversion of cytidine to thymidine resulting in a loss of function of the *TP53* gene product.<sup>15</sup> Apart from *TP53*, other additional mutations in the genome may increase the risk of keratinocyte atypia or stimulate uncontrolled cell proliferation. Furthermore, it is known from mutations in the *KNSTRN* oncogene that they promote this cell atypia.<sup>16</sup> These mutations have been observed in 19% of SCCs and 13% of AKs, while they have never been identified in healthy skin.<sup>15</sup> Apart from genomic mutations in AK, other co-factors seem to stimulate the malignant transformation of AK. It has been suggested that viral infections like human papilloma virus (HPV) play a co-stimulating role in carcinogenesis in up to 30% of the cases of tumor manifestation. While the role of HPV in the development of nonmelanoma skin cancer is still subject of controversial discussion in the literature, a significant risk of developing nonmelanoma skin cancer is observed in patients with iatrogenic immunosuppression, in particular.<sup>17</sup> Although pharmacologic immunosuppression increases the probability that nonmelanoma skin cancer is colonized by HPV, the immunosuppression, which correlates significantly with the development of nonmelanoma skin cancer, is solely dependent on the duration of drug administration. The incidence of nonmelanoma skin cancer is 5% after immunosuppression for 2 years; this value increases significantly with time and reaches 60% in patients on immunosuppression for at least 20 years.<sup>15</sup> Recently published follow-up data from 2022 for a Finnish

cohort of patients with organ transplants evaluated retrospectively for the last 30 years showed that nonmelanoma skin cancer accounts for 53% of all cancer manifestations.<sup>18</sup> Analogous to this situation, nonmelanoma skin cancer was observed as the main cause for tumor-associated mortality in patients with kidney transplants in the population of Australia and New Zealand.<sup>19</sup> Furthermore, non-iatrogenic immunosuppression, especially in case of non-Hodgkin lymphoma or chronic lymphocytic leukemia as underlying disease, seems to considerably increase the risk of nonmelanoma skin cancer including recurrence and a more aggressive course with metastasis.<sup>20</sup> In immunosuppressed patients, the probability to develop SCC and BCC is 4:1 and thus inversely proportional to the ratio in immunocompetent patients.<sup>15</sup> According to Schmitz et al., this can be explained in part by the higher progression rate of up to 30% of AKs to SCCs in immunosuppressed patients.<sup>15</sup> Given that AK is considered a squamous cell carcinoma in situ, the proliferation of atypical keratinocytes is restricted to the epidermis while the dermal-epidermal junction (DEJ) remains intact. Based on the histological assessment of specimens with SCC and adjacent AK tissue, Fernandez-Figueras et al. suggested two main pathways for malignant degeneration of AK to SCC.<sup>21</sup> The classical pathway describes the gradual development of keratinocyte atypia originating from the lower third of the epidermis (AK I) to atypia in the middle third (AK II), and eventually the upper third of the epidermis (AK III) according to the staging of atypia previously suggested by Roewert-Huber.<sup>21,22</sup> In the last stage of the disease, the invasive proliferation is defined based on the loss of integrity of the DEJ and the invasive infiltration of atypical keratinocytes into the dermis. Apart from the classical pathway, it was found that AK I can also progress directly to an invasive SCC without gradual development of atypia in higher epidermal layers, especially if an AK I is growing in close contact to adnexal tissue.<sup>21</sup> The progression from AK to SCC seems to be a complex process triggered by interactions between co-carcinogenic factors. The underlying mechanism is still poorly understood and therefore subject to controversial discussions in the current literature. Based on these assumptions, Schmitz et al. suggested the use of clinical and histological features found in AK lesions to estimate the risk of malignant transformation of AK.<sup>15</sup> The clinical classification according to Olsen and the two histological classifications (PRO score and Roewert-Huber) have the common objective to provide a grading system of the malignant potential of AK. The clinical benefit of these classifications is, however, critically discussed in the literature. Recent studies indicate that the clinical Olsen score alone is insufficient to predict the risk of malignant degeneration.<sup>3,21,23</sup>

The clinical manifestation of actinic keratosis does not correlate with the degree of underlying keratinocyte atypia and the histological PRO score.

In a study performed by Schmitz et al. in 2016, it was shown that the clinical manifestation of AK according to

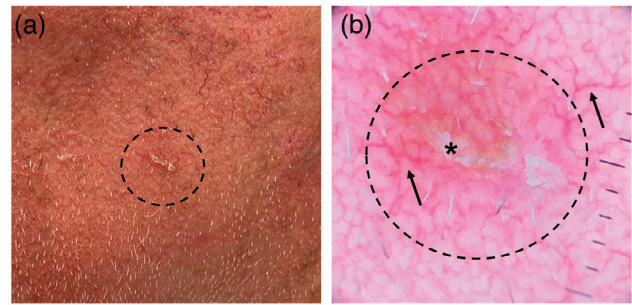
the Olsen classification does not correlate with the degree of underlying keratinocyte atypia measured by Roewert-Huber classification.<sup>23</sup> Only in 53.8% of lesions were clinical and histological classifications equivalent, with the majority (83.1%) consisting of Olsen II and AK II.<sup>23</sup> Another study demonstrated that the expression of the mutated *TP53* gene in AK increases with a higher rate of keratinocyte dysplasia, but no significant level could be defined.<sup>12</sup> Moreover, no significant correlation was found in AK between *TP53* expression, degree of epidermal dysplasia and clinical thickness or thickness of the stratum corneum.<sup>12</sup>

Based on these findings, Heerfordt et al.<sup>12</sup> supported the hypothesis of Schmitz et al.<sup>23</sup> that the clinical manifestation of AK is not a sufficient and reliable predictor for the malignant transformation to SCC. In contrast, Bakshi et al. showed that the mutated state of *TP53* and its increased protein expression could be found in clinically apparent AK, while significantly lower levels were found in regressed AK.<sup>24</sup> In 2019, Schmitz et al.<sup>25</sup> assessed, analogous to the study of Fernandez-Figueras et al.<sup>21</sup>, the epidermis overlying and adjacent to invasive SCC in histological specimens. The epidermal layers were examined with respect to keratinocyte atypia (Roewert-Huber, AK I–III) and basal growth pattern (PRO score I–III). The majority (39.4%) of SCCs showed PRO III in the adjacent epidermis, followed by PRO II (31.9%) and PRO I (25.7%).<sup>25</sup> Furthermore, basal proliferations of atypical keratinocytes (Roewert-Huber AK I) were found in more than 50% of the assessed adjacent AK lesions.<sup>25</sup> The finding that AK I is predominantly associated with invasive SCC was consistent with the study of Fernandez-Figueras et al. who reported that keratinocyte atypia often arises from the lower third of the epidermis (AK I).<sup>21,25</sup> If an AK I advances along adnexal structures, this may also facilitate further development of SCC from AK I lesions.<sup>21</sup> In spite of these controversies, the most recent S3 guidelines for AK and SCC provide no recommendation with respect to risk factors for the development of malignancy in AK.<sup>3</sup> Furthermore, there is no evidence that the risk of malignant degeneration can be predicted based on clinical manifestation.<sup>3</sup> The new insights indicate that downward-directed proliferation and basal atypia in AK represent two major factors for distinguishing high-risk AK. Unfortunately, it is not possible to determine these factors by clinical manifestation and to consistently examine them during follow-up due to the invasiveness and lack of reproducibility of skin biopsy.<sup>21,23</sup> Accordingly, there are no long-term follow-up data of AK documenting the various changes in cellular morphology and epidermal architecture on the pathway to malignant degeneration.

## CLINICAL MANIFESTATION AND DIAGNOSIS OF ACTINIC KERATOSIS

### Clinical manifestation and dermoscopy

While the clinical manifestation of AKs may vary, they generally present as circumscribed reddish, sometimes discrete



**FIGURE 1** (a) Clinical manifestation of AK. Slightly reddish macule, accompanied by keratosis on the left cheek of a patient (circle). (b) Using dermoscopy (DermLite® DL4 dermatoscope, 3Gen Inc., San Juan Capistrano, California, USA), keratosis (asterisk) and a strawberry pattern (circle) with linear wavy vessels (arrow) can be appreciated.

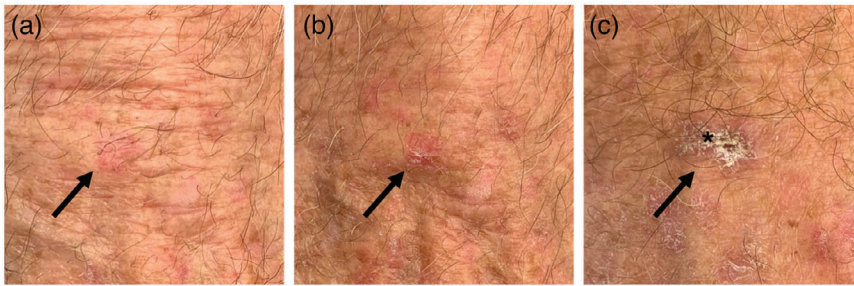
brownish macules accompanied by hyperkeratosis of varying thickness and scaling (Figure 1a). Usually, the lesions arise individually to disseminated, but may, however, coalesce to larger plaque-like formations, also known as field cancerization, in later stages. Apart from the clinical features, AKs may be accompanied by pruritus, erosions, or bleeding.

Generally, the diagnosis of AK is based on clinical and dermoscopic examination of the skin and observation of the clinical features already mentioned. Dermoscopy reveals the so-called “strawberry pattern” characterized by linear reticular vessels surrounding the follicular openings resulting in the appearance of an erythematous pseudonetwork (Figure 1b).<sup>15,26</sup> Compared to histology, dermoscopy has a sensitivity of 98.7% and a specificity of 95% in diagnosis of AK.<sup>26</sup> According to Valdés-Morales, the most common dermoscopic features of AK are scaling (86.7%), followed by follicular openings (83.1%), erythematous pseudonetwork (79.9%), and linear wavy vessels (71.2%).<sup>26</sup>

### Clinical classification according to Olsen

According to Olsen, the manifestation of AK can be classified based on three clinical characteristics (Olsen I–III): erythema, hyperkeratosis, and scaling.<sup>27</sup> In Olsen I, AK presents as a reddish or brownish pigmented macule. In this stage, it is difficult to detect and is easier felt than seen, given that erythema and hyperkeratosis are more or less absent according to the definition (Figure 2a).<sup>27</sup> Actinic keratoses according to Olsen II and III are usually easier to diagnose, given that erythema and the moderate (II) to thick (III) hyperkeratosis provide visible and palpable evidence for the diagnosis (Figure 2b, c).<sup>27</sup> Although the diagnosis of AK is in many cases based on the different degree of the three clinical characteristics (erythema, hyperkeratosis, and scaling), the diagnosis may be challenging in some cases, especially if the lesion is pigmented. In these difficult cases, histology may assist in the differentiation of AK from other





**FIGURE 2** (a) Clinical AK classification according to Olsen. Olsen I manifests as a mild erythematous macule (arrow) on the right hand's dorsum. (b) For Olsen II, increasing erythema and keratosis (arrow) can be appreciated. (c) Olsen III is characterized by thick hyperkeratosis (asterisk).

diagnoses, such as Bowen's disease, seborrheic keratosis, or invasive SCC, due to clear histological characteristics.

## Histology and histological grading system

Histology represents the gold standard for the diagnosis of AK. Histologically, AK is defined by the mandatory keratinocyte atypia in the epidermis.<sup>3</sup> Keratinocyte atypia itself can be detected based on the morphological changes of keratinocyte nuclei, such as pleomorphism, hyperchromasia, and increased nuclear-to-cytoplasmic ratio.<sup>3</sup> Apart from the hyperplasia of atypical keratinocytes and the loss of cell polarity, crowding of basal keratinocytes in the epidermal layers can be identified.<sup>3</sup> Typically, the stratum corneum of the epidermis presents with vertically alternating layers of parahyperkeratosis and orthohyperkeratosis, while the epidermis may be atrophic or acanthotic. The subjacent papillary dermis may present with perivascular inflammation consisting of lymphocytes and plasma cells, while the dermal actinic elastosis is a key feature indicating the underlying UV exposure. AK may also be acantholytic or pigmented. Given that AK is *per definition* a precursor of invasive skin cancer in the form of carcinoma in situ, the integrity of the DEJ presents an important differentiating feature between AK and invasive SCC. Keratinocyte atypia is present in the whole lesion and usually arises from the basal epidermal layers spreading to the uppermost layers.<sup>21,22</sup> While the DEJ remains intact in AK lesions, the basal growth pattern may change during the transformation process to an invasive SCC resulting in epidermal undulation.<sup>28</sup> This undulation may be classified histologically based on the PRO score I–III introduced by Schmitz et al.<sup>28</sup> In summary, the horizontal upward-directed spreading of keratinocyte atypia can be classified by the Roewert-Huber classification, while the PRO score was established to categorize the degree of downward-directed proliferation.<sup>22,28</sup>

### Roewert-Huber classification

The histological grading system of Roewert-Huber evaluates the distribution of keratinocyte atypia originating from the basal cell layer and spreading upwards to the uppermost epidermal layers.<sup>22</sup> For classification of the degree of atypia, the epidermis is divided into three parts. This implies

that atypia dominating in the upper third is typical for the most advanced AK (AK I–III). While grade I atypia is limited to the basal third of the epidermis, grade II atypia is reaching the middle part of the epidermis, and grade III atypia can be observed also in the upper third beneath the stratum corneum of the epidermis. Accordingly, in AK III the whole epidermis presents with atypia.<sup>22</sup>

### PRO score classification

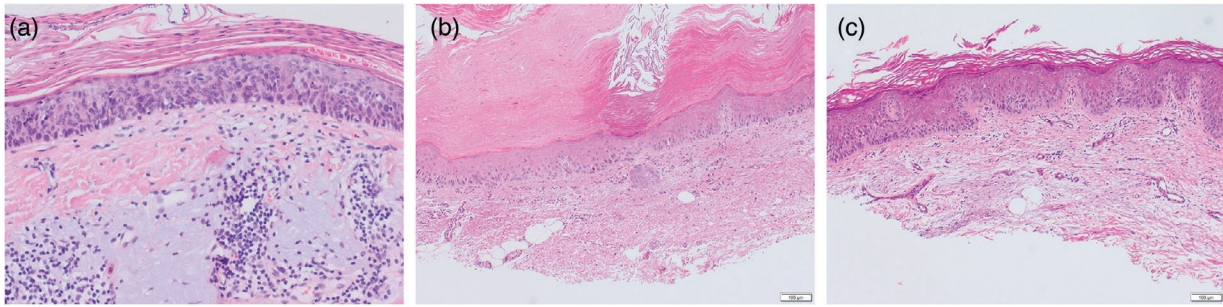
Histologically, the downward-directed proliferation of AK can be classified by PRO score I–III established by Schmitz et al.<sup>28</sup> The early stage of PRO I is characterized by *crowding* of atypical keratinocytes in the basal cell layer (Figure 3a). In PRO II, round nests have formed in the upper papillary dermis (*budding*) resulting in undulation of the basal epidermal layer (Figure 3b).<sup>28</sup> PRO III is characterized by proliferation of atypical keratinocytes forming epidermal buds that protrude into the dermis and exceed the thickness of the epidermis (*papillary sprouting*) (Figure 3c).<sup>28</sup>

Histologically, the downward-directed proliferation of AK can be classified by PRO score I–III.

## Non-invasive imaging techniques

### Optical coherence tomography

Optical coherence tomography (OCT) was originally developed in ophthalmology and is used as non-invasive diagnostic tool in dermatology since the late 1990s.<sup>29,30</sup> The only commercial OCT device currently available is the VivoSight® Dx (Michelson Diagnostics, Kent, United Kingdom) with a lateral resolution of < 7.5 μm and an axial resolution of 10 μm. The penetration depth into the skin is 1.5 to 2 mm. The 3D image has a size of 6 mm x 6 mm x 2 mm. Apart from the diagnosis of BCC, OCT is often used also for AK and facilitates, among others, the differentiation from SCC.<sup>3</sup> Friis et al. analyzed 16 studies on the diagnosis of AK by OCT.<sup>31</sup> Especially morphological criteria, such as disruption of epidermal cell layers (16/16), thickened epidermis (14/16), and evidence for hyperreflective epidermal morphology of streaks and dots (11/16), may facilitate the diagnosis of AK.<sup>31</sup> Additional diagnostic criteria include an



**FIGURE 3** Histological PRO score. PRO I is characterized by crowding of atypical keratinocytes, in the epidermal layer, but no epidermal undulation can be detected (a). For PRO II, the vertical extension of the DEJ protrusion into the papillary dermis does not exceed the thickness of the epidermal layer. For PRO III, the vertical extension of cone-like protrusions exceeds the thickness of the epidermal layer.

atypical honeycomb pattern and the preservation of the DEJ in the vertical OCT view.<sup>31</sup> Moreover, Schuh et al. could show that OCT enables the diagnosis of actinic keratosis, as well as its significant differentiation from BCC based on signal intensity and the respective differences in layer thickness of stratum corneum and epidermis.<sup>32</sup> Marneffe et al. suggested a suitable algorithm for the differentiation of healthy skin, AK, and SCC with high-definition OCT (HD-OCT), still available at the time, as follows: first, the integrity of the DEJ should be assessed. If the DEJ is intact, an invasive SCC can be largely excluded. The presence of AK can be verified based on the patterns mentioned above. The diagnosis of AK should be considered, in particular, if an atypical honeycomb pattern and an alternating sequence of hyperkeratosis and parakeratosis are observed.<sup>33</sup> Assessment of the adnexal structures in *en face* view with evidence of a cockade pattern allows for the exclusion of epithelial involvement of adnexal structures. When the cockade pattern is lost, however, involvement of the adnexal epithelium has to be assumed.<sup>33</sup> This is relevant, since AKs showing only basal atypia (Roewert-Huber AK I) but adnexal involvement often progress directly to an invasive SCC, without passing through the atypia stages AK II and III.<sup>21</sup> One study with OCT reported a diagnostic sensitivity of 100% for clinically apparent AKs and of 73% for subclinical AKs.<sup>34</sup> In dynamic OCT (D-OCT) that also allows for the visualization of blood flow by means of repetitive measurements of moving particles, *curved vessels* were found in AK at a penetration depth of 300  $\mu\text{m}$  in approximately 44% of the cases (versus 8.3% in Bowen's disease and 12.3% in SCC). This criterion seems to be particularly relevant for the differentiation from Bowen's disease, given that in Bowen's disease this vascular pattern is undetectable in 58% of the cases. At a depth of 500  $\mu\text{m}$ , the vascular pattern appears homogeneous and arranged in a reticular pattern (Table 1).<sup>35</sup>

### Line-field confocal optical coherence tomography

Line-field confocal optical coherence tomography (LC-OCT) is a non-invasive imaging tool developed from OCT. It

was developed by Arnaud Dubois in 2018 to detect early forms of skin cancer at cellular resolution.<sup>36</sup> The deepLive™ (DAMAE Medical, Paris, France) is the only LC-OCT device currently available. LC-OCT combines the benefits of OCT and confocal laser microscopy (CLM) with a high resolution of 1  $\mu\text{m}$  and a sufficient penetration depth of 500  $\mu\text{m}$ . It enables vertical, horizontal and 3D image visualization showing the morphological characteristics similar to histological tissue sections. The individual image section has a size of 1.2 mm x 0.5 mm in the horizontal and vertical view.

With LC-OCT, the PRO score in actinic keratosis can be determined in a non-invasive manner.

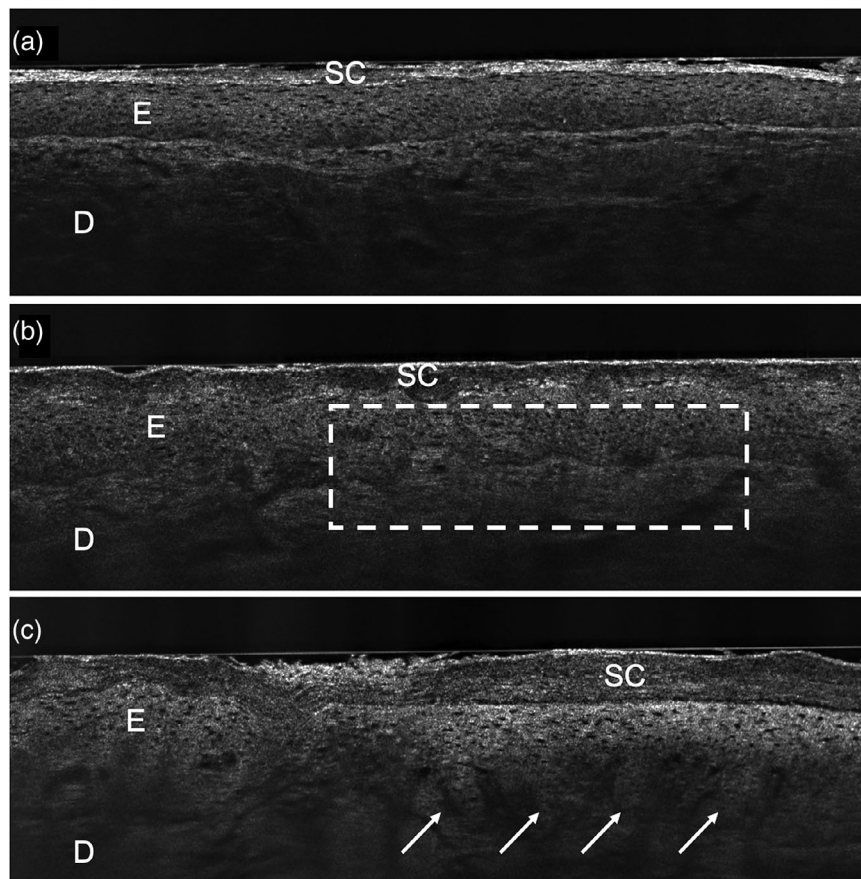
Since introduction of LC-OCT, numerous studies have assessed its use in clinical dermatology to visualize benign and malignant skin lesions like AK, BCC, Bowen's disease, and SCC. Furthermore, Ruini et al. discovered that LC-OCT succeeds in non-invasive assessment of DEJ in real time and thus in quantification of the PRO score (Figure 4a–c).<sup>37,38</sup> Due to their cellular resolution, LC-OCT images also correlate strongly with conventional histopathological sections.<sup>39</sup>

### Confocal laser microscopy

Similar to dermoscopy and OCT, confocal laser microscopy (CLM) can also be used for the diagnosis of AK and SCC in clinically ambiguous lesions.<sup>40</sup> The only device currently commercially available is the VivaScope® 1500 from the company Mavig (Munich, Germany). Individual images are only acquired horizontally and with a size of 750  $\mu\text{m}$  x 750  $\mu\text{m}$  up to a depth of approximately 200  $\mu\text{m}$ . They can be merged to mosaic pictures of 8 mm x 8 mm. Furthermore, there is the VivaScope® 3000 as manual device for more flexible, rapid acquisition. CLM can be used for the detection of subclinical AK lesions and field cancerization.<sup>40</sup> Typically, identification of AK in CLM is based on an atypical honeycomb pattern. A similar pattern can be observed in Bowen's disease. In squamous cell carcinomas, bright reflective horny structures are found in the papillary dermis. After application of topical or other therapies, regular polygonal

**TABLE 1** Overview on the morphological criteria, which allow to distinguish between the three entities: Bowen's disease, AK, SCC using (D-)OCT.<sup>31,33,35,93</sup>

	Bowen's disease	Actinic keratosis	Squamous cell carcinoma
Epidermis	Acanthosis	Acanthosis or atrophy, disrupted epidermal cell layers, hyperreflective pattern of dots and streaks	Hyperreflective tumor infiltrates, periadnexal epithelial infiltration
Dermal-epidermal junction zone	Intact	Intact	Not intact
Vessels	Normal vessel diameter	Normal vessel diameter	Increased vessel diameter
Vascular pattern	Oval or drop-like red structures (blobs)	Curved vessels, homogeneous reticular vascular structure	Disorganized and inhomogeneous vascular pattern without reticular pattern



**FIGURE 4** Visualization of the PRO score using LC-OCT. For (a) PRO I, no protrusion or DEJ undulation can be detected. For (b) PRO II, a slight DEJ undulation (square), and for (c) PRO III, cone-like protrusions (arrows) can be appreciated (LC-OCT, deepLive™, DAMAE Medical, Paris, France; image size: 1.2 × 0.5 mm<sup>2</sup>, lateral and axial resolution: 1.1 μm × 1.3 μm). *Abbr.*: SC, stratum corneum; E, epidermis; D, dermis

keratinocytes and a normalization of the honeycomb pattern are once again recognized.<sup>41–44</sup> A review on CLM found a sensitivity of 91%–100% for AK and of 100% for SCC.<sup>45</sup> For the diagnosis of AK, the epidermal pleomorphism of stratum spinosum and stratum granulosum was used as criterion for the highest sensitivity and specificity.<sup>46</sup>

### Therapy of actinic keratosis

Given that no clinically definite and lesion-specific risk factors for the malignant degeneration of AK have been identified yet, no consensus exists concerning the question

which AKs require therapy. The decision to start a therapy is made even more difficult by the fact that the estimated annual risk of malignant degeneration for each individual AK ranges from 0.03% to 20% and that 60% of SCCs are associated with a precursor AK.<sup>1,6,47</sup> On the other hand, spontaneous remission of AK can be observed in up to 60% of the cases.<sup>47</sup> Based on the results of Schmitz et al.<sup>23,25</sup> and Fernandez-Figueras et al.,<sup>21</sup> the watch-and-wait approach has been increasingly abandoned.<sup>3</sup> Schmitz et al. even state that each individual AK should be treated after diagnosis, given the inadequate predictability of the potential for malignant degeneration.<sup>22</sup> Numerous therapeutic options for the treatment of AK are available ranging from



topical therapies via physical treatment options, such as cryotherapy and light therapy, to ablative regimens. For the decision process of selecting the adequate treatment method for the respective AK, the German S3 guideline recommends the consideration of several secondary aspects, such as age, comorbidity, immunosuppression, number of AK lesions, *compliance* of the patient, and adherence to therapy.<sup>3</sup> With respect to available therapeutic options, lesion-directed treatment options and field-directed therapies targeting not only individual lesions but treating a larger affected anatomical area are distinguished. Accordingly, the latter option also allows for the treatment of subclinical lesions. Lesion-directed therapies include mechanically destructive procedures, such as deep *shave* excisions, curettage or surgical excisions, cryotherapy, and laser therapy, but also photodynamic therapy (PDT) and topical therapies like 5-fluorouracil 0.5% (5-FU) with salicylic acid 10% (Table 2).<sup>15</sup> Cryotherapy is an easy option to induce irreversible damage to cellular organelles or atypical keratinocytes in AK lesions by formation of ice crystals. For this purpose, liquid nitrogen ( $-196^{\circ}\text{C}$ ) is applied for at least two freeze-thaw cycles for 15–60 seconds to the lesions until whitish markings develop. While the therapy is effective due to the induced physical cell damage, it is not specific and, accordingly, will not protect the adjacent healthy skin from harm. A meta-analysis reported a successful treatment outcome free of recurrence in 68% of the cases.<sup>48,49</sup>

Refractory actinic keratoses must be classified as high-risk for malignant degeneration to SCC, given that they frequently exhibit aggressive basal proliferation patterns (PRO III) and a high degree of atypia (AK III).

PDT using 5-aminolevulinic acid (ALA) or the methyl ester methyl aminolevulinate (MAL) is similarly effective in treating individual AK lesions (Olsen I–II) or field cancerization. 5-aminolevulinic acid and MAL act as photosensitizers accumulating specifically in AK. As precursor of the endogenous heme biosynthesis pathway, ALA is converted into the photoactive protoporphyrin IX. During light exposure, reactive oxygen species are formed by photochemical and physical processes within precancerous keratinocytes resulting in DNA strand breaks and thus in induction of apoptosis. A red-light source or daylight can be used for light exposure. Recently published studies indicate that red-light PDT (RL-PDT) is significantly accompanied by hemodynamically relevant side effects like hypertension due to the more severe pain compared to the well-tolerated daylight PDT (DL-PDT).<sup>50</sup> Moreover, DL-PDT appears to be equivalent to RL-PDT in clinical effectiveness while causing less pain. Lacour et al. report a complete clearance rate of treated lesions of 74% for RL-PDT compared to 70% for DL-PDT.<sup>51</sup> With respect to the long-term effect over 24 weeks, Rubel et al. could also show an almost similarly high clearance rate of 96% for DL-PDT compared to 96.6% for RL-PDT.<sup>52</sup> A study performed by Garcia-Gil could demonstrate that DL-MAL-PDT performed at home can be implemented successfully,

if AK lesions are pretreated with 30% urea 7 days prior to therapy. After 3 and 12 months, complete clearance was observed in 47.7% ( $p < 0.001$ ) and 65.9% ( $p < 0.001$ ) of AK lesions, respectively, with the best response rate achieved for AK according to Olsen II and a significant reduction in AKASI score after 12 months.<sup>53</sup> Furthermore, the effectiveness of PDT can be increased by additional pretreatment of AK. Pretreatment can, for example, be performed by topical, systemic, or ablative procedures.<sup>54–56</sup> A study by Maytin et al. could show that the doses of accumulated photoactive protoporphyrins measured in skin biopsies were increased 2 to 3-fold compared to non-pretreated AKs after pretreatment of AKs with 5-FU for 6 days and subsequent exposure to MAL for three additional hours.<sup>55</sup> The subsequently performed RL-PDT achieved a significantly higher clearance rate after 3 and 6 months in pretreated AKs.<sup>55</sup> These results were also observed in other studies.<sup>57–61</sup> Imiquimod 5%/3.75% can also be combined successfully with ALA-PDT.<sup>56</sup> Application of topical retinoids (tazarotene gel 0.1%) twice daily for one week on the upper extremity with subsequent ALA-PDT resulted in significant reduction of more than 50% of treated AK lesions.<sup>62</sup> After pretreatment with adapalene gel 0.1%, ALA-PDT 10% could also achieve a significant reduction of AK lesions on dorsal hands and forearms.<sup>63</sup> Concerning the use of ALA-PDT it should be borne in mind that the treatment of AK on trunk, neck, and extremities is only approved as RL-PDT and that DL-ALA-PDT in these locations is performed in off-label use.

The topical application of vitamin D products (calcitriol/calcipotriol) was also shown to result in enrichment of photoactive protoporphyrins and to induce apoptosis in pretreated AKs, thus achieving a better therapeutic response.<sup>64</sup> Galimberti et al.<sup>65</sup> and Torezan et al.<sup>66</sup> achieved a significantly better therapeutic response for pretreated AKs treated subsequently with MAL-PDT. The combination of systemic therapeutics and combined PDT is an element of preclinical research. Preclinical studies with SCC cell cultures or mouse models have demonstrated a higher apoptosis rate in SCC cell lines or an increased cellular accumulation of protoporphyrins for administration of systemic therapeutics including vitamin D, methotrexate, and acitretin in combination with PDT.<sup>67–69</sup> Interestingly, it was shown that a therapeutic response, based on histological criteria, in AK after MAL-PDT is significantly correlated with increased serum vitamin D levels.<sup>69</sup> Apart from local and systemic combination therapies, PDT can also be combined with mechanical therapeutic procedures, especially to increase the ability of ALA/MAL to penetrate into the lesioned skin.<sup>70</sup> Suitable methods are, for example, ablative laser techniques that remove the uppermost physical skin barrier, the stratum corneum, and create microscopic vertical penetration channels in the epidermis.<sup>70</sup> In this context, the use of Er:YAG and CO<sub>2</sub> lasers in combination with ALA/MAL-PDT is particularly notable, given that this approach achieved a significant reduction of AK lesions and a lower recurrence rate in many application studies even

**TABLE 2** Overview of the different therapy regimens for actinic keratoses.

Therapy and mode of action	Grade (Olsen I–III)	Approach	Location/ max. treatment area (cm <sup>2</sup> )	Application	Field cancerization	Effectiveness (complete remission)
Imiquimod 5% (toll-like receptor 7 agonist)	I–II	F, L	Face, scalp ( $\leq 25$ cm <sup>2</sup> )	3 x/week for 4 weeks	x, approval for immunosuppressed patients restricted	53.7–55% <sup>94,95</sup>
Imiquimod 3.75% (toll-like receptor 7 agonist)	I–II	F	Face, scalp ( $\geq 25$ cm <sup>2</sup> )	1 x/day for 2 weeks, break of 2 weeks, 1 x/day for 2 weeks	x	34–35.6% <sup>96,97</sup>
Diclofenac sodium 3% in hyaluronic acid 2.5% gel (cyclooxygenase 2 inhibitor)	I–II	F	Face, scalp ( $\leq 25$ cm <sup>2</sup> )	2 x/day for 60–90 days	x	41% <sup>98</sup>
5-fluorouracil 5% cream (cytostatic)	I–II	F	Face, scalp	2 x/day for a maximum of 4 weeks	x	42.9–76.6% <sup>99</sup>
5-fluorouracil 0.5% with salicylic acid 10% in solution (cytostatic and keratolytic)	I–II	L, F	Face, scalp ( $\leq 25$ cm <sup>2</sup> )	1 x/day until clearance (maximum of 12 weeks)	x	47.5–57.8% <sup>100</sup>
5-fluorouracil 4% cream (cytostatic)	I–II	L	Face, scalp	1 x/day for a maximum of 4 weeks	x	80% <sup>101</sup>
1% tirbanibulin (spindle inhibitor)	I	L	Face, scalp ( $\leq 25$ cm <sup>2</sup> )	1 x/day for 5 days	x	49% <sup>102</sup>
8% ALA-PDT; 16% MAL-PDT (precursor of protoporphyrin (p) photosensitizer)	I–II	F, L	Face, scalp, extremities	Incubation for 3 h under light-protection bandage, then exposure to red light for 10–20 min; repetition in 4–12 weeks	x	69–93% (face, scalp) 44–80% (extremities) <sup>3</sup>

(Continues)



TABLE 2 (Continued)

Therapy and mode of action	Grade (Olsen I–III)	Approach	Location/ max. treatment area (cm <sup>2</sup> )	Application	Field cancerization	Effectiveness (complete remission)
DL-ALA/MAL–PDT (precursor of protoporphyrin (photosensitizer))		F, L	Face, scalp	Incubation for approx. 30 min, exposure to sun light for 2 h, repetition in 4–12 weeks	x	70–89% <sup>52,103</sup>
Surgical procedures	I–III	L	Face, scalp, trunk, extremities	Curettage, deep shave excision, or surgical excision		No data from RCTs
Cryosurgery	I–III	L	Face, scalp, trunk, extremities	1–2 freeze–thaw cycles with liquid nitrogen (–196°C) for 15–60 s (blanching)		39–76% <sup>3</sup>
Ablative laser methods (CO <sub>2</sub> laser, Erbium:YAG laser)	I–III	L	Face	Several settings, if necessary; depending on clinical response rate	x	72.4–91.91% <sup>3</sup>
Non-ablative laser methods (Nd:YAG laser, 1540 nm fractional laser)	I–III	L	Face	Several settings, if necessary; depending on clinical response rate		No data from RCTs
Chemical peelings (e. g., trichloroacetic acid)	I–III	F, L	Face, scalp		x	31.9% <sup>3</sup>

Abbr.: F, field-directed; L, lesion-directed; RCT, randomized controlled trial

in difficult-to-treat patients on immunosuppression.<sup>72–76</sup> In a meta-analysis by Pei et al.<sup>61</sup>, a significantly higher rate of completely cleared AKs was reported after application of ablative laser therapy in combination with PDT compared to PDT alone. However, this meta-analysis was given only a low evidence level. Similar therapeutic approaches for improving the penetration of ALA/MAL into lesioned skin are pretreatment of AK by microneedling or microdermabrasion to the dermis. Accumulation of protoporphyrins in lesioned skin and a significantly higher rate of completely cleared AK have been demonstrated for both procedures, while microdermabrasion resulted also in improvement of dyspigmentation and skin texture.<sup>77–82</sup> No superior effect was shown for microneedling using needles penetrating the epidermis only.<sup>83</sup>

The treatment of AK may also be performed with ablative laser techniques alone. This is particularly useful for treatment of individual AK Olsen I–III, but is also possible for treatment of field cancerization in immunocompetent individuals.<sup>3</sup> For this purpose, ablative lasers, such as 2940 nm Er:YAG laser or 10,600 nm CO<sub>2</sub> laser (scanned continuous wave), should be used.<sup>84</sup> As already mentioned, treatment of field cancerization with the fractional laser should be performed in combination with RL-PDT or DL-PDT. A fractional 10,600 nm CO<sub>2</sub> laser may also be implemented in off-label use for *laser-assisted drug delivery* (LAAD) to facilitate better penetration of a subsequent topical therapy, such as fluorouracil 5%.<sup>84</sup>

Surgical procedures for individual lesions include curettage, superficial shave excision, and simple surgical excision (Table 2). These procedures are usually restricted to individual AK lesions (Olsen I–III) and should be considered if SCC cannot be excluded with complete certainty by the clinical features.<sup>3</sup>

Field-directed therapeutic options include ALA-PDT and MAL-PDT, but also numerous topical therapies such as 5-fluorouracil (FU) 5%, diclofenac sodium 3%, and imiquimod 3.75% and 5%. Apart from 5-FU 5%, two new 5-FU formulations are currently available for the topical therapy of AK according to Olsen I–II (Table 2). 5-Fluorouracil cream 4% is applied once daily for 2 to 4 weeks and is superior to 5-FU cream 5% applied twice daily.<sup>85</sup> Another topical therapy is the 0.5% solution of 5-FU with 10% salicylic acid (5-FU-SA) that has also shown high effectiveness in field cancerization compared to placebo when applied for treatment of AK on face and scalp once daily for 12 weeks on a maximum treatment area of 25 cm<sup>2</sup>.<sup>86</sup> In a monocentric randomized phase III trial, low-dose 5-FU-SA was superior to 3% diclofenac gel in hyaluronic acid in terms of histological response rate (72% vs. 59.1%) and complete clinical clearance (55.4% vs. 32.0%).<sup>87</sup> Tirbanibulin 1%, a reversible tubulin polymerase inhibitor approved in 2021, is another topical therapy for the early stages of AK. Tirbanibulin inhibits Src tyrosine kinase signaling resulting in cell cycle inhibition during mitosis and thus apoptosis and triggering antiproliferative and antitumoral effects in AK lesions.<sup>88</sup> Tirbanibulin has been approved by the European Medicines

Agency (EMA) for the treatment of non-hyperkeratotic and non-hypertrophic AK (Olsen I) on the face and scalp. Tirbanibulin should be applied on intact skin of an AK lesion once daily for five consecutive days treating a maximum skin area of 25 cm<sup>2</sup>. The therapeutic effect can be assessed clinically 8 weeks after therapy start. If residuals remain, other therapeutic options should be considered, given that there is so far no evidence for the clinical efficacy of tirbanibulin for more than one cycle. The clinical effectiveness of tirbanibulin has been demonstrated in two identical double-blind phase III trials comprising 702 adults with 4–8 AK lesions on the face or scalp.<sup>89</sup> Adults using tirbanibulin as described had significantly higher complete (100%) response rates than those on placebo ( $p < 0.0001$ ) at day 57: 44% vs. 5% and 54% vs. 13%. Significantly higher treatment outcome rates for tirbanibulin compared to placebo were also identified for a partial response ( $\geq 75%$ ) at day 57: 68% vs. 16% and 76% vs. 20%. Effectiveness was found consistently in all examined subgroups including age, gender, AK number at treatment start, and skin type according to Fitzpatrick. After 1 year, recurrence was observed in 47% of the patients with complete (100%) clearance.

A meta-analysis conducted by Heppt et al. showed that tirbanibulin was superior to 3% diclofenac with respect to clearance of lesions and achieved outcomes similar to 5-FU 5%, 4% and 0.5% in combination with salicylic acid, imiquimod 3.75% and 5%, ALA-PDT and MAL-PDT, and cryotherapy.<sup>90</sup> Another new therapy currently in phase I/II is AVX001, a cytosolic phospholipase A<sub>2</sub> $\alpha$  (cPLA<sub>2</sub> $\alpha$ ) enzyme inhibitor, presenting a novel anti-inflammatory field-directed topical therapy.<sup>91</sup>

Although the mentioned therapeutic options show a good clinical effect, recurrence can be observed in up to 85% of the treated AK cases after 1 year of follow-up. Here the definition of recurrence probably also includes newly developed AKs.<sup>7</sup>

Thus, refractory AKs must also be considered high-risk for malignant degeneration to SCC, given that they frequently show aggressive basal proliferation patterns (PRO III) and a high degree of atypia (AK III).<sup>92</sup> Apart from the mentioned histological criteria, Schmitz et al. could retrospectively identify painfulness of AK as clinically independent predictor for refractory behavior of AK.<sup>92</sup> This clinical indicator may, therefore, be useful when selecting a suitable therapy and should also be considered during the follow-up of AK.

Currently, no topical therapeutics are approved for the treatment of actinic keratosis Olsen III.

The therapy of AK Olsen III presents another challenge, given that the topical therapeutics (Table 2) are only approved for AK Olsen I and II. In a cohort of 892 AKs histologically assessed by Schmitz et al.<sup>23</sup>, the proportion of AK Olsen III was only 11.3%. However, in this representative sample and with respect to the overall high prevalence of AK, this percentage of AK Olsen III seems to represent a quite significant subgroup with only limited treatment

options available. In general, AK Olsen III should, therefore, be treated by invasive surgical or ablative procedures such as cryotherapy or laser therapy in everyday clinical routine. Given the histological fact that AK Olsen III does not correlate with an enhanced risk of malignancy, these more invasive treatment regimens seem, therefore, not necessarily indicated. If an SCC cannot be excluded with complete certainty, surgical therapy with histological diagnostic workup should be chosen. Pretreatment of hyperkeratosis in AK Olsen III with keratolytic agents or by physical ablation may be helpful to achieve the desired treatment success. In addition, chemical peelings are available for treatment of AK Olsen III, although a satisfactory treatment effect is only achieved in approximately one third of the cases (Table 2).

## Outlook

The frequently chronic recurrent course of AK suggests that subclinical, histological criteria, such as basal atypia or high PRO score, play a role in malignant transformation or development of recurrence in AK. Since the invasiveness of punch biopsy largely prevents a follow-up of AK, non-invasive imaging methods like LC-OCT may avoid this dilemma and present a suitable instrument for early detection, risk stratification, monitoring during therapy, as well as follow-up and diagnosis of recurrence in the future.

## ACKNOWLEDGEMENT

Open access funding enabled and organized by Projekt DEAL.

## CONFLICT OF INTEREST STATEMENT

The authors are conducting a sponsored clinical phase IV trial with the title: "Line-field confocal optical coherence tomography (LC-OCT) for non-invasive imaging of epidermal changes, quantification (PRO score), monitoring of changes during treatment and recovery of actinic keratosis lesions under the treatment with Tirbanibulin (Klisyri®)" for the company Almirall S.A. J.T. has no other conflict of interest to declare. J.W. received consulting fees from Almirall and Janssen, lecture fees from Almirall, Novartis, Janssen, LEO Pharma, Boehringer-Ingelheim, BMS and a travel grant from Janssen. J.W. also holds the position of President of the German Dermatological Society. S.S. has no other conflict of interest to declare. The manuscript was created without any support of the pharma industry. The reported conflict of interest does not have any influence on the article's content.

## ORCID

Janis Raphael Thamm  <https://orcid.org/0000-0001-6205-7959>

Julia Welzel  <https://orcid.org/0000-0002-6099-7418>

Sandra Schuh  <https://orcid.org/0000-0002-1470-7619>

## REFERENCES

1. Marks R, Rennie G, Selwood TS. Malignant transformation of solar keratoses to squamous cell carcinoma. *Lancet*. 1988;1(8589):795-797.
2. Leiter U, Keim U, Eigentler T, et al. Incidence, Mortality, and Trends of Nonmelanoma Skin Cancer in Germany. *J Invest Dermatol*. 2017;137(9):1860-1867.
3. Heptt MV, Leiter U, Steeb T, et al. S3 guideline for actinic keratosis and cutaneous squamous cell carcinoma - short version, part 1: diagnosis, interventions for actinic keratoses, care structures and quality-of-care indicators. *J Dtsch Dermatol Ges*. 2020;18(3):275-294.
4. Yaldiz M. Prevalence of actinic keratosis in patients attending the dermatology outpatient clinic. *Medicine (Baltimore)*. 2019;98(28):e16465.
5. Foote JA, Harris RB, Giuliano AR, et al. Predictors for cutaneous basal- and squamous-cell carcinoma among actinically damaged adults. *Int J Cancer*. 2001;95(1):7-11.
6. Quaedvlieg PJ, Tirsi E, Thissen MR, Krekels GA. Actinic keratosis: how to differentiate the good from the bad ones? *Eur J Dermatol*. 2006;16(4):335-339.
7. Steeb T, Wessely A, Petzold A, et al. Long-term recurrence rates of actinic keratosis: A systematic review and pooled analysis of randomized controlled trials. *J Am Acad Dermatol*. 2022;86(5):1116-1119.
8. Lim HW, Collins SAB, Resneck JS, Jr., et al. The burden of skin disease in the United States. *J Am Acad Dermatol*. 2017;76(5):958-972 e2.
9. Kirby JS, Gregory T, Liu G, et al. Variation in the cost of managing actinic keratosis. *JAMA Dermatol*. 2017;153(4):264-269.
10. Queille S, Luron L, Spatz A, et al. Analysis of skin cancer risk factors in immunosuppressed renal transplant patients shows high levels of UV-specific tandem CC to TT mutations of the p53 gene. *Carcinogenesis*. 2007;28(3):724-731.
11. Ziegler A, Jonason AS, Leffell DJ, et al. Sunburn and p53 in the onset of skin cancer. *Nature*. 1994;372(6508):773-776.
12. Heerfordt IM, Nissen CV, Poulsen T, et al. Thickness of actinic keratosis does not predict dysplasia severity or P53 expression. *Sci Rep*. 2016;6:33952.
13. Schmitt J, Seidler A, Diepgen TL, Bauer A. Occupational ultraviolet light exposure increases the risk for the development of cutaneous squamous cell carcinoma: a systematic review and meta-analysis. *Br J Dermatol*. 2011;164(2):291-307.
14. Kramata P, Lu YP, Lou YR, et al. Patches of mutant p53-immunoreactive epidermal cells induced by chronic UVB irradiation harbor the same p53 mutations as squamous cell carcinomas in the skin of hairless SKH-1 mice. *Cancer Res*. 2005;65(9):3577-3585.
15. Schmitz L, Oster-Schmidt C, Stockfleth E. Nonmelanoma skin cancer - from actinic keratosis to cutaneous squamous cell carcinoma. *J Dtsch Dermatol Ges*. 2018;16(8):1002-1013.
16. Lee CS, Bhaduri A, Mah A, et al. Recurrent point mutations in the kinetochore gene KNSTRN in cutaneous squamous cell carcinoma. *Nat Genet*. 2014;46(10):1060-1062.
17. Hasche D, Akgul B. Role of human papillomavirus (HPV) in the development of skin cancer. *Hautarzt*. 2022;73(6):417-425.
18. Friman TK, Jaamaa-Holmberg S, Aberg F, et al. Cancer risk and mortality after solid organ transplantation: A population-based 30-year cohort study in Finland. *Int J Cancer*. 2022;150(11):1779-1791.
19. Rosales BM, De La Mata N, Vajdic CM, et al. Cancer mortality in kidney transplant recipients: An Australian and New Zealand population-based cohort study, 1980-2013. *Int J Cancer*. 2020;146(10):2703-2711.
20. Brewer JD, Habermann TM, Shanafelt TD. Lymphoma-associated skin cancer: incidence, natural history, and clinical management. *Int J Dermatol*. 2014;53(3):267-274.
21. Fernandez-Figueras MT, Carrato C, Saenz X, et al. Actinic keratosis with atypical basal cells (AK I) is the most common lesion associated with invasive squamous cell carcinoma of the skin. *J Eur Acad Dermatol Venereol*. 2015;29(5):991-997.



22. Rowert-Huber J, Patel MJ, Forschner T, et al. Actinic keratosis is an early in situ squamous cell carcinoma: a proposal for reclassification. *Br J Dermatol*. 2007;156(Suppl 3):8-12.
23. Schmitz L, Kahl P, Majores M, et al. Actinic keratosis: correlation between clinical and histological classification systems. *J Eur Acad Dermatol Venereol*. 2016;30(8):1303-1307.
24. Bakshi A, Shafi R, Nelson J, et al. The clinical course of actinic keratosis correlates with underlying molecular mechanisms. *Br J Dermatol*. 2020;182(4):995-1002.
25. Schmitz L, Gambichler T, Kost C, et al. Cutaneous squamous cell carcinomas are associated with basal proliferating actinic keratoses. *Br J Dermatol*. 2019;180(4):916-921.
26. Valdes-Morales KL, Peralta-Pedrero ML, Cruz FJ, Morales-Sanchez MA. Diagnostic accuracy of dermoscopy of actinic keratosis: a systematic review. *Dermatol Pract Concept*. 2020;10(4):e2020121.
27. Olsen EA, Abernethy ML, Kulp-Shorten C, et al. A double-blind, vehicle-controlled study evaluating masoprocol cream in the treatment of actinic keratoses on the head and neck. *J Am Acad Dermatol*. 1991;24(5Pt1):738-743.
28. Schmitz L, Gambichler T, Gupta G, et al. Actinic keratoses show variable histological basal growth patterns – a proposed classification adjustment. *J Eur Acad Dermatol Venereol*. 2018;32(5):745-751.
29. Huang D, Swanson EA, Lin CP, et al. Optical coherence tomography. *Science*. 1991;254(5035):1178-1181.
30. Welzel J, Lankenau E, Birngruber R, Engelhardt R. Optical coherence tomography of the human skin. *J Am Acad Dermatol*. 1997;37(6):958-963.
31. Friis KBE, Themstrup L, Jemec GBE. Optical coherence tomography in the diagnosis of actinic keratosis-A systematic review. *Photodiagnosis Photodyn Ther*. 2017;18:98-104.
32. Schuh S, Kaestle R, Sattler EC, Welzel J. Optical coherence tomography of actinic keratoses and basal cell carcinomas – differentiation by quantification of signal intensity and layer thickness. *J Eur Acad Dermatol Venereol*. 2016;30(8):1321-1326.
33. Marneffe A, Suppa M, Miyamoto M, et al. Validation of a diagnostic algorithm for the discrimination of actinic keratosis from normal skin and squamous cell carcinoma by means of high-definition optical coherence tomography. *Exp Dermatol*. 2016;25(9):684-687.
34. Markowitz O, Schwartz M, Feldman E, et al. Defining field cancerization of the skin using noninvasive optical coherence tomography imaging to detect and monitor actinic keratosis in ingenol mebutate 0.015 %-treated patients. *J Clin Aesthet Dermatol*. 2016;9(5):18-25.
35. Themstrup L, Pellacani G, Welzel J, et al. In vivo microvascular imaging of cutaneous actinic keratosis, Bowen's disease and squamous cell carcinoma using dynamic optical coherence tomography. *J Eur Acad Dermatol Venereol*. 2017;31(10):1655-1662.
36. Dubois A, Levecq O, Azimani H, et al. Line-field confocal optical coherence tomography for high-resolution noninvasive imaging of skin tumors. *J Biomed Opt*. 2018;23(10):1-9.
37. Ruini C, Schuh S, Gust C, et al. In-vivo LC-OCT evaluation of the downward proliferation pattern of keratinocytes in actinic keratosis in comparison with histology: first impressions from a pilot study. *Cancers (Basel)*. 2021;13(12).
38. Ruini C, Schuh S, Gust C, et al. Line-field confocal optical coherence tomography for the in vivo real-time diagnosis of different stages of keratinocyte skin cancer: a preliminary study. *J Eur Acad Dermatol Venereol*. 2021;35(12):2388-2397.
39. Chauvel-Picard J, Berot V, Tognetti L, et al. Line-field confocal optical coherence tomography as a tool for three-dimensional in vivo quantification of healthy epidermis: A pilot study. *J Biophotonics*. 2022;15(2):e202100236.
40. S1-Leitlinie: Konfokale Lasermikroskopie in der Dermatologie. 2017:013-76. Available from: <https://register.awmf.org/de/leitlinien/detail/013-076> [Last accessed November 27, 2023].
41. Malvehy J, Alarcon I, Montoya J, et al. Treatment monitoring of 0.5 % 5-fluorouracil and 10 % salicylic acid in clinical and subclinical actinic keratoses with the combination of optical coherence tomography and reflectance confocal microscopy. *J Eur Acad Dermatol Venereol*. 2016;30(2):258-265.
42. Malvehy J, Roldan-Marin R, Iglesias-Garcia P, et al. Monitoring treatment of field cancerisation with 3 % diclofenac sodium 2.5 % hyaluronic acid by reflectance confocal microscopy: a histologic correlation. *Acta Derm Venereol*. 2015;95(1):45-50.
43. Ulrich M, Alarcon I, Malvehy J, Puig S. In vivo reflectance confocal microscopy characterization of field-directed 5-fluorouracil 0.5 %/salicylic acid 10 % in actinic keratosis. *Dermatology*. 2015;230(3):193-198.
44. Ulrich M, von Braunmuehl T, Kurzen H, et al. The sensitivity and specificity of optical coherence tomography for the assisted diagnosis of nonpigmented basal cell carcinoma: an observational study. *Br J Dermatol*. 2015;173(2):428-435.
45. Nguyen KP, Peppelman M, Hoogedoorn L, et al. The current role of in vivo reflectance confocal microscopy within the continuum of actinic keratosis and squamous cell carcinoma: a systematic review. *Eur J Dermatol*. 2016;26(6):549-565.
46. Ulrich M, Maltusch A, Rius-Diaz F, et al. Clinical applicability of in vivo reflectance confocal microscopy for the diagnosis of actinic keratoses. *Dermatol Surg*. 2008;34(5):610-619.
47. Criscione VD, Weinstock MA, Naylor MF, et al. Actinic keratoses: Natural history and risk of malignant transformation in the Veterans Affairs Topical Tretinoin Chemoprevention Trial. *Cancer*. 2009;115(11):2523-2530.
48. Gupta AK, Paquet M, Villanueva E, Brintnell W. Interventions for actinic keratoses. *Cochrane Database Syst Rev*. 2012;12(12):CD004415.
49. Vegter S, Tolley K. A network meta-analysis of the relative efficacy of treatments for actinic keratosis of the face or scalp in Europe. *PLoS One*. 2014;9(6):e96829.
50. Hartmann J, Keller A, Enk A, Gholam P. Hemodynamic changes during conventional and daylight photodynamic therapy of actinic keratoses – a randomized controlled trial. *J Dermatolog Treat*. 2022;33(7):3022-3027.
51. Lacour JP, Ulrich C, Gilaberte Y, et al. Daylight photodynamic therapy with methyl aminolevulinate cream is effective and nearly painless in treating actinic keratoses: a randomised, investigator-blinded, controlled, phase III study throughout Europe. *J Eur Acad Dermatol Venereol*. 2015;29(12):2342-2348.
52. Rubel DM, Spelman L, Murrell DF, et al. Daylight photodynamic therapy with methyl aminolevulinate cream as a convenient, similarly effective, nearly painless alternative to conventional photodynamic therapy in actinic keratosis treatment: a randomized controlled trial. *Br J Dermatol*. 2014;171(5):1164-1171.
53. Garcia-Gil MF, Gracia-Cazana T, Cerro-Munoz P, et al. Fully home-based methyl aminolevulinate daylight photodynamic therapy for actinic keratosis of the face or scalp: A real life open study. *Dermatol Ther*. 2022;35(11):e15879.
54. Gilaberte Y, Moreno R, Juarraz A, Gonzalez S. Significant improvement of facial actinic keratoses after blue light photodynamic therapy with oral vitamin D pretreatment. *J Am Acad Dermatol*. 2022;87(5):e165.
55. Maytin EV, Anand S, Riha M, et al. 5-fluorouracil enhances protoporphyrin IX accumulation and lesion clearance during photodynamic therapy of actinic keratoses: a mechanism-based clinical trial. *Clin Cancer Res*. 2018;24(13):3026-3035.
56. Piaserico S, Mazzetto R, Sartor E, Bortoletti C. Combination-based strategies for the treatment of actinic keratoses with photodynamic therapy: an evidence-based review. *Pharmaceutics*. 2022;14(8):1726.
57. Gilbert DJ. Treatment of actinic keratoses with sequential combination of 5-fluorouracil and photodynamic therapy. *J Drugs Dermatol*. 2005;4(2):161-163.
58. Nissen CV, Heerfordt IM, Wiegell SR, et al. Pretreatment with 5-fluorouracil cream enhances the efficacy of daylight-mediated photodynamic therapy for actinic keratosis. *Acta Derm Venereol*. 2017;97(5):617-621.

59. Tyrrell JS, Morton C, Campbell SM, Curnow A. Comparison of protoporphyrin IX accumulation and destruction during methylaminolevulinic acid photodynamic therapy of skin tumours located at acral and nonacral sites. *Br J Dermatol*. 2011;164(6):1362-1368.
60. Tanghetti EA, Hamann C, Tanghetti M. A Controlled comparison study of topical fluorouracil 5 % cream pre-treatment of aminolevulinic acid/photodynamic therapy for actinic keratosis. *J Drugs Dermatol*. 2015;14(11):1241-1244.
61. Pei S, Kaminska ECN, Tsoukas MM. Treatment of actinic keratoses: a randomized split-site approach comparison of sequential 5-fluorouracil and 5-aminolevulinic acid photodynamic therapy to 5-aminolevulinic acid photodynamic monotherapy. *Dermatol Surg*. 2017;43(9):1170-1175.
62. Galitzer BI. Effect of retinoid pretreatment on outcomes of patients treated by photodynamic therapy for actinic keratosis of the hand and forearm. *J Drugs Dermatol*. 2011;10(10):1124-1132.
63. Galitzer BI. Photodynamic therapy for actinic keratoses of the upper extremities using 10 % aminolevulinic acid gel, red light, and adapalene pretreatment. *J Clin Aesthet Dermatol*. 2021;14(10):19-24.
64. Steeb T, Wessely A, Leiter U, et al. The more the better? An appraisal of combination therapies for actinic keratosis. *J Eur Acad Dermatol Venereol*. 2020;34(4):727-732.
65. Galimberti GN. Calcipotriol as pretreatment prior to daylight-mediated photodynamic therapy in patients with actinic keratosis: A case series. *Photodiagnosis Photodyn Ther*. 2018;21:172-175.
66. Torezan L, Grinblat B, Haedersdal M, et al. A randomized split-scalp study comparing calcipotriol-assisted methyl aminolevulinic acid photodynamic therapy (MAL-PDT) with conventional MAL-PDT for the treatment of actinic keratosis. *Br J Dermatol*. 2018;179(4):829-835.
67. Ye T, Jiang B, Chen B, et al. 5-aminolevulinic acid photodynamic therapy enhance the effect of acitretin on squamous cell carcinoma cells: An in vitro study. *Photodiagnosis Photodyn Ther*. 2020;31:101887.
68. Anand S, Honari G, Hasan T, et al. Low-dose methotrexate enhances aminolevulinic acid-based photodynamic therapy in skin carcinoma cells in vitro and in vivo. *Clin Cancer Res*. 2009;15(10):3333-3343.
69. Moreno R, Najera L, Mascaraque M, et al. Influence of serum vitamin D level in the response of actinic keratosis to photodynamic therapy with methylaminolevulinic acid. *J Clin Med*. 2020;9(2).
70. Desai P, Patlolla RR, Singh M. Interaction of nanoparticles and cell-penetrating peptides with skin for transdermal drug delivery. *Mol Membr Biol*. 2010;27(7):247-259.
71. Portugal I, Jain S, Severino P, Priefer R. Micro- and nano-based transdermal delivery systems of photosensitizing drugs for the treatment of cutaneous malignancies. *Pharmaceuticals (Basel)*. 2021;14(8):772.
72. Gellen E, Fidrus E, Janka E, et al. 5-Aminolevulinic acid photodynamic therapy with and without Er:YAG laser for actinic keratosis: Changes in immune infiltration. *Photodiagnosis Photodyn Ther*. 2019;26:270-276.
73. Togsverd-Bo K, Lei U, Erendsson AM, et al. Combination of ablative fractional laser and daylight-mediated photodynamic therapy for actinic keratosis in organ transplant recipients – a randomized controlled trial. *Br J Dermatol*. 2015;172(2):467-474.
74. Ko DY, Jeon SY, Kim KH, Song KH. Fractional erbium: YAG laser-assisted photodynamic therapy for facial actinic keratoses: a randomized, comparative, prospective study. *J Eur Acad Dermatol Venereol*. 2014;28(11):1529-1539.
75. Rizvi SM, Veierod MB, Mork G, et al. Ablative fractional laser-assisted daylight photodynamic therapy for actinic keratoses of the scalp and forehead in organ transplant recipients: a pilot study. *Acta Derm Venereol*. 2019;99(11):1047-1048.
76. Paasch U, Said T. Treating field cancerization by ablative fractional laser and indoor daylight: assessment of efficacy and tolerability. *J Drugs Dermatol*. 2020;19(4):425-427.
77. Wenande E, Phothong W, Bay C, et al. Efficacy and safety of daylight photodynamic therapy after tailored pretreatment with ablative fractional laser or microdermabrasion: a randomized, side-by-side, single-blind trial in patients with actinic keratosis and large-area field cancerization. *Br J Dermatol*. 2019;180(4):756-764.
78. Donnelly RF, Morrow DI, McCarron PA, et al. Microneedle-mediated intradermal delivery of 5-aminolevulinic acid: potential for enhanced topical photodynamic therapy. *J Control Release*. 2008;129(3):154-162.
79. Bay C, Lerche CM, Ferrick B, et al. Comparison of physical pretreatment regimens to enhance protoporphyrin IX uptake in photodynamic therapy: a randomized clinical trial. *JAMA Dermatol*. 2017;153(4):270-278.
80. Petukhova TA, Hassoun LA, Foolad N, et al. Effect of expedited microneedle-assisted photodynamic therapy for field treatment of actinic keratoses: a randomized clinical trial. *JAMA Dermatol*. 2017;153(7):637-643.
81. Spencer JM, Freeman SA. Microneedling Prior to Levulan PDT for the Treatment of Actinic Keratoses: A Split-Face, Blinded Trial. *J Drugs Dermatol*. 2016;15(9):1072-1074.
82. Chen J, Zhang Y, Wang P, et al. Plum-blossom needling promoted PpIX fluorescence intensity from 5-aminolevulinic acid in porcine skin model and patients with actinic keratosis. *Photodiagnosis Photodyn Ther*. 2016;15:182-190.
83. Lev-Tov H, Larsen L, Zackria R, et al. Microneedle-assisted incubation during aminolevulinic acid photodynamic therapy of actinic keratoses: a randomized controlled evaluator-blind trial. *Br J Dermatol*. 2017;176(2):543-545.
84. Paasch U, Zidane M, Baron JM, et al. S2k-Leitlinie: Lasertherapie der Haut. *J Dtsch Dermatol Ges*. 2022;20:1248-1270.
85. Dohil MA. Efficacy, safety, and tolerability of 4 % 5-fluorouracil cream in a novel patented aqueous cream containing peanut oil once daily compared with 5 % 5-fluorouracil cream twice daily: meeting the challenge in the treatment of actinic keratosis. *J Drugs Dermatol*. 2016;15(10):1218-1224.
86. Stockfleth E, von Kiedrowski R, Dominicus R, et al. Efficacy and safety of 5-fluorouracil 0.5 %/salicylic acid 10 % in the field-directed treatment of actinic keratosis: a phase III, randomized, double-blind, vehicle-controlled trial. *Dermatol Ther (Heidelb)*. 2017;7(1):81-96.
87. Stockfleth E, Kerl H, Zwingers T, Willers C. Low-dose 5-fluorouracil in combination with salicylic acid as a new lesion-directed option to treat topically actinic keratoses: histological and clinical study results. *Br J Dermatol*. 2011;165(5):1101-1108.
88. Schlesinger T, Stockfleth E, Grada A, Berman B. Tirbanibulin for actinic keratosis: insights into the mechanism of action. *Clin Cosmet Investig Dermatol*. 2022;15:2495-2506.
89. Blauvelt A, Kempers S, Lain E, et al. Phase 3 trials of tirbanibulin ointment for actinic keratosis. *N Engl J Med*. 2021;384(6):512-520.
90. Heppt MV, Dykukha I, Graziadio S, et al. Comparative efficacy and safety of tirbanibulin for actinic keratosis of the face and scalp in Europe: a systematic review and network meta-analysis of randomized controlled trials. *J Clin Med*. 2022;11(6):1654.
91. Ortner VK, Johansen B, Kilov K, et al. The Copenhagen Actinic Keratosis Study (COAKS). A decentralised clinical trial to evaluate tolerability, safety and efficacy of daily field-directed topical treatment with cytosolic phospholipase A(2) inhibitor, AVX001, in participants with actinic keratosis: protocol for a randomised controlled phase I/IIa trial. *BMJ Open*. 2022;12(10):e061012.
92. Schmitz L, Brehmer A, Falkenberg C, et al. Treatment-resistant actinic keratoses are characterized by distinct clinical and histological features. *Ital J Dermatol Venerol*. 2021;156(2):213-219.
93. Batz S, Wahrlich C, Alawi A, et al. Differentiation of different non-melanoma skin cancer types using OCT. *Skin Pharmacol Physiol*. 2018;31(5):238-245.
94. Alomar A, Bichel J, McRae S. Vehicle-controlled, randomized, double-blind study to assess safety and efficacy of imiquimod 5 % cream applied once daily 3 days per week in one or two courses of treatment of actinic keratoses on the head. *Br J Dermatol*. 2007;157(1):133-141.
95. Jorizzo J, Dinehart S, Matheson R, et al. Vehicle-controlled, double-blind, randomized study of imiquimod 5 % cream applied 3 days per

- week in one or two courses of treatment for actinic keratoses on the head. *J Am Acad Dermatol.* 2007;57(2):265-268.
96. Swanson N, Abramovits W, Berman B, et al. Imiquimod 2.5 % and 3.75 % for the treatment of actinic keratoses: results of two placebo-controlled studies of daily application to the face and balding scalp for two 2-week cycles. *J Am Acad Dermatol.* 2010;62(4):582-590.
  97. Hanke CW, Beer KR, Stockfleth E, et al. Imiquimod 2.5 % and 3.75 % for the treatment of actinic keratoses: results of two placebo-controlled studies of daily application to the face and balding scalp for two 3-week cycles. *J Am Acad Dermatol.* 2010;62(4):573-581.
  98. Iglesias-Puzas A, Batalla A, Suh-Oh HJ, Florez A. 0.5 % 5-fluorouracil/10 % salicylic acid for the treatment of distal actinic keratoses under daily practice conditions. *J Drugs Dermatol.* 2019;18(3):285-288.
  99. Dreno B, Cerio R, Dirschka T, et al. A novel actinic keratosis field assessment scale for grading actinic keratosis disease severity. *Acta Derm Venereol.* 2017;97(9):1108-1113.
  100. Wu Y, Tang N, Cai L, Li Q. Relative efficacy of 5-fluorouracil compared with other treatments among patients with actinic keratosis: A network meta-analysis. *Dermatol Ther.* 2019;32(3):e12822.
  101. Jansen MHE, Kessels J, Nelemans PJ, et al. Randomized trial of four treatment approaches for actinic keratosis. *N Engl J Med.* 2019;380(10):935-946.
  102. Kempers S, DuBois J, Forman S, et al. Tirbanibulin ointment 1 % as a novel treatment for actinic keratosis: phase 1 and 2 results. *J Drugs Dermatol.* 2020;19(11):1093-1100.
  103. Dianzani C, Conforti C, Giuffrida R, et al. Current therapies for actinic keratosis. *Int J Dermatol.* 2020;59:677-684.

**How to cite this article:** Thamm JR, Welzel J, Schuh S. Diagnosis and therapy of actinic keratosis. *JDDG: Journal der Deutschen Dermatologischen Gesellschaft.* 2024;1-14. <https://doi.org/10.1111/ddg.15288>



## CME QUESTIONS / LERNERFOLGSKONTROLLE

1. Welche Aussage zu aktinischen Keratosen (AK) trifft zu?
  - a. AK sind frühe dermale in-situ Plattenepithelkarzinome.
  - b. Sie werden als Vorstufen des Basalzellkarzinoms betrachtet.
  - c. 60% der Plattenepithelkarzinome gehen aus AK hervor.
  - d. AK Olsen III weisen ein hohes Risiko auf in ein invasives Plattenepithelkarzinom überzugehen.
  - e. AK manifestieren sich üblicherweise an Fußrücken und Fußsohlen sowie am Stamm.

---

2. Welcher Risikofaktor trägt **nicht** dazu bei, aktinische Keratosen zu entwickeln?
  - a. UV-Licht
  - b. Alter
  - c. Hauttyp (Fitzpatrick I und II)
  - d. Immunsuppression
  - e. Autoimmunerkrankung

---

3. Welche Aussage zu *TP53*-Mutationen bei aktinischen Keratosen trifft zu?
  - a. *TP53* ist ein Spindelgift.
  - b. Mutationen von *TP53* finden sich zu 70% bei Plattenepithelkarzinomen.
  - c. UVA-Strahlung führt zu *TP53*-Mutationen.
  - d. Die *TP53*-Mutation führt zur Umwandlung von Adenosin in Guanin.
  - e. *TP53*-Mutationen stimulieren die unkontrollierte Zellproliferation.

---

4. Immunsuppression spielt eine wesentliche Rolle bei der Entwicklung von Plattenepithelkarzinomen aus aktinischen Keratosen. Welche Aussage trifft hierzu **nicht** zu?
  - a. Mit der Dauer der Immunsuppression steigt die Inzidenz von nichtmelanozytärem Hautkrebs an.
  - b. Bei Organtransplantierten macht nichtmelanozytärer Hautkrebs circa die Hälfte aller Manifestationen von Krebs aus.
  - c. Nichtmelanozytärer Hautkrebs ist die Hauptursache für die Tumor-assoziierte Mortalität bei nierentransplantierten Patienten.
  - d. Bei immunsupprimierten Patienten liegt die Wahrscheinlichkeit des Auftretens von nichtmelanozytärem Hautkrebs bei 2 : 1.
  - e. Immunsupprimierte Patienten weisen eine höhere Progressionsrate von 30% der aktinischen Keratosen hin zu Plattenepithelkarzinomen auf.

---

5. Welche Aussage zur malignen Entartung von aktinischen Keratosen trifft zu?
  - a. Aktinische Keratosen Grad I (nach Röver-Huber) können auch direkt in ein Plattenepithelkarzinom fortschreiten.
  - b. Eine HPV-Kolonisation stellt einen wesentlichen Trigger zur Entartung von aktinischen Keratosen dar.
  - c. Aktinische Keratosen entwickeln sich mit zunehmender Atypie der Keratinozyten vom Stratum granulosum ausgehend bis zur dermoepidermalen Junktionszone in ein Plattenepithelkarzinom.
  - d. UV-Licht stellt das einzige Karzinogen für die Entwicklung von AK dar.
  - e. Das Risiko für die maligne Entartung einer aktinischen Keratose liegt bei 60%.

---

6. Aktinische Keratosen können verschieden klassifiziert werden. Welche Aussage zur PRO-Klassifikation trifft zu?
  - a. Dabei wird die Epidermis in drei Drittel geteilt.
  - b. Die PRO-Klassifikation beurteilt das Ausmaß der Abwärtsproliferation anhand der PRO-Scores I–III.
  - c. Sie wurde von Röver-Huber entwickelt.
  - d. PRO III beurteilt die Keratinozytenatypien im oberen Drittel unter der Hornschicht der Epidermis.
  - e. PRO I ist charakterisiert durch das Zusammendrängen von atypischen Keratinozyten im Stratum spinosum.

---

7. Welche der genannten bildgebenden Techniken ermöglicht die Quantifizierung des PRO-Scores von aktinischen Keratosen in vivo in Echtzeit?
  - a. Dermatoskopie
  - b. Optische Kohärenztomographie (OCT)
  - c. Konfokale Lasermikroskopie (KLM)
  - d. Line-Field konfokale Lasermikroskopie (LC-OCT)
  - e. Hochfrequenz-Ultraschall

---

8. Welche der Kombinationen aus diagnostischem Merkmal und nichtinvasivem bildgebenden Gerät trifft zu?
  - a. Erythematöses Pseudonetzwerk – konfokale Lasermikroskopie
  - b. Nachweis von hyperreflektiven Streifen und Punkten – Hochfrequenz-Ultraschall

- c. Atypisches Honigwabemuster – konventionelle optische Kohärenztomographie
  - d. Kurven-förmige Gefäße in 300 µm Tiefe – dynamische optische Kohärenztomographie
  - e. Verdickung der Epidermis – Dermatoskopie
- 
9. Welche Therapieoptionen kommen für die Feldkanzerisierung von aktinischen Keratosen **nicht** in Frage?
- a. Imiquimod
- 
- b. 5-Fluorouracil
  - c. PDT
  - d. Großflächige chirurgische Verfahren
  - e. Chemische Peelings
- 
10. Welche Kombination aus Wirkmechanismus und Therapie trifft zu?
- a. Imiquimod – Cyclooxygenase-2-Hemmer
  - b. 5-Fluorouracil – Vorstufe von Protoporphyrin
  - c. Diclofenac-Natrium – Toll-like-Rezeptor-7-Agonist
  - d. Tirbanibulin – Spindelgift
  - e. ALA-PDT – Zytostatikum

---

Liebe Leserinnen und Leser, der Einsendeschluss an die DDA für diese Ausgabe ist der 31. Juni 2024.

Die richtige Lösung zum Thema "Mikrozirkulationsstörungen der Haut" von Heft 2 2024 ist: 1b, 2c, 3e, 4d, 5a, 6c, 7a, 8c, 9a, 10b

Bitte verwenden Sie für Ihre Einsendung das aktuelle Formblatt auf der folgenden Seite oder aber geben Sie Ihre Lösung online unter <http://jddg.akademie-dda.de> ein.

---