

GUIDELINE

S3 guideline „actinic keratosis and cutaneous squamous cell carcinoma“ – update 2023, part 2: epidemiology and etiology, diagnostics, surgical and systemic treatment of cutaneous squamous cell carcinoma (cSCC), surveillance and prevention

Ulrike Leiter^{3,†} | **Markus V. Heppt^{1,2,†}** | **Theresa Steeb^{1,2}** | **Mareike Alter⁴** |
Teresa Amaral³ | **Andrea Bauer⁵** | **Falk G. Bechara⁶** | **Jürgen C. Becker⁷** |
Eckhard W. Breitbart⁸ | **Helmut Breuninger³** | **Thomas Diepgen⁹** | **Thomas Dirschka¹⁰** |
Thomas Eigentler¹¹ | **A. K. Stephan ElGammal¹²** | **Moritz Felcht^{13,14}** | **Michael J. Flaig¹⁵** |
Markus Follmann¹⁶ | **Klaus Fritz¹⁷** | **Stephan Grabbe¹⁸** | **Rüdiger Greinert¹⁹** |

†The first two authors and the last two have contributed equally to the manuscript.

Guidelines commissioned by: Dermatological Cooperative Oncology Group (DeCOG) (Arbeitsgemeinschaft Dermatologische Onkologie; ADO) of the German Cancer Society (DKG) and the German Society of Dermatology (Deutsche Dermatologische Gesellschaft; DDG)

Participating societies:

Arbeitsgemeinschaft Dermatologische Histologie (ADH)
 Arbeitsgemeinschaft Dermatologische Onkologie der DKG und DDG (ADO)
 Arbeitsgemeinschaft Dermatologische Prävention e.V. (ADP)
 Arbeitsgemeinschaft Gesundheitsökonomie und Evidenz-basierte Medizin der DDG (AGED)
 Arbeitsgemeinschaft Palliativmedizin in der DKG (APM)
 Arbeitsgemeinschaft Radiologische Onkologie (ARO)
 Arbeitsgemeinschaft Tumorklassifikation in der Onkologie der DKG (ATO)
 Arbeitsgemeinschaft Berufs- und Umweltdermatologie (ABD)
 Arbeitsgemeinschaft physikalische Diagnostik in der Dermatologie in der DDG (ApDD)
 Berufsverband der Deutschen Dermatologen e.V. (BVDD)
 Bundesverband Deutscher Pathologen e.V. (BDP)
 Deutsche Dermatologische Gesellschaft (DDG)
 Deutsche Gesellschaft der Plastischen, Rekonstruktiven und Ästhetischen Chirurgen (DGPRÄC)
 Deutsche Gesellschaft für Arbeitsmedizin und Umweltmedizin (DGAUM)
 Deutsche Gesellschaft für Chirurgie (DGCH)
 Deutsche Gesellschaft für Dermatochirurgie e.V. (DGDC)
 Deutsche Gesellschaft für HNO-Heilkunde, Kopf- und Hals-Chirurgie (DGHNOKHC)
 Deutsche Gesellschaft für Mund-, Kiefer- und Gesichtschirurgie (DGMKG)
 Deutsche Gesellschaft für Palliativmedizin (DGP)
 Deutsche Gesellschaft für Pathologie (DGPath)
 Deutsche Gesellschaft für Radioonkologie e.V. (DEGRO)
 Deutsche Gesellschaft für Ultraschall in der Medizin (DEGUM)
 Deutsche Röntgengesellschaft (DRG)
 Deutsche Gesetzliche Unfallversicherung (DGUV)
 Hautkrebsnetzwerk (Patientenvertretung)

The long version and the method report of the guideline can be found at www.awmf.org

Valid until 01/2028 or until next guideline update.

This is an open access article under the terms of the [Creative Commons Attribution-NonCommercial-NoDerivs](https://creativecommons.org/licenses/by-nc-nd/4.0/) License, which permits use and distribution in any medium, provided the original work is properly cited, the use is non-commercial and no modifications or adaptations are made.

© 2023 The Authors. Journal der Deutschen Dermatologischen Gesellschaft published by Wiley-VCH GmbH on behalf of Deutsche Dermatologische Gesellschaft.

Ralf Gutzmer⁴ | Axel Hauschild²⁰ | Uwe Hillen²¹ | Stephan Ihler²² |
Swen Malte John²³ | Lukas Kofler²⁴ | Oliver Koelbl²⁵ | Albrecht Krause-Bergmann²⁶ |
Klaus Kraywinkel²⁷ | Steffen Krohn²⁸ | Thomas Langer¹⁶ | Carmen Loquai²⁹ |
Christoph R. Löser³⁰ | Peter Mohr¹⁹ | Dorothée Nashan³¹ | Monika Nothacker³² |
Christina Pfannenberger³³ | Carmen Salavastru³⁴ | Lutz Schmitz¹⁰ | Eggert Stockfleth⁶ |
Rolf-Markus Szeimies³⁵ | Claas Ulrich³⁶ | Susanne Voelter-Mahlknecht³⁷ |
Dirk Vordermark³⁸ | Michael Weichenthal²⁰ | Julia Welzel³⁹ | Kai Wermker⁴⁰ |
Susanne Wiegand⁴¹ | Claus Garbe^{3,†} | Carola Berking^{1,2,†}

Correspondence

Ulrike Leiter, MD, PhD, University Department of Dermatocology, Eberhard-Karls-Universität, Liebermeisterstrasse 25, 72076 Tübingen, Germany.
Email: ulrike.leiter@med.uni-tuebingen.de

Summary

Actinic keratosis (AK) are common lesions in light-skinned individuals that can potentially progress to cutaneous squamous cell carcinoma (cSCC). Both conditions may be associated with significant morbidity and constitute a major disease burden, especially among the elderly. To establish an evidence-based framework for clinical decision making, the guideline “actinic keratosis and cutaneous squamous cell carcinoma” was updated and expanded by the topics cutaneous squamous cell carcinoma in situ (Bowen’s disease) and actinic cheilitis. The guideline is aimed at dermatologists, general practitioners, ear nose and throat specialists, surgeons, oncologists, radiologists and radiation oncologists in hospitals and office-based settings, as well as other medical specialties, policy makers and insurance funds involved in the diagnosis and treatment of patients with AK and cSCC. A separate guideline exists for patients and their relatives. In this part, we will address aspects relating to epidemiology and etiology, diagnostics, surgical and systemic treatment of cutaneous squamous cell carcinoma (cSCC), surveillance and prevention.

INTRODUCTION

The guideline represents a short version of the complete guideline available at www.awmf.org. Information on the treatment of actinic keratosis, actinic cheilitis, cutaneous squamous cell carcinoma in situ (Bowen’s disease), occupational disease and structures of care can be found in part 1 of the short version – update 2023 of the guideline or in the long version. A full list of references and the analysis of evidence underlying the recommendations and statements, along with the conflicts of interest of the authors involved in the present guideline, are available in the long version and in the guideline report. The guideline is an update of the previous version published in 2020.^{1,2}

METHODOLOGY

See long version at www.awmf.org.

EPIDEMIOLOGY AND ETIOLOGY

Epidemiology of actinic keratosis and squamous cell carcinoma

See long version at www.awmf.org.

Mortality

See long version at www.awmf.org.

Risk factor immunosuppression

See long version at www.awmf.org.

Prognostic factors for the transition from actinic keratosis to invasive squamous cell carcinoma

See long version at www.awmf.org.

Consensus-based statement**Modified 2022**

- EC** The data situation for reliable prognostic factors of the transition from AK to SCC is insufficient. At the moment, no reliable values for the probability of progression can be given. The following clinical factors are prognostically unfavorable:
- Immunosuppression
 - Therapy resistance
 - Field cancerization

Strong consensus

Abbr.: EC, expert consensus

Consensus-based statement**Modified 2022**

- EC** Existing clinical and histologic systems (e.g., classification according to Olsen, graduation into keratinocytic intraepidermal neoplasia 1–3, counting of lesions) are not sufficiently validated prognostically and thus dispensable in clinical practice.

Consensus

Prognostic factors for metastasis in invasive squamous cell carcinoma

See long version at www.awmf.org.**Evidence-based statement****Checked 2022**

- LoE 4** Histopathologic factors (tumor infiltration depth to be determined vertically, desmoplasia, degree of differentiation, perineural growth) and clinical factors (localization, horizontal tumor diameter, comorbidities such as immunosuppression) are considered prognostic factors for metastasis or disease-specific survival.

4: *De novo* research

Strong consensus

Abbr.: LoE, level of evidence

DIAGNOSTICS

Classification, definition and nomenclature of actinic keratosis

See long version at www.awmf.org.**Consensus-based recommendation****Checked 2022**

- EC** The term “actinic keratosis” shall be used.

Strong consensus

Evidence-based statement**New 2022**

- LoE 2** Multiple qualitative and quantitative factor integrating scores (e.g., AK-FAS, AKASI) improve standardized reporting of findings for actinic keratosis.

2: *De novo* research

Strong consensus

Classification, definition und nomenclature of actinic cheilitis

See long version at www.awmf.org.**Consensus-based statement****New 2022**

- EC** Actinic cheilitis is etiologically and morphologically the counterpart of actinic keratosis of the keratinizing squamous epithelium of the skin at the red of the lips.

Strong consensus

Consensus-based statement**Checked 2022**

- EC** Bowen's disease is defined as an intraepidermal proliferation of highly atypical and polymorphic keratinocytes occupying the entire width of the epidermis. In this respect, Bowen's disease represents a special variant, which can progress into an invasive, then usually bowenoid differentiated (pleomorphic, low differentiated) squamous cell carcinoma (Bowen carcinoma).

Strong consensus

Classification, definition und nomenclature of invasive squamous cell carcinoma

See long version at www.awmf.org.**Consensus-based statement****Checked 2022**

- EC** Squamous cell carcinoma of the skin is a malignant neoplasm of the keratinocytes of the epidermis. The tumors can develop different degrees of differentiation (see also WHO/UICC classification).

Strong consensus

Consensus-based statement**Checked 2022**

- EC** Squamous cell carcinoma of the skin arises in most cases, but not necessarily, from intraepidermal proliferation of atypical keratinocytes.

Strong consensus

Consensus-based statement**Checked 2022**

- EC** Invasive squamous cell carcinoma of the skin is said to occur when there is histomorphologically demonstrable disruption of the basement membrane beneath an intraepithelial keratinocytic proliferation in no traumatized skin.

Consensus

Consensus-based statement**Checked 2022**

- EC** The following variants of squamous cell carcinoma of the skin can be distinguished histomorphologically (some of these are reflected in the WHO/UICC classification):
- adenosquamous squamous cell carcinoma of the skin
 - acantholytic (adenoid, pseudoglandular) squamous cell carcinoma of the skin
 - Bowen's carcinoma/ bowenoid differentiated squamous cell carcinoma of the skin
 - desmoplastic squamous cell carcinoma of the skin
 - keratoacanthoma-like squamous cell carcinoma of the skin/keratoacanthoma
 - lymphoepithelioma-like squamous cell carcinoma of the skin
 - pseudovascular (pseudoangiosarcomatous, pseudoangiomatous) squamous cell carcinoma of the skin
 - spindle cell (sarcomatoid) squamous cell carcinoma of the skin
 - verrucous squamous cell carcinoma of the skin (epithelioma cuniculatum)

Strong consensus

Consensus-based statement**Checked 2022**

- EC** Classification of squamous cell carcinoma of the skin should be based on histologic and clinical parameters according to the currently used TNM systems of the UICC or AJCC.

Strong consensus

For classification, the WHO/UICC/AJCC classification can be used. This is particularly useful for clinically very large SCC (Table 1, 2).

Field cancerization

See long version at www.awmf.org.

Consensus-based statement**Checked 2022**

- EC** A generally accepted definition of field carcinization does not exist. Field carcinization includes an area of skin with multiple actinic keratoses surrounded by visible UV-related skin damage.

Strong consensus

Importance of non-invasive diagnostic procedures

See long version at www.awmf.org.

Consensus-based statement**Checked 2022**

- EC** Diagnosis is made by clinical examination and inspection.

Strong consensus

Consensus-based recommendation**Checked 2022**

- EC** Dermatoscopy, confocal laser microscopy, and optical coherence tomography may be used to diagnose actinic keratosis and squamous cell carcinoma of the skin when findings are clinically unclear.

Strong consensus

Histologic diagnosis

See long version at www.awmf.org.

Consensus-based statement**Checked 2022**

- EC** Actinic keratosis does not require histologic diagnosis if typical clinical findings are present.

Strong consensus

Consensus-based recommendation**Checked 2022**

- EC** In case of resistance to therapy and clinically unclear findings, a tissue sample shall be obtained.

Strong consensus

Consensus-based recommendation**Modified 2022**

- EC** If squamous cell carcinoma of the skin, actinic cheilitis or Bowen's disease is clinically suspected, histology shall also be obtained to differentiate other benign or malignant neoplasia. Preoperatively, the maximum diameter of the neoplasia should be documented for squamous cell carcinoma of the skin and Bowen's disease.

Consensus

Consensus-based statement**Checked 2022**

- EC** Depending on the clinical situation, punch biopsies, shallow ablations ("shave" excisions), or excisional biopsies are appropriate.

Consensus

Consensus-based recommendation**Checked 2022**

- EC** If the clinical picture is clear for squamous cell carcinoma of the skin, complete resection may be performed without prior probing biopsy.

Consensus

Parameters of the histological report

See long version at www.awmf.org.

Consensus-based recommendation**Checked 2022**

- EC** The following histomorphologic variants should be designated when present:
- atrophic
 - hypertrophic
 - acantholytic
 - pigmented
 - lichenoid
 - bowenoid
 - actinic keratosis.

Strong consensus

TABLE 1 TNM classification of SCC of the skin for the labial skin (excluding labial red), trunk, upper extremities and shoulders, lower extremities, and hip and scrotum (8th edition, 2017).

TNM classification			
T category			
TX	Primary tumor cannot be assessed		
T0	No evidence of primary tumor		
Tis	Carcinoma in situ		
T1	Tumor 2 cm or less in greatest extension		
T2	Tumor more than 2 cm but not more than 4 cm in greatest extent		
T3	Tumor more than 4 cm in greatest extent or superficial bone invasion or perineural invasion (PNI) or deep invasion*		
T4a	Tumor with macroscopic bone invasion/ bone marrow invasion		
T4b	Tumor with invasion of the axial skeleton including foramina and/or involvement of the vertebral foramen up to the epidural space		
*“deep invasion“ is defined as invasion beyond the subcutaneous fat or >6 mm (measured from the stratum granulosum of the adjacent epidermis to the base of the tumor).			
Perineural invasion as a criterion for T3 is defined as clinical or radiologic involvement of nameable nerves without involvement of the foramina or skull base.			
In the case of multiple simultaneous tumors, the tumor with the highest T category is classified and the number of delineable tumors is indicated in parentheses, e.g., T2(5).			
N category			
NX	Regional lymph nodes cannot be evaluated		
N0	No regional lymph node metastases		
N1	Metastasis(s) in a regional lymph node, 3 cm or less in greatest extent		
N2	Metastasis(s) in one lymph node, more than 3 cm but not more than 6 cm in greatest extent or in multiple lymph nodes, none more than 6 cm in greatest extent		
N3	Metastasis(s) in one lymph node more than 6 cm in greatest extent		
M category			
M0	No distant metastases		
M1	Distant metastases		
Stage classification			
Stage 0	Tis	N0	M0
Stage I	T1	N0	M0
Stage II	T2	N0	M0
Stage III	T3	N0	M0
	T1, T2, T3	N1	M0
Stage IV	T1, T2, T3	N2, N3	M0
	T4	Any N	M0
	Any T	Any N	M1

Consensus-based recommendation

Checked 2022

- EC** The histologic report of squamous cell carcinoma of the skin shall include the following in addition to the diagnosis:
- histological tumor type (for specific subtypes of squamous cell carcinoma of the skin)
 - description of the histological depth extension in relation to the anatomical stratification (especially from level V, corresponding to infiltration of the subcutis)
 - measurement of the depth extension from an invasion depth of 2 mm (corresponds approximately to the diameter of a 10x field of view)
 - in the positive case, indication of the presence of perineural spread, vascular invasion or low differentiation
 - completeness of resection of the invasive tumor portion

Strong consensus

Diagnosis of spread in invasive squamous cell carcinoma

See long version at www.awmf.org.

Consensus-based recommendation

Checked 2022

- EC** If the presence of squamous cell carcinoma of the skin is suspected, the initial examination shall include inspection of the entire skin organ.

Strong consensus

TABLE 2 TNM classification of SCC of the head and neck according to AJCC/UICC (8th edition, 2017).

T category			
TX	Primary tumor cannot be assessed		
T0	No evidence of primary tumor		
Tis	Carcinoma in situ		
T1	Tumor 2 cm or less in greatest extension		
T2	Tumor more than 2 cm but not more than 4 cm in greatest extent		
T3	Tumor more than 4 cm in greatest extent or superficial bone invasion or perineural invasion or deep invasion*		
T4a	Tumor with macroscopic bone invasion/ bone marrow invasion		
T4b	Tumor with invasion of the axial skeleton including foramina and/or involvement of the vertebral foramen up to the epidural space		
*“deep invasion“ is defined as invasion beyond the subcutaneous fat or >6 mm (measured from the stratum granulosum of the adjacent epidermis to the base of the tumor) Perineural invasion as a criterion for T3 is defined as clinical or radiologic involvement of named nerves without involvement of the foramina or skull base.			
N category (clinical)			
N0	No regional lymph node metastases		
N1	Metastasis(s) in a regional lymph node, 3 cm or less in greatest extent		
N2	Metastasis(s) as described below:		
N2a	Metastasis(s) in solitary ipsilateral lymph node, more than 3 cm but not more than 6 cm in greatest extent, without extra nodal spread		
N2b	Metastases in multiple ipsilateral lymph nodes, none more than 6 cm in greatest extent, without extra nodal spread		
N2c	Metastases in bilateral or contralateral lymph nodes, none more than 6 cm in greatest extent, without extra nodal spread		
N3a	Metastasis(s) in one lymph node, more than 6 cm in greatest extent, without extra nodal spread		
N3b	Metastasis(s) in a single or multiple lymph nodes, clinically in extra nodal spread*		
*The presence of skin or soft tissue involvement (invasion) or clinical signs of nerve involvement is considered clinical extra nodal spread.			
N category (pathological)			
pN0	No regional lymph node metastases		
pN1	Metastasis(s) in solitary ipsilateral lymph node, 3 cm or less in greatest extent, without extra nodal spread		
pN2	Metastasis(es) as described below:		
pN2a	Metastasis(s) in solitary ipsilateral lymph node, 3 cm or less in greatest extent, with extra nodal spread or more than 3 cm but not more than 6 cm in greatest extent, without extra nodal spread		
pN2b	Metastases in multiple ipsilateral lymph nodes, none more than 6 cm in greatest extent, without extra nodal spread		
pN2c	Metastases in bilateral or contralateral lymph nodes, none more than 6 cm in greatest extent, without extra nodal spread		
pN3a	Metastasis(s) in one lymph node, more than 6 cm in greatest dimension, without extra nodal spread		
pN3b	Metastasis(s) in one lymph node more than 3 cm in greatest extent with extra nodal spread or in multiple ipsilateral, contralateral or bilateral lymph nodes with extra nodal spread		
M category			
M0	No distant metastases		
M1	Distant metastases		
The pT categories correspond to the T categories. pM1 means that distant metastases were confirmed microscopically.			
Stage classification			
Stage 0	Tis	N0	M0
Stage I	T1	N0	M0
Stage II	T2	N0	M0
Stage III	T3	N0	M0
	T1, T2, T3	N1	M0
Stage IV	T1, T2, T3	N2, N3	M0
	T4	Any N	M0
	Any T	Any N	M1

Abbreviations/ Legends:

MCS: Micrographically controlled surgery
 SCC: Squamous cell carcinoma

↓ should follow

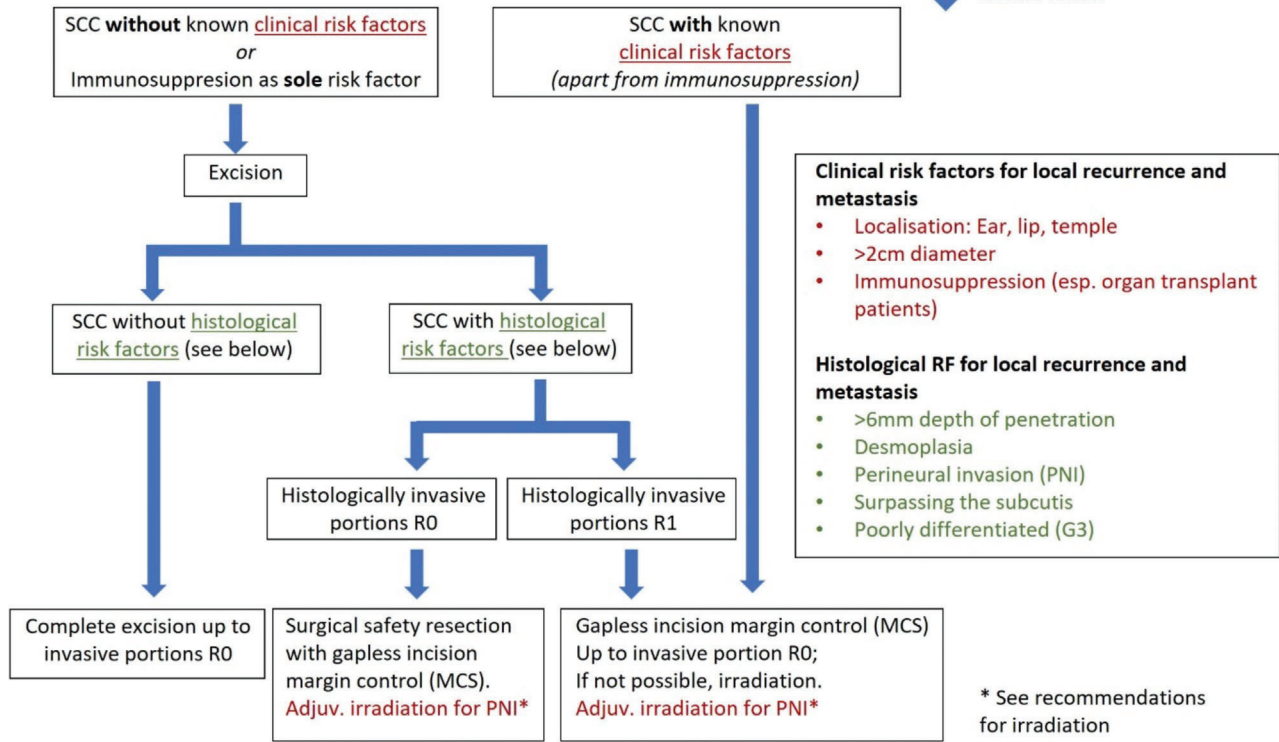


FIGURE 1 Algorithm surgical therapy.

SURGICAL AND SYSTEMIC TREATMENT OF CUTANEOUS SQUAMOUS CELL CARCINOMA

Surgical therapy of the primary tumor

Consensus-based recommendation	Checked 2022
EC Locoregional lymph node ultrasonography shall be performed when locoregional metastases are suspected. Locoregional lymph node ultrasonography should be performed when risk factors are present.	
Consensus	
Consensus-based recommendation	Checked 2022
EC X-ray thoracic examination shall not be performed as a standard of care when locoregional or distant metastasis of squamous cell carcinoma of the skin is suspected or demonstrated.	
Consensus	
Consensus-based recommendation	checked 2022
EC Abdominal ultrasonography shall not be performed as a standard of care when locoregional or distant metastasis of squamous cell carcinoma of the skin is suspected or demonstrated.	
Strong consensus	
Consensus-based recommendation	Checked 2022
EC If metastasis is suspected, cross-sectional imaging shall be performed.	
Strong consensus	

Consensus-based recommendation	New 2022
EC The following risk factors of SCC shall be reported to the examining pathologist/dermatopathologist if present: recurrence, tumor diameter > 2 cm, localization ear, lip or temple, immunosuppression and evidence of perineural invasion, no displaceability from the subsurface.	
Strong consensus	
Consensus-based recommendation	New 2022
EC Surgical therapy of the primary tumor shall be performed according to the following algorithm (Figure 1).	
Strong consensus	

Although there is no doubt in the literature that surgical excision of squamous cell carcinoma of the skin is the method of choice, there is little consensus for the exact design of the excision and subsequent histologic examination. Detailed information on surgical excision of SCC is provided in the long version of the guideline. Figure 1 shows the algorithm for surgical therapy of the primary tumor.

Operative procedure after R0 resection

See long version at www.awmf.org.

Consensus-based recommendation	Checked 2022
EC As long as an R0 resection has not been histologically confirmed, wound closure shall only be performed if the resection wheels can be clearly assigned postoperatively (e.g., no displacement flaps).	
Strong consensus	

Sentinel lymph node biopsy

See long version at www.awmf.org.

Evidence-based statement	Checked 2022
LoE 3 There are no valid data on the prognostic and therapeutic value of SLNB.	
3: <i>De novo</i> research	
Strong consensus	

Prophylactic and therapeutic lymphadenectomy

See long version at www.awmf.org.

Evidence-based recommendation	Checked 2022
GoR A Prophylactic lymphadenectomy shall not be performed	
LoE 3	
Strong consensus	

Abbr.: GoR, grades of recommendation

Evidence-based statement	Checked 2022
LoE 3 There are insufficient data on the value of regional lymphadenectomy in the setting of a positive sentinel lymph node biopsy.	
Strong consensus	

Evidence-based recommendation	Checked 2022
GoR B Regional (therapeutic) lymphadenectomy should be performed when lymph node metastasis is clinically manifest.	
LoE 3	
Strong consensus	

Evidence-based statement	Checked 2022
LoE 3 Improvement in locoregional tumor control has been described for regional therapeutic lymphadenectomy for nodal metastasis.	
Strong consensus	

Lymphadenectomy in the head and neck region

See long version at www.awmf.org.

Evidence-based statement	Checked 2022
LoE 3 In the head and neck region, there is no general consensus on the level of dissection required.	
Strong consensus	

Adjuvant and postoperative Radiotherapy

See long version at www.awmf.org.

Evidence-based recommendation	Checked 2022
GoR B For tumors that are not locally resectable in sano or inoperable patients, radiotherapy should be performed.	
LoE 3 3: <i>De novo</i> research	
Strong consensus	

Evidence-based recommendation	Checked 2022
GoR B Postoperative radiotherapy should be performed for: R1 or R2 resection (if post resection is not possible) Extensive lymph node involvement (> 1 affected lymph node, lymph node metastasis > 3 cm, capsule rupture) Intraparotid lymph node involvement	
LoE 2 2: <i>De novo</i> research	
Strong consensus	

Evidence-based recommendation	Modified 2022
GoR B Adjuvant radiotherapy should be performed in the presence of extensive perineural sheath infiltration (PNI).	
LoE 2 2: <i>De novo</i> research	
Strong consensus	

Evidence-based recommendation	Modified 2022
GoR 0 Adjuvant radiotherapy may be considered if the resection margin is narrow.	
LoE 2 2: <i>De novo</i> research	
Strong consensus	

Evidence-based statement	New 2022
LoE 2 Current data do not support a recommendation for combining adjuvant radiotherapy with system therapy.	
2: <i>De novo</i> research	
Strong consensus	

Therapy of the local or loco-regional recurrence

See long version at www.awmf.org.

Consensus-based recommendation	Checked 2022
EK Locoregional recurrence shall be surgically removed if clinically locally possible.	
Strong consensus	

Evidence-based recommendation	Checked 2022
GoR A Micrographically controlled surgery (MCS) shall be performed.	
LoE 2 2: <i>De novo</i> research	
Strong consensus	

Evidence-based recommendation	Checked 2022
GoR B If a R1 or R2 situation that cannot be further resected arises during the course of resection, postoperative radiotherapy should be performed at the R1 or R2 localization.	
LoE 2 2: <i>De novo</i> research	
Strong consensus	

Evidence-based recommendation	Checked 2022
GoR B In case of interdisciplinary determination of inoperability, radiotherapy should be performed.	
LoE 3 3: <i>De novo</i> research	
Strong consensus	

Consensus-based recommendation	Checked 2022
EC For therapy of local or locoregional recurrence, the indication for electrochemotherapy or systems therapy should be considered if surgical or radiotherapeutic options are not available.	
Consensus	

Therapy in the advanced (locally advanced or metastasized) stage

See long version at www.awmf.org.

Consensus-based recommendation	New 2022
EC Patients with locally advanced or metastatic SCC shall be offered first-line immunotherapy with a PD-1 inhibitor approved for this indication.	
Strong consensus	

Consensus-based recommendation	New 2022
EC In case of progression under PD-1 blockade or contraindications to this type of immunotherapy, EGFR-directed therapy or chemotherapy shall be offered.	
Strong consensus	

Consensus-based recommendation	New 2022
EC In case of (distant) metastasis or locally advanced disease that cannot be controlled by surgical or radiotherapeutic interventions or only with major limitations of functionality, the indication for systemic therapy shall be considered.	
Strong consensus	

Consensus-based recommendation	New 2022
EC The indication for system therapy should be made in an interdisciplinary tumor board.	
Consensus	

If there is an indication for systemic therapy, then the best data, although only from uncontrolled studies, are available for PD-1 inhibitors (Table 3).

Palliative care

Regarding palliative care aspects, reference is made to the extended S3 guideline on palliative care of the guideline program on oncology.⁸

SURVEILLANCE AND PREVENTION

Follow-up examination methods

See long version at www.awmf.org.

Consensus-based recommendation	Modified 2022		
EC Follow-up of patients with SCC of the skin should be offered at risk-adjusted intervals according to the following schedule:			
	Year 1–2	Year 3–5	Year 6–10
Primary tumor stage			
Low risk	6-monthly	annually	–
High risk	3-monthly	6-monthly	annually
Immunosuppressed patients	3-monthly	3–6 monthly	3–6-monthly according to risk profile
Advanced stages			
Locally advanced/metastatic	3-monthly (up to and including year 3)	3–6 monthly (year 4–5)	6 monthly/annually
Strong consensus			

TABLE 3 Ongoing therapeutic trials with the use of PD1 blockers in cutaneous SCC (NBZ = next follow-up time).

Therapy	Line	Study phase	Number of evaluable patients	Median response duration (months)	Response rates	Reference
Cemiplimab	Any	1	26	Not reached (median NBI 11.1 months)	50%	Migden et al., 2018 ³
Cemiplimab (cohort 1, weight-adjusted dose every 2 weeks)	Any	2	59 (with metastases)	Not reached (median NBI 16.5 months).	49.2%	Migden et al., 2018 ³ Rischin et al., 2020 ⁴
Cemiplimab (Cohort 2, weight-adjusted dose every 2 weeks)	Any	2	78 (locally advanced)	Not reached (median NBI 9.3 months)	44%	Migden et al., 2020 ⁵
Cemiplimab (Cohort 3, fixed dose every 3 weeks)	Any	2	56 (with metastases)	Not reached (median NBZ 8.1 months)	41.1%	Rischin et al., 2020 ⁴
Pembrolizumab (CARSKIN)	1	2	39	Not reached (median NBI 22.4 months)	41%	Maubec et al., 2020 ⁶
Pembrolizumab	Any	2	29			NCT02964559
Pembrolizumab + radiotherapy	Post-operative adjuvant	2	37			NCT03057613
Pembrolizumab (Keynote 629)	Any	2	105	Not reached (median NBI 11.4 months)	34%	Grob et al., 2020 ⁷

Consensus-based statement		New 2022									
CE	The following examination methods are recommended depending on risk factors of the primary tumor, immunosuppression or after locally advanced and metastatic squamous cell carcinoma of the skin according to the present scheme:										
		Physical examination			Lymph node sonography			Imaging examinations CT, MRT, PET-CT			
Year		1–2	3–5	6–10	1–2	3–5	6–10	1–3	4–5	6–10	
Primary tumors		2x	1x	–	0–2x	–	–	–	–	–	
Low risk											
High risk		4x	2x	1x	1–4x***	0–2x***	–	0–/2x**	–	–	
Immunocompromised patients		4x	2–4x	2–4x	1–4x***	0–2x***	–	0–2x**	–	–	
Locally advanced/metastasized		4x	4x	2–4x	4x	2x	–	2x	–	–	
*For R0 resected stages, Low risk: TD ≤ 6 mm, ≤ 4 mm in desmoplasia, G1–2 differentiation, High risk, TD > 6 mm, > 4 mm in desmoplasia, G3–4 differentiation, perineural tumor growth, immunocompromised and patients with secondary tumors, see question I.3.											
**In the case of perineural tumor growth											
***Depending on the risk factors											
Consensus											

Consensus-based recommendation	Checked 2022
EC Clinical examination shall be performed regularly in all patients after squamous cell carcinoma of the skin as part of follow-up and shall include inspection of the entire skin organ and inspection and palpation of the primary excision site, in-transit pathway, and regional lymph node station.	
Strong consensus	

Consensus-based recommendation	Modified 2022
EC Lymph node ultrasonography should be performed in patients at high risk of metastasis* or with unclear palpation findings and in cases of state after locally advanced and metastatic squamous cell carcinoma of the skin.	
*High risk: TD > 6 mm, > 4 mm in desmoplasia, G3–4 differentiation, perineural tumor growth, immunosuppressed and patients with secondary tumors.	
Strong consensus	

Consensus-based recommendation	Modified 2022
EC X-ray thoracic examinations and abdominal ultrasonography should not be routinely performed during follow-up.	
Strong consensus	

Consensus-based recommendation	Modified 2022
EC Cross-sectional imaging should be performed to clarify recurrences, e.g., with suspected involvement of functional structures, in cases of locally advanced or metastatic squamous cell carcinoma of the skin, or in cases of suspected perineural tumor growth or metastatic findings.	
Strong consensus	

Consensus-based recommendation

New 2022

EC All patients with squamous cell carcinoma of the skin (e.g., even with a tumor thickness of ≤ 2.0 mm without the presence of other risk factors) shall be followed up because of the possible development of secondary skin tumors. The frequency of follow-up should also consider the number of actinic keratoses as well as squamous cell carcinomas of the skin in the history.

Strong consensus

Measures of the primary prevention of actinic keratosis and squamous cell carcinoma of the skin

On this topic, we refer to the detailed S3 guideline “Prevention of skin cancer”.⁹

Preventive measures for special risk groups

On this topic, we refer to the detailed S3 guideline “Prevention of skin cancer”.⁹

AFFILIATIONS

¹Department of Dermatology, Uniklinikum Erlangen, Friedrich-Alexander-Universität Erlangen-Nürnberg (FAU), Erlangen, Germany

²Comprehensive Cancer Center Erlangen-European Metropolitan Area of Nuernberg, (CCC ER-EMN), Erlangen, Germany

³Center of Dermatoonology, University Department of Dermatoonology, Eberhard-Karls-University Tuebingen, Tübingen, Germany

⁴Department of Dermatology, Johannes Wesling Medical Center, Ruhr University Bochum Campus Minden, Minden, Germany

⁵Department of Dermatology, University Hospital Carl Gustav Carus, Technical University Dresden, Dresden, Germany

⁶Department of Dermatology, Venerology, and Allergology, St. Josef-Hospital, Ruhr-University Bochum, Bochum, Germany

⁷Translational Skin Cancer Research (TSCR), DKTK Essen/Düsseldorf, University Medicine Essen, Essen, Germany

⁸Association of Dermatological Prevention, Buxtehude, Germany

⁹Institute of Clinical Social Medicine, University Heidelberg, Heidelberg, Germany

¹⁰CentroDerm Wuppertal, Wuppertal, Germany

¹¹Charité – Universitätsmedizin Berlin, corporate member of Freie Universität Berlin and Humboldt Universität zu Berlin, Berlin, Germany

¹²Clinic of Dermatology, Hospital Bethesda, Freudenberg, Germany

¹³Department of Dermatotomy, St. Josefhospital Heidelberg GmbH, Heidelberg, Germany

¹⁴Department of Dermatology, Venereology und Allergy, University Medicine Mannheim, Mannheim, Germany

¹⁵Department of Dermatology and Allergy, University Hospital, LMU Munich, München, Germany

¹⁶German Guideline Program in Oncology, German Cancer Society, Berlin, Germany

¹⁷Dermatology and Laser Consultation Center, Landau, Germany

¹⁸Department of Dermatology, Mainz University Medical School, Mainz, Germany

¹⁹Elbe Clinics Stade Buxtehude GmbH, Medical Center Buxtehude, Buxtehude, Germany

²⁰Department of Dermatology, University Hospital Schleswig-Holstein Campus Kiel, Kiel, Germany

²¹Department of Dermatology & Venerology, Vivantes Hospital Neukölln, Berlin, Germany

²²DERMPATH Muenchen, München, Germany

²³Department of Dermatology and Environmental Medicine, University of Osnabrueck, Institute for Interdisciplinary Dermatological Prevention and Rehabilitation (iDerm) at the University of Osnabrueck, Osnabrück, Germany

²⁴Study Center for Dermatotomy, University Hospital Tuebingen, Eberhard-Karls-University, Tübingen, Germany

²⁵Clinic and Polyclinic for Radiooncology, University Medical Center Regensburg, Regensburg, Germany

²⁶Clinic for Trauma-, Orthopedics-, and Plastic Surgery, Department for Plastic-, Aesthetic- and Handsurgery, Gütersloh, Germany

²⁷Robert Koch-Institute, Berlin, Germany

²⁸German Social Accident Insurance (DGUV), Berlin, Germany

²⁹Department of Dermatology, Medical Center Bremen-Ost, Bremen, Germany

³⁰Skin Hospital, Skin Cancer Center, Ludwigshafen Hospital, Ludwigshafen, Germany

³¹Department of Dermatology, Klinikum Dortmund, Dortmund, Germany

³²Association of the Scientific Medical Societies in Germany (AWMF), Institute for Medical Knowledge Management, c/o Philipps Universität Marburg, Marburg, Germany

³³Department of Diagnostic and Interventional Radiology, Eberhard-Karls-University Tuebingen, Tübingen, Germany

³⁴Pediatric Dermatology Discipline, Dermato-oncology Research Facility, “Colentina” Clinical Hospital, Bucharest 020125, “Carol Davila” University of Medicine and Pharmacy, Bucharest, Rumania

³⁵Department of Dermatology and Allergology, Klinikum Vest GmbH, Recklinghausen, Germany

³⁶Dermatologie am Regierungsviertel, Berlin, Germany

³⁷Institute of Occupational Medicine, Charité-Universitätsmedizin Berlin, Corporate Member of Freie Universität Berlin and Humboldt Universität zu Berlin, Berlin, Germany

³⁸Department of Radiation Oncology, Martin-Luther-University Halle-Wittenberg, Halle/Saale, Germany

³⁹Department of Dermatology, University Hospital Augsburg, Augsburg, Germany

⁴⁰Klinikum Osnabrueck, Department for Oral and Maxillofacial Surgery, Plastic and Aesthetic Operations, Osnabrück, Germany

⁴¹Department of Otorhinolaryngology, Head and Neck Surgery, University Hospital Leipzig, Leipzig, Germany

ACKNOWLEDGEMENTS

Open access funding enabled and organized by Projekt DEAL.

CONFLICT OF INTEREST

See long version at www.awmf.org.

REFERENCES

- Heppt MV, Leiter U, Steeb T, et al. S3 guideline for actinic keratosis and cutaneous squamous cell carcinoma – short version, part 1: diagnosis, interventions for actinic keratoses, care structures and quality-of-care indicators. *J Dtsch Dermatol Ges.* 2020.18(3):275-294.
- Leiter U, Heppt MV, Steeb T, et al. S3 guideline for actinic keratosis and cutaneous squamous cell carcinoma (cSCC) – short version, part 2: epidemiology, surgical and systemic treatment of cSCC, follow-up, prevention and occupational disease. *J Dtsch Dermatol Ges.* 2020.18(4):400-413.
- Migden MR, Rischin D, Schmults CD, et al. PD-1 Blockade with cemiplimab in advanced cutaneous squamous-cell carcinoma. *N Engl J Med.* 2018. 379(4):341-351

4. Rischin D, Migden M, Lim A, Schmults C, Khushalani N, Hughes B, et al. Phase 2 study of cemiplimab in patients with metastatic cutaneous squamous cell carcinoma: primary analysis of fixed-dosing, long-term outcome of weight-based dosing. *J Immunother Cancer*. 2020;8(1):e000775.
5. Migden M, Khushalani N, Chang A, Lewis K, Schmults C, Hernandez-Aya L, et al. Cemiplimab in locally advanced cutaneous squamous cell carcinoma: results from an open-label, phase 2, single-arm trial. *Lancet Oncol*. 2020;21(2):294-305.
6. Maubec E, Boubaya M, Petrow P, et al. Phase II study of pembrolizumab as first-line, single-drug therapy for patients with unresectable cutaneous squamous cell carcinomas. *J Clin Oncol*. 2020;38(26):3051-3061.
7. Grob J, Gonzalez R, Basset-Seguín N, et al. Pembrolizumab monotherapy for recurrent or metastatic cutaneous squamous cell carcinoma: a single-arm phase II trial (KEYNOTE-629). *J Clin Oncol*. 2020;38(25):2916-2925.
8. Leitlinienprogramm Onkologie (Deutsche Krebsgesellschaft, Deutsche Krebshilfe, AWMF): Palliativmedizin für Patienten mit einer nicht-heilbaren Krebserkrankung. Langversion 2.2.2020.
9. Leitlinienprogramm Onkologie (Deutsche Krebsgesellschaft DK. S3-Leitlinie Prävention von Hautkrebs, Langversion 21). 2021; AWMF-Registernummer: 032/052OL.

How to cite this article: Leiter U, Heppt MV, Steeb T, et al. S3 guideline „actinic keratosis and cutaneous squamous cell carcinoma“ – update 2023, part 2: epidemiology and etiology, diagnostics, surgical and systemic treatment of cutaneous squamous cell carcinoma (cSCC), surveillance and prevention. *JDDG: Journal der Deutschen Dermatologischen Gesellschaft*. 2023;21:1422–1433. <https://doi.org/10.1111/ddg.15256>