

LETTER TO THE EDITOR

A distinct clinical phenotype in a German kindred with motor neuron disease carrying a *CHCHD10* mutation

Delia Kurzwelly,^{1,2} Stefanie Krüger,³ Saskia Biskup³ and Michael T. Heneka^{1,2}

1 Department of Neurology, University of Bonn, Bonn, Germany

2 German Centre for Neurodegenerative Diseases (DZNE), Bonn, Germany

3 CeGaT GmbH - Centre for Genomics and Transcriptomics, Tübingen, Germany

Correspondence to: Michael T. Heneka, MD,
Prof. of Clinical Neuroscience,
Department of Neurology,
University of Bonn, and German Centre for Neurodegenerative Diseases (DZNE),
Sigmund-Freud-Straße 25,
D-53127 Bonn, Germany
E-mail: michael.heneka@ukb.uni-bonn.de

Sir,

Emerging data provide evidence for *CHCHD10* as a new candidate gene in familial amyotrophic lateral sclerosis (ALS) and frontotemporal dementia (FTD) (Bannwarth *et al.*, 2014; Johnson *et al.*, 2014; Müller *et al.*, 2014). This gene encodes a mitochondrial protein located in the intermembrane space (Bannwarth *et al.*, 2014). Mutant *CHCHD10* may lead to altered mitochondrial genome stability and maintenance of cristae junctions (Bannwarth *et al.*, 2014; Chaussenot *et al.*, 2014). So far, three different mutations located either in the non-structured N-terminal region or in the α -helix of the *CHCHD10* gene have been attributed to cause both ALS and ALS-FTD phenotypes.

Here we report another large German family with a history suggestive of autosomal-dominant motor neuron disorder (Fig. 1). After excluding a repeat expansion in *C9orf72* and mutations in 25 other known ALS genes in parallel by next-generation sequencing we performed whole-exome sequencing of three affected individuals (Patients III.1, III.2 and III.9). This identified a heterozygous c.44G>T variant (p.Arg15Leu) in exon 2 of the *CHCHD10* gene which has recently been reported by Müller *et al.* (2014) as the likely cause of pure ALS in two German families and was also identified in three families with familial motor neuron disease in the USA (Johnson *et al.*, 2014). The mutation segregated with disease in another cousin (Patient III.5) of our index patient

(Patient III.1) and could not be identified in his 41-year-old son (Patient IV.1) and an 85-year-old aunt (Patient II.7), who are both unaffected. No DNA samples were available from the deceased Patients I.1, II.3, II.6 and II.9, as well as from further to-date unaffected family members. However, because of the variable age of onset ranging from 41 to 73 years (59.5 ± 11.2 years; mean \pm SD) only such individuals without clinical signs of a motor neuron disorder clearly after the latest disease onset within the family may really be regarded healthy. In our case, only individuals from the second generation (Fig. 1) would now have fulfilled this criterion with all other unaffected family members still being at risk.

Of note, seven of eight affected patients were males. All of them were diagnosed with motor neuron disease/ALS. Similar to the German families carrying the p.Arg15Leu mutation described by Müller *et al.* (2014), all of our patients exhibited upper limb onset exclusively, presenting with progressive, mostly atonic paresis, muscle wasting and fasciculations in either proximal (Patients II.6 and III.1 with symmetrical onset) or distal muscles (Patients III.2, III.5 and III.9 with a more asymmetrical distribution at onset), spreading out slowly and leading to severe disability of the upper extremities as disease progressed. At least three patients developed bulbar symptoms, however, not requiring supplemental tube feeding. None showed emotional instability. Patients III.1, III.2, III.5 and III.9

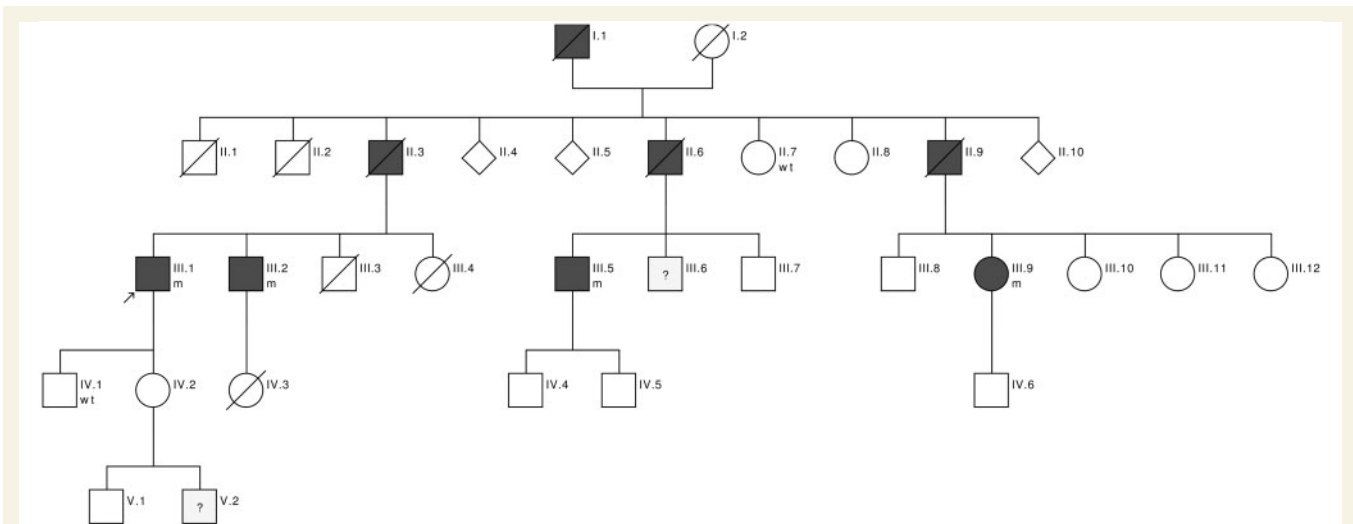


Figure 1 Kindred pedigree. Available genotypes are shown. The arrow denotes the index patient. Filled symbols represent affected individuals. DNA for genetic testing was not available from the deceased Patients I.1, II.3, II.6 and II.9, and from further unaffected individuals. Clinical and demographic information could not be obtained for all family members. Pedigree created with the CeGaT PedigreeChartDesigner. wt = wild-type; m = mutant.

have hyperreflexia and spasticity of the lower limbs and developed a spastic gait disorder, but not revealing marked weakness of the legs. Nevertheless, Patients III.5 and III.9 are wheelchair-bound due to imbalance as a result of the spastic gait and profound palsy of the upper extremities. After a disease course of 15 years, Patient III.5 has flaccid paraplegia of the arms and a pronounced dropped head syndrome, severe bulbar palsy as well as extensive hyperreflexia, spasticity and spontaneous cloni of both legs with largely preserved muscular strength. In the last follow-up, he exhibited cerebellar oculomotor disorder with abnormal smooth pursuits, dysmetric saccades and gaze-evoked nystagmus, but otherwise no signs of cerebellar ataxia. Patient III.6 presented with fasciculations but no further clinical and diagnostic signs of a motor neuron disease. However, he was lost to follow-up. Furthermore, one grandson (Patient V.2) of Patient III.1, who is now 12 years old, is suffering from muscle weakness and mental retardation of unknown aetiology since infancy. Work-up in a specialized genetic and neuropaediatric centre failed to establish a diagnosis. Symptoms do not seem to progress over time according to his mother, but to date he has not been available for clinical examination in our department. None of our patients have symptoms suggestive of frontotemporal lobar degeneration.

ALSFRS-R (ALS Functional Rating Scale, Revised; Cedarbaum *et al.*, 1999) score is available for four individuals ranging from 40 after a disease course of 2 years in Patient III.1 to 20 in Patient III.5 15 years after disease onset with a mean progression rate of 3.3 per year. EMG (performed in Patients III.1, III.2, III.5 and III.9) is indicative of a chronic neurogenic process rather than a myopathy. Neither of our patients had a muscle biopsy, but further examinations are in line with ALS diagnosis.

Proton magnetic resonance spectroscopy was performed in Patients III.1, III.2 and III.5, and revealed neurodegeneration within the primary motor area and in the brainstem. Survival times of four patients already deceased (Patients I.1, II.3, II.6, II.9) range from 2 to 12 years (5.8 ± 4.5 years; mean \pm SD). At present, four patients are still alive 2 to 15 years after disease onset (7 ± 5.6 years; mean \pm SD). Patients with an early disease onset ≤ 50 years had slower disease progression and survival times of >10 years as compared to family members who first became symptomatic in their seventies, suggesting that additional factors might contribute to a slowly progressive or else more aggressive phenotype. Unfortunately, no clinical information was provided by Johnson *et al.* (2014), but all patients were diagnosed with pure ALS.

In summary, we identified another ALS family with the heterozygous *CHCHD10* mutation c.44G>T (p.Arg15Leu). Thus far, among seven unrelated families with pure ALS and *CHCHD10* mutations, six have been reported to carry this variant. In contrast to the cases reported by Müller *et al.* (2014) our family history is suggestive of complete penetrance, given the absence of unaffected individuals transmitting the disease. However, we are aware that this conclusion has limited power due to the small number of unaffected individuals available for genetic testing. Lacking clinical details of the three families reported by Johnson *et al.* (2014) we still may hypothesize that the three German families share a common phenotype with upper limb onset and predominant lower motor neuron affection, spasticity and bulbar signs occurring later in the disease course and an overall slower disease progression, even though survival times reported by Müller *et al.* (2014) were somewhat longer than in our family. To date, cerebellar signs were only found in one

patient diagnosed with pure ALS, but that may also be due to other, e.g. vascular, reasons as he is a heavy smoker. However, a more aggressive phenotype may be associated with later disease onset.

Although functional studies for the p.Arg15Leu variant are lacking and determination of the frequency of *CHCHD10* mutations in larger cohorts and thus additional data on the phenotypic spectrum are needed, our data further substantiate the assumed causal genetic link between *CHCHD10* mutations and ALS. Perspectively, for a subset of patients with familial ALS it may even be a reasonable diagnostic algorithm to search for a *CHCHD10* mutation before screening other known ALS genes, if patients present with upper limb onset, lower motor neuron dominance, variable spasticity and bulbar signs occurring during the disease course, and a more or less slow to moderate clinical deterioration with sustained ability to walk and longer survival times up to more than 10 years. Nevertheless, even within a family there seems to be clinical variability, especially with regard to the age of onset and survival times.

References

- Bannwarth S, Ait-El-Mkadem S, Chaussonot A, Genin EC, Lacas-Gervais S, Fragaki K, et al. A mitochondrial origin for frontotemporal dementia and amyotrophic lateral sclerosis through *CHCHD10* involvement. *Brain* 2014; 137: 2329–45.
- Cedarbaum JM, Stambler N, Malta E, Fuller C, Hilt D, Thurmond B, et al. The ALSFRS-R: a revised ALS functional rating scale that incorporates assessments of respiratory function. BDNF ALS Study Group (Phase III). *J Neurol Sci* 1999; 169: 13–21.
- Chaussonot A, Le Ber I, Ait-El-Mkadem S, Camuzat A, de Septenville A, Bannwarth S, et al. Screening of *CHCHD10* in a french cohort confirms the involvement of this gene in FTD-ALS. *Neurobiol Aging* 2014; 35: 2884.e1–4. <http://dx.doi.org/10.1016/j.neurobiolaging.2014.07.022>.
- Johnson J, Glynn S, Gibbs J, Nalls M, Sabatelli M, Restagno G, et al. Mutations in the *CHCHD10* gene are a common cause of familial amyotrophic lateral sclerosis. *Brain* 2014; 137(Pt 12): e311. doi:10.1093/brain/awu265.
- Müller K, Andersen P, Hübers A, Marroquin N, Volk A, Danzer K, et al. Two novel mutations in conserved codons indicate that *CHCHD10* is a motor neuron disease gene. *Brain* 2014; 137(Pt 12): e309. doi:10.1093/brain/awu227.