

RELATO DE CASO

Community-acquired neonatal SARS-CoV-2 infection: case report

Infecção neonatal por SARS-CoV-2 adquirida na comunidade: relato de caso
Infección neonatal por SARS-CoV-2 adquirida en la comunidad: reporte de caso

Kamila Mohammad Kamal Mansour¹ ORCID 0000-0001-6025-1870

Bruna Eduarda Diehl¹ ORCID 0000-0002-1160-135X

Fabiana Rafaela Santos de Mello¹ ORCID 0000-0001-6268-1815

Daniela Miranda Uroda¹ ORCID 0000-0002-8999-0180

Rafik Ali Juma Hamid¹ ORCID 0000-0001-6013-7410

Éboni Marília Reuter¹ ORCID 0000-0002-0470-2910

Dulciane Nunes Paiva¹ ORCID 0000-0001-5629-3285

¹Universidade de Santa Cruz do Sul (UNISC), Santa Cruz do Sul, Rio Grande do Sul, Brasil.

Endereço: Avenida Independência, 2293, Santa Cruz do Sul – RS. CEP: 96815-900.
Bloco 42 - Programa de Pós-Graduação Mestrado e Doutorado em Promoção da Saúde (PPGPS).

E-mail: dulciane@unisc.br

Submetido: 06/11/2023

Aceite: 07/03/2024

ABSTRACT

Background and Objectives: Data collection on the incidence of COVID-19 is conducted less frequently in newborns (NB) than in adults. In view of the small number of described neonatal SARS-CoV-2 infections, in this study, we report a clinical case of community-acquired COVID-19 infection in a newborn. **Methods:** Clinical characteristics were collected from the medical records from April 2021 until the final outcome of the newborn in May 2021. **Results:** This article discusses the case of a full-term male newborn aged 38 weeks. On the 17th day of life, this newborn was admitted to the pediatric unit with fever and zone 4 jaundice, mild lower chest retraction and tachypnea. The mother was diagnosed with COVID-19. Late neonatal sepsis with pulmonary focus was detected. The newborn was hospitalized and the antigen test for COVID-19 came back positive. The condition of the neonate rapidly deteriorated and he was referred to the neonatal intensive care unit (NICU), where he was intubated and placed on pressure-controlled mechanical ventilation. During his second week in the NICU, he developed severe pulmonary hypertension with decreased peripheral oxygen saturation and tachycardia. The newborn required blood transfusion and was put into prone position during part of the treatment. Reductions in mechanical ventilation parameters were not tolerated by the NB's organism and he developed progressive hypoxemia. The newborn died 1 month and 3 days after hospitalization. **Conclusion:** Our study shows a case of community-acquired COVID-19 that progressed to the severe form of the disease.

Keywords: COVID-19. SARS-CoV-2. Neonatal Intensive Care. Communicable Diseases, Emerging.

RESUMO

Justificativa e Objetivos: A coleta de dados sobre a ocorrência de covid-19 em recém-nascidos (RN) não é tão frequente quanto em adultos. Portanto, devido ao baixo número de infecções neonatais por SARS-CoV-2 descritas, relatamos, neste estudo, um caso clínico de infecção por covid-19 em um recém-nascido na comunidade. **Métodos:** As características clínicas foram coletadas dos prontuários desde abril de 2021 até o último desfecho do RN, em maio de 2021. **Resultados:** Este artigo abordará um RN do sexo masculino, a termo, com 38 semanas. No 17º dia de vida, o RN deu entrada na unidade pediátrica com quadro de febre e icterícia zona 4, leve retração torácica inferior e taquipneia. A mãe foi diagnosticada com covid-19. Foi detectada sepse neonatal tardia com foco pulmonar. O RN foi internado e o teste de antígeno para covid-19 deu positivo. O quadro do RN regrediu rapidamente, sendo encaminhado à unidade de terapia intensiva neonatal (UTIN), onde foi entubado e adaptado à ventilação mecânica em modo pressão controlada. Na segunda semana de internação na UTIN, desenvolveu hipertensão pulmonar grave com diminuição da saturação periférica de oxigênio e taquicardia. O RN necessitou de transfusão sanguínea e a posição prona foi realizada por períodos. Reduções nos parâmetros do ventilador mecânico não foram toleradas e o RN apresentou hipoxemia progressiva. O RN faleceu um mês e três dias após a internação. **Conclusão:** Nossos achados apresentam um caso de covid-19 adquirida na comunidade que evoluiu para a forma grave da doença.

Descritores: Covid-19. SARS-CoV-2. Terapia Intensiva Neonatal. Doenças Transmissíveis Emergentes.

RESUMEN

Justificación y Objetivos: La recolección de datos sobre los contagios por covid-19 en recién nacidos (RN) no es tan frecuente como en adultos. En este contexto, y debido al bajo número de infecciones neonatales por SARS-CoV-2 descritas, en este estudio se describe un caso clínico de infección posnatal por covid-19 en un recién nacido en la comunidad. **Métodos:** Se recogieron características médicas de las historias clínicas desde abril de 2021 hasta el último resultado del RN en mayo de 2021. **Resultados:** Este artículo reporta el caso de un RN del sexo masculino, a término de 38 semanas. Al 17.º día de vida, el RN ingresó a la unidad de pediatría con fiebre e ictericia zona 4, leve retracción torácica inferior y taquipnea. La madre dio positivo para covid-19. En el RN se detectó sepsis neonatal tardía con foco pulmonar. Lo hospitalizaron, y la prueba de antígenos para covid-19 dio como resultado positivo. El estado del RN empeoró rápidamente, lo remitieron a la unidad de cuidados intensivos neonatales (UCIN), donde requirió intubación y ventilación mecánica controlada por presión. En la segunda semana en la UCIN, desarrolló hipertensión pulmonar grave con disminución de la saturación periférica de oxígeno y taquicardia. El RN requirió transfusión sanguínea, y lo pusieron en posición prona por períodos. El paciente no soportó las reducciones en los parámetros del ventilador mecánico y presentó una hipoxemia progresiva. El RN falleció un mes y tres días después de la hospitalización. **Conclusión:** Los hallazgos muestran un caso del covid-19 adquirido en la comunidad que progresó a la forma grave de la enfermedad.

Palabras Clave: COVID-19. SARS-CoV-2. Cuidado Intensivo Neonatal. Enfermedades Transmisibles Emergentes.

INTRODUCTION

Neonatal Severe Acute Respiratory Syndrome-Coronavirus-2 (SARS-CoV-2) infection is uncommon but some life-threatening infections have been reported.¹ SARS-CoV-2 can infect newborns (NB) either from the environment (community-acquired) or from the pregnant mother *in utero* or *peripartum* during labor.^{1,2} In children, COVID-19 infection rates are similar to those in adults, but with predominantly mild or asymptomatic manifestations. Transmission in children typically involves those with preexisting comorbidities, with only 1% requiring hospitalization, less than 0.02% requiring intensive care, and low mortality rates.³

Neonatal COVID-19 infections usually present mild symptoms, but in some cases, they develop into neonatal SARS-CoV-2 multisystem inflammatory syndrome, a more severe form of the disease³ Data collection on the incidence of COVID-19 is conducted less frequently in newborns (NB) than in adults. In view of the small number of described neonatal SARS-CoV-2 infections, in this study, we report a clinical case of postnatal community-acquired COVID-19 infection in a newborn.

METHODS

This is an observational and prospective case report of a newborn admitted to a teaching hospital in southern Brazil. Clinical characteristics were collected from medical records from April 2021 to the final outcome of the newborn in May 2021. The study was conducted in accordance with the ethical standards established by the Ministry of Health Resolutions 466/2012, 510/2016 and 580/2018. Written informed consent was obtained from the NB's mother. The Research Ethics Committee of the University of Santa Cruz do Sul approved this study on April 9, 2021, under no. 4.641.390 and CAAE no. 45402221.5.0000.5343.

RESULTS

This is the case of a full-term male newborn (38 weeks), Apgar 9/9 and large for gestational age. He was born to a 24-year-old mother by Cesarean section with complete prenatal care. There were no complications during pregnancy and delivery, and the baby was discharged 48hs *post-partum*. The newborn was healthy, exclusively breastfed, and had normal physiological functions until the 17th day of life, when he was admitted to the pediatric unit with fever (38.5°C) and zone 4 jaundice, mild lower chest retraction and

tachypnea (65 breaths/min). The mother was diagnosed with COVID-19. The NB's medical records did not contain information on the mother's vaccination status.

Seven days after the onset of the mother's symptoms, the newborn became symptomatic. Community-acquired SARS-CoV-2 was suspected. The newborn was tested for other vertically transmitted infectious diseases, but all results were negative. Late neonatal sepsis with pulmonary focus was detected (Rodwell).⁴ The newborn was subsequently hospitalized (Figure 1).




Figure 1. Timeline prior to admission to the neonatal intensive care unit.

According to the protocol of the hospital, the imaging exams (Figure 2) and the antigen test for COVID-19—performed using a nasal swab—yielded positive results for COVID-19. The NB's condition rapidly deteriorated and he was referred to the neonatal intensive care unit (NICU) (Figure 3), where he was intubated and placed on pressure-controlled mechanical ventilation (MV).

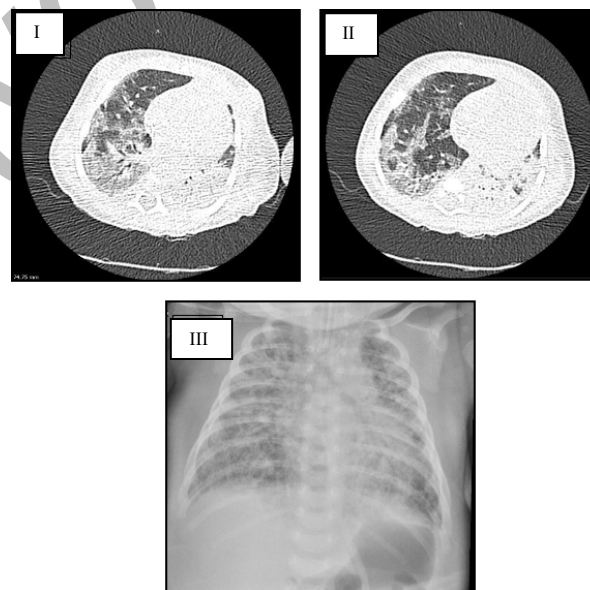


Figure 2. Chest computed tomography. Computed tomography (I and II) showing ground-glass opacities with reticulation (mosaic), multifocal, predominantly peripheral, affecting 50–75% of the parenchyma, accompanied by consolidations, typical alterations of viral pneumonia. Chest X-ray (III) showing diffuse

and heterogeneous interstitial infiltrates affecting practically the entirety of both lungs. The image also shows bronchial wall thickening and pulmonary hyperinflation.

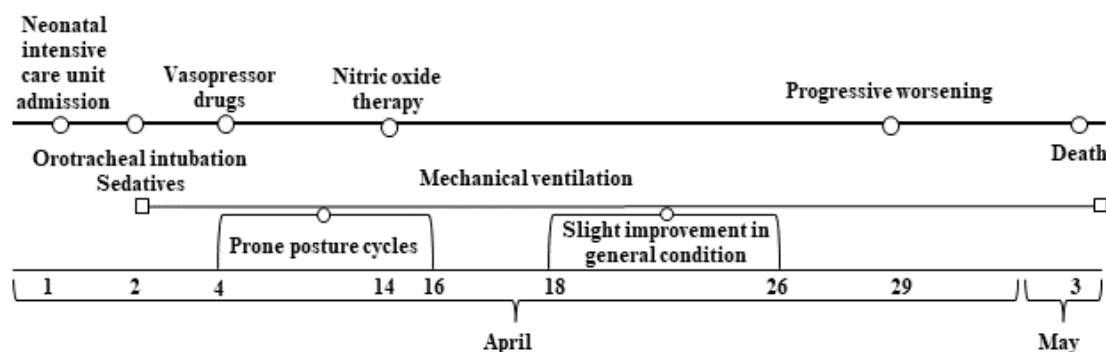


Figure 3. Timeline after admission to the neonatal intensive care unit.

Laboratory tests showed a d-dimer of 1,892.2 ng/mL, and prophylaxis with enoxaparin was started. The newborn had bacterial pneumonia confirmed by blood culture, the infection was diagnosed on his first day at the NICU. He was treated with oxacillin and amikacin. Based on positive blood cultures performed during hospitalization, he was also treated with vancomycin and cefepime, azithromycin, vancomycin, and meropenem. He presented hemodynamic instability/hypotension and severe pulmonary hypertension (PH). The newborn showed a decrease in peripheral oxygen saturation, as well as tachycardia and generalized edema.

The neonate required blood transfusions and underwent nitric oxide therapy for PH with unsatisfactory results. In addition, he received physical therapy three times per day and was put into prone position during part of the treatment. Reductions in MV parameters were not tolerated by his organism. On his last day of life, the newborn was pale, cyanotic, hypothermic and in anasarca. He developed progressive hypoxemia and died due to complications caused by COVID-19 infection after 1 month and 3 days of hospitalization (Table 1).

Table 1. Arterial blood gas tests and ventilatory strategies used during key periods of the neonate's hospitalization in the neonatal intensive care unit.

Hospitalization period	1 st ND Admission 24 th DL	2 nd ND 25 th DL	2 nd ND 25 th DL	2 nd ND 25 th DL	8 th ND 31 st DL	18 th ND 41 st DL	30 th ND 53 rd DL
Date	04/01/2021	04/01/2021	04/01/2021	04/01/2021	04/09/2021	04/19/2021	05/01/2021
Ventilatory strategy	LF (O2 3 l/min)	Campanula (15 l/min/80%)	HF (10 l/min/100%)	IMV (PCV 20×6/75%)	IMV (PCV 38×8/100%)	IMV (PCV 40×8/100%)	IMV (PCV 39×7/100%)

pH	7.36	7.40	7.37	7.36	7.38	7.53	7.24
PaO₂ (mmHg)	54.8	53.2	37.5	105.9	143.8	42.7	22.8
PaCO₂ (mmHg)	40.3	42.5	50.0	49.1	53.0	49.8	66.2
HCO₃ (mEq/l)	22.6	25.7	28.4	27.5	30.6	40.7	27.9
CO₂ (mmol/l)	23.9	27.1	29.9	29.0	32.2	42.2	29.9
EB (mEq/l)	-2.5	+0.8	+2.3	+1.5	+4.4	+15.4	-1.2
SaO₂ (%)	86.9	88.1	72.0	97.7	99.1	76.8	28.7
RPaO₂/FiO₂	228.3	52.9	37.5	141.2	143.0	42.7	22.8

ND: NICU days; DL: days of life; LF: low-flow oxygen therapy; HF: high flow; IMV: invasive mechanical ventilation; PCV: pressure-controlled ventilation; PaO₂ partial pressure of oxygen in arterial blood; PaCO₂: partial pressure of carbon dioxide in arterial blood; HCO₃: serum bicarbonate concentration; CO₂: carbon dioxide; BE: base excess; SaO₂: oxygen saturation; RPaO₂/FiO₂: ratio of arterial oxygen partial pressure to fractional inspired oxygen.

DISCUSSION

Our case report differs from the existing literature because the NB case described had severe repercussions of the disease, causing the infected newborn to be hospitalized for 1 month and 3 days, until his death. Towards the end of his illness, the newborn presented anasarca, hypotension, and severe hypoxemia.

NB can also be infected with coronavirus, although they are less susceptible to the severe form, and they usually have a good prognosis, as shown by a study published in 2020, which reported the case of a 17-day-old newborn who presented transient fever and diarrhea but did not develop serious complications.^{5,6,7}

Cases of community-acquired transmission in this population occur via close contact with infected individuals or breastfeeding, as happened in this case. In NB, the presentation of COVID-19 tends to be asymptomatic or mild or does not differ from that of other neonatal diseases.³

Although the frequency of SARS-CoV-2 infection in neonates is extremely low, a portion of neonates affected by COVID-19 may present more severe symptoms, requiring intensive care, which indicates that the disease is more severe in newborns than in older children.⁸

Community-acquired cases are more likely to require hospitalization due to the presentation of the spectrum of clinical features of SARS-CoV-2 infection, including

fever, respiratory symptoms and feeding difficulties, as seen in this case report.⁹ We encourage the vaccination of pregnant women against the SARS-CoV-2 virus and further research on this topic in infected newborns.

REFERENCES

1. Raschetti R, Vivanti AJ, Vauloup-Fellous C, et al. Synthesis and systematic review of reported neonatal SARS-CoV-2 infections. *Nature Communications* 2020;11(1):1–10; doi: 10.1038/s41467-020-18982-9.
2. Hamid S, Woodworth K, Pham H, et al. COVID-19-associated hospitalizations among U.S. infants aged. *MMWR Morb Mortal Wkly Rep* 2022;71(45):1442–1448; doi: 10.15585/MMWR.MM7145A3.
3. Calvo C, Tagarro A, Méndez Echevarría A, et al. COVID-19 pandemic. What have we learned? *Anales de Pediatría (English Edition)*. 2021 Nov;95(5):382.e1–8. doi: 10.1016/j.anpede.2021.10.002.
4. Rodwell RL, Leslie AL, Tudehope DI. Early diagnosis of neonatal sepsis using a hematologic scoring system. *J Pediatr*. 1988 May;112(5):761-7. doi: 10.1016/s0022-3476(88)80699-1. PMID: 3361389.
5. Zeng LK, Tao XW, Yuan WH, et al. First case of neonate infected with novel coronavirus pneumonia in China. *Chinese Journal of Pediatrics*. 2020;58(0):E009.doi: 10.3760/cma.j.issn.0578-1310.2020.0009.
6. dos Santos Beozzo GPN, de Carvalho WB, Krebs VLJ, et al. Neonatal manifestations in COVID-19 patients at a Brazilian tertiary center. *Clinics*. 2020;75:e2407. <https://doi.org/10.6061/clinics/2020/e2407>
7. Wang S, Guo L, Chen L, et al. A case report of neonatal 2019 coronavirus disease in china. *clinical infectious diseases*. 2020; 71(15):853-857. doi: 10.1093/cid/ciaa225.
8. Dhir SK, Kumar J, Meena J, et al. Clinical features and outcome of sars-cov-2 infection in neonates: a systematic review. *Journal of Tropical Pediatrics*. 2021; 67(3):fmaa059. doi: 10.1093/tropej/fma
9. Raschetti R, Vivanti AJ, Vauloup-Fellous C, et al. Synthesis and systematic review of reported neonatal SARS-CoV-2 infections. *Nat Commun*. 2020;11:5164. doi: 10.1038/s41467-020-18982-9.

Authors' contributions:

Kamila Mohammad Kamal Mansour, Daniela Miranda Uroda, Éboni Marília Reuter, Dulciane Nunes Paiva contributed to the bibliographic research; writing of the abstract, introduction, methodology, discussion, interpretation and description of results, conclusions; revision of the manuscript; and preparation of tables and statistics. **Bruna Eduarda Diehl, Fabiana Rafaela Santos de Mello, Rafik Ali Juma Hamid** contributed to the bibliographic research; writing the abstract, introduction, methodology, discussion, conclusion; and revision of the manuscript.

All authors approved the final version and are responsible for all aspects of the work, including ensuring its accuracy and integrity.

Layout Version