



Computer Application of Ultrasound and Nuclear Magnetic Resonance Images for the Anatomical Learning of the Pelvis and the Female Pelvic Floor

Lourdes Asensio Romero¹ · Manuel Asensio Gómez¹ · Alberto Prats-Galino² · Juan Antonio Juanes Méndez¹

Received: 8 January 2019 / Accepted: 6 March 2019 / Published online: 19 March 2019
© Springer Science+Business Media, LLC, part of Springer Nature 2019

Abstract

Computer applications have been incorporated as valuable components in teaching, especially thanks to the advancement and innovation of new technologies during the last decades. The implementation of these computer developments in medicine and in the field of medical teaching with different utilities has been a revolution. This is manifested with greater intensity in certain medical specialties and in different areas of medical education, for example in the study of human anatomy, especially in parts of the human body of great complexity such as the pelvis and the pelvic floor of women. New technologies are also important in the use, study and interpretation of radiological tests, including ultrasound and nuclear magnetic resonance. This implies a change in the study and learning techniques of students, resident doctors and specialists in gynecology, radiodiagnosis, urology and many other medical specialties, considering new computer developments as a good alternative or complement to existing teaching methods. For this reason, we consider that computer programs like the one we present in this work can be very useful in the future of education and more specifically in the training of specialists in medicine.

Keywords Medical education · Computer development · Anatomical-radiological atlas · Female pelvic floor · Nuclear magnetic resonance · Ultrasound

Introduction

The advancement of new technologies has meant an important progress in medicine, especially in recent decades. The computer developments of which we can make use at present have stimulated a revolution in medical training, as well as in the

practice of medicine. Currently these technological advances are being incorporated in the field of medical education with the aim of improving the efficiency of this teaching, providing a more technical and modern basis that facilitates learning in different areas of medical knowledge [1–5].

Within the range of tools that we can use in medicine, we find image studies. These tests facilitate knowledge of the anatomy and diagnosis of many pathologies; therefore, it is essential in medical training a good knowledge and interpretation of these radiological procedures. Our aim has been to develop an interactive application that serves as a teaching tool, based on tutorial systems, which provides the user with ultrasound (endovaginal-transperineal-endoanal) images and magnetic resonance imaging (MRI) in order to guide them in their learning. In our work we have focused on a complex anatomical area such as the pelvis and the pelvic floor of women, contributing to the study of this area with a true anatomo-radiological atlas. [6–15].

The pelvic floor is the supporting structure of the organs of the pelvis. It is composed of muscle groups and connective structures (fascias and ligaments). Three compartments are established from the anatomo-functional point of view:

This article is part of the Topical Collection on *Education & Training*

✉ Lourdes Asensio Romero
lourdes90.ar@gmail.com

Manuel Asensio Gómez
mago59@usal.es

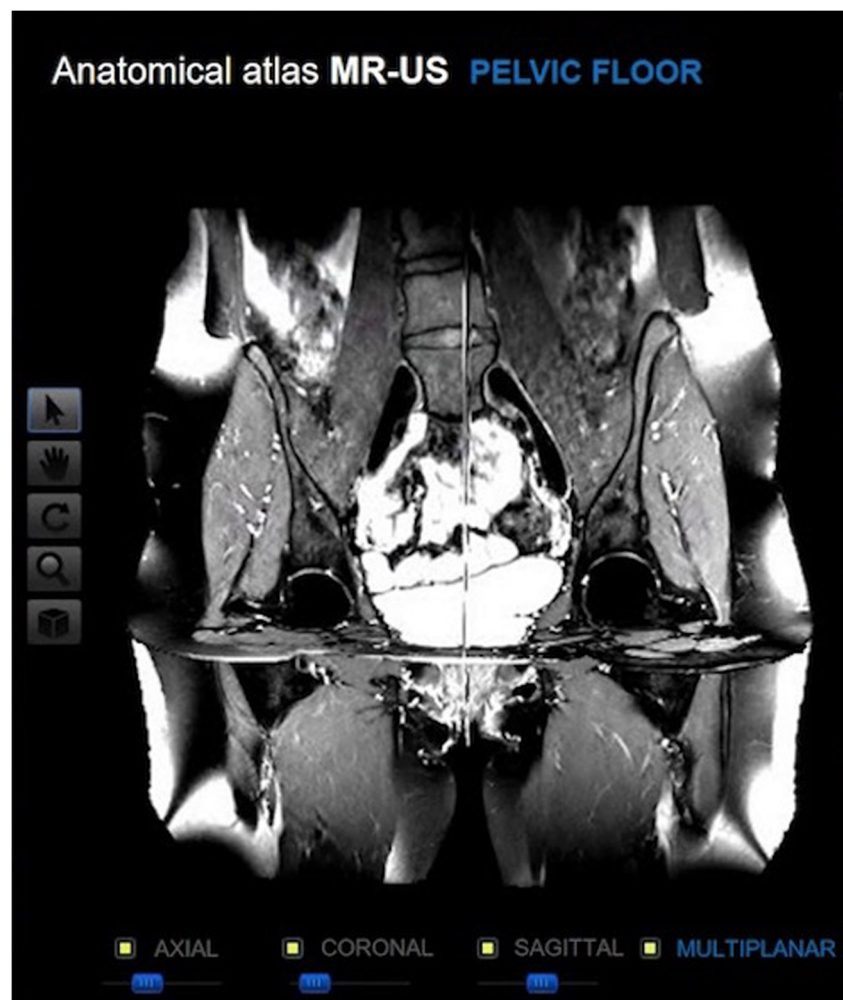
Alberto Prats-Galino
aprats@ub.edu

Juan Antonio Juanes Méndez
jajm@usal.es

¹ Department of Human Anatomy and Histology, School of Medicine, University of Salamanca, Salamanca, Spain

² Department of Human Anatomy and Embryology, School of Medicine, University of Barcelona, Barcelona, Spain

Fig. 1 Toolbar of small icons in the left area of the screen



anterior, middle or central and posterior. Complementary tests such as conventional radiology with contrast, nuclear magnetic resonance (NMR) and ultrasound are used to diagnose many pathologies of this anatomical area [16–26].

Our purpose is to provide medical students and resident doctors with a tool to expand their knowledge in anatomy and in the interpretation of radiological images, through the use of interactive computer applications. This form of learning through technological resources, such as the one we present, is considered a good alternative or complement to the teaching resources currently used [25–30].

Methodology

Acquisition and processing of radiological images

All images were obtained from a 29-year-old volunteer woman with no known history of gynaecological pathology.

Nuclear magnetic resonance

We used high resolution images, enhanced in different sequences (T1, T2 and proton density) in the three planes of space (axial, coronal and sagittal) for the overall anatomical study of the abdomen and pelvis. However, we only included high resolution images of the pelvis, spaced 0.5 mm and improved in proton density (DP) for our computer development. We use a 1.5 Tesla unit (Magnetine Healthineers, Siemens) to obtain images of the three planes of space.

The acquisition protocol consisted of sequences in two dimensions (2D) of the abdomino-pelvic region with the following parameters common to the three orientations: repetition time = 3220; echo time = 14; thickness of cut of 3 mm; matrix = 512×512 ; turning angle = 150° . The specific acquisition parameters for each orientation were for axial and sagittal planes: space between cuts = 3.6 mm and pixel space = $0.547 \text{ mm} \times 0.547 \text{ mm}$. For coronal plane: space between cuts = 4.8 mm and space between pixels = $0.586 \text{ mm} \times 0.586 \text{ mm}$.

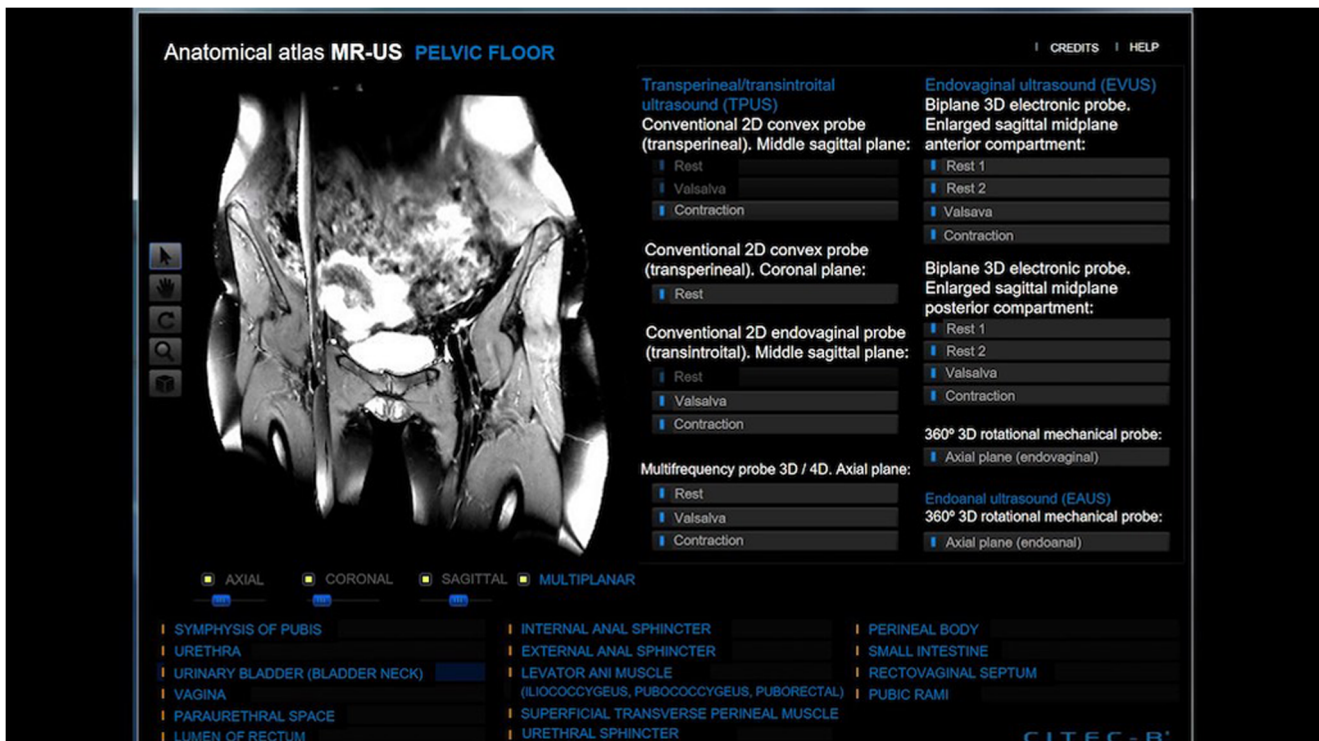

Fig. 2 Screen of the anatomico-radiological viewer of the pelvic floor. On the left side MRI with a list of main anatomical structures in the lower area; on the right side the ultrasound vision options are displayed

Ultrasound

Two ultrasound scanners (Siemens Acuson Antares and Voluson E6) were used to acquire the images of the pelvis and the pelvic floor, with different image modes [B-mode, M-mode, color Doppler, intensity Doppler, pulsed Doppler (PW), continuous Doppler (CW), and three / four dimensions (3D / 4D)].

These ultrasound devices allow the acquisition of anatomical and volumetric images from any plane, with advanced volume contrast and differentiation of structures with great precision. All this thanks to the technical specifications of both devices and the chance to use different types of probes: convex probe CH6-2 [2-6 MHz], endovaginal probe EV9F4 [4-9 MHz], intracavitary probe IC5-9-D [4-9 MHz] and convex probe 3D / 4D RAB4- 8-D [2-8 MHz].

The exploration routes used were vaginal, transintroital, rectal or endoanal and transperineal. It was necessary to place the patient in a position of dorsal lithotomy with the hips flexed, in light abduction and with the heels close to the buttocks to capture the images (at rest, contraction and with Valsalva maneuver) through the different routes of exploration.

Installation and minimum system requirements

Our computer program is prepared for self-execution.

The minimum computer equipment requirements are a 32 MB memory card that supports DirectX 8.0 in window mode, a Pentium III 450 MHz processor; 128 MB of RAM and 40 MB of free memory on the hard drive. It is recommended that the computer have a 3D acceleration card that supports DirectX 9.0 in window mode such as NVidia's GeForce range or the ATI Radeon range.

The programming has been made in visual C, including ActiveX controls, designed to optimize the graphic acceleration capabilities of current equipment.

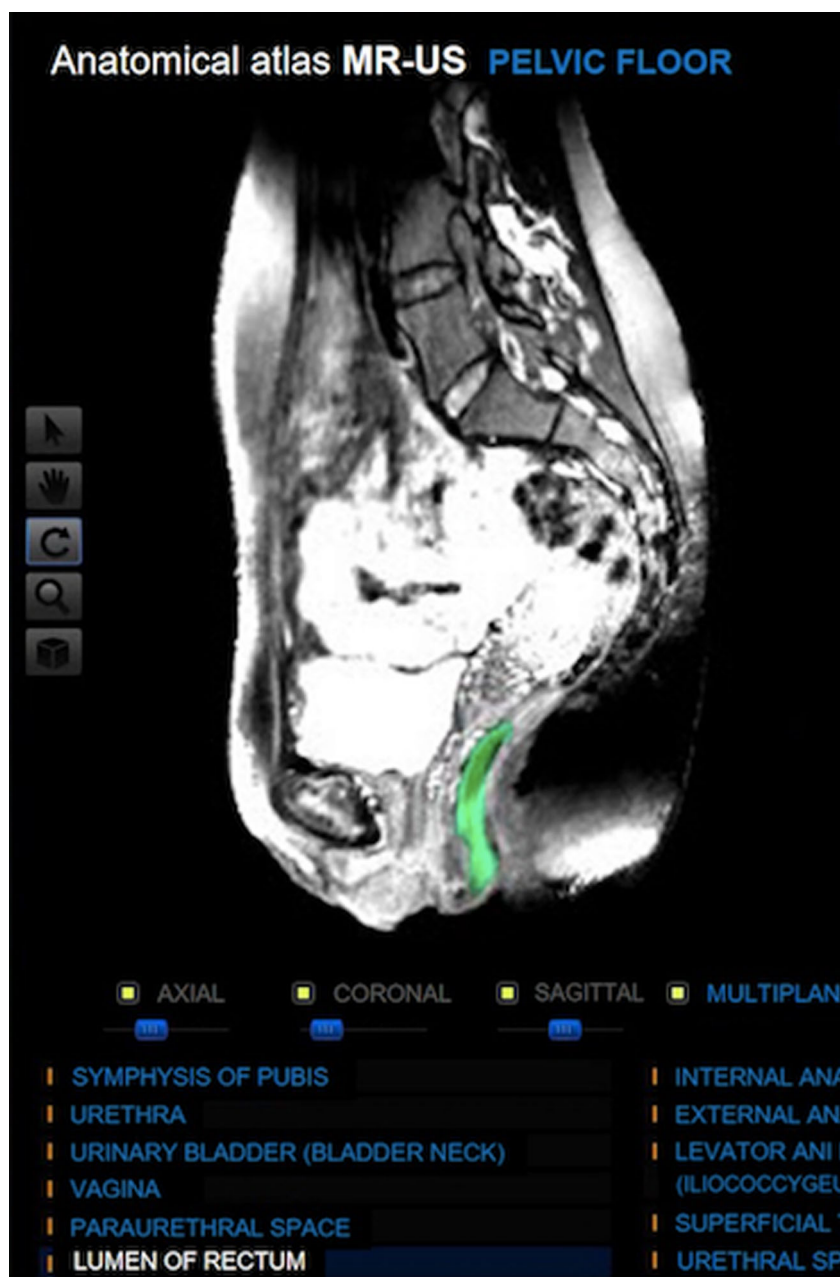Results

Generally the computer programs for teaching are formed by three modules: the module that manages the communication with the user, the module that contains the information of the program and the module that manages the actions of the computer and its answers to the actions of the users.

The interface is the element through which the communication between the users and the computer program is established.

An interface easy to understand and use, like the one we present in our computer program for the visualization and interaction with the anatomical structures of the female pelvis, through images of complementary tests such as NMR and ultrasound, allows users (students or resident doctors) improve and speed up their learning.

Fig. 3 MRI with anatomical structure identified in the image with green color



The options to handle the images are available in a toolbar with small icons (Fig. 1), which include a zoom, mobilization of the image, add or remove one of the planes of the space, and others options.

Our computer application allows the user to navigate freely through the MRI and ultrasound images. We can analyze from any angle and in the three planes of space (axial, coronal and sagittal) the sectional images of NMR. A list of the main anatomical structures of the female pelvis is shown in the lower area of the screen, being able to select any of them to locate it in the image (Figs. 2 and 3).

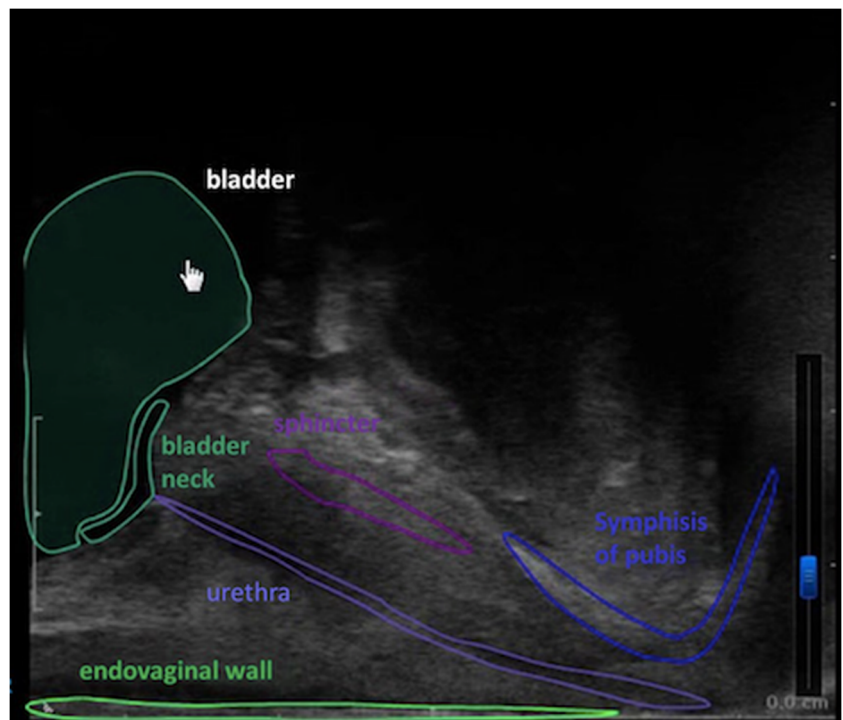
The ultrasound images can be evaluated one after the other, simulating movement and placement de cursor over the

structure shown it can be identified (Figs. 4 and 5). Our computer development allows the simultaneous display of MRI and ultrasound images, facilitating radiological correlation (Fig. 6).

Discussion

The technological and computer resources have been incorporated into our daily lives, innovating and facilitating many aspects of it. In the field of education there is a constant desire to incorporate technological advances, in order to implement student learning and provide teaching resources [1, 2, 27, 29].

Fig. 4 Ultrasound image with the identification of bladder when the cursor is over it



The use of computer programs is especially advantageous in the teaching of human anatomy and in the interpretation of radiological diagnostic tests, consisting of the anatomical visualization of each patient.

Imaging studies help in the knowledge of the anatomy and the diagnosis of different pathologies that affect the pelvis. These techniques have evolved over time, improving their diagnostic accuracy and serving as essential

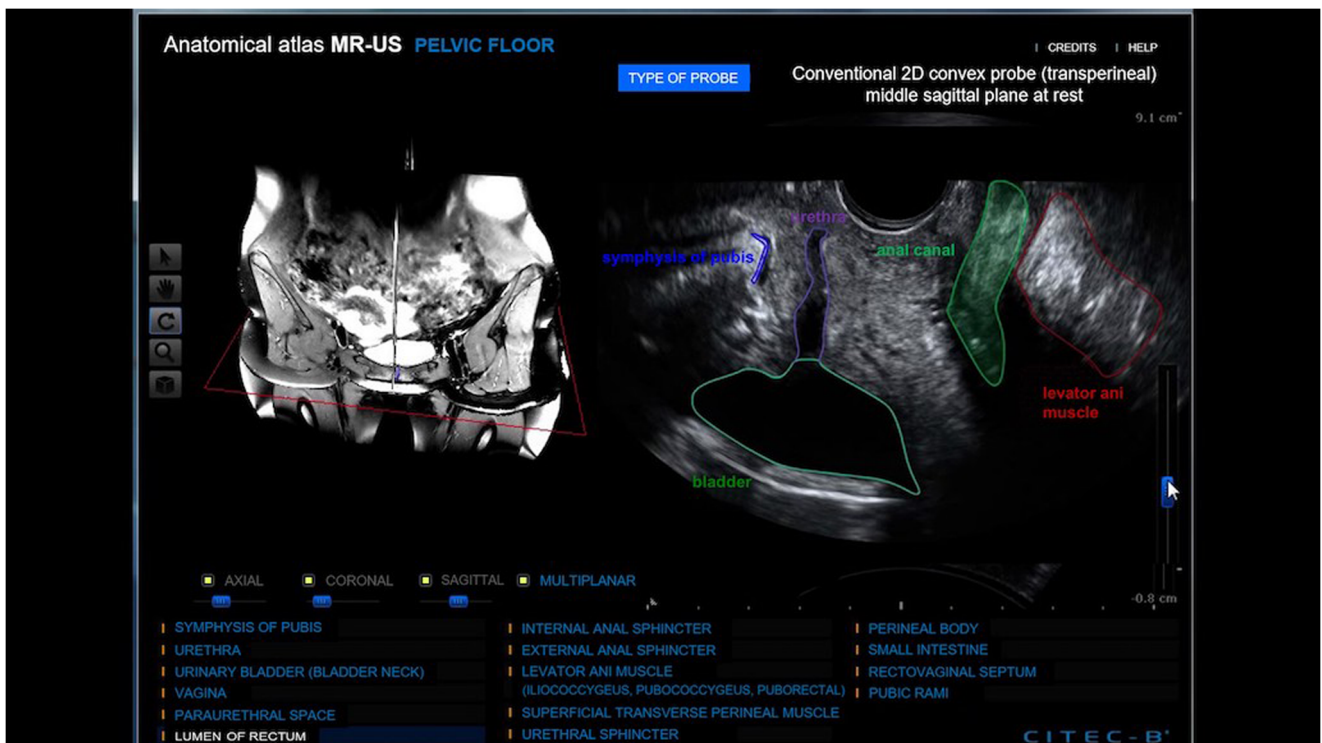

Fig. 5 Screen of the anatomico-radiological viewer. The ultrasound image on the right shows the identification of the anatomical structures that can be recognized

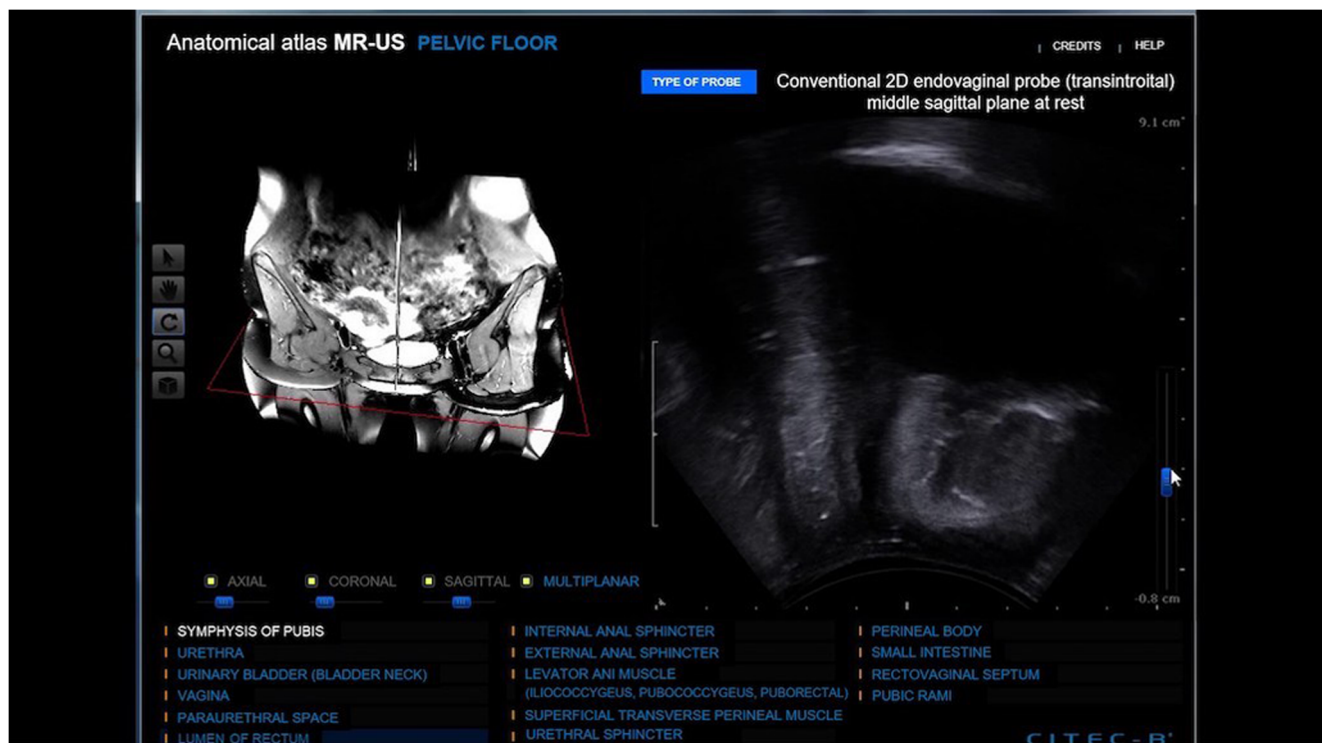


Fig. 6 Images of NMR and ultrasound are shown simultaneously

decision elements to support a therapeutic plan [6–11, 13–15, 31–33].

Physical examination is an important pillar of the assessment of anatomical lesions and alterations of pelvic static in the field of Urogynecology. Due to the anatomical complexity of the pelvis, the necessary precision in the location of the lesion, the importance of the existence of an adjacent anatomical lesion and the possibility of need surgical treatment it is necessary to use the images obtained from NMR and ultrasound for the diagnosis and treatment of some pathology processes [12, 16–26, 34–37].

For this reason, we consider that our computer development can be used as an important tool for medical education in the university or practicing a medical specialty such as gynecology. We have focused on an area of special anatomical and functional complexity such as the pelvis and the pelvic floor of women. We present images of ultrasound and NMR, with the possibility of assessing them together, making it possible for the user to relate the images and the anatomical information of each structure. The MRI of our computer program allows the visualization of the anatomical structures of the pelvis and the pelvic floor in the three planes of space. The user's interface of our computer development enables a simple and intuitive communication between user and program, permitting to focus on a specific pelvic structure, its information and its visualization using different imaging techniques. For all the reasons explained above, we consider our computer

development as a good teaching tool that can be useful for the diagnosis and treatment of pelvic floor pathology [29, 31].

Compliance with ethical standards

Conflict of interest L. Asensio Romero declares that she has no conflict of interest. M. Asensio Gómez declares that he has no conflict of interest. A. Prats-Galino declares that he has no conflict of interest. J. A. Juanes Méndez declares that he has no conflict of interest.

Ethical approval All procedures performed in studies involving human participants were in accordance with the ethical standards of the institutional and/or national research committee and with the 1964 Helsinki declaration and its later amendments or comparable ethical standards. This article does not contain any studies with animals performed by any of the authors.

Informed consent Informed consent was obtained from all individual participants included in the study.

References

1. Trelease, R. B., From chalkboard, slides, and paper to e-learning: How computing technologies have transformed anatomical sciences education. *Anat. Sci. Educ.* 9(6):583–602, 2016. <https://doi.org/10.1002/ase.1620>.
2. Tabernero Rico, R. D., Juanes Méndez, J. A., and Prats Galino, A., New Generation of Three-Dimensional Tools to Learn Anatomy. *J.*

- Med. Syst. 41(5):88, 2017. <https://doi.org/10.1007/s10916-017-0725-4>.
3. Ghosh, S. K., Evolution of illustrations in anatomy: A study from the classical period in Europe to modern times. *Anat. Sci. Educ.* 8(2):175–188, 2015. <https://doi.org/10.1002/ase.1479>.
 4. Estai, M., and Bunt, S., Best teaching practices in anatomy education: A critical review. *Ann. Anat. - Anat. Anzeiger* 208:151–157, 2016. <https://doi.org/10.1016/j.aanat.2016.02.010>.
 5. Berney, S., Bétrancourt, M., Molinari, G., and Hoyek, N., How spatial abilities and dynamic visualizations interplay when learning functional anatomy with 3D anatomical models. *Anat. Sci. Educ.* 8(5):452–462, 2015. <https://doi.org/10.1002/ase.1524>.
 6. Peng, Y., Khavari, R., Nakib, N. A., Boone, T. B., and Zhang, Y., Assessment of urethral support using MRI-derived computational modeling of the female pelvis. *Int. Urogynecol. J.* 27(2):205–212, 2016. <https://doi.org/10.1007/s00192-015-2804-8>.
 7. Giannini, A., Iodice, V., Picano, E., Russo, E., Zampa, V., Ferrari, V., and Simoncini, T., Magnetic Resonance Imaging–Based Three Dimensional Patient-Specific Reconstruction of Uterine Fibromatosis: Impact on Surgery. *J. Gynecol. Surg.* 33(4):138–144, 2017. <https://doi.org/10.1089/gyn.2016.0119>.
 8. García del Salto, L., Miguel Criado, J., Aguilera del Hoyo, L. F., Gutiérrez Velasco, L., Fraga Rivas, L., Manzano Paradela, M., Díez Pérez de las Vacas, M. I., Marco Sanz, A. G., and Fraile Moreno, E., MR Imaging–based Assessment of the Female Pelvic Floor. *RadioGraphics* 34(5):1417–1439, 2014. <https://doi.org/10.1148/rg.345140137>.
 9. Bitti, G. T., Argiolas, G. M., Ballicu, N., Caddeo, E., Cecconi, M., Demurtas, G., Matta, G., Peltz, M. T., Secci, S., and Siotto, P., Pelvic Floor Failure: MR Imaging Evaluation of Anatomic and Functional Abnormalities. *RadioGraphics* 34(2):429–448, 2014. <https://doi.org/10.1148/rg.342125050>.
 10. Bertrand, M. M., Macri, F., Mazars, R., Droupy, S., Beregi, J. P., and Prudhomme, M., MRI-based 3D pelvic autonomous innervation: a first step towards image-guided pelvic surgery. *Eur. Radiol.* 24(8):1989–1997, 2014. <https://doi.org/10.1007/s00330-014-3211-0>.
 11. Vellucci, F., Regini, C., Barbanti, C., and Luisi, S., Pelvic floor evaluation with transperineal ultrasound: a new approach. *Minerva Ginecol.* 70(1):58–68, 2018. <https://doi.org/10.23736/S0026-4784.17.04121-1>.
 12. Rostaminia, G., Manonai, J., Leclaire, E., Omoumi, F., Marchiorlatti, M., Quiroz, L. H., and Shobeiri, S. A., Interrater reliability of assessing levator ani deficiency with 360° 3D endovaginal ultrasound. *Int. Urogynecol. J.* 25(6):761–766, 2014. <https://doi.org/10.1007/s00192-013-2286-5>.
 13. Dietz, H. P., Pelvic Floor Ultrasound. *Clin. Obstet. Gynecol.* 60(1): 58–81, 2017. <https://doi.org/10.1097/GRF.0000000000000264>.
 14. Portilla, F., Rubio Manzanares Dorado, M., Pino Díaz, V., Vazquez Monchul, J. M., Palacios, C., Díaz Pavón, J. M., Sánchez Gil, J. M., and García Cabrera, A. M., Utilidad de la ecografía dinámica tridimensional en el estudio del suelo pélvico. *Cirugía Española* 93(8): 530–535, 2015. <https://doi.org/10.1016/j.ciresp.2014.11.005>.
 15. Chamié, L. P., Ferreira Rodrigues Ribeiro, D. M., Caiado, A. H. M., Warmbrand, G., and Serafini, P. C., Translabial US and Dynamic MR Imaging of the Pelvic Floor: Normal Anatomy and Dysfunction. *RadioGraphics* 38(1):287–308, 2018. <https://doi.org/10.1148/rg.2018170055>.
 16. Alt, C. D., Hampel, F., Hallscheidt, P., Sohn, C., Schlehe, B., and Broucker, K. A., 3 T MRI-based measurements for the integrity of the female pelvic floor in 25 healthy nulliparous women. *Neurourol. Urodyn.* 35(2):218–223, 2016. <https://doi.org/10.1002/nau.22697>.
 17. Alapatí, S., and Jambhekar, K., Dynamic Magnetic Resonance Imaging of the Pelvic Floor. *Semin. Ultrasound, CT MRI* 38(3): 188–199, 2017. <https://doi.org/10.1053/j.sult.2016.11.002>.
 18. Youssef, A., Montaguti, E., Sanlorenzo, O., Cariello, L., Awad, E. E., Pacella, G., Ghi, T., Pilu, G., and Rizzo, N., A New Simple Technique for 3-Dimensional Sonographic Assessment of the Pelvic Floor Muscles. *J. Ultrasound Med.* 34(1):65–72, 2015. <https://doi.org/10.7863/ultra.34.1.65>.
 19. Ram, R., Oliphant, S. S., Barr, S. A., and Pandey, T., Imaging of Pelvic Floor Reconstruction. *Semin. Ultrasound, CT MRI* 38(3): 200–212, 2017. <https://doi.org/10.1053/j.sult.2016.11.003>.
 20. Notten, K. J. B., Kluivers, K. B., Fütterer, J. J., Schweitzer, K. J., Stoker, J., Mulder, F. E., Beets-Tan, R. G., Vliegenhart, R. F. A., Bossuyt, P. M., Kruitwagen, R. F. P. M., Roovers, J. P. W. R., and Weemhoff, M., Translabial Three-Dimensional Ultrasonography Compared With Magnetic Resonance Imaging in Detecting Levator Ani Defects. *Obstet. Gynecol.* 124(6):1190–1197, 2014. <https://doi.org/10.1097/AOG.0000000000000560>.
 21. Graupera B, Pascual MÁ, Hereter L, Pedrero C (2018) Role of 3D Ultrasound in the Evaluation of Uterine Anomalies. In: Tinelli A, Pacheco LA, Haimovich S (eds) *Hysteroscopy*. Springer, Cham, pp 69–82. https://doi.org/10.1007/978-3-319-57559-9_8
 22. Kim, K. Y., Cheng, J. W., Shen, J. K., Wagner, H., and Staack, A., Translabial Ultrasound Evaluation of Pelvic Floor Structures and Mesh in the Urology Office and Intraoperative Setting. *Urology* 120:267, 2018. <https://doi.org/10.1016/j.urolgy.2018.07.004>.
 23. Murad-Regadas, S. M., Pinheiro Regadas, F. S., Veras Rodrigues, L., Pereira, J. J. R., Fernandes, G. O. S., Dealcanfreitas, I. D., and Mendonca Filho, J. J., Use of Dynamic 3-Dimensional Transvaginal and Transrectal Ultrasonography to Assess Posterior Pelvic Floor Dysfunction Related to Obstructed Defecation. *Dis. Colon Rectum* 57(2):228–236, 2014. <https://doi.org/10.1097/DCR.0000000000000028>.
 24. Morin, M., Bergeron, S., Khalifé, S., Mayrand, M. H., and Binik, Y. M., Morphometry of the Pelvic Floor Muscles in Women With and Without Provoked Vestibulodynia Using 4D Ultrasound. *J. Sex. Med.* 11(3):776–785, 2014. <https://doi.org/10.1111/jsm.12367>.
 25. Javadian, P., O’Leary, D., Rostaminia, G., North, J., Wagner, J., Quiroz, L. H., and Shobeiri, S. A., How does 3D endovaginal ultrasound compare to magnetic resonance imaging in the evaluation of levator ani anatomy? *Neurourol. Urodyn.* 36(2):409–413, 2017. <https://doi.org/10.1002/nau.22944>.
 26. Chan, L., and Tse, V., Pelvic floor ultrasound in the diagnosis of sling complications. *World J. Urol.* 36(5):753–759, 2018. <https://doi.org/10.1007/s00345-018-2253-3>.
 27. Yiasemidou, M., Glassman, D., Mushtaq, F., Athanasiou, C., Williams, M. M., Jayne, D., and Miskovic, D., Mental practice with interactive 3D visual aids enhances surgical performance. *Surg. Endosc.* 31(10):4111–4117, 2017. <https://doi.org/10.1007/s00464-017-5459-3>.
 28. Pujol, S., Baldwin, M., Nassiri, J., Kikinis, R., and Shaffer, K., Using 3D Modeling Techniques to Enhance Teaching of Difficult Anatomical Concepts. *Acad. Radiol.* 23(4):507–516, 2016. <https://doi.org/10.1016/j.acra.2015.12.012>.
 29. Coomes Peterson, D., and Mlynarczyk, G. S. A., Analysis of traditional versus three-dimensional augmented curriculum on anatomical learning outcome measures. *Anat. Sci. Educ.* 9(6):529–536, 2016. <https://doi.org/10.1002/ase.1612>.
 30. Salsi, G., Cataneo, I., Gaia Dodaro, M., Rizzo, N., Pilu, G., Sanz Gascón, M., and Youssef, A., Three-dimensional/four-dimensional transperineal ultrasound: clinical utility and future prospects. *Int. J. Women’s Health* 9:643–656, 2017. <https://doi.org/10.2147/IJWH.S103789>.
 31. Xue, Y. H., Ding, S. Q., Ding, Y. J., and Pan, L. Q., Role of three-dimensional endoanal ultrasound in assessing the anal sphincter morphology of female patients with chronic proctalgia. *World J. Gastroenterol.* 23(21):3900, 2017. <https://doi.org/10.3748/wjg.v23.i21.3900>.

32. Xuan, Y., Yue, S., Sun, L., Pei, Y., Wang, J., Tan, L., Lu, Z., Yang, L., An, Y., Jiang, Y., and Wu, Q., Repeatability of Female Midurethral Measurement Using High-Frequency 3-Dimensional Transvaginal Ultrasonography. *J. Ultrasound Med.*, 2017. <https://doi.org/10.1002/jum.1447>.
33. Wlazlak, E., Kluz, T., Kociszewski, J., Frachowicz, K., Janowska, M., Wlazlak, W., and Surkont, G., The analysis of repeatability and reproducibility of bladder neck mobility measurements obtained during pelvic floor sonography performed introitally with 2D transvaginal probe. *Ginekol. Pol.* 88(7):360–365, 2017. <https://doi.org/10.5603/GP.a2017.0068>.
34. Vergeldt, T. F. M., Notten, K. J. B., Stoker, J., Fütterer, J. J., Beets-Tan, R. G., Vliegen, R. F. A., Schweitzer, K. J., Mulder, F. E. M., van Kuijk, S. M. J., Roovers, J. P. W. R., Kluivers, K. B., and Weemhoff, M., Comparison of translabial three-dimensional ultrasound with magnetic resonance imaging for measurement of levator hiatal biometry at rest. *Ultrasound Obstet. Gynecol.* 47(5):636–641, 2016. <https://doi.org/10.1002/uog.14949>.
35. Thibault-Gagnon, S., McLean, L., Goldfinger, C., Pukall, C., and Chamberlain, S., Differences in the Biometry of the Levator Hiatus at Rest, During Contraction, and During Valsalva Maneuver Between Women With and Without Provoked Vestibulodynia Assessed by Transperineal Ultrasound Imaging. *J. Sex. Med.* 13(2):243–252, 2016. <https://doi.org/10.1016/j.jsxm.2015.12.009>.
36. Rostaminia, G., White, D., Quiroz, L. H., and Shobeiri, S. A., 3D pelvic floor ultrasound findings and severity of anal incontinence. *Int. Urogynecol. J.* 25(5):623–629, 2014. <https://doi.org/10.1007/s00192-013-2278-5>.
37. Kaniewska, M., Golofit, P., Heubner, M., Maake, C., and Kubik-Huch, R. A., Suspensory Ligaments of the Female Genital Organs: MRI Evaluation with Intraoperative Correlation. *RadioGraphics.* 38(7):2195–2211, 2018. <https://doi.org/10.1148/rg.2018180089>.

Publisher's Note Springer Nature remains neutral with regard to jurisdictional claims in published maps and institutional affiliations.